

Acute herpes zoster radiculopathy mimicking cervical radiculopathy after ChAdOx1 nCoV-19/AZD1222 vaccination

Andrew Dermawan ¹, Matthew Jun Min Ting ², Thomas Chemmanam ^{3,4}, Chok Lui²

¹General Medicine, Royal Perth Hospital, Perth, Western Australia, Australia

²Geriatric department, St John of God Midland Public and Private Hospitals, Midland, Western Australia, Australia

³Neurology, Sir Charles Gairdner Hospital, Nedlands, Western Australia, Australia

⁴Neurology, St John of God Midland Public and Private Hospital, Midland, Australian Capital Territory, Australia

Correspondence to

Dr Andrew Dermawan; andrew.dermawan@health.wa.gov.au

Accepted 29 March 2022

SUMMARY

This case report describes an 84-year-old man who presented with 3 weeks of gradually worsening right arm weakness associated with a painful vesicular rash across his arm. This occurred 3 days after his first dose of the ChAdOx1 nCoV-19/AZD1222 (University of Oxford, AstraZeneca and the Serum Institute of India) vaccine. The diagnosis was complicated by the presence of right C5–C6 foraminal stenosis compressing on the C6 nerve root sheath on non-contrast MRI, leading to an initial diagnosis of cervical radiculopathy. However, a positive varicella zoster virus-PCR test and findings of abnormal contrast enhancement of his right C5–C7 nerve roots on gadolinium-enhanced MRI resulted in a revision of his diagnosis to zoster radiculopathy. He was subsequently commenced on oral valaciclovir and made significant recovery. This report aims to highlight the diagnostic dilemma between cervical radiculopathy secondary to spondylosis and zoster radiculopathy and how an erroneous diagnosis could result in inappropriate, aggressive surgical intervention and delayed treatment with antiviral therapy.

BACKGROUND

Herpes zoster colonises the dorsal root ganglion and may remain dormant for years.¹ When reactivation occurs, patients often present with a vesicular rash in the dermatome of the affected root. These can cause sensory changes with marked allodynia.¹ When the motor nerve root is involved, it can produce weakness in the affected myotome, resulting in a clinical picture of zoster radiculopathy.¹

The pattern of weakness in zoster radiculopathy is similar to that of spinal radiculopathy, thus the diagnosis is often mistaken as the latter. Vesicular erythematous skin rash of shingles and associated neuralgia are often major clues to the diagnosis, which can be easily overlooked.² This report presents a case of an older man who presents with unilateral upper limb weakness in C5–C6 distribution, which occurs 3 days after SARS-CoV-2 vaccination and preceded the onset of vesicular rash.

CASE PRESENTATION

A male patient in his 80s presented to the emergency department with 3 weeks of gradually worsening right upper limb weakness with an associated painful rash. Initial symptoms were weakness of his shoulder followed by burning pain in his right arm

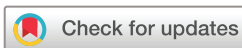1 week later with associated radiation up his neck and paraesthesia. He applied moisturising cream in attempt to alleviate the pain. Another week later, he developed a vesicular rash on the flexor surface of his arm and shoulder (figures 1 and 2). Coincidentally, he had his first dose of the ChAdOx1 nCoV-19/AZD1222 vaccine administered intramuscularly into the ipsilateral (right) arm 3 days prior to symptom onset. He consulted his general practitioner on day 17, who prescribed him doxycycline and requested an MRI scan of his cervical spine showing right C5 and C6 foraminal stenoses compressing on the C6 nerve root sheath.

His previous medical history included type 2 diabetes, hypertension, hypercholesterolaemia and shingles in the right ophthalmic nerve (V₁) dermatome 4 years ago. His medications were metformin extended release of 1000 mg/day, rosuvastatin 10 mg/day, candesartan/hydrochlorothiazide 32/12.5 mg/day, pantoprazole 40 mg two times a day, glucosamine 1000 mg/day, Blackmores Macu-Vision one tablet/day, insulin glargine U300 44 units daily and insulin glulisine 5–7 units with dinner.

On neurological examination of the right upper limb using the Medical Research Council Scale, he had 2/5 weakness of shoulder abduction and 3/5 weakness of elbow flexion and extension. His distal hand strength was 5/5. His biceps and brachioradialis reflexes were diminished, but triceps reflex was intact. The motor signs were in keeping with a lower motor neuron lesion. He had reduced sensation to C5 and C6 dermatomes, which coincided with the dermatomal distribution of his vesicular rash. His left upper limb and lower limb neurological examinations were unremarkable with no evidence of sensorimotor loss. Overall, his neurological examination was in keeping with C5 and C6 radiculopathy shown on the MRI spine.

INVESTIGATIONS

His blood test showed a mild inflammatory pattern with elevated white cell count of $14.1 \times 10^9/L$ (reference range 4.0–11.0) and lymphocytosis of $5.4 \times 10^9/L$ (reference range 1.0–4.0). The C reactive protein was normal at 1.9 mg/L (reference range <3.0). PCR testing of a skin lesion swab from a blister returned positive for varicella zoster virus (VZV), confirming the diagnosis of shingles.



© BMJ Publishing Group Limited 2022. No commercial re-use. See rights and permissions. Published by BMJ.

To cite: Dermawan A, Ting MJM, Chemmanam T, et al. *BMJ Case Rep* 2022;**15**:e248943. doi:10.1136/bcr-2022-248943

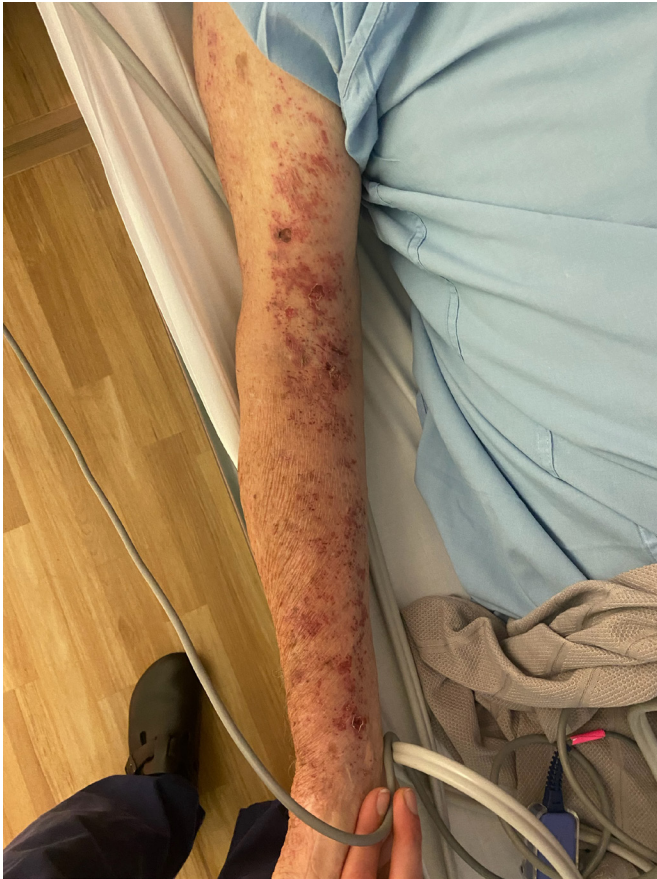

Figure 1 Vesicular rash on the flexor surface of his right arm corresponding to C5 and C6 dermatomes.

An MRI of the brain was performed and excluded intracranial pathology such as infarct, haemorrhage or tumour.

Given the time course of his weakness, neuralgia and rash, zoster radiculopathy was a differential to his initial diagnosis of C5/C6 radiculopathy. Therefore, a neurology consult was

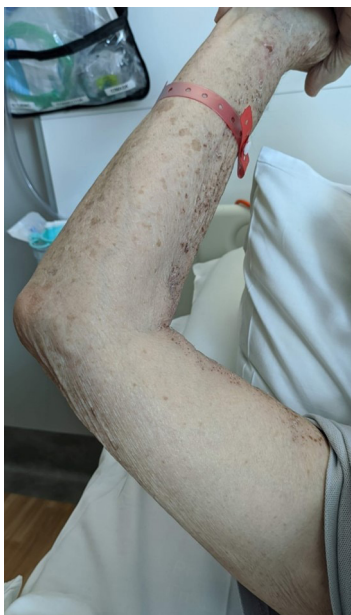

Figure 2 Another view of his vesicular rash corresponding to C5 and C6 dermatomes.

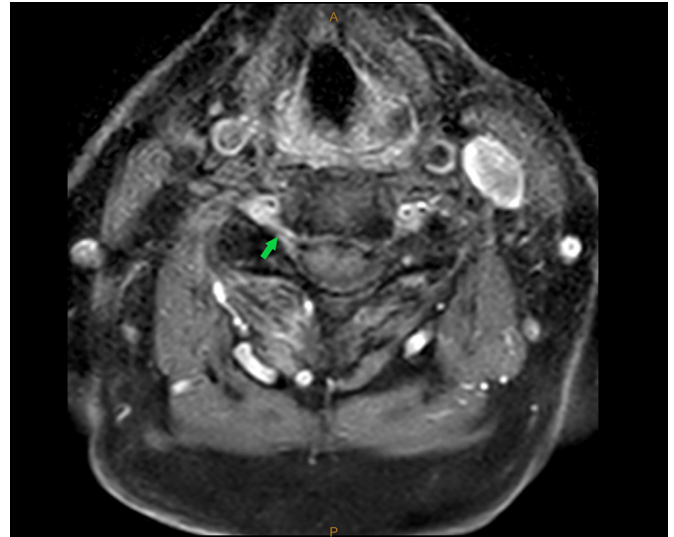


Figure 3 Gadolinium enhanced T1 cross-section of his cervical spine showing right C5 nerve root enhancement (green arrow).

obtained. Nerve conduction study and electromyography (EMG) showed denervation of C5/C6 myotomes, consistent with C5/C6 nerve root involvement. However, it was unable to differentiate between the two aetiologies. Lumbar puncture was not indicated as there was no evidence of central nervous system (CNS) involvement. Instead, a repeated MRI cervical spine with gadolinium contrast was performed and showed abnormal contrast enhancement of the C5, C6 and C7 nerve roots, suggestive of an inflammatory neuritis such as zoster radiculopathy (figure 3).

DIFFERENTIAL DIAGNOSIS

The main differential diagnosis to zoster radiculopathy in this case would be cervical spine radiculopathy to C5 and C6 secondary to cervical spondylosis. However, cervical radiculopathy would not usually enhance on MRI. Additionally, there would be a lack of response to antiviral therapy.

Other causes of inflammatory neuropathies would include diabetes or vasculitis. He had poor glycaemic control with glycated haemoglobin A1c of 9.8%. However, these would often present with bilateral symmetrical distal neuropathy in a glove and stocking distribution. Finally, he did not have raised inflammatory markers or other constitutional symptoms to suggest vasculitis.

Secondary and tertiary syphilis were also possibilities due to the presence of a rash and neuropathy; however, syphilis serology was negative on presentation.

TREATMENT

He was commenced on oral valaciclovir 1g three times a day for a total of 21 days on discussion with an infectious diseases specialist. After 5 days of treatment, his weakness and rash improved significantly. His right shoulder abduction weakness improved to 3/5, and right elbow flexion and extension improved to 4/5. Systemic glucocorticoid therapy was not indicated at the time given his initial response to oral antiviral therapy.

Postherpetic neuralgia developed 10 days after his onset of shingles, manifesting as intermittent intense burning pain over his shoulder as well as allodynia to the right C5 dermatome on light touch. He was commenced on pregabalin 75 mg two times a day.

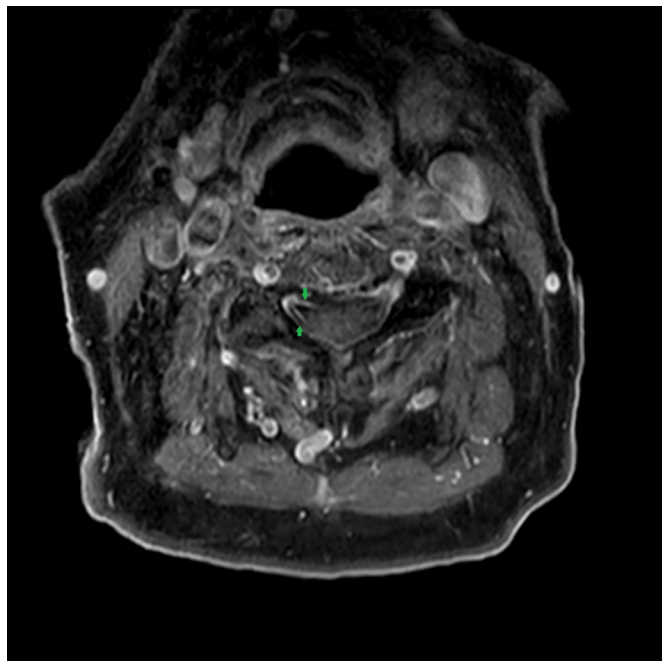


Figure 4 MRI image of gadolinium contrast enhancement on the right dorsal and ventral C5 nerve rootlets (green arrow).

OUTCOME AND FOLLOW-UP

Six weeks later, a follow-up MRI C-spine with gadolinium contrast showed persisting contrast enhancement on C5/C6 level. The background spondylotic changes and foraminal narrowing were unaltered from previous study, most pronounced at bilateral C4/C5 level and right C5/C6 level. His MRI brain was normal with no gadolinium contrast enhancement.

He was again recalled 10 days later for another dedicated cervical spine MRI with gadolinium contrast study, and there is confirmed pathological enhancement on the right-sided dorsal

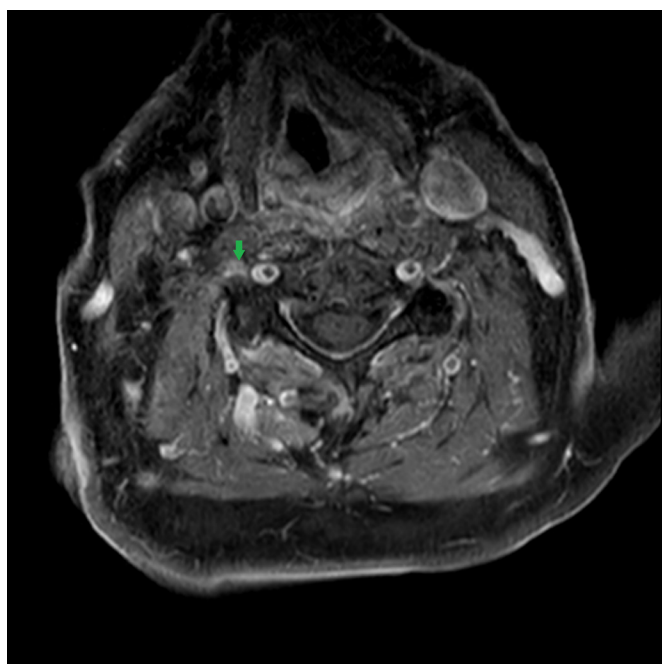


Figure 5 MRI image of gadolinium contrast enhancement on right C5 nerve root (green arrow).

and ventral C5 nerve rootlets and right C5 nerve root (figures 4 and 5). However, the right C6 and C7 nerve root enhancement has resolved compared with the initial scan. As such, this confirmed radiological improvement.

He described persisting weakness on his shoulder abduction, but improved elbow strength. His rash has also resolved. His main concern was the persistent postherpetic neuralgia and allodynia, which is currently managed on lignocaine patches and pregabalin 75 mg two times a day. He attends outpatient physiotherapy sessions and continues his home exercise programme. On examination, his right shoulder abduction was 3/5 and right elbow flexion was 4/5, while the rest of his upper limb strength were 5/5. Overall, the right arm weakness and pain are showing a trajectory of improvement since his discharge.

Six months later, he has persistent weakness in shoulder abduction but to a lesser degree. This is confirmed by another repeat MRI scan, which showed no evidence of intradural or cord enhancement, but there is persistent mild oedema and thickening of the right C5 and C6 nerve distal to the foramina. It was concluded that he had an unusual complication from zoster radiculopathy, simulating a disc compression-related radiculopathy. He has been adequately treated for zoster radiculopathy, and his residual weakness and sensory symptoms are likely a sequela from the initial inflammation, further exacerbated by his C5/C6 cervical radiculopathy.

He also had his second and third dose booster vaccination without a relapse of his zoster radiculopathy or any other complication.

DISCUSSION

This case highlights a diagnostic challenge in identifying inflammatory neuritis, such as zoster infection, apart from cervical radiculopathy. His initial non-contrast cervical spine MRI scan suggested C5–C6 cervical radiculopathy, which would be consistent with his examination findings. It was only after his rash manifested in the same dermatome that prompted a repeat MRI scan with gadolinium contrast, and his diagnosis was reassessed to be zoster radiculopathy. He was commenced on oral valaciclovir and regained his right upper limb strength gradually. In addition, the administration of his first ChAdOx1 nCoV-19/AZD1222 vaccine 3 days prior to symptom onset raises the possibility of vaccine-related immune-mediated zoster reactivation, which warrants further research.

There are many neurological complications of herpes zoster infection, namely, postherpetic neuralgia, herpes zoster ophthalmicus, Ramsay Hunt Syndrome, meningitis, encephalitis, myelitis and peripheral motor neuropathy. Herpes zoster (otherwise known as shingles) results from reactivation of latent zoster infection in the sensory ganglia and its incidence increases with age and immunosuppression. On reactivation, the virus spreads resulting in neuritis, with or without a vesicular rash in the corresponding dermatome.² Zoster radiculopathy is thought to be an extension of the neuritis from the sensory ganglion into the peripheral motor neurons.³

The diagnosis can often be established on clinical grounds alone with a positive skin lesion swab for VZV PCR.² MRI with gadolinium contrast would be expected to show abnormal signal on T2-weighted images and/or contrast enhancement of the affected nerves.² Cerebrospinal fluid PCR is not a useful test because of lower sensitivity and is not indicated unless there is suggestion of meningitis or encephalitis.^{2,4}

There have been many case reports where zoster radiculopathy has been misdiagnosed as spinal radiculopathy, especially

when it involves the same segment.² Often, motor weakness may precede the eruption of a typical rash. This could result in inappropriate aggressive surgical intervention and delayed treatment with antiviral therapy.

Peripheral neuropathy is only described in about 1%–5% of patients with herpes zoster infection.³ However, postmortem analysis found EMG abnormalities in 53% of patients who developed shingles, including those who did not experience any weakness.^{3,5} In addition, the motor nerve involvement may not correspond to the same dermatome as the rash. There are reports of inflammatory findings in motor nerves contralateral to the side of the rash.⁵ A possible explanation is that the inflammatory response can extend widely to involve nerve roots in multiple adjacent segments bilaterally.^{3,5} Therefore, zoster radiculopathy could reflect a state of systemic inflammation rather than being confined to the same affected dermatome.

Our report discusses a patient with zoster radiculopathy and cervical radiculopathy in the same segment. Although they may be separate pathologies, an association may exist and warrant further clinical discussion and evaluation.⁶ Kang *et al* described a patient with herpes zoster and cervical spinal stenosis at the same spinal level.⁷ Miller *et al* also described a patient with zoster radiculopathy with concurrent C5–C6 cervical spine radiculopathy occurring a week following his influenza and pneumococcal vaccination.⁶

There remains a possibility that our patient's zoster radiculopathy was associated with his recent ChAdOx1 nCoV-19/AZD1222 vaccination, given the symptom onset after 3 days of receiving his first dose. There are multiple reports of shingles reactivation associated with mRNA (BNT162b2 (Pfizer-BioNtech)) and inactivated (Covaxin (Bharat Biotech/Indian Council of Medical Research)) COVID-19 vaccination.^{8–11} Additionally, there are also reports of shingles reactivation following other vaccines such as inactivated influenza, hepatitis A and rabies.¹¹ To our knowledge, this is the first case of shingles associated with an adenovirus vector COVID-19 vaccine. It is thought that immune dysregulation caused by vaccine administration could play a role in the virus reactivation.¹¹ There are also reports of zoster radiculopathy being triggered following spinal decompression and fusion surgeries, although mechanism remains unknown.^{4,6,12}

The likely cause of his recurrent flares of shingles is due to advanced age-related immunosenescence, exacerbated by the

administration of SARS-CoV-2 vaccine. Nevertheless, underlying immunosuppression should also be excluded. This includes HIV infection, diabetes, malignancy and use of immunosuppressive therapy.¹³

Based on the European consensus-based (S2k) guideline on the management of herpes zoster in 2016 and the Recommendations for the Management of Herpes Zoster: Clinical Infectious Diseases in 2007, antiviral treatment with acyclovir, valaciclovir or famciclovir is recommended for herpes zoster with neurological dissemination, such as zoster radiculopathy.^{14,15} In uncomplicated zoster infection without CNS or ocular involvement, the duration of antiviral therapy should be 7 days.¹³ In our case, his treatment was extended to 21 days due to peripheral nervous system involvement. Intravenous acyclovir is only recommended for CNS involvement, such as meningitis, encephalitis or myelitis.¹⁴ Addition of systemic glucocorticoid therapy can be considered if there is facial paralysis, cranial polyneuritis, peripheral nerve involvement or CNS involvement, although the benefits have not been proven.¹⁴

Contributors AD is the primary author of the case report. MT contributed with the discussion section of the case report and editing the draft. TC is the neurologist involved with the investigation, diagnosis and management of the patient. He contributed to the case presentation and investigation section. CL is the geriatrician consultant who manages the patient overall. He also is the overall supervisor of the case report.

Funding The authors have not declared a specific grant for this research from any funding agency in the public, commercial or not-for-profit sectors.

Competing interests None declared.

Patient consent for publication Consent obtained directly from patient(s)

Provenance and peer review Not commissioned; externally peer reviewed.

Case reports provide a valuable learning resource for the scientific community and can indicate areas of interest for future research. They should not be used in isolation to guide treatment choices or public health policy.

ORCID iDs

Andrew Dermawan <http://orcid.org/0000-0002-0172-7872>

Matthew Jun Min Ting <http://orcid.org/0000-0003-2505-9423>

Thomas Chemmanam <http://orcid.org/0000-0002-3327-6076>

REFERENCES

- Hsu P. Acute lumbosacral radiculopathy: Pathophysiology, clinical features, and diagnosis - UpToDate. Available: https://www.uptodate.com.qlibresources.health.wa.gov.au/contents/acute-lumbosacral-radiculopathy-pathophysiology-clinical-features-and-diagnosis?search=zoster+radiculopathy&source=search_result&selectedTitle=3~150&usage_type=default&display_rank=3 [Accessed 20 Jul 2021].
- Bhushan S, Dominguez L, Shirazi E, *et al*. Acute herpes zoster radiculopathy of the lower extremity with dermatomal rash and lumbar nerve enhancement on MRI. *Mayo Clin Proc Innov Qual Outcomes* 2020;4:608–10.
- Haanpää M, Häkkinen V, Nurmikko T. Motor involvement in acute herpes zoster. *Muscle Nerve* 1997;20:1433–8.
- Koda M, Mannoji C, Oikawa M, *et al*. Herpes zoster sciatica mimicking lumbar canal stenosis: a case report. *BMC Res Notes* 2015;8:320.
- Watson CPN, Deck JH, Morshead C, *et al*. Post-Herpetic neuralgia: further post-mortem studies of cases with and without pain. *Pain* 1991;44:105–17.
- Miller SC, Cox JM, Olding KJ. Cervical radiculopathy associated with shingles herpes zoster infection. *J Chiropr Med* 2019;18:225–8.
- Kang S-H, Song H-K, Jang Y. Zoster-associated segmental paresis in a patient with cervical spinal stenosis. *J Int Med Res* 2013;41:907–13.
- Eid E, Abdullah L, Kurban M, *et al*. Herpes zoster emergence following mRNA COVID-19 vaccine. *J Med Virol* 2021;93:5231–2.
- Arora P, Sardana K, Mathachan SR. Herpes zoster after inactivated COVID-19 vaccine: a cutaneous adverse effect of the vaccine. *J Cosmet Dermatol* 2021.
- Aksu SB, Öztürk GZ. A rare case of shingles after COVID-19 vaccine: is it a possible adverse effect? *Clin Exp Vaccine Res* 2021;10:198.
- Bostan E, Yalici-Armagan B. Herpes zoster following inactivated COVID-19 vaccine: a coexistence or coincidence? *J Cosmet Dermatol* 2021;20:1566–7.

Learning points

- ▶ Herpes zoster and spinal spondylosis are conditions with increased incidence in older adults. Zoster radiculopathy could mimic a spinal radiculopathy, especially in this population.
- ▶ Given the high incidence of radiological spinal degenerative changes in older adults, it is important to have diagnostic flexibility, particularly when the clinical picture does not fully comport with imaging findings.
- ▶ Limb weakness could precede painful neuropathy or vesicular rash, which makes diagnosis of zoster radiculopathy challenging.
- ▶ MRI spine with gadolinium contrast would be expected to demonstrate contrast enhancement in keeping with an inflammatory neuritis.
- ▶ There may be a link between various COVID-19 vaccines and shingles reactivation, which deserves further study.

- 12 Drazin D, Hanna G, Shweikeh F, *et al.* Varicella-Zoster-Mediated radiculitis reactivation following cervical spine surgery: case report and review of the literature. *Case Rep Infect Dis* 2013;2013:1–5.
- 13 Albrecht M. Treatment of herpes zoster in the immunocompetent host. UpToDate, 2020. Available: https://www.uptodate-com.qelibresources.health.wa.gov.au/contents/treatment-of-herpes-zoster-in-the-immunocompetent-host?search=zoster+treatment&source=search_result&selectedTitle=1~150&usage_type=default&display_rank=1 [Accessed 17 Mar 2022].
- 14 RH D, RW J JB, *et al.* Recommendations for the management of herpes zoster. *Clin Infect Dis* 2007;44.
- 15 Werner RN, Nikkels AF, Marinović B, *et al.* European consensus-based (S2k) Guideline on the Management of Herpes Zoster - guided by the European Dermatology Forum (EDF) in cooperation with the European Academy of Dermatology and Venereology (EADV), Part 2: Treatment. *J Eur Acad Dermatol Venereol* 2017;31:20–9.

Copyright 2022 BMJ Publishing Group. All rights reserved. For permission to reuse any of this content visit <https://www.bmj.com/company/products-services/rights-and-licensing/permissions/>
BMJ Case Report Fellows may re-use this article for personal use and teaching without any further permission.

Become a Fellow of BMJ Case Reports today and you can:

- ▶ Submit as many cases as you like
- ▶ Enjoy fast sympathetic peer review and rapid publication of accepted articles
- ▶ Access all the published articles
- ▶ Re-use any of the published material for personal use and teaching without further permission

Customer Service

If you have any further queries about your subscription, please contact our customer services team on +44 (0) 207111 1105 or via email at support@bmj.com.

Visit casereports.bmj.com for more articles like this and to become a Fellow