

# Systemic Inflammation Is Associated With Neurologic Involvement in Pediatric Inflammatory Multisystem Syndrome Associated With SARS-CoV-2

Mario Sa, MD, Luwaiza Mirza, BSc, Michael Carter, MD, Lalani Carlton Jones, MD, Vasantha Gowda, MD, Jennifer Handforth, MD, Tammy Hedderly, MD, Julia Kenny, PhD, Karine Lascelles, MD, Jean-Pierre Lin, PhD, Daniel Lumsden, PhD, Marilyn McDougall, MD, Owen Miller, MD, Thomas Rossor, MD, Vinay Shivamurthy, MD, Ata Siddiqui, MD, Rahul Singh, MD, Shan Tang, PhD, Marie White, MD, Susan Byrne, PhD, and Ming Lim, PhD, on behalf of the Evelina PIMS-TS Study Group\*

## Correspondence

Dr. Lim  
ming.lim@gstt.nhs.uk

*Neurol Neuroimmunol Neuroinflamm* 2021;8:e999. doi:10.1212/NXI.0000000000000999

## Abstract

### Objective

Pediatric inflammatory multisystem syndrome temporally associated with SARS-CoV-2 (PIMS-TS) is a severe immune-mediated disorder. We aim to report the neurologic features of children with PIMS-TS.

### Methods

We identified children presenting to a large children's hospital with PIMS-TS from March to June 2020 and performed a retrospective medical note review, identifying clinical and investigative features alongside short-term outcome of children presenting with neurologic symptoms.

### Results

Seventy-five patients with PIMS-TS were identified, 9 (12%) had neurologic involvement: altered consciousness (3), behavioral changes (3), focal neurology deficits (2), persistent headaches (2), hallucinations (2), excessive sleepiness (1), and new-onset focal seizures (1). Four patients had cranial images abnormalities. At 3-month follow-up, 1 child had died, 1 had hemiparesis, 3 had behavioral changes, and 4 completely recovered. Systemic inflammatory and prothrombotic markers were higher in patients with neurologic involvement (mean highest CRP 267 vs 202 mg/L,  $p = 0.05$ ; procalcitonin 30.65 vs 13.11  $\mu\text{g/L}$ ,  $p = 0.04$ ; fibrinogen 7.04 vs 6.17 g/L,  $p = 0.07$ ; D-dimers 19.68 vs 7.35 mg/L,  $p = 0.005$ ). Among patients with neurologic involvement, these markers were higher in those without full recovery at 3 months (ferritin 2284 vs 283  $\mu\text{g/L}$ ,  $p = 0.05$ ; D-dimers 30.34 vs 6.37 mg/L,  $p = 0.04$ ). Patients with and without neurologic involvement shared similar risk factors for PIMS-TS (Black, Asian and Minority Ethnic ethnicity 78% vs 70%, obese/overweight 56% vs 42%).

### Conclusions

Broad neurologic features were found in 12% patients with PIMS-TS. By 3-month follow-up, half of these surviving children had recovered fully without neurologic impairment. Significantly higher systemic inflammatory markers were identified in children with neurologic involvement and in those who had not recovered fully.

From the Children's Neurosciences (M.S., V.G., T.H., K.L., J.-P.L., D.L., T.R., R.S., S.T., S.B., M.L.), Paediatric Intensive Care (M.C., J.H., J.K., M.M.), Department of Paediatric Neuroradiology (L.C.J., A.S.), Department of Congenital Heart Disease (O.M.), Department of Pediatric Rheumatology (V.S.), and Department of General Paediatrics (M.W.), Evelina London Children's Hospital, Guy's and St Thomas' NHS Foundation Trust; Department of Women and Children's Health (L.M., M.C., J.H., J.K., O.M., M.W., M.L.), School of Life Course Sciences, King's College London; and Department of Neuroradiology (L.C.J., A.S.), King's College Hospital, London, United Kingdom.

\*Coinvestigators of the Evelina PIMS-TS Study Group are listed at [links.lww.com/NXI/A473](https://links.lww.com/NXI/A473).

Go to [Neurology.org/NN](https://Neurology.org/NN) for full disclosures. Funding information is provided at the end of the article.

The Article Processing Charge was funded by the authors.

This is an open access article distributed under the terms of the Creative Commons Attribution-NonCommercial-NoDerivatives License 4.0 (CC BY-NC-ND), which permits downloading and sharing the work provided it is properly cited. The work cannot be changed in any way or used commercially without permission from the journal.

## Glossary

ICU = intensive care unit; Ig = immunoglobulin; mRS = modified Rankin Scale; PIMS-TS = pediatric inflammatory multisystem syndrome temporally associated with SARS-CoV-2.

SARS-CoV-2 is a novel and highly pathogenic respiratory coronavirus causing the global COVID-19 pandemic. Neurologic syndromes have been reported within the acute phase of disease, and these may arise from presumed direct viral invasion or result from a para or postinfectious inflammation.<sup>1</sup> Although children present with a milder course of disease and case fatality rates are lower, a severe multisystem hyperinflammatory response has been reported in children during the pandemic, clinically defined as pediatric inflammatory multisystem syndrome temporally associated with SARS-CoV-2 (PIMS-TS)<sup>2</sup> or multisystem inflammatory syndrome in children.<sup>3</sup> Children present with fever, abdominal pain, diarrhea, shock, myocardial injury, and development of coronary artery aneurysms.<sup>4</sup> Central and peripheral neurologic involvement was also noted in PIMS-TS.<sup>5</sup> Here, we characterize the spectrum of neurologic features among a cohort of 75 children with PIMS-TS and aim to identify differences to those presenting without neurologic symptoms.

## Methods

A retrospective cross-sectional review of patients with PIMS-TS admitted to Evelina London Children's Hospital was performed to identify the clinical and investigative features alongside short-term outcome of children presenting with neurologic symptoms. Patients younger than

18 years and admitted between March and June 2020 who met the following criteria were included in our cohort:

1. Prospective diagnosis of PIMS-TS according to the Royal College of Paediatrics and Child Health case definition<sup>2</sup> (persistent fever, inflammation, and evidence of single or multiorgan dysfunction and exclusion of other microbial causes) following review by a multidisciplinary team comprising of at least 1 each of infectious diseases, intensive care, cardiology, rheumatology, and general pediatric specialists.
2. New onset of at least one of the following: features of encephalopathy<sup>6</sup> (altered consciousness that persisted for longer than 24 hours, including lethargy, irritability, or a change in personality and behavior), seizures, movement disorder, psychiatric, and/or any neurologic deficit.

All inflammatory and prothrombotic investigations (table e-1, [links.lww.com/NXI/A474](https://links.lww.com/NXI/A474)) were taken before therapy (including aspirin); the highest value was used for analysis. The modified Rankin Scale (mRS)<sup>7</sup> at last clinical review was used to document clinical outcome. Demographic features and inflammatory markers were compared with the cohort of patients with PIMS-TS admitted during the same period with no neurologic symptoms. Statistical analysis was performed using SPSS 24.0 IBM (Chicago,

**Table 1** Demographic and Clinical Information of the 9 Patients Presenting With Neurologic Features

Patients	Neurologic features (syndrome)	Neurologic investigations	Systemic features	Inflammatory markers	SARS-CoV-2	Treatment and outcome
<b>1, female, 2 y, Afro-Caribbean, obesity</b>	Altered consciousness (encephalopathy secondary to systemic inflammation)	Brain CT and MRI/MRA: normal EEG: fluctuating encephalopathic CSF: normal (pleocytosis, oligoclonal band, and NSABs)	Fever Lymphadenopathy, periorbital and lip edema Abdominal pain Mild left ventricular impairment and coronary aneurysm	Ferritin 275 µg/L; CRP: 189 mg/L; procalcitonin: 4.72 µg/L; fibrinogen: 8.6 g/L; D-dimers: 12.86 mg/L	PCR NP and serology positive, PCR CSF negative	IVIG; IVMP (3 d); tocilizumab (1 dose) Complete recovery at 3 mo (mRS 0)
<b>2, male, 4 y, Caucasian</b>	Altered consciousness; behavioral changes (encephalopathy secondary to systemic inflammation)	Brain MRI: normal EEG: normal CSF: mixed oligoclonal bands (serum and CSF)	Fever Intense abdominal pain, diarrhoea, and vomits Bright coronaries and dilated left anterior descending coronary artery	Ferritin: 172 µg/L; CRP: 283 mg/L; procalcitonin: 4.98 µg/L; fibrinogen: 6.8 g/L; D-dimers: 10.6 mg/L	PCR NP and serology negative	IVIG; IVMP (3 d) Behavioral changes at 3 mo follow-up (mRS 3)
<b>3, female, 6 y, Asian</b>	Severe behavioral changes (encephalopathy secondary to systemic inflammation)	Not performed	Fever Rash, face and feet edema Abdominal pain and vomits Coronary aneurysm	Ferritin: 74 µg/L; CRP: 80 mg/L; fibrinogen: 4.1 g/L; D-dimers: 1.2 mg/L	PCR NP and serology positive	Oral prednisolone Complete recovery at 4 mo (mRS 0)

Continued

**Table 1** Demographic and Clinical Information of the 9 Patients Presenting With Neurologic Features (*continued*)

Patients	Neurologic features (syndrome)	Neurologic investigations	Systemic features	Inflammatory markers	SARS-CoV-2	Treatment and outcome
<b>4, female, 8 y, Afro-Caribbean, obesity</b>	Altered consciousness; visual hallucinations (encephalopathy secondary to systemic inflammation)	Brain MRI: normal CSF: ND	Fever Sore throat Vomits and diarrhoea Impaired ventricular function and shock	Ferritin: 642 µg/L; CRP: 470 mg/L; procalcitonin: 56.15 µg/L; fibrinogen: 6.8 g/L; D-dimers: 10.36 mg/L	PCR NP negative, serology positive	IVIG; IVMP (3 d) Complete recovery at 4 mo (mRS 0)
<b>5, male, 12 y, Caucasian, overweight</b>	Persistent severe headaches; sleepiness (encephalopathy secondary to systemic inflammation)	Brain CT and MRI/MRA: normal CSF: ND	Fever Rash, pedal edema, and conjunctivitis Abdominal pain and vomits Bright coronaries and hypotension	Ferritin: 136 µg/L; CRP: 94 mg/L; procalcitonin: 1.19 µg/L; fibrinogen: 1.4 g/L; D-dimers: 1.05 mg/L	PCR NP and serology negative	IVIG; IVMP (3 d). Complete recovery at 3 mo (mRS 0)
<b>6, female, 12 y, Afro-Caribbean, obesity</b>	Behavioral changes; cognitive deterioration (toxo/metabolic encephalopathy)	Brain MRI: subtle cortical changes EEG: reduced left posterior background rhythms CSF: ND	Fever Rash, cracked lips, conjunctivitis, and lymphadenopathy ARDS Abdominal pain, diarrhoea, and vomits Coronary aneurysm, impaired ventricular function, and shock	Ferritin: 4,815 µg/L; CRP: 343 mg/L; procalcitonin: 77.6 µg/L; fibrinogen: 6.8 g/L; D-dimers: 69.76 mg/L	PCR NP negative, serology positive	IVIG (2 doses); IVMP (5 d); infliximab (1 dose) Mild behavioral changes/low mood at 4 mo follow-up (mRS 1)
<b>7, male, 14 y, Afro-Caribbean, obesity, α-thalassemia trait</b>	Headaches; focal neurology with asymmetric pupils (stroke)	Brain CT: acute infarction (figure 1E) CSF: ND	Fever ARDS Diarrhea Impaired ventricular function and shock	Ferritin: 4,220 µg/L; CRP: 556 mg/L; procalcitonin: >100 µg/L; fibrinogen: 10.8 g/L; D-dimers: 13.49 mg/L	PCR NP and serology positive	No immune treatment Deceased after 8 d of admission
<b>8, female, 15 y, Afro-Caribbean, overweight, HbC trait</b>	Behavioral changes; visual and auditory hallucinations; new onset of seizures (toxo/metabolic encephalopathy)	Brain MRI: hippocampal and splenium of corpus callosum changes (figure 1, A–D) EEG: focal spike-wave discharges CSF: normal (pleocytosis, oligoclonal band, and NSABs)	Fever ARDS Impaired ventricular function and shock	Ferritin: 640 µg/L; CRP: 99 mg/L; procalcitonin: 0.22 µg/L; fibrinogen: 6.8 g/L; D-dimers: 28.79 mg/L	PCR NP, PCR CSF, and serology negative	IVIG; IVMP (3 d). Memory difficulties at 3-mo follow-up. Seizures resolved (mRS 2)
<b>9, male, 10 y, Afro-Caribbean, sickle cell</b>	Encephalopathy; left sided facial weakness. Hypertension and bradycardia (raised ICP) (stroke)	Brain CT/MRI: right frontal intraparenchymal haemorrhage (figure 1F) and infarction CSF: ND	Fever Dorsal, chest, and thighs pain (sickle cell crisis). Abdominal pain and vomits	Ferritin: 1,572 µg/L; CRP: 296 mg/L; procalcitonin: 0.34 µg/L; fibrinogen: 7.3 g/L; D-dimers: 29.08 mg/L	PCR NP negative, serology positive	IVIG; IVMP (3 d); tocilizumab (1 dose) Left hemiparesis (mRS 4)

Abbreviations: ARDS = acute respiratory distress syndrome; CRP = C-reactive protein; ICP = intracranial pressure; IVIG = IV immunoglobulin; IVMP = IV methylprednisolone; MRA = magnetic resonance angiogram; mRS = modified Rankin Scale; ND = not done; NSAB = neuronal surface antibody; NP = nasopharyngeal.

IL). A *p* value less than 0.05 was considered statistically significant, and care was given to limiting multiple comparison.

### Standard Protocol Approvals, Registrations, and Patient Consents

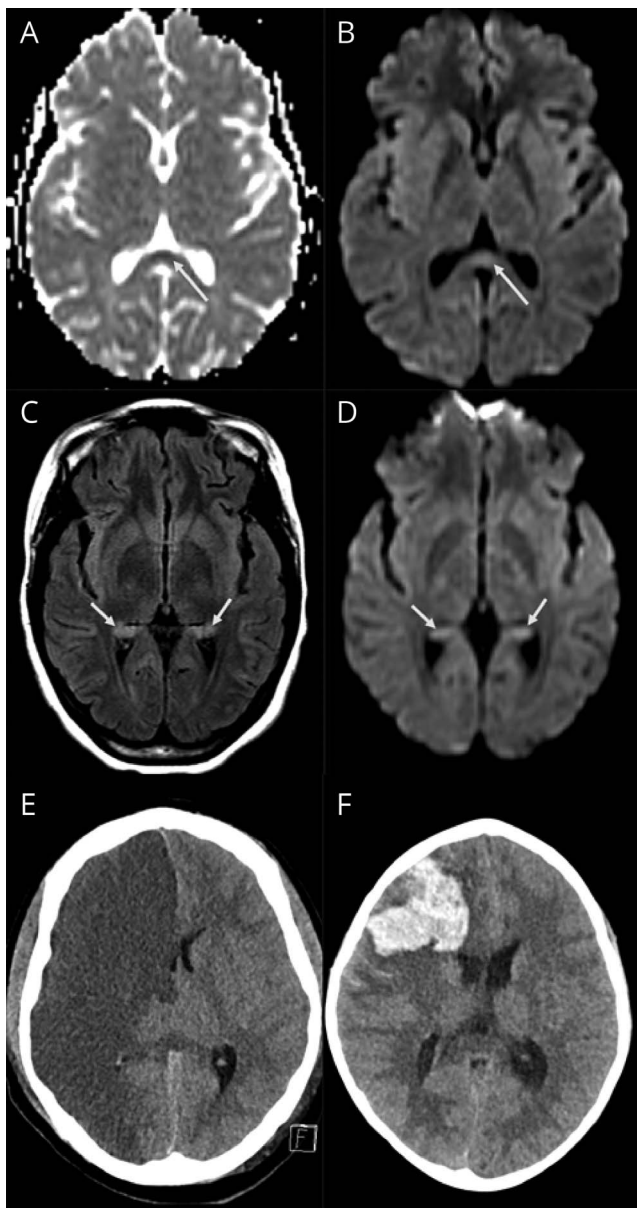
As only data required for standard medical care were collected, a full ethics review under the terms of the

Governance Arrangements of Research Ethics Committees in the United Kingdom was deemed not necessary by the institutional PIMS-TS Study Group.

### Data Availability

Deidentified participant data not included in the article are available on request by any qualified investigator to the corresponding author.

**Figure 1** Brain MRI/CT Images



(A–F) MRI findings. The top row (A and B) showing ADC and DWI images of patient 8 shows mild diffusion restriction in the splenium of the corpus callosum (long arrows). The middle row (C and D) in the same patient also shows mild bilateral hippocampal changes on FLAIR with diffusion restriction on DWI. The bottom row shows CT images in 2 different patients; image E from patient 7 shows an acute right anterior circulation infarct, and image F from patient 9 shows an acute right frontal intraparenchymal hemorrhage. DWI = diffusion-weighted imaging; FLAIR = fluid-attenuated inversion recovery.

## Results

### Clinical and Investigative Features

A total of 75 children (33% female; median 10 years, interquartile range 7.9 years) were diagnosed with PIMS-TS. At the time of testing availability (June–July 2020), 51 (68%) had detectable immunoglobulin (Ig) G to SARS-CoV-2. Of the 75 children, 9 (12%) had neurologic features (table 1; table e-2, [links.lww.com/NXI/A475](https://links.lww.com/NXI/A475)), altered consciousness

(3/9; 33%), acute behavioral changes (3/9; 33%), focal neurologic deficits (2/9; 22%), severe persistent headaches (2/9; 22%), visual/auditory hallucinations (2/9; 22%), excessive sleepiness (1/9; 11%), and new-onset of focal seizures (1/9; 11%). All patients had fever at symptom onset and the range of systemic features include had gastrointestinal symptom (8/9; 89%), cardiovascular instability (5/9; 56%), and respiratory symptoms (4/9; 44%). Four patients (44%) had left ventricular dysfunction and 5 (56%) coronary artery abnormalities.

Four patients had abnormal imaging: focal diffusion restriction involving the splenium of the corpus callosum and mild signal changes in hippocampal regions (patient 8, figure 1, A–D); acute infarction (patient 7, figure 1E); intraparenchymal hemorrhage and infarction (patient 9, figure 1F); and subtle cortical changes as a possible sequelae of hypoxic event (patient 6). EEG showed abnormalities in the 3 of the 4 patients tested. These were reduced amplitude of background rhythms in 2 (patients 1 and 6; features of encephalopathy) and sharpened slow waves in 1 (patient 8; seizure liability). Three children had CSF analysis, and this was normal in 2 and neither had SARS-CoV-2 identified in CSF. One child had matched oligoclonal bands in serum and CSF (patient 2). Mean highest measured inflammatory markers were raised (table 2). Evidence of active infection (positive nasopharyngeal swab PCR) was found in 3 (33%) patients, and a further 3 (33%) had evidence of recent infection (negative PCR and positive IgG serology).

### Early Neurologic and Behavioral Outcome

One patient died after extensive brain infarction (patient 7, mRS 6), and another was transferred to a neurosurgical center for management of intraparenchymal hemorrhage (patient 9, mRS 4). The other 7 patients were discharged home after a median period of 11 (range 6–25) days of admission. Four (57%) patients recovered completely (mRS 0) at 3-month follow-up review. In the other 3 children, the following outcomes were seen: reported persistent significant behavioral and social interaction difficulties (mRS 3), mild behavioral changes with low mood (mRS 1), and memory difficulties (mRS 2).

### Comparison With Children Who Did Not Exhibit Neurologic Symptoms

Comparison was made between those with PIMS-TS and associated neurologic involvement ( $n = 9$ ) and those without neurologic involvement ( $n = 66$ ) (table 2). Risk factors for PIMS-TS were similar: Black, Asian and Minority Ethnic ethnicity 78% vs 70%, obesity (body mass index >95th centile)/overweight (86th–95th centile) 56% vs 42%. Both groups had comparable number and duration of intensive care unit (ICU) admission and cardiac involvement. Notably, systemic inflammatory markers were higher in patients with neurologic involvement (figure 2). Considering patients with neurologic involvement ( $n = 9$ ), peak inflammatory and

**Table 2** Comparison Between Those With PIMS-TS and Associated Involvement and Those Without Neurologic Involvement

	PIMS-TS and neurology symptoms (n = 9)		No neurology symptoms (n = 66)	p Value
Female, n (%)	5 (56)		20 (30)	0.15
Median age at symptom onset, y	10 (IQR 8.4)		10 (IQR 8.1)	0.43
Ethnicity: BAME, n (%)	7 (78)		43 (65)	0.45
Obese/overweight, n (%) <sup>a</sup>	5 (56)		28 (42)	0.49
GI symptoms, n (%)	8 (89)		53 (80)	0.53
Respiratory symptoms, n (%)	4 (44)		31 (47)	0.89
Cardiac involvement, n (%)	7 (78)		46 (70)	0.62
Evidence of SARS-CoV-2 infection, n (%) <sup>b</sup>	6 (67)		45 (68)	0.93
Median admission duration, d	11		8	0.08
ICU admission, n (%)	6 (67)		42 (64)	0.86
Median ICU admission, d	6.5		3	0.69
<b>Immunomodulatory treatment, n (%)</b>				
First line (IVIg/IVMP)	7 (78)		63 (95)	0.11
Second line (anakinra/infliximab/tocilizumab)	2 (22)		25 (38)	0.48
<b>Inflammatory markers<sup>c</sup></b>				
CRP, mg/L	267 (median: 283; IQR: 244)		202 mg/L (median: 188; IQR: 141)	0.05
Ferritin, µg/L	1,395 (median: 640; IQR: 1,400)		980 (median: 549; IQR: 871)	0.21
Procalcitonin, µg/L	30.65 (median: 4.72; IQR: 61.51)		13.11 (median: 3.10; IQR: 8.03)	0.04
Fibrinogen, g/L	7.04 (median: 6.8; IQR: 0.5)		6.17 (median: 5.9; IQR: 1.7)	0.07
D-dimers, mg/L	19.68 (median: 12.86; IQR: 18.43)		7.35 (median: 3.36; IQR: 6.87)	0.005
	Residual symptoms (n = 5)		Complete recovery (n = 4)	
CRP, mg/L	315 (median: 296; IQR: 60)		207 (median: 142; IQR: 170)	0.19
Ferritin, µg/L	2,284 (median: 1,572; IQR: 3,580)		283 (median: 206; IQR: 245)	0.05
Procalcitonin, µg/L	36.63 (median: 4.98; IQR: 77.26)		20.69 (median: 4.72; IQR: 27.48)	0.32
Fibrinogen, g/L	7.70 (median: 6.8; IQR: 0.5)		6.23 (median: 6.1; IQR: 2.18)	0.13
D-dimers, mg/L	30.34 (median: 28.79; IQR: 15.59)		6.37 (median: 5.78; IQR: 9.82)	0.04

Abbreviations: BAME = Black, Asian and Minority Ethnic; CRP = C-reactive protein; ICU = intensive care unit; IQR = interquartile range; IVIG = IV immunoglobulin; IVMP = IV methylprednisolone.

Peak inflammatory marker comparison between those with residual neurologic symptoms and those with complete neurologic recovery at 3-month follow-up.

<sup>a</sup> Obesity defined as body mass index >95th centile and overweight as 86th–95th centile for age and sex.

<sup>b</sup> Positive nasopharyngeal swab PCR or positive serology.

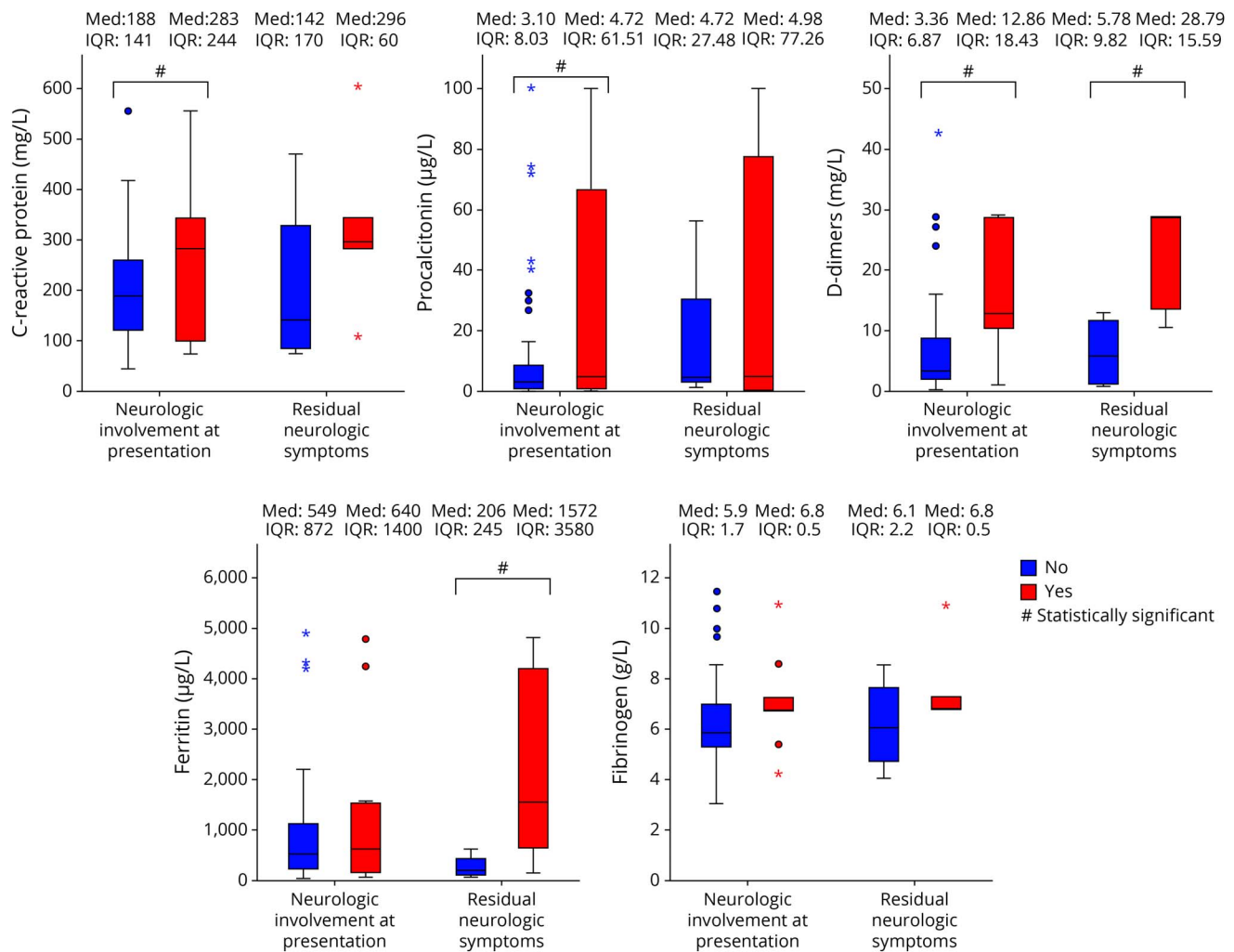
<sup>c</sup> Mean of highest measured inflammatory marker.

prothrombotic markers during acute disease were higher in children with sequelae at 3-month follow-up (n = 5) in comparison with children with complete neurologic recovery (n = 4) (table 2, figure 2).

## Discussion

In this study, we describe the spectrum of neurologic manifestations in 9 children with PIMS-TS. The frequency of

**Figure 2** Box Plot Graphs Comparing Highest Pretreatment Mean Inflammatory Markers



Box plot graphs comparing highest mean inflammatory markers. Left side of each plot: comparison of PIMS-TS patients (n = 75) without (blue, n = 66) and with (red, n = 9) neurologic involvement during acute illness. Right side of each plot: comparison of PIMS-TS patients with neurologic involvement at presentation (n = 9) without (blue, n = 4) and with (red, n = 5) neurologic residual symptoms at 3-month follow-up. Asterisks denote outliers >3 times the interquartile range (IQR). PIMS-TS = pediatric inflammatory multisystem syndrome temporally associated with SARS-CoV-2.

neurologic symptoms was relatively low (12%), and this was comparable to a previous smaller cohort.<sup>5</sup> Two children developed extensive stroke. Stroke in adult patients has been extensively reported and is thought to be due to inflammation driven hypercoagulability with thrombotic microangiopathy playing a major role in COVID-19 syndromes.<sup>8</sup> A characteristic radiologic feature noted in our cohort is the splenic lesion. Among other neuroradiologic features, the same splenic findings had been previously reported and also with a favorable clinical outcome, during the acute SARS-CoV-2 infection<sup>5</sup> and delayed hyperinflammatory syndrome.<sup>9</sup>

Of interest, SARS-CoV-2 IgG was undetected in 24 (32%) of children. One plausible explanation for this is that antibody concentrations may have decayed to below the threshold of detection by the time testing was clinically available in our patients.<sup>10</sup> Alternatively, antibody specificity and concentrations are known to differ in children with PIMS-TS in

comparison to adults with COVID-19,<sup>11</sup> explaining an incomplete seroprevalence in this PIMS-TS cohort. Seronegative patients with PIMS-TS were phenotypically similar to seropositive patients with PIMS-TS, presented in the period of the first surge of cases in the UK COVID-19 pandemic, and were negative by PCR and relevant serology to extensive virologic testing.

The key finding of our study is that children with neurologic symptoms as part of their PIMS-TS presentation have significantly higher systemic inflammatory markers than children without neurologic features. These findings support the hypothesis that PIMS-TS-associated neurologic involvement comprises a systemic para or postinfectious immune-mediated phenomenon. A study from our institution has demonstrated that there is a distinct immunophenotype with high levels of interleukin activation in children with PIMS-TS.<sup>12</sup> The key question of how systemic inflammation might

lead to CNS symptoms often implicates blood-brain barrier integrity or direct transfer via the circumventricular organs and regions devoid of a barrier.<sup>13</sup>

Of the surviving 8 children with PIMS-TS and neurologic symptoms, only half have returned to their baseline at 3-month follow-up. Similar difficulties are described short-term complications of ICU admissions in children.<sup>14</sup> However, the important observation in our study is that those with residual reported symptoms had higher inflammatory markers at presentation. Systemic hyperinflammation may acutely influence brain structural connections and could lead to long-term neurocognitive sequelae, as seen in some patients following autoimmune encephalitis.<sup>15</sup>

This single-center retrospective observational study spans a short period where the case definition and management of a newly evolving disease entity was being established and has inherent limitations. The full spectrum of the neurologic symptoms would have been underestimated in children in critical care and may result in inaccurate cross-sectional comparison. In addition, treatment effects cannot be systematically evaluated, as within this cohort, virtually all have been given first-line immune therapy (70/75, 93%), and that therapy was variably escalated to second line in 28/75 (37%).

Nevertheless, we were able to demonstrate that children with neurologic features during acute PIMS-TS illness have a higher burden of inflammation, which may in turn influence their recovery, raising the question as to the utility of these biomarkers in directing inflammation treatments. Presence of neurologic features should alert the clinician to the potential for more systemic inflammation. Further larger scale multicenter collaborative studies are already being initiated<sup>16</sup> to map the fuller spectrum of acute and long-term neurologic features of PIMS-TS and to evaluate the treatment effects of attenuating inflammation on neurologic outcome.

## Acknowledgment

The authors are thankful to all members of the clinical teams caring for the complex needs of the patients described in this article (detailed in appendix 2, [links.lww.com/NXI/A473](https://links.lww.com/NXI/A473)).

## Study Funding

No targeted funding reported.

## Disclosure

M. Lim receives research grants from Action Medical Research, the DES society, GOSH charity, National Institute for Health Research, MS Society, and SPARKS charity; receives research support grants from the London Clinical Research Network and Evelina Appeal; has received consultation fees from CSL Behring, Novartis, and Octapharma; received travel grants from Merck Serono; and was awarded educational grants to organize meetings by Novartis, Biogen Idec, Merck Serono, and Bayer. V. Gowda receives research grants from

PTC Pharma; receives personal fees from Roche; has received sponsoring for conference attendance from PTC Pharma and Biogen; participates in commercial clinical trials from Wave Life Sciences and Catabasis. All other authors have no disclosures. Go to [Neurology.org/NN](https://Neurology.org/NN) for full disclosures.

## Publication History

Received by *Neurology: Neuroimmunology & Neuroinflammation* November 25, 2020. Accepted in final form February 22, 2021.

## Appendix 1 Authors

Name	Location	Contribution
<b>Mario Sa, MD</b>	Evelina London Children's Hospital (Evelina), United Kingdom	Designed and conceptualized the study; major role in the acquisition of data; analyzed the data; and drafted the manuscript
<b>Luwaiza Mirza, BSc</b>	King's College London, United Kingdom	Major role in the acquisition of data and analyzed the data
<b>Michael Carter, MD</b>	King's College London, United Kingdom	Major role in the acquisition of data; analyzed the data; and revised the manuscript for intellectual content
<b>Lalani Carlton Jones, MD</b>	Evelina, United Kingdom	Revised the manuscript for intellectual content
<b>Vasanth Gowda, MD</b>	Evelina, United Kingdom	Revised the manuscript for intellectual content
<b>Jennifer Handforth, MD</b>	Evelina, United Kingdom	Revised the manuscript for intellectual content
<b>Tammy Hedderly, MD</b>	Evelina, United Kingdom	Revised the manuscript for intellectual content
<b>Julia Kenny, PhD</b>	Evelina, United Kingdom	Major role in the acquisition of data and revised the manuscript for intellectual content
<b>Karine Lascelles, MD</b>	Evelina, United Kingdom	Revised the manuscript for intellectual content
<b>Jean-Pierre Lin, PhD</b>	Evelina, United Kingdom	Revised the manuscript for intellectual content
<b>Daniel Lumsden, PhD</b>	Evelina, United Kingdom	Revised the manuscript for intellectual content
<b>Marilyn McDougall, MD</b>	Evelina, United Kingdom	Major role in the acquisition of data and revised the manuscript for intellectual content
<b>Owen Miller, MD</b>	Evelina, United Kingdom	Major role in the acquisition of data and revised the manuscript for intellectual content
<b>Thomas Rossor, MD</b>	Evelina, United Kingdom	Revised the manuscript for intellectual content
<b>Vinay Shivamurthy, MD</b>	Evelina, United Kingdom	Major role in the acquisition of data and revised the manuscript for intellectual content

Continued

## Appendix 1 (continued)

Name	Location	Contribution
<b>Ata Siddiqui, MD</b>	Evelina, United Kingdom	Revised the manuscript for intellectual content
<b>Rahul Singh, MD</b>	Evelina, United Kingdom	Revised the manuscript for intellectual content
<b>Shan Tang, PhD</b>	Evelina, United Kingdom	Revised the manuscript for intellectual content
<b>Marie White, MD</b>	Evelina, United Kingdom	Major role in the acquisition of data and revised the manuscript for intellectual content
<b>Susan Byrne, PhD</b>	Evelina, United Kingdom	Designed and conceptualized the study; analyzed the data; and revised the manuscript for intellectual content
<b>Ming Lim, PhD</b>	Evelina, United Kingdom	Designed and conceptualized the study; analyzed the data; and revised the manuscript for intellectual content

## Appendix 2 Coinvestigators

Coinvestigators are listed at [links.lww.com/NXI/A473](https://links.lww.com/NXI/A473).

## References

1. Ellul MA, Benjamin L, Singh B, et al. Neurological associations of COVID-19. *Lancet Neurol* 2020;19:767–783.
2. The Royal College of Paediatrics and Child Health. Guidance: paediatric multisystem inflammatory syndrome temporally associated with COVID-19. [rcpch.ac.uk/sites/default/files/2020-05/COVID-19-Paediatric-multisystem-%20inflammatory%20syndrome-20200501.pdf](https://rcpch.ac.uk/sites/default/files/2020-05/COVID-19-Paediatric-multisystem-%20inflammatory%20syndrome-20200501.pdf). Accessed January 11, 2021.
3. Centers for Disease Control and Prevention. Multisystem inflammatory syndrome in children (MIS-C) associated with coronavirus disease 2019 (COVID-19). [emergency.cdc.gov/han/2020/han00432.asp](https://emergency.cdc.gov/han/2020/han00432.asp). Accessed January 11, 2021.
4. Whittaker E, Bamford A, Kenny J, et al. Clinical characteristics of 58 children with a pediatric inflammatory multisystem syndrome temporally associated with SARS-CoV-2. *JAMA* 2020;324:259–269.
5. Abdel-Mannan O, Eyre M, Lobel U, et al. Neurologic and radiographic findings associated with COVID-19 infection in children. *JAMA Neurol* 2020;77(11):1–6.
6. Granerod J, Ambrose HE, Davies NW, et al. Causes of encephalitis and differences in their clinical presentations in England: a multicentre, population-based prospective study. *Lancet Infect Dis* 2010;10(12):835–844.
7. Bigi S, Fischer U, Wehrli E, et al. Acute ischemic stroke in children versus young adults. *Ann Neurol* 2011;70(2):245–254.
8. Merrill JT, Erkan D, Winakur J, James JA. Emerging evidence of a COVID-19 thrombotic syndrome has treatment implications. *Nat Rev Rheumatol* 2020;16(10):581–589.
9. Lindan CE, Mankad K, Ram D, et al. Neuroimaging manifestations in children with SARS-CoV-2 infection: a multinational, multicentre collaborative study. *Lancet Child Adolesc Health* 2020;5(3):167–177.
10. Ibarondo FJ, Fulcher JA, Goodman-Meza D, et al. Rapid decay of anti-SARS-CoV-2 antibodies in persons with mild COVID-19. *N Engl J Med* 2020;383(11):1085–1087.
11. Carter MJ, Shankar-Hari M, Tibby SM. Paediatric inflammatory multisystem syndrome temporally-associated with SARS-CoV-2 infection: an overview. *Intensive Care Med* 2021;47(1):90–93.
12. Carter MJ, Fish M, Jennings A, et al. Peripheral immunophenotypes in children with multisystem inflammatory syndrome associated with SARS-CoV-2 infection. *Nat Med* 2020;26(11):1701–1707.
13. Obermeier B, Verma A, Ransohoff RM. The blood-brain barrier. *Handb Clin Neurol* 2016;133:39–59.
14. Als LC, Picouto MD, Hau SM, et al. Mental and physical well-being following admission to pediatric intensive care. *Pediatr Crit Care Med* 2015;16(5):e141–e149.
15. Peer M, Pruss H, Ben-Dayana I, Paul F, Arzy S, Finke C. Functional connectivity of large-scale brain networks in patients with anti-NMDA receptor encephalitis: an observational study. *Lancet Psychiatry* 2017;4(10):768–774.
16. The CoroNerve Studies Group. CoroNerve. [coronerve.com](https://coronerve.com). Accessed January 11, 2021.