



## Esophageal lichen planus\*

Janine Pichler de Oliveira<sup>1</sup>  
Luna Azulay Abulafia<sup>1,2</sup>

Natalia Caballero Uribe<sup>1</sup>  
Leonardo Pereira Quintella<sup>1,3</sup>

DOI: <http://dx.doi.org/10.1590/abd1806-4841.20153255>

**Abstract:** Lichen planus is a chronic inflammatory disease that affects the skin, mucous membranes, nails and scalp. Esophageal lichen planus is a rarely reported manifestation of lichen planus, presenting itself commonly in middle-aged women, with symptoms such as dysphagia. We report a case of esophageal lichen planus in a 54-year-old woman associated with oral, cutaneous and unguinal lichen planus. Although lichen planus is a disorder well known by dermatologists, reports of esophageal lichen planus are rare in dermatologic literature. The esophageal lichen planus is little known and underdiagnosed, with a significant delay between the onset of symptoms and diagnosis.

**Keywords:** Endoscopy, digestive system; Lichen planus; Lichen planus, oral

### INTRODUCTION

Lichen planus (LP) is a common disease that usually involves the scalp, nails, skin and mucosae. It affects 0.5% to 2% of the population and has a predilection for women between the fourth and fifth decade of life.<sup>1,2</sup> Esophageal lichen planus (ELP) is a rarely reported manifestation of LP that frequently presents itself in middle-aged women as dysphagia secondary to upper esophageal lesions and stenoses.<sup>3,4,5</sup> ELP is a recently recognized entity. In 1982, Al-Shihabi-Jackson and Lefter, simultaneously, but in independent studies, reported the first cases of ELP in English literature.<sup>3</sup> Even though LP is a disorder well known by dermatologists, reports of ELP are rare in dermatological literature.

### CASE REPORT

Female patient, 54 years old, reported for 3 months hyperchromic pruritic papules distributed on the trunk, upper and lower limbs, associated with unguinal dystrophy and whitish plaque on the dorsum of the tongue. She reported odynophagia and dysphagia. The examination showed white thin streaks of reticulated aspect over the dorsum of tongue; on jugal mucosa there were bilateral white streaks of ar-

boriform aspect (Figures 1 and 2). On the upper limbs: hyperchromic polygonal papules, measuring 2-5 mm, with predominance in the flexural area of the wrists. On nail apparatus: longitudinal convergent streaks, dorsal pterygium, melanonychia, onychorexis and onychodystrophy (Figure 3). In the left pretibial region, there were hyperchromic plaques of keratotic and hypertrophic surface (Figure 4). Cutaneous and unguinal biopsies resulted in a report compatible with lichen planus. Histopathology of jugal mucosa showed epithelium with acanthosis and an inflammatory process in "lichenoid pattern". In upper digestive endoscopy it was observed: white streaks of reticulate aspect in the upper third of esophagus (Figure 5). Biopsy of esophagus: chorion with confluent inflammatory infiltrate in the present connective stroma and among basal keratinocytes of squamous epithelium (Figure 6). Laboratory tests without changes. Topical occlusive clobetasol was administered in the pretibial region in addition to antihistamine and prednisone 60 mg/day with significant improvement of esophageal, cutaneous, oral and nail symptoms after 4 weeks.

Received on 07.11.2013

Approved by the Advisory Board and accepted for publication on 28.11.2014

\* Work performed at Instituto de Dermatologia Professor Rubem David Azulay da Santa Casa de Misericórdia do Rio de Janeiro – Rio de Janeiro (RJ), Brazil.

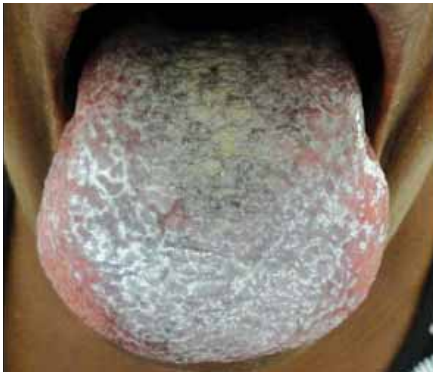Financial Support: None.  
Conflict of Interest: None.

<sup>1</sup> Instituto de Dermatologia Prof. Rubem David Azulay, Santa Casa de Misericórdia do Rio de Janeiro - Rio de Janeiro (RJ), Brazil.

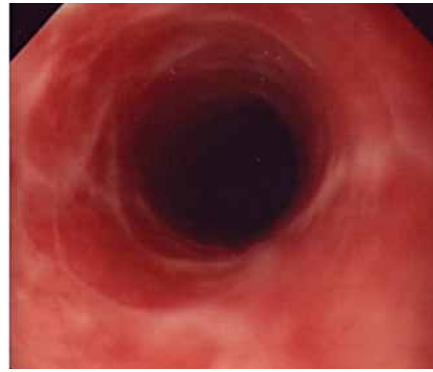
<sup>2</sup> Universidade do Estado do Rio de Janeiro (UERJ) - Rio de Janeiro (RJ), Brazil.

<sup>3</sup> Instituto Nacional de Infectologia Evandro Chagas da FIOCRUZ - Rio de Janeiro (RJ), Brasil.

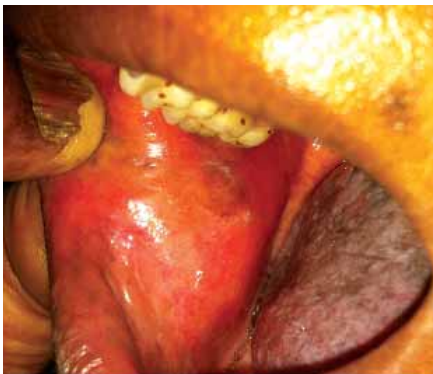©2015 by Anais Brasileiros de Dermatologia



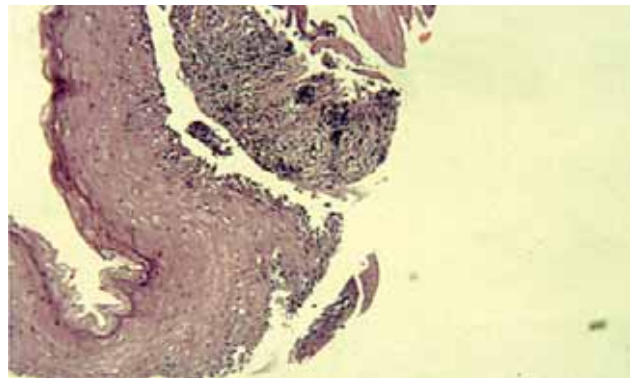
**FIGURE 1:** Thin white streaks of reticulate aspect on the dorsum of tongue



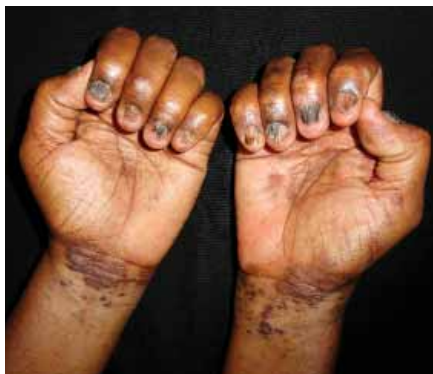**FIGURE 5:** Upper digestive endoscopy: white streaks of reticulate aspect in upper third of esophagus



**FIGURE 2:** Bilateral white streaks of arboriform aspect in jugal mucosa



**FIGURE 6:** Chorion with confluent inflammatory infiltrate in the present connective stroma and among basal keratinocytes of squamous epithelium

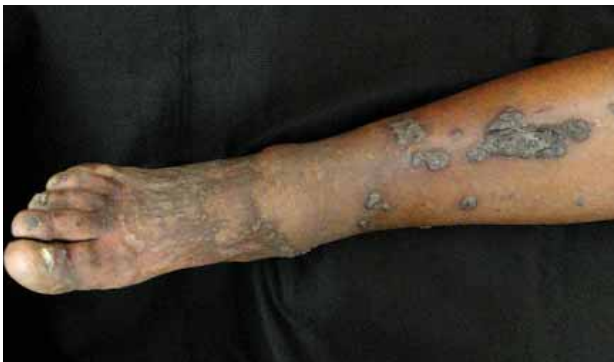

**FIGURE 3:** Dorsal pterygium, melanonychia, onychorexis, onychodystrophy on fingernails, hyperchromic, bright and polygonal papules on wrists

**DISCUSSION**

Lichen planus is a chronic inflammatory disease that involves the skin, mucosae, nails and scalp.<sup>1</sup> The true prevalence of esophageal lichen planus in the general population is almost impossible to determine for several reasons, such as: lack of clinical and pathological knowledge of this condition, high rates of asymptomatic or subtle disease, and the possibility that esophageal involvement may be the only manifestation of lichen planus.<sup>3,6-9</sup>

During a review of 79 cases published in the literature about ELP a marked predilection for middle-aged women was noticed, affecting preferably patients with oral and/or vulvar LP, as well as the described case. Extraesophageal LP may be present in up to 99% of the patients, and it is more commonly found in the oral cavity (89%) and vulva (42%). The patient presented oral, but not genital LP. The most common symptoms are dysphagia (81%), odynophagia (24%) and weight loss (14%), the same ones reported by our patient.<sup>3</sup> Other symptoms that suggest the involvement of the esophagus include hoarseness, choking, and epigastric pain. Changes in the symptoms, such as epigastric pain and reflux to odynophagia, may



**FIGURE 4:** Papules and hypertrophic plaques with keratotic surface on left leg

suggest a malignant transformation to squamous cell carcinoma. Although it has not been possible to clearly determine in literature the onset of symptoms of ELP with respect to extraesophageal LP, certain observations showed that esophageal symptoms may precede, appear simultaneously or develop after the diagnosis of cutaneous, oral or genital LP.

Thyroid diseases were the most commonly associated with ELP, however the patient in question did not present any associated comorbidity. Even though infectious hepatitides, especially hepatitis C, have been reported as associated with LP, there are no data specifically associating infectious hepatitis with ELP.<sup>3</sup>

Endoscopy findings are fundamental to perform diagnosis of ELP, for the disease typically involves the proximal and middle esophagus, as in this clinical case, whereas reflux esophagitis is always distal.<sup>10</sup> Preservation of gastroesophageal junction in ELP is an important resource that helps in the differentiation of ELP and gastroesophageal reflux disease. The description of esophageal findings in endoscopy may vary and, sometimes, are described as "subtle", but the majority characteristically include pseudomembranes, friability and bleeding of the inflamed mucosa, especially after the passage of the endoscope, besides submucosal papules and plaques. Other suggestive findings include reticulated white streaks, such as in the present case; in addition to erosions, ulcerations and stenoses.

The literature review discloses that, differently from cutaneous LP lesions, the histopathology of ELP is highly variable and many times inconclusive, with unspecific histopathological diagnosis, such as "esophagitis" or "chronic inflammation", similar to what was found in our case.<sup>3,10</sup> However, the physician is oftentimes capable of achieving a definitive diagnosis with the correct clinical approach and suggestive histopathological characteristics. The litera-

ture about ELP histopathology is extremely scarce. In general, the histopathological characteristics resemble more oral LP than cutaneous LP.

The esophagus lacks a granular layer and stratum corneum, hypergranulosis is often absent and hyperkeratosis, if present, is composed of parakeratosis rather than orthokeratosis. Dense lymphocytic band infiltrating the lamina propria, degeneration of the basal layer and subepidermal Civatte bodies (necrotic keratinocytes) are typically present.

IgM deposits detected through direct immunofluorescence are highly characteristic, but do not diagnose LP.<sup>1</sup>

Esophageal lichen planus is a potentially premalignant condition for squamous cell carcinoma, with cases already described. The risk of transformation into malignant diseases is currently unknown, but it can be equivalent to oral lesions - approximately 1-3%.<sup>3,6</sup>

Endoscopy should be carried out in all patients with mucocutaneous LP who complain of dysphagia or odynophagia. Authors recommend endoscopic evaluation every 1-2 years, mainly in patients with oral lichen planus or oral lichen planus associated with squamous cell carcinoma.<sup>3</sup>

Therapies for ELP include systemic corticosteroids, cyclosporine, azathioprine and systemic retinoids (etretinate and acitretin). The analysis showed that systemic corticoids were the most efficient in the dose of 40-60 mg/day during 4-6 weeks. The response was normally observed in 1 to 2 weeks.

Esophageal lichen planus is little known and underdiagnosed, presenting a significant delay between the onset of symptoms and the diagnosis. This disease must be strongly considered as differential diagnosis in middle-aged women with LP which presents symptoms such as dysphagia and odynophagia. □

## REFERENCE

- Sharma A, Bialynicki-Birula R, Schwartz RA, Janniger CK. Lichen planus: an update and review. *Cutis*. 2012;90:17-23.
- Cribier B, Frances C, Chosidow O. Treatment of lichen planus: an evidence-based medicine analysis of efficacy. *Arch Dermatol*. 1998;134:1521-30.
- Fox LP, Lightdale CJ, Grossman ME. Lichen planus of the esophagus: What dermatologists need to know. *J Am Acad Dermatol*. 2011;65:175-83.
- Carlos AM, Müller H, Freitas RR, da Silva Santos OS. Oral lichen planus (OLP): clinical and complementary diagnosis. *An Bras Dermatol*. 2010;85:669-75.
- Czerninski R, Pikovsky A. Update and review of oral lichen planus. *Refuat Hapeh Vehashinayim*. 2013;30:31-7,80.
- Menges M, Hohloch K, Pueschel W, Stallmach A. Lichen planus with oesophageal involvement. A case report and review of the literature. *Digestion*. 2002;65:184-9.
- Ruzo JS, Tchekmedyian AJ, Millán MAV, López JAY, Monreal FA, Aguirre PAA, Iglesias JLV. Liquen plano esofágico: hallazgos clínicos, endoscópicos, endosonográficos e histológicos. *Rev Esp Enferm Dig*. 2005;97:753-55.
- Evans AV, Fletcher CL, Owen WJ, Hay RJ. Oesophageal lichen planus. *Clin Exp Dermatol*. 2000;25:36-7.
- Sheehan-Dare RA, Cotterill JA, Simmons AV. Oesophageal lichen planus. *Br J Dermatol*. 1986;115:729-30.
- Navas-Alfaro SE, da Fonseca EC, Guzmán-Silva MA, Rochael MC. Análise histopatológica comparativa entre liquen plano oral e cutâneo. *J Bras Patol Med Lab* 2003;39:351-60.

## MAILING ADDRESS:

Natalia Caballero Uribe

Rua Cananeia 168

CEP 09060480 - Santo André - SP

Brazil

E-mail: natycaballero476@gmail.com

How to cite this article: Oliveira JP, Uribe NC, Azulay-Abulafia L, Quintella LP. Esophageal lichen planus. *An Bras Dermatol*. 2015; 90(3):394-6.