

CASE REPORT

Strangulated Richter's incisional hernia presenting as an abdominal mass with necrosis of the overlapping skin. A case report and review of the literature

Georgios Sahsamani^{ID}, Stavros Samaras, Konstantinos Gkouzis & Georgios Dimitrakopoulos

1st Department of Surgery, 401 General Military Hospital, Athens, Greece

Correspondence

Georgios Sahsamani, 1st Department of Surgery, 401 General Military Hospital of Athens, Mesogeion Avenue 138 and Katexaki, Athens 15561, Greece. Tel: +30 210 7494236; Fax: +30 210 7494095; E-mail: sachsamani@hotmail.com

Funding Information

No sources of funding were declared for this study.

Received: 2 August 2016; Accepted: 25 November 2016

Clinical Case Reports 2017; 5(3): 253–256

doi: 10.1002/ccr3.776

Introduction

Richter's hernia is defined as the protrusion of the antimesenteric wall of a bowel loop through a rigid orifice in the abdominal wall. It is a rare medical condition with innocuous clinical manifestation leading usually to misdiagnosis. Due to its possible complications and high mortality rates [1], an accurate preoperative diagnosis and timely surgical management are mandatory. We present the case of a 47-year-old male patient with sudden onset of periumphalic pain and a tender discolored umbilical mass due to a strangulated umbilical hernia of the Richter type, manifesting 6 months after laparoscopic surgery. The strangulation was so severe that caused distension and necrosis of the overlapping skin and elimination of the umbilicus. Our perioperative management will be discussed, with a review of the literature.

Case Presentation

A 47-year-old Caucasian male admitted in the emergency department, complaining of progressive cramping periumphalic pain for the past 6 h, combined with two

Key Clinical Message

Although rare, clinicians must be alerted of Richter hernias in patients presenting with innocuous gastrointestinal obstruction symptoms, synchronous with an erythematous hernia. An incarcerated incisional hernia located in a previous laparoscopic insertion site further raises suspicion, while timely surgical management is essential to avoid bowel perforation or resection.

Keywords

Case report, incisional hernia, richter hernia, strangulated hernia, umbilical hernia.

episodes of vomiting. He was in agony, while breathing heavily due to severe pain. His past medical history included glaucoma, hypertension, and a laparoscopic cholecystectomy 6 months ago. Physical examination revealed a hard and tender periumphalic mass, with distension of the abdominal wall and elimination of the umbilicus (Fig. 1). The overlapping skin was discolored with signs of ischemia and necrosis. Manipulation of the mass was avoided.

Laboratory data uncovered a WBC count of $19.7 \times 10^3/\mu\text{L}$, and hemoglobin was 12.4 g/dL. Biochemistry examinations disclosed AST 6 U/L, ALT 10 U/L, alkaline phosphatase 74 U/L, albumin 4.1 g/dL, LDH 947 U/L, potassium 4.2 mEq/L, sodium 146 mEq/L, creatinine 1.2 mg/dL, urea 122 mg/dL, and glucose 84 mg/dL. Urine examinations were within normal limits.

Ultrasonography of the bulging area revealed a strangulated umbilical hernia with its sac containing the antimesenteric wall of a bowel loop and a large concentration of fluid. Patient was in serious pain, thus rendering the examination difficult. Necrotic signs of the periumphalic skin along with patient's severe clinical condition led to the decision of performing emergency surgery prior to a

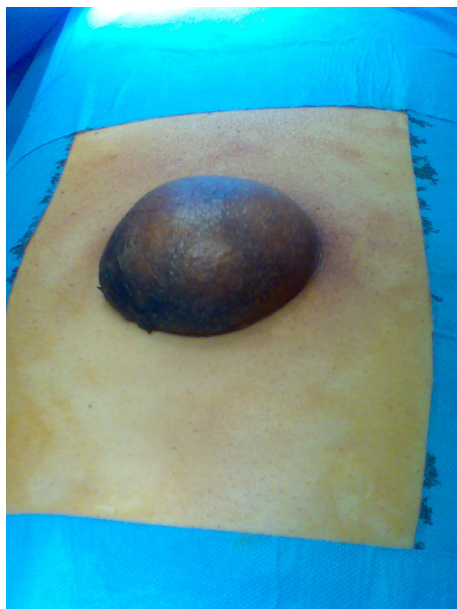

Figure 1. Periumphalic mass with the overlapping skin being discolored and ischemic. The umbilicus is eliminated.

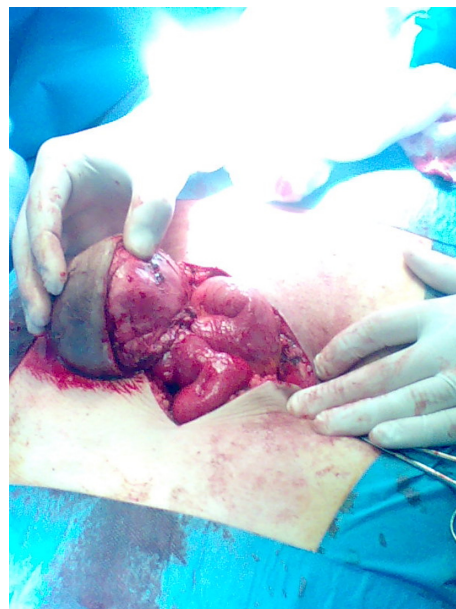

Figure 2. Hernia sac with incarcerated part of the antimesenteric small bowel wall.

CT examination of the abdomen. After written consent was obtained, patient was taken to the operating room.

Under general anesthesia, a midline supra-infraumbilical incision was performed, enclosing the abdominal dilatation. A large hernia sac was uncovered passing through the umbilical ring (Fig. 2). Proximal small bowel loops were edematous (Fig. 3A and B). Intestinal lumen was patent but stenosed due to the herniated part of the bowel wall. Opening the hernia sac uncovered a large concentration of serous fluid and the circumferential part of a small bowel loop being strangulated, discolored, but with no signs of gangrene (Fig. 4). After resolving the strangulation, the intestine regained its peristalsis and no resection was performed. Subsequently, an intraperitoneal mesh (Proceed-Ethicon, MediCare, Athens) was sutured to the overlying fascia, in order to strengthen the abdominal wall. Due to necrotic signs, the overlapping skin was excised, and umbilicoplasty was implemented for fixation of the umbilicus.

Postsurgical period was uneventful, with normal intestinal function on the 2nd postoperative day. Patient was discharged at 6th day with no complications. 6-month follow-up showed no recurrence of the hernia or further episodes of vomiting.

Discussion

Richter's hernia is characterized by the protrusion of the antimesenteric part of the intestine through a rigid abdominal wall defect [2]. August Gottlob Richter was the first to describe it in 1778 [2]. It is a rare type of

hernia with the femoral ring being the most common site of development (71–88%). Other encountered locations are the inguinal canal (23–24%) and the abdominal wall (4–6%), usually after abdominal incisions [3, 4]. Hernias of the Richter type usually involve the terminal ileus, but other parts of the gastrointestinal tract can also become incarcerated [4]. Approximately 6% of all strangulated hernias are of the Richter type [1]. Clinical manifestation can be obscure and misleading, with vague abdominal pain, nausea, and episodes of vomiting; it is characterized by the absence of gastrointestinal obstruction symptoms despite the strangulation, as the bowel lumen remains patent. In case of a high index of suspicion for such a hernia, manual reduction is not advisable; it could lead to the introduction of necrotic bowel inside the abdominal cavity. A compromised bowel wall can lead to intra-abdominal bowel perforation, peritonitis, and rapid clinical deterioration. Presentation can also be as an acute abdomen with typical obstructive ileus symptoms as seen in our patient. Cases of intermittent progressive ileus have also been reported as the incarcerated wall can lead to incomplete gastrointestinal obstruction [1]. Physical examination can be inconclusive with the presence of an erythematous hernia being the most specific finding. Clinicians must be suspected for the possibility of a Richter-type hernia in patients with an abdominal bulge in a previous laparoscopic insertion site. We suggest a 24-h surveillance of patients after reduction in a tender incarcerated abdominal or inguinal hernia and the absence of gastrointestinal obstruction symptoms.

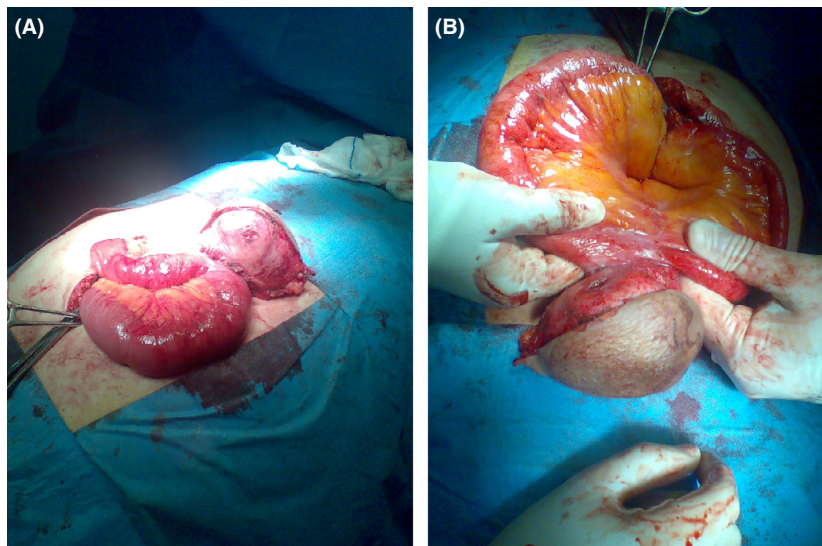


Figure 3. (A, B) Edematous bowel loops proximal to the strangulation.

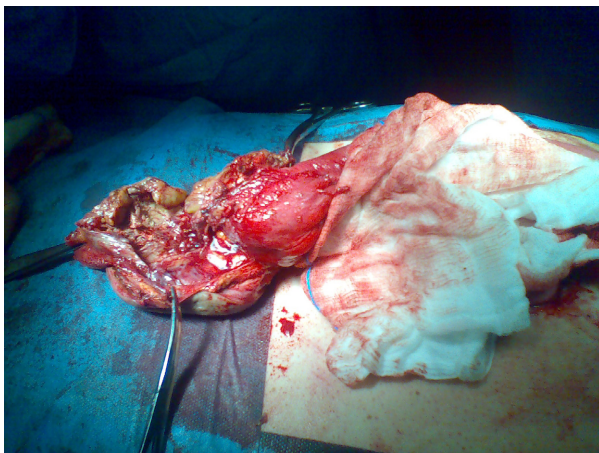


Figure 4. Opened hernia sac. The incarcerated bowel wall segment had no signs of gangrene due to timely surgical intervention.

There are various radiological modalities, with U/S and CT scan playing a major role in diagnosing this condition [5]. A U/S scan can identify the incarcerated wall segment, and compare its blood perfusion and possible edema with the circumferential nonpathologic part. A CT examination can show the contents of the hernia's sac, thus helping in the preoperative management and differential diagnosis from abdominal mass or abscess, although due to the apparent emergency nature of this condition, an accurate diagnosis is often made intraoperatively [6, 7].

Richter's hernia requires urgent surgical management due to its possible complications. Strangulation of the bowel wall compromises its blood perfusion and causes

ischemia. This can lead to gangrene and bowel perforation, further resulting in peritonitis or the creation of a subcutaneous abscess [3, 4]. Open surgery or laparoscopy methods are viable for treatment. Resection of the gangrenous part of the bowel is suggested if it comprises more than 50% of the circumference bowel wall or extends to the mesenteric part [3].

Due to timely surgical intervention, our patient avoided bowel perforation and a possible resection. Incarceration of the bowel wall possibly occurred through the laparoscopic insertion site created 6 months ago.

Conclusion

Although a rare medical condition, clinicians must have a high index of suspicion for the possibility of a Richter-type hernia, in patients presenting with innocuous gastrointestinal obstruction symptoms synchronous with an erythematous hernia. The presence of an incarcerated incisional hernia located in a previous laparoscopic insertion site further raises suspicion, while diagnosis can be set with U/S or CT scan. Timely surgical management is essential to avoid bowel perforation or resection.

Conflict of Interest

All authors declare that they have no conflict of interest.

Authorship

GS: wrote the manuscript, collected and analyzed the data, reviewed the literature, while he also critically revised the submitted manuscript. SS and KG: reviewed

the literature and contributed in manuscript preparation. GD: performed the operation with the help of KG, while he supervised the entire manuscript preparation and submission process. All authors accepted the final version of the submitted manuscript.

References

1. Kang, C.-H., and C.-Y. Tsai. 2014. Richter's femoral hernia manifested by a progressive ileus. *Formos J. Surg.* 47:193–196.
2. Steinke, W., and R. Zellweger. 2000. Richter's hernia and Sir Frederick Treves: an original clinical experience, review, and historical overview. *Ann. Surg.* 232:710–718.
3. Martis, J. J., K. V. Rajeshwara, M. K. Shridhar, D. Janardhanan, and S. Sudarshan. 2011. Strangulated Richter's Umbilical Hernia - a case report. *Indian J. Surg.* 73:455–457.
4. Arkoulis, N., G. Savanis, and G. Simatos. 2012. Richter's type strangulated femoral hernia containing caecum and appendix masquerading as a groin abscess. *J. Surg. Case Rep.* 2012:6.
5. Middlebrook, M. R., and F. Eftekhari. 1992. Sonographic findings in Richter's hernia. *Gastrointest Radiol.* 17:229–230.
6. Hayden, G. E., and K. L. Sprouse. 2011. Bowel obstruction and hernia. *Emerg. Med. Clin. North Am.* 29:319–345, ix.
7. Lassandro, F., F. Iasiello, N. L. Pizza, T. Valente, M. L. Stefano, R. Grassi, et al. 2011. Abdominal hernias: radiological features. *World J. Gastrointest Endosc.* 3:110–117.