

Treatment for thoracoabdominal aortic aneurysm by fenestrated endovascular aortic repair with physician-modified stent graft

Journal of International Medical Research

2018, Vol. 46(5) 2014–2022

© The Author(s) 2018

Reprints and permissions:

sagepub.co.uk/journalsPermissions.nav

DOI: 10.1177/0300060518761521

journals.sagepub.com/home/imr



**Xin Yang, Xiang-Chen Dai, Jie-Chang Zhu,
Yu-Dong Luo, Hai-Lun Fan, Zhou Feng,
Yi-Wei Zhang and Fan-Guo Hu**

Abstract

Despite being widely used for several years, the endovascular aortic repair (EVAR) of a thoracoabdominal aneurysm (TAAA) remains challenging, particularly the revascularization of the abdominal aortic visceral branches. A 66-year-old male was admitted to hospital with abdominal bloating and pain. Computed tomographic angiography (CTA) confirmed a Crawford type III TAAA from the distal descending aorta to the suprarenal abdominal aorta that involved the celiac axis, accompanied with an occlusion of the left subclavian artery. Fenestrated-EVAR was performed successfully and 1 week later CTA showed a type III endoleak, which had resolved 3 months later, without stent migration or visceral artery occlusion. In this present case, the surgeons preferred to perform the procedure in three surgical stages, postponing the deployment of a covered stent in the CA fenestration to provide additional time for the development of collateral circulation to the spinal cord as a possible means of preventing postoperative paraplegia.

Keywords

Thoracoabdominal aortic aneurysm, endovascular aortic repair, fenestrated, physician-modified stent graft

Date received: 26 November 2017; accepted: 4 February 2018

Department of Vascular Surgery, Tianjin Medical University General Hospital, Tianjin, China

Corresponding author:

Xiang-Chen Dai, Department of Vascular Surgery, Tianjin Medical University General Hospital, 154 Anshan Road, Heping District, Tianjin 300052, China.
Email: 13302165917@163.com



Creative Commons Non Commercial CC BY-NC: This article is distributed under the terms of the Creative Commons Attribution-NonCommercial 4.0 License (<http://www.creativecommons.org/licenses/by-nc/4.0/>)

which permits non-commercial use, reproduction and distribution of the work without further permission provided the original work is attributed as specified on the SAGE and Open Access pages (<https://us.sagepub.com/en-us/nam/open-access-at-sage>).

Introduction

Despite being widely used for several years, the endovascular aortic repair (EVAR) of a thoracoabdominal aneurysm (TAAA) remains challenging, particularly the revascularization of the abdominal aortic visceral branches. The parallel stent graft technique is relatively easy, but the incidence of endoleaks and stent occlusion is high because of the gutter between the stents.¹ Fenestrated and branched EVAR might overcome the latter shortcomings by maintaining the original anatomical structure and blood supply of visceral arteries without the development of a gutter. In the last 2 years, the Department of Vascular Surgery, Tianjin Medical University General Hospital, Tianjin, China has performed over 60 fenestrated (f)-EVARs. The case presented here illustrates the successful three-stage implantation of four fenestrated stent grafts in a patient with a Crawford type III TAAA and occlusion of the left subclavian artery (LSA).

Case report

A 66-year-old male was admitted to the Department of Vascular Surgery, Tianjin Medical University General Hospital, Tianjin, China in October 2016 with the main complaint of abdominal bloating and pain for 2 days. A thoracoabdominal aortic aneurysm (Crawford type III) from the distal descending aorta to the suprarenal abdominal aorta that involved the celiac axis (CA), accompanied with an occlusion of the LSA, was diagnosed by computed tomographic angiography (CTA) (Figure 1). Using 3-Mensio Workstation software (Pie Medical Imaging, Maastricht, The Netherlands), aortic measurements were obtained with the superior margin of the CA as baseline (Table 1; Figures 2A and 2B).

In brief, the surgical procedure involved the following three stages (Figure 3): (i) revascularization of the LSA, which was cannulated through the femoral artery and the left brachial artery. Under local anaesthesia, a balloon-expandable bare metal stent was implanted at the location of the occlusion (Figures 3A and 3B); (ii) modification and deployment of the stent graft with four fenestrations, and revascularization of the superior mesenteric artery (SMA) and bilateral renal arteries (RA) but not the CA; and (iii) revascularization of the CA.

The surgeon created four fenestrations in a 26 × 26 × 134 mm Zenith Flex thoracic stent graft (Cook Medical, Bloomington, IN, USA; Table 1; Figure 4). First, the outer sheath of the stent graft's delivery system was retracted to verify that the stent graft released completely. Secondly, a marker pen was used to mark the previously determined fenestrated position, which was notched using an electro-tome. Thirdly, the radio-opaque wire of a snare (the head of a 20 mm × 120 cm amplatz goose neck snare kit; Medtronic, Dublin, Ireland) was sutured along the edges of the fenestrations to serve as fluoroscopic markers. Next, a 0.014-inch diameter guidewire was used to narrow the stent graft at its dorsal portion.¹ Then the anterior part of this guidewire was placed into the inner core conveyer. While the posterior part was prepared for standby application. A 0.014-inch diameter guidewire also was placed into the fenestration of the left RA. Finally, the modified stent graft was sent back into the delivery system.

With the patient under general anaesthesia, the bilateral femoral arteries were punctured using Seldinger's technique. The left axillary artery was then incised for standby use. A pigtail catheter was advanced through the right femoral access into the T10 section. The images from digital subtraction angiography (DSA) in Figures 3C and 3D show the

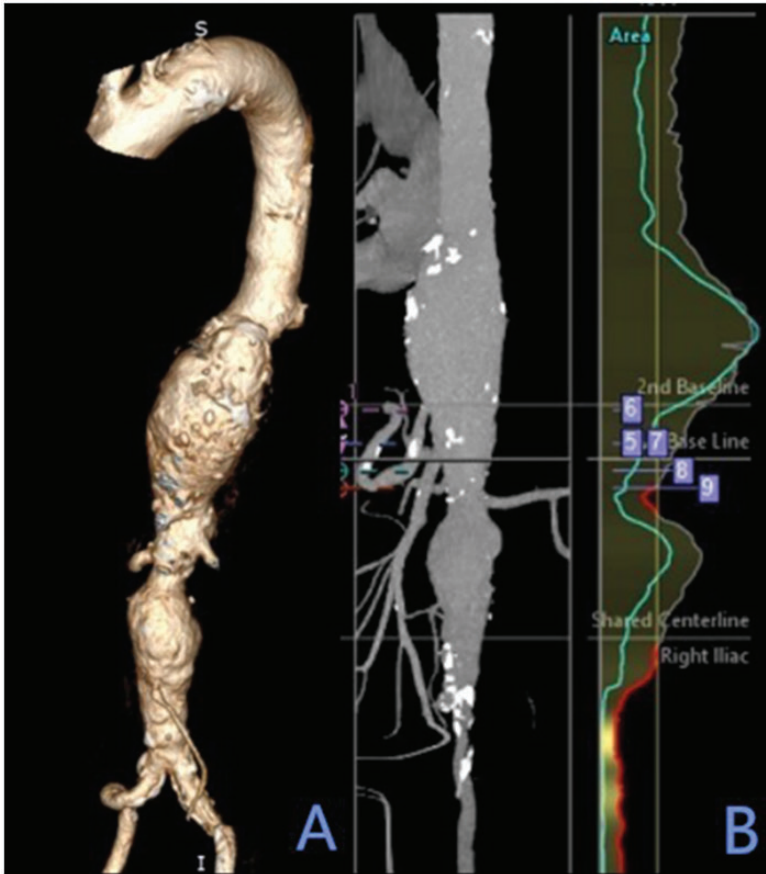

Figure 1. Preoperative computed tomographic angiography of a 66-year-old male who complained of abdominal bloating and pain for 2 days: (A) three-dimensional image of the aorta and iliac artery; (B) two-dimensional image of the same structures. A thoracoabdominal aortic aneurysm (Crawford type III) from the distal descending aorta to the suprarenal abdominal aorta that involved the celiac axis, accompanied with an occlusion of the left subclavian artery, was diagnosed. The colour version of this figure is available at: <http://imr.sagepub.com>.

abdominal aortic aneurysm at this point. Via the left femoral artery, the Cook $26 \times 26 \times 134$ mm Zenith Flex thoracic stent graft (Cook Medical), which had been modified with four fenestrations for the SMA, CA and bilateral RAs, was deployed with the help of the guidewire. A guidewire was also placed into the bilateral RAs and the SMA (Figure 3E), and long sheaths were introduced via the left axillary artery. After the covered stent graft opened completely, 6×24 mm balloon-expandable bare metal

stents were advanced through both the left and right RAs (Figures 3F and 3G); and an 8×25 mm Viabahn™ self-expanding covered stent (Gore & Associates, Flagstaff, AZ, USA) was placed into the SMA, while postponing revascularization of the CA. Next, a Medtronic thoracic covered stent graft ($30 \times 30 \times 150$ mm; Medtronic) was placed connecting with the proximal area of the Cook $26 \times 26 \times 134$ mm Zenith Flex thoracic stent graft close to the edge of the CA fenestration (Figure 3H), and another

Table 1. Aortic measurements were obtained with the superior margin of the celiac axis as baseline in a 66-year-old male with a thoracoabdominal aortic aneurysm (Crawford type III) from the distal descending aorta to the suprarenal abdominal aorta that involved the celiac axis, accompanied with an occlusion of the left subclavian artery

Aortic measurements	Distance, mm	Aortic diameter, mm	Radian length, mm	Clock position	Branch diameter, mm	Bifurcation diameter, mm	Angle	Bony landmark
Proximal neck of aneurysm	-82.0	25.0						
Celiac axis	0	33.0	10.5	1:30	7.0	23.0	RAO60 CRA10	T12-L1
Superior mesenteric artery	19.0	25.0	0.0	12:30	7.5		RAO60	Superior L1
Left renal artery	34.0	21.0	19.5	3:45	6.0		LAO15	Inferior L1
Right renal artery	39.0	19.0	13.0	9:45	6.0		LAO15	Superior L2

RAO, right anterior oblique; CRA, cranial; LAO, left anterior oblique.

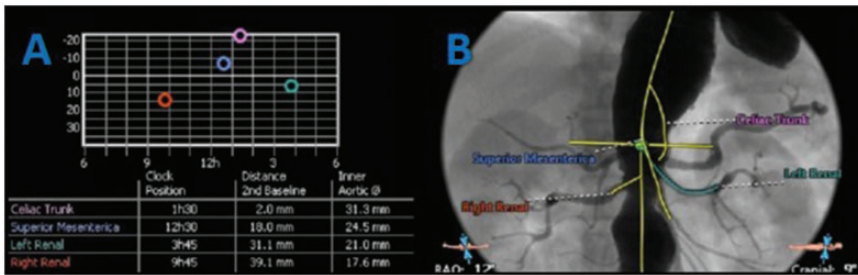


Figure 2. Preoperative aortic measurements were obtained with the superior margin of the celiac axis as baseline in a 66-year-old male with a thoracoabdominal aortic aneurysm (Crawford type III) from the distal descending aorta to the suprarenal abdominal aorta that involved the celiac axis, accompanied with an occlusion of the left subclavian artery: (A) measurement of the clock position, distance 2nd baseline, and inner aortic angle of the abdominal branches; (B) central line of abdominal branches. The colour version of this figure is available at: <http://imr.sagepub.com>.

Gore covered stent graft (28 × 12 × 170 mm; Gore & Associates) and a right iliac extension (16 × 12 × 120 mm) were implanted connecting with the distal area of the Cook 26 × 26 × 134 mm Zenith Flex thoracic stent graft (Figure 3I). DSA showed that the TAAA was completely repaired, with patent bilateral RAs, SMA and bilateral iliac arteries, and an endoleak at the CA section where the reconstruction of the CA fenestration had been postponed (Figures 3J and 3K).

The Perclose ProGlide® Suture-Mediated Closure System (Abbott Laboratories, Abbott Park, IL, USA) was used to suture the bilateral femoral arteries to ensure haemostasis.

Subsequent revascularization of the CA after 7 days was performed under local anaesthesia as follows. The left brachial artery was punctured, a 6-F sheath (Cordis, Milpitas, CA, USA) was introduced, and the catheter was placed into the aortic arch.

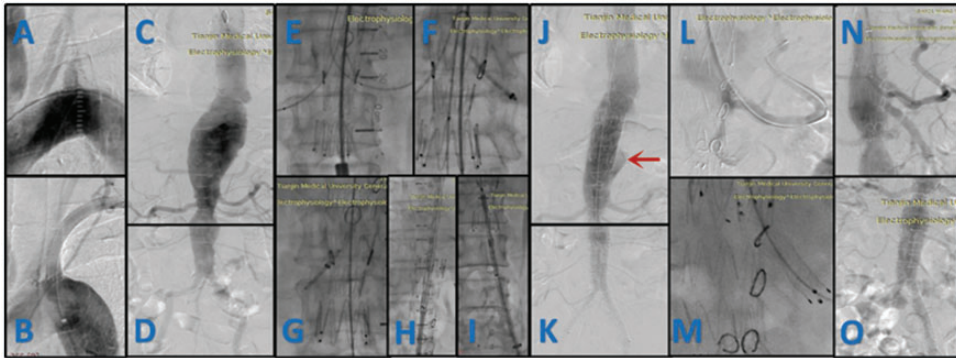


Figure 3. Surgical procedure in a 66-year-old male with a thoracoabdominal aortic aneurysm (Crawford type III): (A) left subclavian artery (LSA) before stent implantation; (B) LSA post stent implantation; (C) preoperative digital subtraction angiography (DSA) of the aneurysm above the kidney; (D) preoperative DSA of the infrarenal aneurysm; (E) the guidewire and sheath were advanced through the superior mesenteric artery and the bilateral renal arteries; (F) the stent was placed into the left renal artery; (G) the stent was placed into the right renal artery; (H) the aortic covered stent was released; (I) the stent was placed into the infrarenal aneurysm; (J) DSA of the aneurysm above the kidney after release with the arrow showing the overflowing contrast medium; (K) DSA of the infrarenal aneurysm after release; (L) DSA after the guidewire was placed into the celiac axis (CA); (M) CA stent was implanted; (N) DSA of the aneurysm above the kidney after CA stenting; (O) DSA of the infrarenal aneurysm after CA stenting. The colour version of this figure is available at: <http://imr.sagepub.com>.




Figure 4. The surgeon created four fenestrations in a $26 \times 26 \times 134$ mm Zenith Flex thoracic stent graft (Cook Medical, Bloomington, IN, USA): (A) the fenestration *in vitro*; (B) the modified stent graft was sent back into the delivery system. The arrow shows the preloading guidewire. The colour version of this figure is available at: <http://imr.sagepub.com>.

DSA showed a normal CA fenestration area and contrast medium overflow at the location where the reconstruction had been postponed (Figure 3L). With the help of a 6-F sheath (Cordis), a 35×150 mm Radifocus[®] guidewire (Terumo, Leuven, Belgium) was advanced into the CA, and the sheath was placed via a 35×300 mm Hi-Torque Supra

Core[®] 35 guidewire (Abbott Laboratories). Finally, an 8×25 mm Viabahn[™] self-expanding covered stent (Gore & Associates) and an 8×40 mm Fluency[®] Plus Endovascular Stent Graft (BARD Peripheral Vascular, Tempe, AZ, USA) were advanced and deployed (Figure 3M). Thoracoabdominal aortic DSA 1 week later

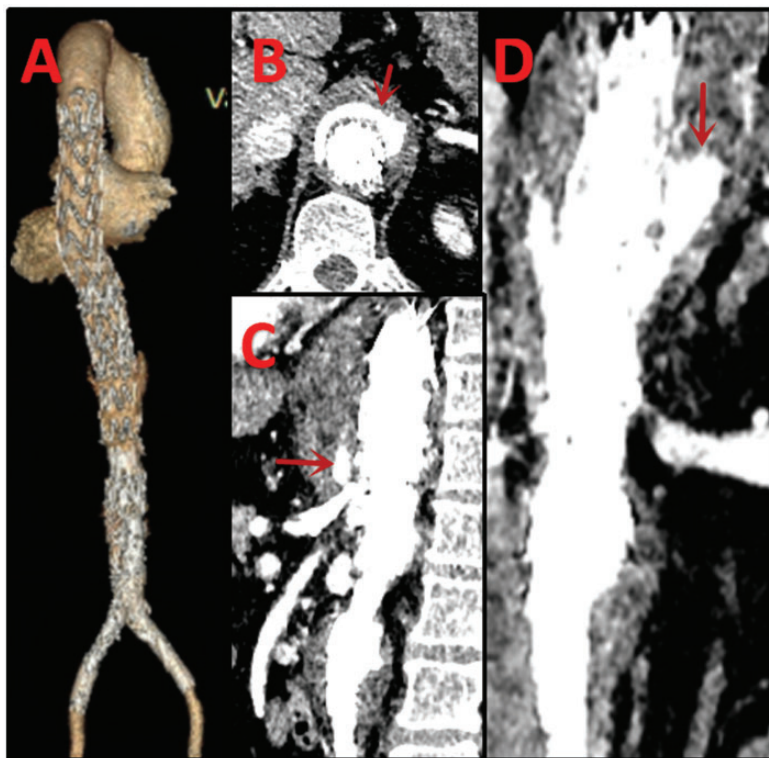


Figure 5. Postoperative computed tomographic angiography images at 1 week after the final surgical stage in a 66-year-old male with a thoracoabdominal aortic aneurysm (Crawford type III): (A) three-dimensional image of the aorta and iliac artery; (B–D) endoleak around the graft in axial, sagittal, and coronal images, respectively. The arrows show the endoleak at the section of CA. The colour version of this figure is available at: <http://imr.sagepub.com>.

showed that the TAAA was isolated completely and that the visceral arteries remained patent (Figures 3N and 3O).

In terms of the patient's postoperative recovery, a physical examination after the first surgical stage revealed recovery of a brachial artery pulse with normalization of the skin temperature of the left arm. Following the second surgical stage, the patient no longer suffered from chest or abdominal pain and had greater left arm flexibility. After the third surgical stage, the patient ate normally and moved well. Thoracoabdominal aortic CTA 1 week later showed no stent migration and sustained patency of all visceral arteries.

However, there remained a type III endoleak around the origin of the celiac artery (Figure 5). CTA at 3-months follow-up showed that the type III endoleak had resolved and there was no stent migration or visceral artery occlusion (Figure 6).

Discussion

Fenestrated stent graft technology, albeit more technically complex and requiring more experience than parallel stent graft techniques, broadens the surgical options for EVAR of TAAA while reducing post-operative complications. In the present case, a three-stage surgical approach was

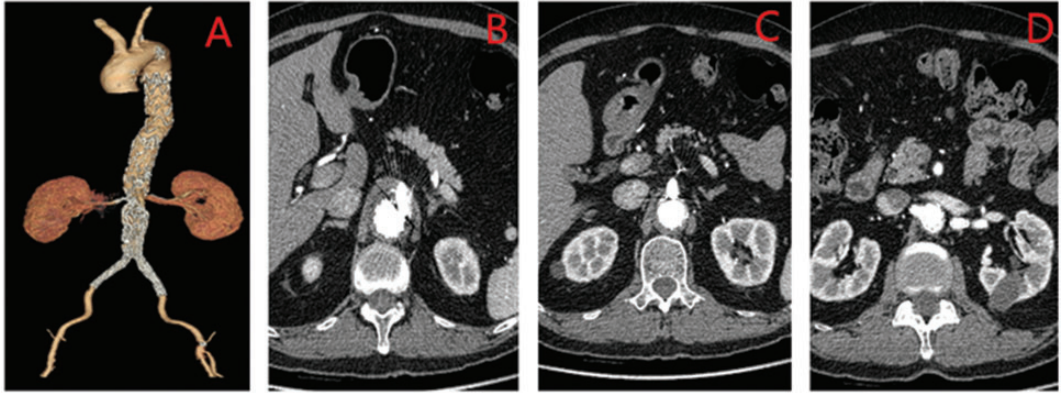


Figure 6. Postoperative computed tomographic angiography images at 3 months after the final surgical stage in a 66-year-old male with a thoracoabdominal aortic aneurysm (Crawford type III): (A) three-dimensional image of the aorta and iliac artery; (B–D) no endoleaks were observed at the celiac trunk, superior mesenteric artery, and renal artery levels, respectively. The colour version of this figure is available at: <http://imr.sagepub.com>.

used to postpone fenestration of the celiac axis and allow additional time for collateral circulation, which might have prevented postoperative paraplegia. Studies involving a greater number of cases with longer-term follow-up are warranted to confirm the generalizability and relevance of the favourable short-term results obtained with the surgeon-improved fenestrated stent graft used in this present case.

Thoracoabdominal aneurysm describes an aneurysm involving both the thoracic and abdominal aorta, as well as their visceral branches: the CA, SMA and RAs. The most common is a Crawford type III TAAA with lesions at the distal area of the aorta (below the T6 section) and the entire abdominal aorta,² as was the case in the patient described in the present report. Although vascular surgeons have been treating TAAA for many years, preservation of all visceral branches of the abdominal aorta remains a challenge. There are currently three main methods for TAAA treatment, namely traditional open surgery, hybrid surgery and endovascular repair. Endovascular repair has lower perioperative mortality than traditional open surgery

because it can avoid injury to organs around the aorta, massive bleeding and blood transfusion, infection and other complications.³ However, reconstruction of the blood supply from the abdominal aortic visceral branches increases the difficulty of endovascular repair. At present, reconstructive methods for the visceral branches include parallel, fenestrated, sandwich, and branched stent graft technologies. The parallel stent graft method is technically convenient and preserves the blood supply via the branched stent graft released in parallel with the aortic stent graft; however, the gutter² between the two stent grafts leads to complications such as endoleak and branch stent occlusion.^{2,4} The sandwich technique is an effective method for treatment but type III endoleaks have always been an issue and it is harder to operate than fenestration or parallel stent graft.⁵ Fenestrated stent graft technology is accurate and it is a viable alternative for patients without healthy proximal landing zones.⁶ However, it requires preoperative measurements to ensure precise matching between branchial and aortic covered stent grafts and it is technically much more challenging than

parallel stent grafting. According to a review,⁷ parallel stent graft technology appears to be suitable for patients at high risk for open repair or contained rupture aneurysms, while fenestrated stent graft technology is more appropriate for more than two aortic branches with a lower risk of rupture. Compared with f-EVAR, branched stent graft technology replaces fenestration with branched stent graft, which more efficiently extends the landing zone and decreases the endoleak rate; however, it needs more space to unfold, which renders it suitable for larger aneurysms. At present, there are no custom-made fenestrated stent grafts or branched stent grafts available in mainland China, therefore a physician-modified stent graft was used in the current case.

Although f-EVAR has many advantages over other methods, it has important limitations such as postoperative blockage of branching vessels.⁸ A previous report demonstrated that even with the custom design of currently approved fenestrated technology, shuttering of the SMA occurred in one-half of patients, with no clinical events noted.⁸ A study in patients with pararenal aortic aneurysms documented a 2.5% incidence of early postoperative mesenteric ischaemia, with 5.1% of patients undergoing reinterventions related to signs or symptoms of mesenteric ischaemia (3.8% early and 1.3% late).⁹ Therefore, it is very important to ensure the accuracy of preoperative measurements of each branching vessel and of the selected stent graft because they greatly affect the success of the stent release and the long-term blood supply.

A complication that requires attention is postoperative paraplegia that can be fatal,¹⁰ and whose occurrence is predominantly influenced by blocking the vasa vasorum of the spinal cord. The spinal cord is fed mainly by the anterior and posterior spinal arteries, which originate from the two vertebral arteries; and the radicular

artery, which originates from spinal branches of the vertebral arteries and spinal branches of ascending cervical arteries, deep cervical arteries, intercostal arteries, lumbar arteries and sacral arteries. The cervical junction originates from the radicular and ascending cervical arteries; the thoracic junction from the intercostal arteries; the lumbar section from lumbar arteries; and the sacrococcygeal segment from the lateral iliac artery. There is a basilic artery located in the fourth thoracic junction called the artery of Adamkiewicz, which originates anywhere from T5 to L3, but usually between T9 and T12 (approximately 75% of cases) and on the left side. The present case illustrates how a diffuse TAAA may block the artery of Adamkiewicz and the lumbar arteries leading to poor perfusion of the relative segments of the spinal cord. Collateral circulation is also considered essential to the blood supply of the spinal cord. In animal studies, research has shown that blocking the middle sacral artery and LSA can damage spinal cord function.^{11,12} In the present case, the 8 × 25 mm ViabahnTM self-expanding covered stent was placed in the bilateral common iliac artery, which could block the middle sacral artery, impacting blood supply and function of the spinal cord. In theory, the best way to reduce the incidence of postoperative paraplegia is to best preserve blood supply. In this current case, the surgeons preferred to perform the procedure in three stages postponing fenestration of the CA to provide additional time for collateral circulation to the spinal cord as a possible means to prevent postoperative paraplegia. However, aneurismal haemodynamic changes may lead to high aneurismal cavity pressure or increased rupture rate. Therefore, more research and improvements are warranted. Perioperative haemodynamic changes may also underlie paraplegia.¹³ To this end, reducing peripheral arterial blood pressure

to ease stent graft release may decrease perfusion to the spinal cord arteries and lead to paraplegia. Increased procedural accuracy can lessen procedural time and minimize risk of postoperative paraplegia.

Declaration of conflicting interests

The authors declare that there are no conflicts of interest.

Funding

This research received no specific grant from any funding agency in the public, commercial, or not-for-profit sectors.

References

- Oderich GS. Technique of adding a diameter-reducing wire to the modified TX2 fenestrated stent graft. *Vascular* 2010; 18: 350–355.
- Overeem SP, Boersen JT, Schuurmann RCL, et al. Classification of gutter type in parallel stenting during endovascular aortic aneurysm repair. *J Vasc Surg* 2017; 66: 594–599.
- Nordon IM, Hinchliffe RJ, Holt PJ, et al. Modern treatment of juxtarenal abdominal aortic aneurysms with fenestrated endografting and open repair – a systematic review. *Eur J Vasc Endovasc Surg* 2009; 38: 35–41.
- de Beaufort HWL, Cellitti E, de Ruiter QMB, et al. Midterm outcomes and evolution of gutter area after endovascular aneurysm repair with the chimney graft procedure. *J Vasc Surg* 2018; 67: 104–112.
- Schwierz E, Kolvenbach RR, Yoshida R, et al. Experience with the sandwich technique in endovascular thoracoabdominal aortic aneurysm repair. *J Vasc Surg* 2014; 59: 1562–1569.
- Zhu J, Zhao L, Dai X, et al. Fenestrated thoracic endovascular aortic repair using physician modified stent grafts for acute type B aortic dissection with unfavourable landing zone. *Eur J Vasc Endovasc Surg* 2018; 55: 170–176.
- Donas KP, Eisenack M, Panuccio G, et al. The role of open and endovascular treatment with fenestrated and chimney endografts for patients with juxtarenal aortic aneurysms. *J Vasc Surg* 2012; 56: 285–290.
- Ullery BW, Lee GK and Lee JT. Shuttering of the superior mesenteric artery during fenestrated endovascular aneurysm repair. *J Vasc Surg* 2014; 60: 900–907.
- Banno H, Cochennec F, Marzelle J, et al. Comparison of fenestrated endovascular aneurysm repair and chimney graft techniques for pararenal aortic aneurysm. *J Vasc Surg* 2014; 60: 31–39.
- Messe SR, Bavaria JE, Mullen M, et al. Neurologic outcomes from high risk descending thoracic and thoracoabdominal aortic operations in the era of endovascular repair. *Neurocrit Care* 2008; 9: 344–351.
- Strauch JT, Spielvogel D, Lauten A, et al. Importance of extrasegmental vessels for spinal cord blood supply in a chronic porcine model. *Eur J Cardiothorac Surg* 2003; 24: 817–824.
- Meylaerts SA, De Haan P, Kalkman CJ, et al. Prevention of paraplegia in pigs by selective segmental artery perfusion during aortic cross-clamping. *J Vasc Surg* 2000; 32: 160–170.
- Azizzadeh A, Huynh TT, Miller CC, et al. Postoperative risk factors for delayed neurologic deficit after thoracic and thoracoabdominal aortic aneurysm repair: a case-control study. *J Vasc Surg* 2003; 37: 750–754.