



## Vaginal calculus in adult woman: A case report

Ida Bagus Gde Tirta Yoga Yatindra<sup>a</sup>, Kadek Budi Santosa<sup>b,\*</sup>, Ida Bagus Tatwa Yatindra<sup>c</sup>

<sup>a</sup> Internship Doctor at Tabanan Hospital, Denpasar, Indonesia

<sup>b</sup> Department of Urology, Medical Faculty of Udayana University, Sanglah Hospital, Denpasar, Indonesia

<sup>c</sup> Department of Surgery Tabanan Hospital, Denpasar, Indonesia

### ARTICLE INFO

#### Keywords:

Vaginal calculus  
Urethrovaginal fistula  
Secondary vaginal obstruction

### ABSTRACT

Vaginal calculus in adult woman is an extremely rare condition. The diagnosis and management can be challenging due to rare cases. We present a case of vaginal calculus in adult woman secondary to urethrovaginal fistula due to previous pelvic trauma. The patient barely has no complaint until one day she is experiencing infertility. Stone extraction, vaginoplasty and urethroplasty with Martius flap were performed with satisfactory results.

### 1. Introduction

The diagnosis of vaginal calculus in women is challenging. The clinical appearance can be varied and silent, as in our case, the patient presented with complaints of infertility. Vaginal calculus is classified into primary or secondary calculus. Primary vaginal calculi are believed to originate from the stasis of urine in the vagina with or without vaginal outlet obstruction, whereas secondary vaginal calculi result from crystallization of urinary constituents around a foreign body in the vagina.<sup>1</sup> Following trauma, the rare appearance of urethrovaginal fistula in females mainly occurs in the proximal part of the urethra or bladder neck.<sup>2</sup> Vaginal outlet obstruction is infrequently associated with primary vaginal stones, which form due to the chronic pooling of urine in the vagina. This report describes a case of giant primary vaginal calculus resulting from a urethrovaginal fistula with partial vaginal outlet obstruction secondary to pelvic trauma in an adult woman.

### 2. Case presentation

A 30-year-old female presented with a chief complaint of infertility after marriage. She suffered from urine leakage from the vagina for 25 years. She also experiences irregular menstruation and dysmenorrhea since she was 13 years old. These complaints were not bothersome so the patient did not seek treatment for years. She had a history of a traffic accident causing bladder rupture and got surgery when she was five years old. Inspeculo examination and urethroscopy found partial vaginal obstruction distal to the calculus and urethrovaginal fistula 1,5 cm in diameter, 2 cm from external meatus of the urethra (Fig. 1). CT-

Scan demonstrated two calculus sizes 3,6 × 5,5 × 5,8 cm attached to the base of the posterior bladder and anterior of the rectum wall (Fig. 2).

For the surgery, an incision was performed through fibrotic tissue at the obstruction site on the posterior vaginal wall to remove the vaginal stone. It showed an expanded superior segment of the vagina, which had two solid and slick calculi (Fig. 3). After removing the stones, a posterior submucosal vaginal flap is made to expand the vaginal lumen to a normal level. The urethrovaginal fistula was repaired using Martius flap tissue interposition. Both vaginoplasty and urethrovaginal fistula were closed using 4.0 absorbable sutures. The urethral catheter was removed two weeks after the operation. The patient was symptom-free at six month of follow-up examination.

### 3. Discussion

Urethral or vaginal trauma is uncommon, but it can be causing serious injury in females. These injuries are usually associated with pelvic fractures and vaginal tears. Primary repair is not always associated with an optimal outcome and can result in subsequent urethrovaginal fistula, vaginal obstruction, and vaginal calculi.<sup>3</sup>

Our case was classified as primary vaginal calculus caused by urethrovaginal fistula and vaginal obstruction due to pelvic trauma and surgery. Urethrovaginal fistula and vaginal outlet obstruction can facilitate stasis of urine in the vagina, leading to the formation of vaginal calculus and obstruct menstrual blood flow, which manifests dysmenorrhea. Another possible mechanism, the turbulence of urine flow in the urethra, can cause primary urethral calculus to migrate to the vagina and grow.

\* Corresponding author.

E-mail address: [busanbsa@gmail.com](mailto:busanbsa@gmail.com) (K.B. Santosa).

<https://doi.org/10.1016/j.eucr.2022.102013>

Received 28 December 2021; Received in revised form 19 January 2022; Accepted 23 January 2022

Available online 31 January 2022

2214-4420/© 2022 The Authors.

Published by Elsevier Inc.

This is an open access article under the CC BY-NC-ND license

(<http://creativecommons.org/licenses/by-nc-nd/4.0/>).

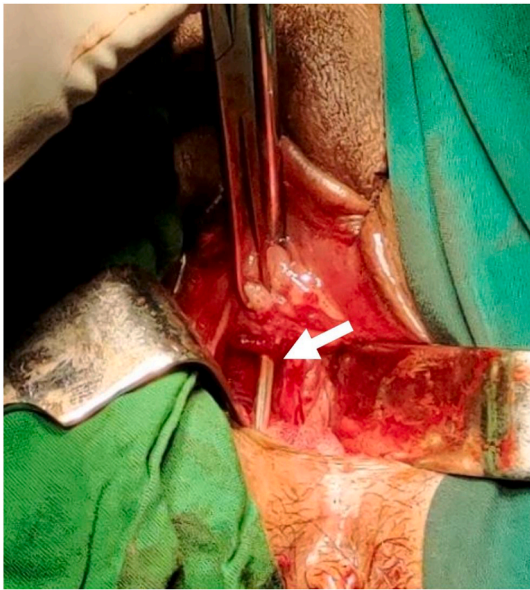


Fig. 1. Urethrovaginal fistula (white arrow).

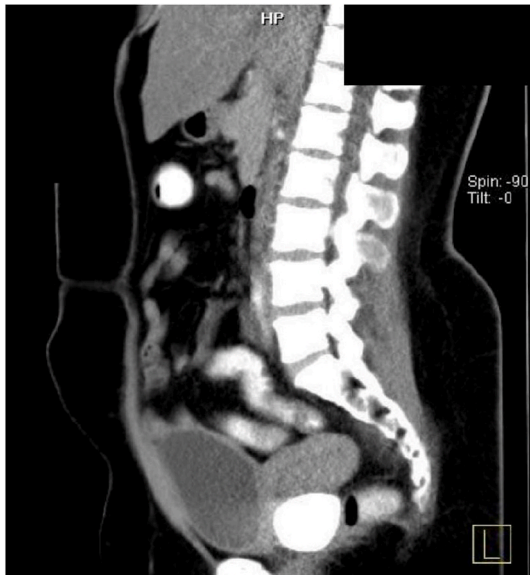


Fig. 2. A non-contrast Ct scan demonstrated calculus sizes  $3,6 \times 5,5 \times 5,8$  cm attached to the base of the posterior bladder and anterior of the rectum wall.

Infection with urease-producing bacteria, such as *Proteus mirabilis*, *Klebsiella* sp., or *E Coli*, can change the normally acidic pH of the vagina to alkaline, predisposing the precipitation of triple phosphate (struvite) calculi. Vaginal obstruction will also cause sexual quality problems and infertility in an adult woman.

Several cases of vaginal calculi have been previously studied but none have reported a case in a married adult woman complaining of infertility.<sup>1,3,4</sup> Our case shows that this disease can be less disturbing and silent for many years. Social, psychological, and knowledge factors may

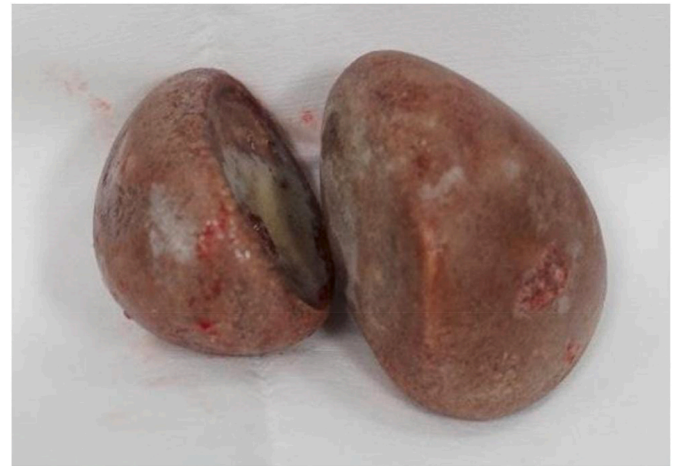

Fig. 3. Vaginal calculi.

also influence the decision to seek treatment.

In this case, the transvaginal approach can be made to remove giant vaginal stones. This approach will benefit less post-operative pain, short hospital stays and allows for vaginoplasty, urethral repair, and subsequent flap interposition in one step compared to the transabdominal approach. In cases of vaginal calculi in children, the transabdominal approach will be more feasible to remove the stones due to a small and narrow vagina. We used interposition Martius flap as an additional layer during urethrovaginal repair due to a large fistula and tenous closure with poor tissue quality. Although there is no high-level evidence that such flaps improve outcomes, but some authors found that the Martius flap gives a high success rate in complex urethrovaginal fistulas.<sup>5</sup>

The formation of primary vaginal calculi is slow and remains undetected when it does not cause any symptoms in the patient. Vaginal calculus should be included in the differential diagnosis when calculus is found in the pelvis on plain radiographs, especially in women with infertility and dysmenorrhea. A careful pelvic examination, CT scan dan cystoscopy can help to find the presence of a urethrovaginal fistula.

#### 4. Conclusion

This case demonstrates that vaginal calculus can occur as a late complication of pelvic trauma. Transvaginal approach stone removal with subsequent vaginoplasty and urethrovaginal fistula repair may restore the patient's quality of life.

#### References

1. Plaire JC, Snodgrass WT, Grady RW, Mitchell ME. Vaginal calculus secondary to partial vaginal outlet obstruction in pediatric patients. *J Urol.* 2000;164:132–133.
2. Mauermann J, Gonzalez R, Franc-Guimond J, Filipas D. The anterior sagittal transrectal approach for traumatic urethrovaginal fistula closure. *J Urol.* 2004;171:1650–1651.
3. Holland AJA, Cohen RC, McKertich KMF, Cass DT. Urethral trauma in children. *Pediatr Surg Int.* 2001;17:58–61.
4. Chen S, Ge R, Zhu L, et al. Giant primary vaginal calculus secondary to vesicovaginal fistula with partial vaginal outlet obstruction in a 12-year-old girl. *Urology.* 2011;78(4):908–910.
5. Patil U, Waterhouse K, Laungani G. Management of 18 diY- cult vesicovaginal and urethrovaginal Wstulas with modiWed Ingel- man-Sundberg and Martius operations. *J Urol.* 1980;123:653–656.