

# Mortality following snake bite envenomation by *Bitis arietans* in an HIV positive child

## A case report

Gregory B. Firth (MBBCh, FC Orth (SA), MMed (Orth) (Rand))<sup>a,\*</sup>, Matthew Street (MBBCh, FC Orth (SA))<sup>a</sup>, Yammesh Ramguthy (MBChB, FC Orth (SA))<sup>a</sup>, Linda Doedens (MBBCh, FCP Ped (SA))<sup>b</sup>

### Abstract

Snake bites occur commonly in the rural areas of South Africa. Hospitals where snake bites are uncommon should always have protocols on standby in the event of such cases presenting. This is the first reported case documenting the effect of human immunodeficiency virus (HIV) on snake bite in South African children.

A case report and review of relevant information about the case was undertaken.

We present a case of a 1-year-old child referred from a peripheral hospital following a snake bite to the left upper limb with a compartment syndrome and features of cytotoxic envenomation. The patient presented late with a wide area of necrotic skin on the arm requiring extensive debridement. The underlying muscle was not necrotic. Polyvalent antivenom (South African Institute of Medical Research Polyvalent Snakebite Antiserum) administration was delayed by 4 days after the snake bite. The patient was also diagnosed with HIV and a persistent thrombocytopenia possibly due to both HIV infection and the snake bite venom. Lower respiratory tract infections with subsequent overwhelming sepsis ultimately resulted in the child's death.

The case highlights the challenge of treating a snake bite in a young child with HIV and the detrimental outcome of delayed treatment. A protocol is essential in the management of snake bites in all hospitals.

Level IV, Case report.

This case highlights the interaction of snake bite envenomation and HIV infection on thrombocytopenia.

**Abbreviations:** AIDS = acquired immune deficiency syndrome, HIV = human immunodeficiency virus, PICU = pediatric intensive care unit, WHO = World Health Organization.

**Keywords:** compartment syndrome, HIV and thrombocytopenia, pediatric, snake bite

## 1. Introduction

The global burden of snake bites is often underestimated. Swaroop and Grab<sup>[1]</sup> were the first to definitively highlight this burden in 1954. Snake bite was added to the World Health Organization (WHO) neglected list of tropical diseases in 2009. An estimated 5.5 million people are bitten by snakes per year resulting in 400,000 amputations and between 20,000 and 125,000 deaths annually.<sup>[2]</sup> A relatively recent report

highlighted that one of the highest burdens exist in sub-Saharan Africa. The incidence of snake bite envenomation in central sub-Saharan Africa was 3.33/100,000 population with a mortality rate of 0.53/100,000 population. These figures were considerably lower compared with countries neighboring South Africa.<sup>[3]</sup> Snake bites occur relatively commonly in rural areas of South Africa. Patients presenting with cytotoxic envenomation are usually associated with Puff Adder bites. Algorithms for the management of these patients should be available in every rural hospital. These areas should have access to antivenom and protocols to guide the management of these cases. Hospitals where snake bites are uncommon should also have protocols on standby in the event of such cases presenting.<sup>[4]</sup>

The burden of human immunodeficiency virus (HIV) in developing countries is substantial. According to WHO statistics from 2011, there are over 5.6 million people living with HIV in South Africa and over 16 million acquired immune deficiency syndrome (AIDS) orphans living in sub-Saharan Africa.<sup>[5]</sup> The effect of HIV on snake bites in South African children has not been described in the literature. HIV has been associated with multiorgan dysfunction but never directly associated with snake bites.

The case discussed below is that of a 1-year-old child from a poor community, 300 km West of Johannesburg. The burden of mortality for snake bite victims has been shown to occur in poor communities.<sup>[6]</sup> This case highlights the association between snakebite, HIV, thrombocytopenia, and mortality.

Editor: Akhilanand Chaurasia.

The authors have no funding and conflicts of interest to disclose.

<sup>a</sup> Department of Orthopedic Surgery, Chris Hani Baragwanath Academic Hospital, University of the Witwatersrand, Johannesburg, <sup>b</sup> Department of Intensive Care and Pediatric Department, Chris Hani Baragwanath Academic Hospital, University of the Witwatersrand, Johannesburg, South Africa.

\* Correspondence: Gregory B. Firth, Department of Orthopedic Surgery, Chris Hani Baragwanath Academic Hospital, University of the Witwatersrand, Chris Hani Rd, Soweto, Johannesburg, South Africa (email: greg.firth@gmail.com).

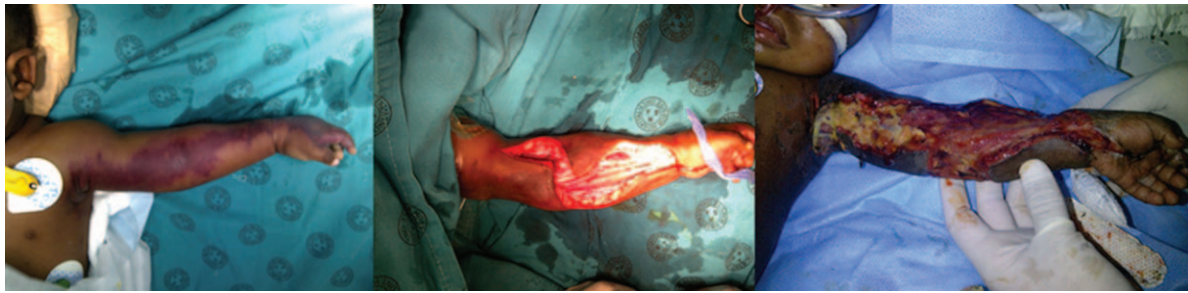
Copyright © 2016 the Author(s). Published by Wolters Kluwer Health, Inc. All rights reserved.

This is an open access article distributed under the Creative Commons Attribution-NoDerivatives License 4.0, which allows for redistribution, commercial and non-commercial, as long as it is passed along unchanged and in whole, with credit to the author.

Medicine (2016) 95:27(e4001)

Received: 13 March 2016 / Received in final form: 2 May 2016 / Accepted: 1 June 2016

<http://dx.doi.org/10.1097/MD.0000000000004001>



**Figure 1.** Left: Initial presentation with swelling and demarcation of superficial tissue necrosis extending from the left hand up to the axilla. Middle: Left arm after emergency fasciotomy. Right: Preoperative situation before the 3rd debridement. Maggots were found in the axillary region. Despite extensive slough that had to be removed, the muscles were still viable.

## 2. Case presentation

A 1-year-old child was referred to our tertiary center from a peripheral hospital. He presented 2 days after the snake bite with severe left upper limb swelling extending from the hand up into the axilla and involving the shoulder joint. Clinically the swelling was accompanied by a compartment syndrome. Features of cytotoxic envenomation with a wide area of necrotic skin on the volar aspect of the arm and forearm required extensive debridement postinitial emergency fasciotomy (Fig. 1). Polyvalent antivenom (South African Institute of Medical Research Polyvalent Snakebite Antiserum) administration was delayed and once obtained was given 4 days after the snake bite. This antivenom is made from the venom of 10 different species including Adders, Mambas, and Cobras. During admission to the pediatric intensive care unit (PICU), the patient was newly diagnosed with HIV. A persistent thrombocytopenia occurred, caused by either the HIV infection or the snake's venom (cytotoxic envenomation presentation in keeping with *Bitis arietans* [Puff Adder] envenomation). Repeated lower respiratory tract infections and overwhelming sepsis ultimately resulted in the child's death. The time interval between antivenom administration and death was 8 days.

Written informed consent was obtained from the parents.

## 3. Discussion

There is substantial morbidity and mortality related to admission of an HIV positive child to a PICU. The management of these children in the PICU has been well described. Argent showed that these children are more commonly affected by severe respiratory tract infections as in the case described above.<sup>[7]</sup> Before the advent of antiretroviral medication, the mortality rate was 100% in children with AIDS and 20% in cases of severe pneumonia.<sup>[8,9]</sup> The patient in this case report was not started on antiretroviral medication.

The association of HIV in antiretroviral naive children with thrombocytopenia is well described.<sup>[10–13]</sup> HIV may in fact cause a pancytopenia due to either bone marrow hypoplasia or myelofibrosis. The diagnosis of thrombocytopenia is usually incidental but significant bleeding can occur. The cause of the thrombocytopenia is twofold—peripheral destruction as well as decreased production of infected megakaryocytes. The degree of thrombocytopenia does not correlate with the patient's immune status. Symptomatic HIV associated thrombocytopenia occurs most commonly in undiagnosed children with HIV under 2 years of age.<sup>[11]</sup> Initiation of antiretroviral therapy has been shown to be effective in treating HIV-related thrombocytopenia but the

response is variable. HIV-related thrombocytopenia was found to be a poor prognostic factor with no specific correlation to the patient's immune status.<sup>[12]</sup>

This case shows similar findings to presentations from a study done in Eshowe, South Africa<sup>[14,15]</sup>—the most common symptom was painful progressive swelling (282/333). The occurrence of compartment syndrome was extremely rare (4/282). Although this patient had a fasciotomy of both his arm and forearm, the tissues were not found to be typical of a compartment syndrome, putting the diagnosis of compartment syndrome in to question. The skin and subcutaneous tissues of the arm and forearm in fact became necrotic and subsequently required extensive debridement. Children in this series were also at greatest risk of developing bite site complications and severe and gross swelling. This was also found in the case under discussion.

The snake species that bit this child had a combination of hemorrhagic and cytotoxic venom. This was evidenced by massive tissue necrosis of the arm as well as pancytopenia that required transfusion with both packed red cells and platelets. The snake that commonly causes these symptoms of envenomation and is also commonly found in the area in which the patient lived is the African Puff Adder (*B arietans*). Although the species was not positively identified by a specialist, the clinical features were typical of *B arietans*. Also this is the main cytotoxic species found in this area of South Africa, which explains why myotoxic and cytolytic components within the venom contributed to local tissue necrosis. Other digestive hydrolases, secondary effects of inflammation, ischemia from thrombosis and compartment syndrome also contribute to local necrosis.<sup>[14,15]</sup> Currier et al<sup>[16]</sup> showed that the African Puff Adder has a high degree of inter-specimen variability in terms of protein expression, immunogenicity, and activity of snake venom metalloproteinases. This variation may have implications for efficacy of antivenom given to patients and may have future consequences in selecting specimens for antivenom production.<sup>[16]</sup>

The effect of HIV on envenomation has not been discussed before in the literature—it is possible that the combination of the HIV-related immunodeficiency was exacerbated by the envenomation in this patient that led to his demise.

## 4. Conclusion

This case highlights the challenge of treating a cytotoxic snake bite in a young child with HIV and the detrimental outcome of delay in treatment. HIV infection and envenomation were co-contributory in leading to the thrombocytopenia and

overwhelming sepsis in this case. A protocol is essential in the management of snake bites in every hospital. All snake bite victims should be tested for HIV infection.

## References

- [1] Swaroop S, Grab B. Snakebite mortality in the world. *Bull Wld Hlth Org* 1954;10:35–76.
- [2] Williams D, Gutiérrez JM, Harrison R, et al. The Global Snake Bite Initiative: an antidote for snake bite. *Lancet* 2010;375:89–91.
- [3] Kasturitane A, Wickremasinghe AR, de Silva N, et al. The global burden of snakebite: a literature analysis and modelling based on regional estimates of envenoming and deaths. *PLoS Med* 2008;5:e218.
- [4] Blaylock RS. The identification and syndromic management of snakebite in South Africa. *SA Fam Pract* 2005;47:48–53.
- [5] WHO. Global HIV/AIDS response: epidemic update and health sector response towards universal access. Progress report 2011. WHO, UNAIDS, UNICEF 2011. [http://www.who.int/hiv/pub/progress\\_report2011/en/index.html](http://www.who.int/hiv/pub/progress_report2011/en/index.html) (accessed August 21, 2014).
- [6] Harrison RA, Hargreaves A, Wagstaff SC, et al. Snake envenoming: a disease of poverty. *PLoS Negl Trop Dis* 2009;3:e569.
- [7] Argent AC. Managing HIV in the PICU: the experience at the Red Cross War Memorial Children's Hospital in Cape Town. *Indian J Pediatr* 2008;75:615–20.
- [8] Jeena PM, Coovadia HM, Bhagwanjee S. Prospective, controlled study of the outcome of human immunodeficiency virus-1 antibody-positive children admitted to an intensive care unit. *Crit Care Med* 1996;24:963–7.
- [9] Zar HJ, Hanslo D, Tannenbaum E, et al. Aetiology and outcome of pneumonia in human immunodeficiency virus-infected children hospitalized in South Africa. *Acta Paediatr* 2001;90:119–25.
- [10] Meira DG, Lorand-Metze I, Toro DC, et al. Bone marrow features in children with HIV infection and peripheral blood cytopenias. *J Trop Pediatr* 2005;51:114–9.
- [11] Wainwright RD, Poyiadjis S, Naidu G, et al. Psychosocial aspects of immune thrombocytopenia and secondary human immunodeficiency virus-related pediatric immune thrombocytopenia in the Republic of South Africa. *Pediatr Blood Cancer* 2006;47:692–3.
- [12] Kumar P, Gupta RA, Chandra J, et al. Clinical course of children with HIV associated thrombocytopenia. *Indian J Pediatr* 2012;79:1201–5.
- [13] Shah I, Murthy A. Bone marrow abnormalities in HIV infected children, report of three cases and review of the literature. *J Res Med Sci* 2014;19:181–3.
- [14] Blaylock R. Epidemiology of snakebite in Eshowe, KwaZulu-Natal, South Africa. *Toxicon* 2004;43:159–66.
- [15] Warrell DA. Snakebite symposium. *Lancet* 2010;375:77–88.
- [16] Currier RB, Harrison RA, Rowley PD, et al. Intra-specific variation in venom of the African Puff Adder (*Bitis arietans*): differential expression and activity of snake venom metalloproteinases (SVMPs). *Toxicon* 2010;55:864–73.