

# Role of whole-brain computed tomography perfusion in head injury patients to predict outcome

T S Bindu, Sameer Vyas, Niranjana Khandelwal, Vikas Bhatia, Sivashanmugam Dhandapani<sup>1</sup>, Ajay Kumar, Chirag K Ahuja

Departments of Radiodiagnosis and Imaging and <sup>1</sup>Neurosurgery, Postgraduate Institute of Medical Education and Research, Chandigarh, India

**Correspondence:** Dr. Sameer Vyas, Department of Radiodiagnosis and Imaging, Postgraduate Institute of Medical Education and Research, Chandigarh, India. E-mail: sameer574@yahoo.co.in

## Abstract

**Purpose:** To evaluate utility, pattern, and extent of perfusion abnormalities in traumatic brain injury by using whole-brain computed tomography perfusion (CTP) and to assess co-relation of CTP data clinically with Glasgow outcome score (GOS). **Materials and Methods:** Prospective analytic evaluation of the traumatic head injury patients who were immediately taken up for CTP was done. Patient's demographic, clinical, and radiological findings were tabulated and analyzed. GOS was measured by a neurosurgeon after 3 months of trauma who was blinded to CTP results. **Results:** Of the 78 patients included in this study, 28 patients were found to have GOS 5, 19 of them had GOS 4, 27 of them had GOS 3, and 4 of them had a GOS 2. Higher mean cerebral blood flow (CBF) and cerebral blood volume (CBV) values were observed in those who had a better GOS, i.e., 4 or 5, whereas those in the GOS range  $\leq 3$  had lower mean CBF and CBV values. **Conclusion:** Statistically significant positive correlation was found between cerebral perfusion parameters with that of GOS. CBF of frontal area shows better correlation with GOS. CBF was the most important predictor among all the perfusion parameters.

**Key words:** CT; CT perfusion; Glasgow outcome score; head trauma

## Introduction

Traumatic brain injury (TBI) is a leading cause of mortality and morbidity worldwide.<sup>[1]</sup> It is the leading cause of disability in young patients globally, especially those <40 years of age.<sup>[2]</sup> Data for 2005 in India had shown that road traffic injuries resulted in economic losses of up to 3% of the gross domestic product as estimated for the year 2005.<sup>[3]</sup> A vast majority of TBI is classified as mild, with most showing adequate and quick recovery. However, some may show persistent disabling symptoms that interrupt with their normal daily

routine activities.<sup>[4]</sup> Severe brain injury has been found to be the most important predictor of unfavorable outcome in patients even with associated multiple extra-cranial injuries.<sup>[3]</sup> Therapeutic decisions are based on providing prognostic information; however, accurate clinical assessment is frequently lacking in these cases.<sup>[1]</sup>

TBI not only causes structural damage in the form of contusions or diffuse axonal injury but also causes secondary alterations in hemodynamic parameters leading to ischemia and cellular dysfunction. Multiple mechanisms

This is an open access article distributed under the terms of the Creative Commons Attribution-NonCommercial-ShareAlike 3.0 License, which allows others to remix, tweak, and build upon the work non-commercially, as long as the author is credited and the new creations are licensed under the identical terms.

**For reprints contact:** reprints@medknow.com

**Cite this article as:** Bindu TS, Vyas S, Khandelwal N, Bhatia V, Dhandapani S, Kumar A, *et al.* Role of whole-brain computed tomography perfusion in head injury patients to predict outcome. Indian J Radiol Imaging 2017;27:268-73.

### Access this article online

#### Quick Response Code:



**Website:**  
www.ijri.org

**DOI:**  
10.4103/ijri.IJRI\_454\_16

are thought to be involved in pathophysiology of ischemia following TBI, which include direct vessel autoregulatory failure leading to hypotension, paucity of nitric oxide or cholinergic neurotransmitters, and vasoconstriction.<sup>[4]</sup> Noncontrast computed tomography (NCCT) is the initial diagnostic modality in trauma but around 20% of patients with normal scans on admission later show suboptimal outcome. NCCT can underestimate the lesion size and can also provide little information on secondary ischemic injury.<sup>[4,5]</sup> Various techniques, such as single photon emission computed tomography (SPECT), positron emission tomography (PET), and Xenon perfusion, have been used over the years that provide information regarding injury and prognosis in TBI patients.<sup>[3]</sup>

Computed tomography perfusion (CTP) is an imaging technique that uses dynamics of injected contrast material and allows rapid qualitative and quantitative evaluation of cerebral perfusion by generating cerebral blood flow (CBF), cerebral blood volume (CBV), and mean transit time (MTT) maps providing clinically important information in patients with stroke, subarachnoid hemorrhage (SAH), and head injury.<sup>[5,6]</sup> CT scan is universally available, rapid, and provides quantitative data that designate CTP the preferred modality of choice in emergency settings.<sup>[5,7-10]</sup> Magnetic resonance (MR) perfusion gives only semi-quantitative information and is not frequently used in trauma or SAH patients.<sup>[11-13]</sup> Other techniques, such as SPECT, PET, and Xenon perfusion CT, have come up in the past for evaluating extent of injury and providing information regarding injury and prognosis. CTP can provide equivalent information to these modalities with advantages of easy availability, short acquisition time, and lower radiation dose.<sup>[9,10]</sup> To the best of author's knowledge, this is the first study performed comparing CTP parameters with clinical outcome in Indian subset population.

## Materials and Methods

This prospective study was conducted over a period of 1 year with enrollment of 92 patients with TBI. Inclusion criteria included presence of closed TBI, age group 18–60 years, and Glasgow coma score (GCS) range 4–15 (mild head injury: GCS >14; moderate head injury: GCS = 9–13; severe head injury GCS <8). Exclusion criteria included presentation after 24 hours of injury, major hemorrhagic contusion, presence of SAH, or extradural hematoma (EDH) requiring surgical intervention, renal dysfunction, pregnancy, hypotension, hyperglycemia, known allergy to iodine, or serious systemic injury. Patients with poor GCS (<4) and significant brain contusion injury were excluded from this study as these patients undergo surgical interventions and hospital admissions.

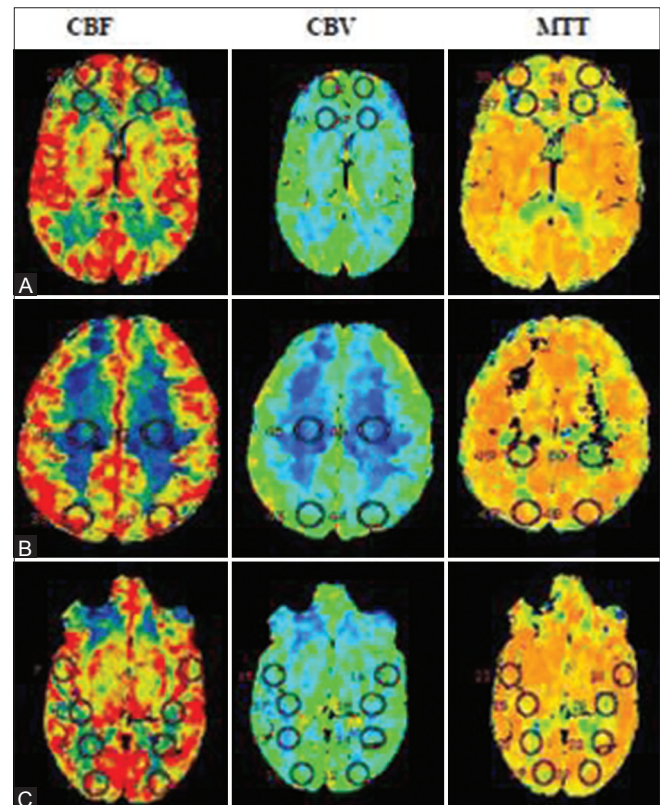
### Computed tomography technique

Whole-brain CTP was performed following NCCT with LightSpeed VCT, GE Health Systems, 64-slice multiple

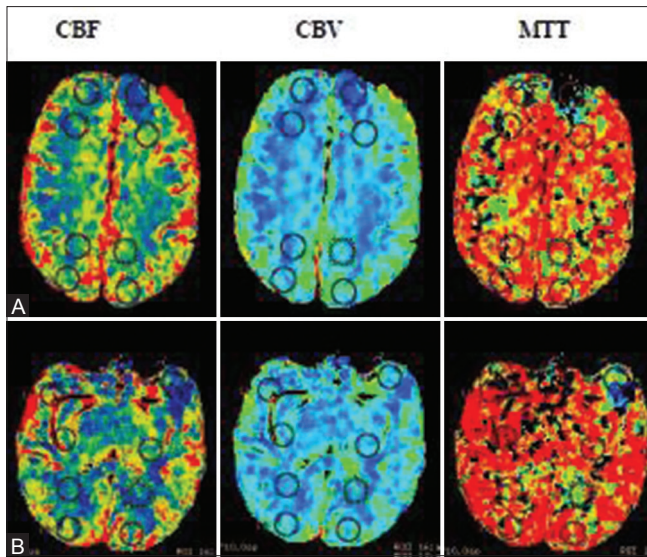
detector CT (MDCT) scanner after intravenous nonionic iodinated contrast. The acquisition parameters for CTP were 80 kV and 200 mAs. CTP acquisition was initiated 7 s after injecting 50 ml of nonionic low osmolar contrast agent (300 mg/100 ml of iodine) at a rate of 5 ml/s in the antecubital vein through power injector followed by saline flush. A single slab of 8 cm covering the whole brain was used for perfusion information. After data acquisition, images were transferred to a postprocessing workstation where Terarecon software was used to create parametric maps for clinical interpretation, which includes CBV, CBF, and MTT. Perfusion parameters obtained were analyzed by drawing 15 mm × 15 mm region of interest (ROI) in frontal and parietal lobes at the level of centrum semi-ovale and in temporal and occipital lobes at the level of thalamus with comparative ROI on opposite side [Figures 1-3]. Results were compared with Glasgow outcome score (GOS)<sup>[2,3]</sup> [Figure 4]. GOS was assessed by a neurosurgeon after 3 months of trauma who was blinded to CTP results at the outpatient clinic or over the phone when patient could not be contacted in person.

### Statistical analysis

Continuous data were given as mean ± SD and range. Normality of quantitative data was checked by measures of Kolmogorov–Smirnov tests of normality. For comparison of two groups GOS ≤3 and >3 independent *t*-test was used.



**Figure 1 (A-C):** (A-C) Patient had a GCS 14 at the time of admission and normal cerebral perfusion parameters as depicted in cerebral perfusion maps. On follow up patient had GOS 5



**Figure 2 (A and B):** (A and B) This patient had a Glasgow coma scale of 9 at admission and on three months of follow up Glasgow outcome score turned out to be 3. Note frontal reduced cerebral blood flow and volume with corresponding raise in mean transit time. Quantitative analysis revealed reduced perfusion parameters on left frontal lobe [CBF-15 ml/100g/min; CBV 1.8 ml/100g; MTT-7.1 s]

All statistical tests were two-sided and performed at a significance level of  $\alpha = 0.05$ . Analyses were conducted using Statistical Package for the Social Sciences (SPSS) for Windows (version 17.0; SPSS Inc., Chicago, IL, USA).

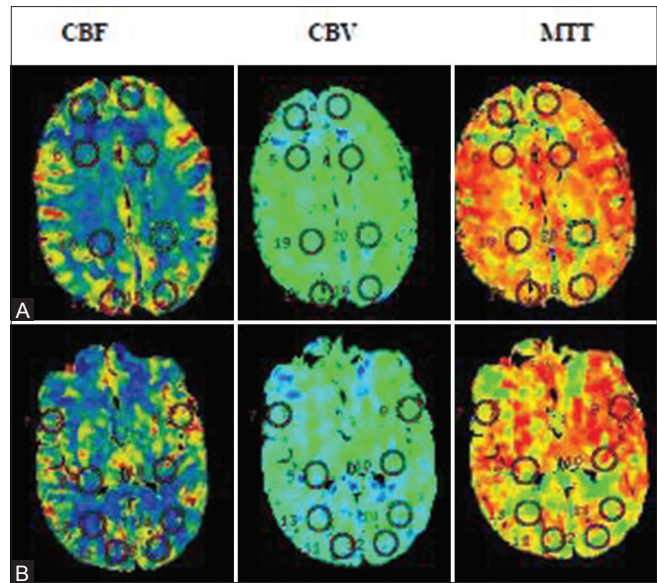
## Results

Of the 92 patients who fulfilled the inclusion criteria and enrolled for the study, data of only 78 patients were evaluated as the data of 11 patients could not be analyzed due to motion artifacts and data concerning outcome was missing in 3 patients due to loss of follow-up. Patient characteristics are displayed in Table 1. The mean time following trauma and CTP scanning was 3.9 hours. CTP scanning involved no complication or adverse reactions to the contrast material. On follow-up at 3 months, 28 patients had a GOS of 5, 19 had GOS of 4, 27 had GOS of 3, and 4 had a GOS of 2.

In the study patients with higher mean CBF and CBV values had a better GOS, i.e., 4 or 5 on follow-up, whereas those with lower mean CBF and CBV values had poor GOS at follow-up. We also found that CBF of frontal area showed better correlation with GOS, and CBF was the most important predictor among all the perfusion parameters.

## Discussion

TBI causes various structural as well as hemodynamic changes which may not be visible using conventional NCCT.<sup>[4,5]</sup> Mild TBI has been found to be associated with physical and psychosocial dysfunction leading to significant disability with persistent headaches and memory



**Figure 3 (A and B):** (A and B) This patient had a Glasgow coma scale of 8 at admission and on three months of follow up Glasgow outcome score turned out to be 3. Note bifrontal reduced cerebral blood flow and volume with corresponding raise in mean transit time. Quantitative analysis revealed reduced perfusion parameters on left frontal lobe [CBF-right 15 ml/100g/min, left- 21 ml/100mg/ml]; CBV right- 1.2 ml/100g, left 1.8ml/100g; MTT-right -7.1 s, left 6.5s]

**Table 1: Patient characteristics and demographic details**

Total number of participants	78
No. of females	11
No. of males	67
Mean age, years (male)	37 (SD±21.4)
Mean age, years (female)	43 (SD±14.9)
Road traffic accidents	68
Fall from height	5
Assault	4
Miscellaneous	1
Mean duration of data acquisition from admission to hospital	3.9 h (SD±2.2)
Mild head injury (GCS ≥14)	42
Moderate head injury (GCS 9-13)	23
Severe head injury (GCS <8)	13
Presence of mild hemorrhagic contusion, minimal SAH, EDH	12

deficits.<sup>[14]</sup> Metting *et al.*<sup>[14]</sup> performed a study evaluating the CTP results in varied severity of head injury. They found relation between cerebral perfusion and severity of injury (GCS). They found that those with a GCS score <15 had significantly reduced CBF and CBV in the frontal and occipital gray matter, while those with a score of 15 showed a relatively greater CBF in the frontal white matter. They used two thick slabs of 14.4 mm coverage each at the level of basal ganglia, thalami, and third ventricle. Their technical limitation of limited coverage and positioning of slabs could have missed perfusion changes in the other regions of the brain. This study was technically superior to them as we had had whole brain coverage reflecting changes in all the regions of the brain.



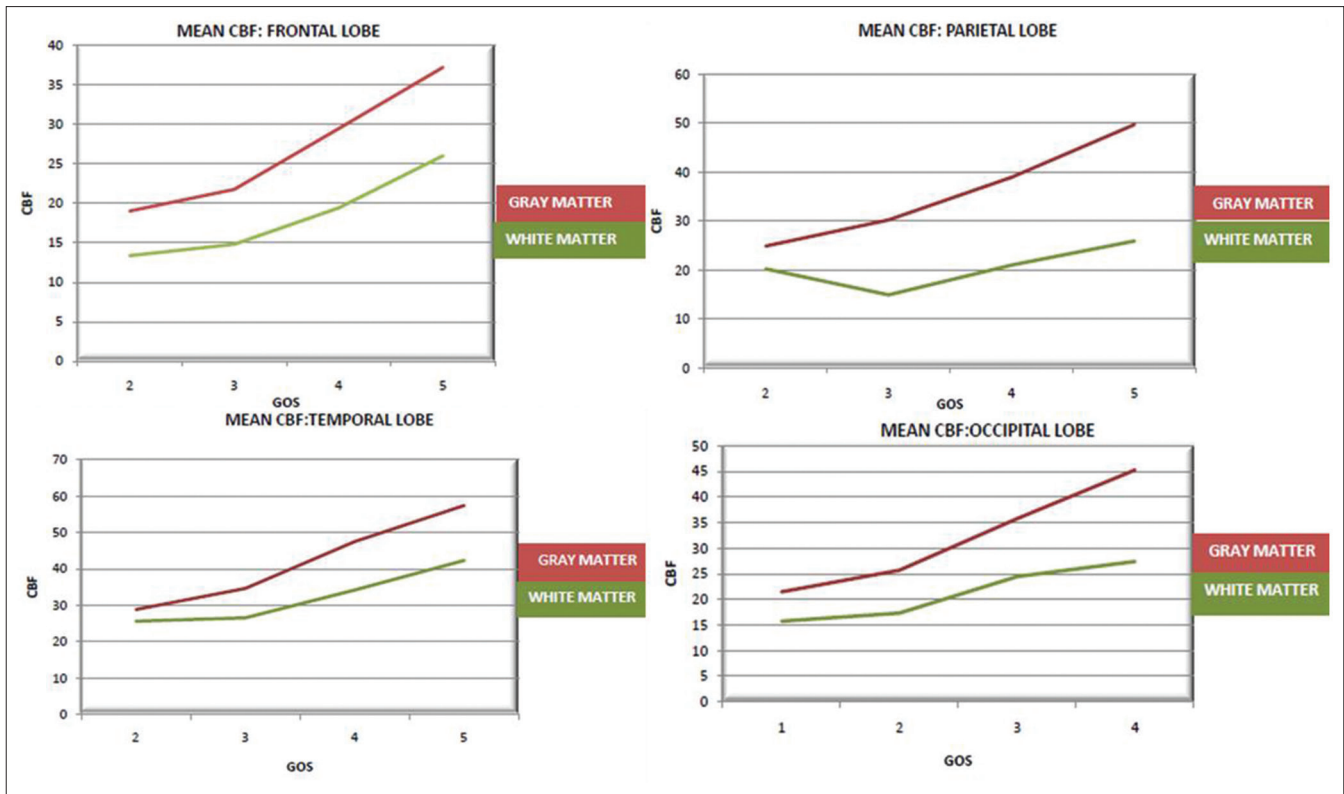


Figure 4A: Image showing relationship of mean cerebral blood flow (CBF) versus Glasgow outcome scale (GOS)

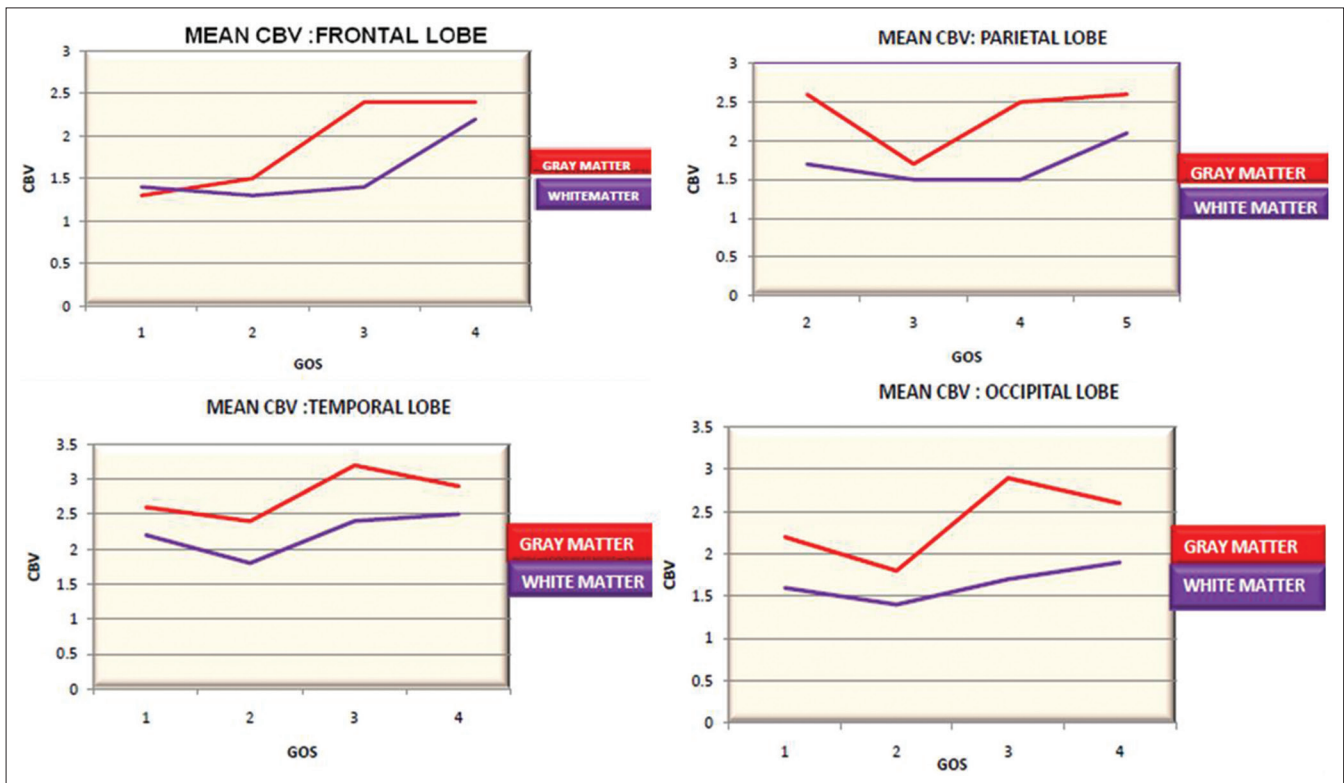
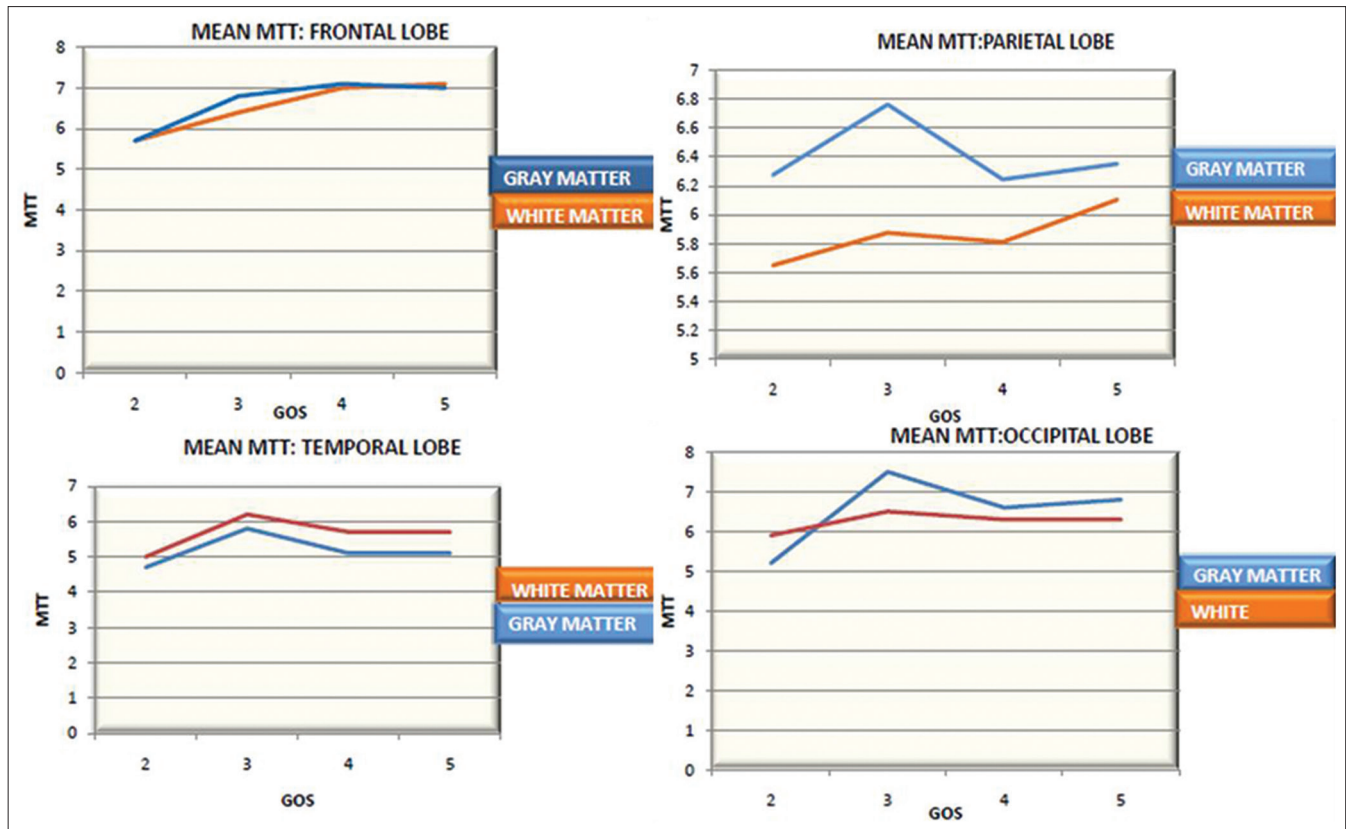


Figure 4B: Image showing relationship of mean cerebral blood volume (CBV) versus Glasgow outcome scale (GOS)

Wintermark *et al.*<sup>[5]</sup> performed their CTP study in head injury patients. They demonstrated that reduced CBF and

CBV on admission were also predictive of outcome in severe head injury patients. Their study included 130 patients with



**Figure 4C:** Image showing relationship of mean transit time (MTT) versus Glasgow outcome scale (GOS)

severe trauma having a GCS of 8 or less. Clinical variables, NCCT, and CTP scans were compared to GOS at 3 months. They found that patients with a GOS score of 3–5 had high rCBF values, whereas patients with a GOS score of 2 or less showed low rCBF values. They concluded that CTP provides important prognostic information in head trauma patients. Their study had limited coverage with placement of only two 10 mm slabs.

Shankar and Lumet<sup>[15]</sup> observed that CBF and CBV in the perilesional brain parenchyma are altered. They found that there was increase in the size of hematoma in the follow-up CT scan in areas showing perilesional ischemia. This observation is also helpful in prognostication of head injury patients. However, in this study we excluded patients with significant contusions and thus similar observations were not demonstrated. Previous studies have been done in Indian subset of patients with head trauma for prognostication. Dhandapani *et al.*<sup>[16]</sup> evaluated patients with mild to moderate head injury with GCS score of 9–14 who underwent MR spectroscopy (MRS) and/or SPECT and compared them with various clinical factors and neurological outcome at 3 months. They found that SPECT has higher sensitivity and prognostic value than single voxel proton MRS in head injury patients. They also found that severe hypoperfusion in SPECT was associated with unfavorable outcome, independent of other confounding factors. An association with advanced age and lower

socioeconomic status resulting in poor outcome have also been mentioned in previous studies.<sup>[17,18]</sup>

This is the first study in India comparing CTP with GOS in head injury patients. We carried CTP with whole brain coverage to evaluate prognostic information of the traumatic head injury. The results had shown correlation of GOS at 3 months from the scan and cerebral perfusion parameters. This finding is in agreement with previous studies, which evaluated the role of CTP on the prognosis of TBI.<sup>[4,5]</sup> The use of these modalities leads to optimal treatment decisions and therapeutic interventions in those predicted to have a good outcome. Though CTP is associated with increased radiation dose, most of the patients undergoing CTP are adult patients needing emergent intervention. In this setting, we believe that the benefits of perfusion CT examination are likely to outweigh the risk from radiation. Risk of radiation with CTP is comparable to single-phase Xenon perfusion CT, which comes with much higher radiation and lower spatial resolution. Radiation is also lesser than PET and SPECT. Protocols wherein CT angiography and CTP are simultaneously acquired with the use of MDCT scanners can be an answer to the radiation dose issues, which is possible with the use of MDCT scanners. Based on this data and previous results, it is observed that CTP provides important information regarding prognosis of the patients with TBI. We suggest the use of CTP as a problem-solving

tool in cases of clinico-radiological discordance or when there is patient deterioration in spite of adequate treatment.

### Limitations

Standardization of the ROI measurement site is required for better reproducibility and for comparison of different studies. We used ROI as described with the rationale of covering and obtaining perfusion information from all the lobes. Inhomogeneity among the patient population was another drawback. Standardized protocols are needed for uniform database and reproducibility. Follow-up was done for 3 months in the study, which could be a limitation, as a longer follow-up may have shown alteration of GOS. Most of the patients in this study had mild head injury. Therefore, there is a need for a study with larger sample size, with better stratification of age groups and equal distribution of sex ratio. Motion of the patient, especially trauma victims could make most of the studies noninterpretable as seen in some of the cases. Also, there is less scope for sedation of these patients as it may hinder in assessment of clinical status for further management.

A small number of patients had shown presence of minimal EDH, SAH, or small contusion, which may interfere with final GOS. However, these were considered to be therapeutically insignificant at the time of initial evaluation by the neurosurgeon. Future studies directly comparing CTP with PET and SPECT can help further validate the use of this widely available modality in prognostication.

### Conclusion

CTP is an established modality to evaluate tissue perfusion and should be used as a problem-solving tool in select cases where there is clinico-radiological discordance or patient deterioration in spite of adequate treatment. The ready availability, less time consumption, and provision for quantitative data make CTP the preferred modality of choice. CTP can provide information regarding extent of injury, underlying physiological changes, and prognosis for recovery of comparable accuracy at the rate of low radiation dose as compared with SPECT, PET, and Xenon perfusion CT.

### Financial support and sponsorship

Nil.

### Conflicts of interest

There are no conflicts of interest.

### References

1. MRC CRASH Trial Collaborators, Perel P, Arango M, Clayton T, Edwards P, Komolafe E, Pocock S, *et al.* Predicting outcome after traumatic brain injury: Practical prognostic models based on large cohort of international patients. *BMJ*. 2008; 336:425-9.
2. Bruns JJr, Hauser WA. The epidemiology of traumatic brain injury: A review. *Epilepsia* 2003;44:2-10.
3. Gururaj G. Road traffic deaths, injuries and disabilities in India: Current scenario. *Natl Med J India* 2008;21:14-20.
4. Metting Z, Rodiger LA, Stewart RE, Oudkerk M, De Keyser J, van der Naalt J. Perfusion computed tomography in the acute phase of mild head injury: Regional dysfunction and prognostic value. *Ann Neurol* 2009;66:809-16.
5. Wintermark M, van Melle G, Schnyder P, Revelly JP, Porchet F, Regli L, *et al.* Admission perfusion CT: Prognostic value in patients with severe head trauma. *Radiology* 2004;232:211-20.
6. Hoeffner GG, Case I, Jain R, Gujar SK, Shah GV, Deveikis JP, *et al.* Cerebral perfusion CT: Technique and clinical application. *Radiology* 2004;231:632-44.
7. Mayer TE, Hamann GF, Baranczyk J, Rosengarten B, Klotz E, Wiesmann M, *et al.* Dynamic CT perfusion imaging of acute stroke. *AJNR Am J Neuroradiol* 2000;144:1-9.
8. Murayama K, Katada K, Nakane M, Toyama H, Anno H, Hayakawa M, *et al.* Whole brain perfusion CT performed with a prototype 256-detector row CT system: Initial experience. *Radiology* 2009;250:202-11.
9. Parsons MW. Perfusion CT: Is it clinically useful? *Int J Stroke* 2008;3:41-50.
10. Salinas CL, Provenzale JM, Wintermark M. Responses to the ten most frequently asked questions about perfusion CT. *AJR Am J Roentgenol* 2011;196:53-60.
11. Garnett MR, Blamire AM, Corkill RG, Rajagopalan B, Young JD, Cadoux-Hudson TA, *et al.* Abnormal cerebral blood volume in regions of contused and normal appearing brain following traumatic brain injury using perfusion magnetic resonance imaging. *J Neurotrauma* 2001;18:585-93.
12. Essig M, Shiroshi MS, Nguyen TB, Saake M, Provenzale JM, Enterline D, *et al.* Perfusion MRI: The five most frequently asked technical questions. *AJR Am J Roentgenol* 2013;200:24-34.
13. Gallagher CN, Hutchinson PJ, Pickard JD. Neuroimaging in trauma. *Curr Opin Neurol* 2007;20:403-9.
14. Bazarian JJ, McClung J, Shah MN, Cheng YT, Flesher W, Kruass J. Mild traumatic brain injury in the United states, 1998-2000. *Brain Inj* 2005;19:85-91.
15. Shankar JJ, Lum C. Whole brain CT perfusion on a 320 -slice CT scanner. *Indian J Radiol Imaging* 2011;21:209-14.
16. Dhandapani S, Sharma A, Sharma K, Das L. Comparative evaluation of MRS and SPECT in prognostication of patients with mild to moderate head injury. *J Clin Neurosci* 2014;21:745-50.
17. Dhandapani SS, Manju D, Mahapatra AK. The economic divide in outcome following severe head injury. *Asian J Neurosurg* 2012;7:17-20.
18. Dhandapani S, Manju D, Sharma B, Mahapatra A. Prognostic significance of age in traumatic brain injury. *J Neurosci Rural Pract* 2012;3:131-5.