



Contents lists available at ScienceDirect

## International Journal of Surgery Case Reports

journal homepage: [www.casereports.com](http://www.casereports.com)

## Isolated primary subcutaneous hydatid in right hypochondrium region: Case report

Samer Makki Mohamed Al-Hakkak

Faculty of Medicine, Department of Surgery, Jabir Ibn Hayyan Medical University, Iraq

## ARTICLE INFO

## Article history:

Received 28 March 2018

Received in revised form 29 May 2018

Accepted 13 June 2018

Available online 30 June 2018

## Keywords:

Subcutaneous

Hydatid cyst

Unusual site

Right hypochondrium

Primary

Isolated

## ABSTRACT

**INTRODUCTION:** Hydatid cyst (HC) disease is a serious health problem in endemic areas, solitary primary subcutaneous hydatid cyst is not frequent and the only symptom is generally a silent growing mass. Total excision remains the mainstay of treatment. The aim of the study was to present a case surgically treated. **CASE PRESENTATION:** 48-year-old female farmer presented with HC of the right hypochondrium who was managed surgically.

**DISCUSSION:** The mechanism of primary subcutaneous localization is unclear. There are two potential mechanisms; (a) direct subcutaneous contamination through an injured skin or (b) subcutaneous colonization of ingested eggs after passing liver and lungs. I believe that subcutaneous colonization of the parasite in the circulation after ingestion is an only reliable mechanism than the other contact theory, because of the cases in literature occur without any direct contamination.

**CONCLUSION:** Primary subcutaneous hydatid cyst must always be considered in the differential diagnosis of silent growing mass in soft tissues or subcutaneous. History and physically associated with ultrasound and magnetic resonance imaging are sufficient to achieve a correct preoperative diagnosis.

© 2018 The Author(s). Published by Elsevier Ltd on behalf of IJS Publishing Group Ltd. This is an open access article under the CC BY-NC-ND license (<http://creativecommons.org/licenses/by-nc-nd/4.0/>).

## 1. Introduction

Hydatid disease is an anthroponosis caused by *Echinococcus* species. The species involved in the disease are *E. granulosus*, *E. multilocularis*, *E. vogeli* and *E. oligarthrus*. *E. granulosus* is the most commonly responsible for cystic formation [1]. Canids are the definitive hosts in which the adult tapeworm lives inside small intestine. The eggs (gravid proglottids), scattered through faeces, are ingested by herbivores (intermediate host) during fodder, and larvae (oncospheres) are released in the small intestine. The specific conformation gives them the ability to penetrate the intestinal wall, reaching the circulatory system and potentially to land in every part of the body, usually localizing in liver (68.8–80%) and lungs (10–22.4%), where the larvae develop into hydatid cyst (metacestode). Humans represent intermediate hosts in parasite life cycle when occasionally ingest eggs. Endemic areas are countries of the temperate zones, where the common intermediate hosts, sheep, goats, and cattle, are raised, such as in North Africa, the Middle East, Central Europe, Australia, and South America [6,7]. Rare localizations are represented by spleen (0.9–8%), skeleton (0.2–3%), kidney (0.4–3.7%), brain (0.4–1%), cardiac muscle (0.02–1.1%), peritoneum (2–5.2%), subcutis (1.6%) [2,3]. The precise percentage of site involvement varies and the precise incidence of unusual loca-

tions is difficult to ascertain because they are only reported as case reports. The hydatid cyst grows slowly over years and causes symptoms usually because of compression of adjacent structures. A high index of suspicion, radiological investigations, and histopathological examination is necessary for establishing the diagnosis of hydatid disease at unusual sites in the body. Primary subcutaneous hydatid disease means that there is not any primary focus of hydatidosis. This is a rare disease and can have difficulties in diagnosis and management, particularly for inexperienced clinicians. Even in the endemic areas, detection of a subcutaneous hydatid cyst results with apprehension for anaphylaxis or local/systemic recurrences.

Isolated subcutaneous hydatid extremely rare. These lesions may remain asymptomatic for a long period. They don't have any specific symptoms and signs are related to size, location or complications of the cyst [4].

The solitary primary subcutaneous localization is extremely rare, and its incidence is unknown [5].

## 2. Case presentation

A 48-year-old farmer woman presented to our hospital with a 4 months history of upper abdominal pain associated with nausea and vomiting. It was associated with dyspeptic symptoms and become worse following ingestion of high-fat meal contents. Clinically, a differential of gallstone disease was considered. Ultrasonography of abdomen revealed a contracted gallbladder with multiple stones with normal wall thickness, so the fact of clinical

E-mail addresses: [sammerhakak1971@yahoo.com](mailto:sammerhakak1971@yahoo.com), [sammerhakak1971@gmail.com](mailto:sammerhakak1971@gmail.com)

<https://doi.org/10.1016/j.ijscr.2018.06.002>

2210–2612/© 2018 The Author(s). Published by Elsevier Ltd on behalf of IJS Publishing Group Ltd. This is an open access article under the CC BY-NC-ND license (<http://creativecommons.org/licenses/by-nc-nd/4.0/>).

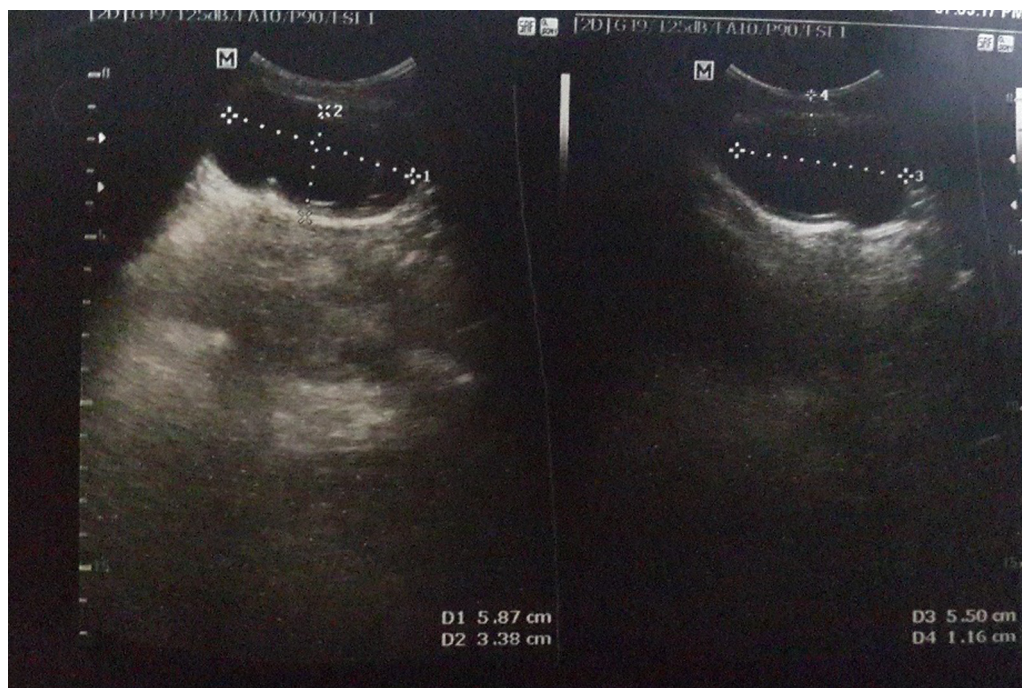


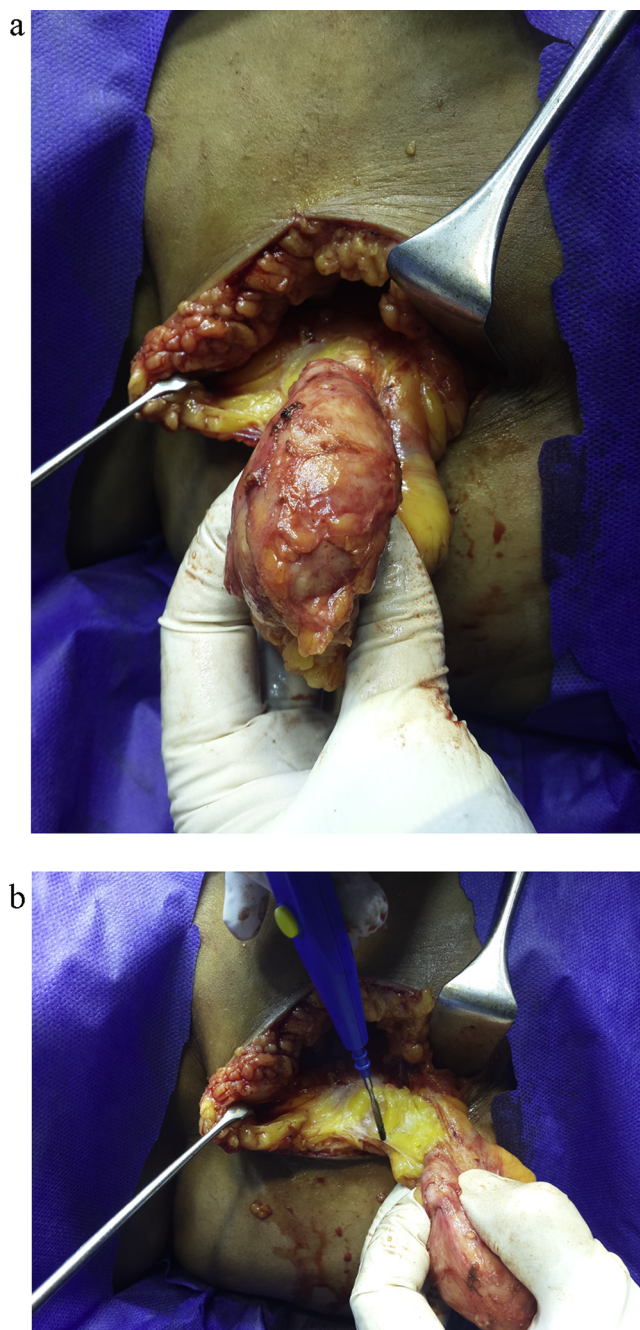
Fig. 1. Ultrasound picture show subcutaneous cystic mass with its dimension.

diagnosis considering finding cholelithiasis, ultrasound also show a subcutaneous cystic mass about  $58 \times 55 \times 38$  mm in size seen about 11 mm from skin within the subcutaneous fatty layer in the right hypochondrium anteriorly as shown in (Fig. 1) and no other abdominal cystic mass was found. During the physical examination, a subcutaneous palpable mass was detected Complete blood count and chest X-ray was normal. The computed tomography showed no abdominal abnormalities. Serological enzyme-linked immune-absorbent assay (ELISA) was negative for the Echinococcal antigens. A complete surgical resection was performed carefully to keep the mass intact and not to cause any other cyst formation (Fig. 2a and b). Histopathological examination of the surgical specimen demonstrated that the mass was a multivesicular hydatid cyst (Fig. 3). The patient was started on albendazole for three months (10 mg/kg/day) four each 1 month take one week rest to avoid side effects of drugs. Uneventful postoperative recovery of the patient was provided. Removed hydatid cyst is showed on (Fig. 4a and b).

### 3. Discussion

It is well known that *Echinococcus granulosus* is transmitted to humans mainly through the gastrointestinal tract and the parasite reaches the liver firstly via the portal vein. After the first filtration from the hepatocytes, some parasites pass through the liver and head to the lungs. After the second filtration of the alveolar system of the lungs, the fugitive parasites can nestle to every organ or tissue except hair follicles, nails or teeth [8]. Isolated, primary hydatid cyst in the subcutaneous location is a very rare condition and the cumulative systematic review of this rare disease can give us some clues about the transmission of *Echinococcus*. In the literature, the occurrence of the subcutaneous hydatid cysts is 2% and most of these subcutaneous localizations are secondary to other organ localizations such as liver or lung [9,10]. In our case, the hydatid cyst was only found in subcutaneous right hypochondrium region without other organ involvement which indicates that the cyst was primary. Hydatid cystic disease has a nonspecific clinical course and symptoms depend on its localization and size. It is usually presented as painless, non-inflammatory mass. Proper his-

tory taking, knowledge about endemics and risk factors and using the variety of diagnostic methods such as US, CT, ELISA tests or hematological tests are important for the diagnosis of cases with subcutaneous findings. The US is a useful tool for determination of localization, size, type, and diagnosis of the cyst. Moreover, CT can be helpful for the other organ involvement and preparation of the surgery by showing the adjacent organs. Although it is less capable of detecting calcifications, MRI can show most of the features of a hydatid cyst [11]. The best treatment choice for primary hydatid cysts is complete surgical resection [12]. In the subcutaneous cyst removal, the resection should be done very carefully without causing any rupture since the subcutaneous cyst location is difficult to determine before the surgery. If the cyst is not available to be removed in an intact form, the content of the cyst should be removed intraoperatively and the empty cyst should be washed with scolicidal agents and then be removed. Drug treatment with albendazole for three months showed beneficial outcomes for preventing the postoperative reoccurrence of hydatid cystic disease [13]. A negative ELISA serology does not rule out cystic echinococcosis as clearly demonstrated in this case. Not only may a patient have an echinococcal cyst with a negative serology, but there may also not be a consistent relationship between the extent of the infection and serological results [14,15]. In some series 30–40% of patients with cystic echinococcosis are antibody negative and this may be due to the ability of *E. granulosus* antigens to inhibit B cell activity and proliferation [16]. Although the sensitivity of serological testing is not clearly dependent on the extent of disease. The mechanism of primary subcutaneous localization is unclear. There are two potential mechanisms; (a) direct subcutaneous contamination through an injured skin or (b) subcutaneous colonization of ingested eggs after passing liver and lungs [17,18]. We believe that subcutaneous colonization of the parasite in the circulation after ingestion is a more reliable mechanism than the direct contact theory. We conducted a case presentation and a literature review of studies published in the medical literature accessed via PubMed, Medline, and the Google Scholar databases, this is the first one in the right hypochondrium, although echinococcosis can occur in any part of the body it was usually secondary to liver and lung which



**Fig. 2.** Complete surgical excision.

was most filtering organs, it reaches the subcutaneous tissue and logged without primary source, still the mechanism unclear.

#### 4. Conclusion

A primary subcutaneous hydatid cyst should be in mind in the differential diagnosis of soft tissue masses, particularly for patients who have lived in regions where a hydatid cyst is endemic. When a subcutaneous cystic mass has detected the diagnosis of hydatid cyst should be considered. The best treatment is the surgical excision of the cysts. The parasite reaches subcutaneous tissue by rout of blood no other proofed rout until now, it was just reported cases about subcutaneous hydatid because of an extremely rare condition, still why it was logged in subcutaneous tissue unknown.

#### Conflict of interest

No conflict of interest.

#### Sources of funding

None.

#### Ethical approval

For my institution there is no specific protocol about my ethical approval of my case report, and according to my institution ethical approval is not required.

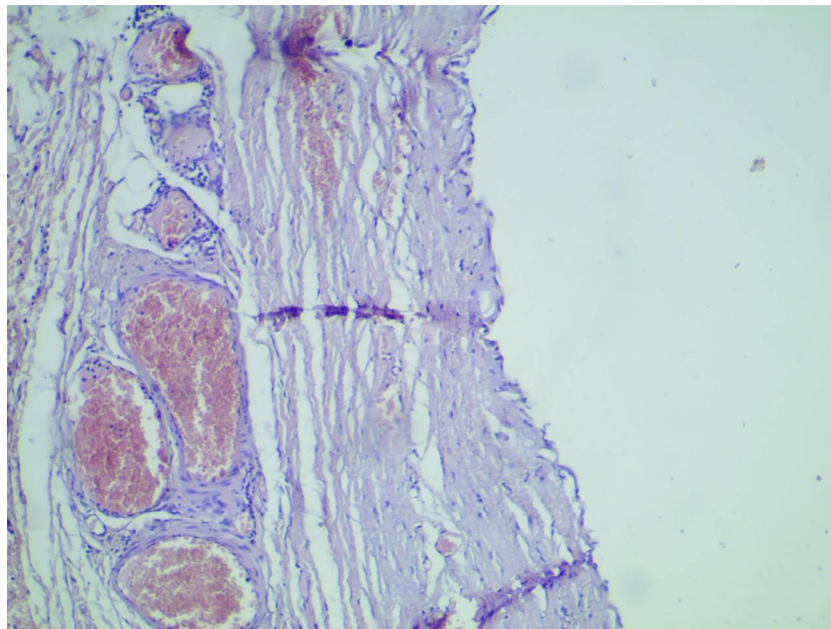


Fig. 3. Histological showing thick fibrous wall and necrotic material.

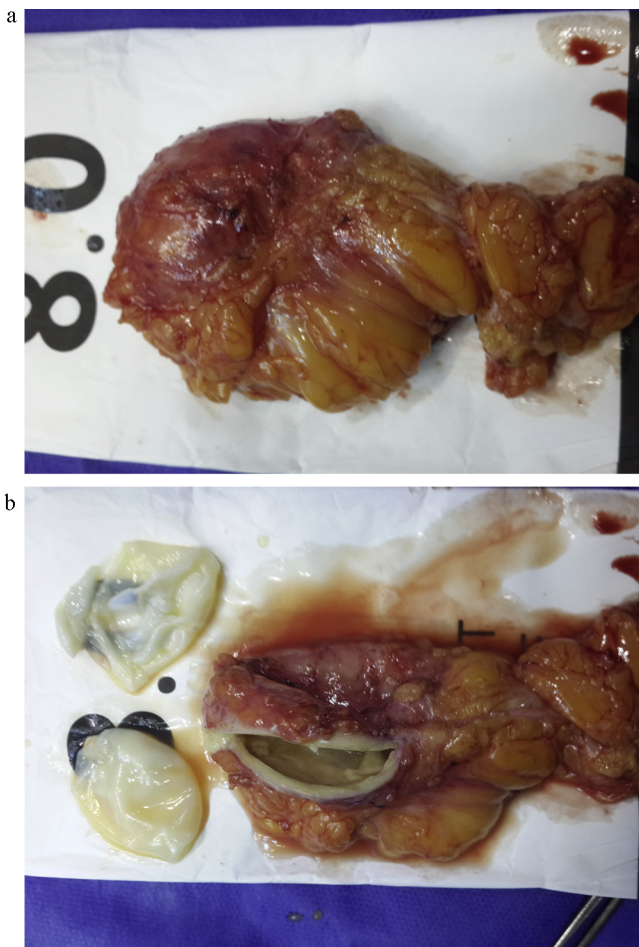


Fig. 4. Removed Hydatid cyst opening content show daughter cysts.

**Consent**

Written informed consent was obtained from the patient for publication of this case report and accompanying images. A copy of the written consent is available for review by the Editor-in-Chief of this journal on request.

**Author contributions**

I am only the contributory author for this my case report.

**Registration of research studies**

Registration ID 3857.

**Guarantor**

Samer Makki Al-Hakkak.

**References**

- [1] G. Salamone, L. Licari, B. Randisi, P. Di Carlo, R. Tutino, N. Falco, G. Augello, C. Raspanti, G. Cocorullo, G. Gulotta, A primary subcutaneous hydatid cyst in the thigh a case report, *Ann. Ital. Chir.* 87 (April (8)) (2016), pii: S2239253X16024324.
- [2] G. Salamone, R. Tutino, J. Atzeni, L. Licari, N. Falco, G. Orlando, G. Gulotta, Liver hydatidosis: reasoned indications of surgical treatment. Comparison between conservative and radical techniques. Retrospective study, *Ann. Ital. Chir.* 85 (2014) 422–430.
- [3] J. Eckert, P. Deplazes, Biological, epidemiological, and clinical aspect of Echinococcosis, a zoonosis of increasing concern, *Clin. Microbiol. Rev.* 17 (1) (2004) 107–135.
- [4] A. Di Cataldo, R. Latino, A. Cocuzza, G. Li Destri, Unexplainable development of a hydatid cyst, *World J. Gastroenterol.* 15 (2009) 3309–3311.
- [5] A. Dirican, B. Unal, C. Kayaalp, V. Kirimlioglu, Subcutaneous hydatid cysts occurring in the palm and the thigh: two case reports, *J. Med. Case Rep.* 13 (273) (2008).
- [6] Z. Orhan, H. Kara, T. Tuzuner, I. Sencan, M. Alper, Primary subcutaneous cyst hydatid disease in proximal thigh: an unusual localisation: a case report, *BMC Musculoskelet. Disord.* 7 (2003) 25.
- [7] A. Dirican, B. Unal, C. Kayaalp, V. Kirimlioglu, Subcutaneous hydatid cysts occurring in the palm and the thigh: two case reports, *J. Med. Case Rep.* 13 (2008) 273.

- [8] Kayaalp Hydatid cyst of the liver, in: L.H. Blumgart, R.J. Belghiti, R.P. DeMatteo, W.C. Chapman, M.W. Büchler, L.E. Hann, M. D'Angleca (Eds.), *Surgery of Liver Biliary Tract and Pancreas*, 4th ed., Saunders Elsevier, Philadelphia, 2007, p. 952e70.
- [9] A. Dirican, B. Unal, C. Kayaalp, V. Kirimlioglu, Subcutaneous hydatid cysts occurring in the palm and the thigh: two case reports, *J. Med. Case Rep.* 2 (2008) 273.
- [10] A. Ousadden, H. Elbouhaddouti, K.H. Ibnmajdoub, K. Mazaz, K. Aittaleb, A solitary primary subcutaneous hydatid cyst in the abdominal wall of a 70-year-old woman: a case report, *J. Med. Case Rep.* 5 (2011) 270.
- [11] Z. Orhan, H. Kara, T. Tuzuner, I. Sencan, M. Alper, Primary subcutaneous cyst hydatid disease in proximal thigh: an unusual localisation: a case report, *BMC Musculoskelet. Disord.* 4 (2003) 25.
- [12] A. Dirican, B. Unal, C. Kayaalp, V. Kirimlioglu, Subcutaneous hydatid cysts occurring in the palm and the thigh: two case reports, *J. Med. Case Rep.* 2 (2008) 273.
- [13] M. Gümüş, Y. Yagmur, H. Gümüş, M. Kapan, A. Onder, A. Büyük, Primary hydatid disease of diaphragm with subcutaneous extension, *J. Infect. Dev. Ctries.* 5 (August (8)) (2011) 599–602.
- [14] L. Force, J.M. Torres, A. Carrillo, J. Busca, Evaluation of eight serological tests in the diagnosis of human echinococcosis and follow-up, *Clin. Infect. Dis.* 15 (September (3)) (1992) 473–480.
- [15] M.P. Zarzosa, A. Orduña Domingo, P. Gutiérrez, P. Alonso, M. Cuervo, A. Prado, Evaluation of six serological tests in diagnosis and postoperative control of pulmonary hydatid disease patients, *Diagn. Microbiol. Infect. Dis.* 35 (December (4)) (1999) 255–262.
- [16] W. Zhang, D.P. McManus, Recent advances in the immunology and diagnosis of echinococcosis, *FEMS Immunol. Med. Microbiol.* 47 (June (1)) (2006) 24–41.
- [17] Cuneyt Kayaalp, Abuzer Dirican, Cemalettin Aydin, *Int. J. Surg.* 9 (2) (2011) 117–121.
- [18] R.A. Agha, A.J. Fowler, A. Saetta, I. Barai, S. Rajmohan, D.P. Orgill, for the SCARE Group, The SCARE Statement: consensus-based surgical case report guidelines, *Int. J. Surg.* 34 (2016) 180–186.

#### Open Access

This article is published Open Access at [sciencedirect.com](https://www.sciencedirect.com). It is distributed under the [IJSCR Supplemental terms and conditions](#), which permits unrestricted non commercial use, distribution, and reproduction in any medium, provided the original authors and source are credited.