

Predominantly cystic central mucoepidermoid carcinoma developing from a previously diagnosed dentigerous cyst: case report and review of the literature

Banavar Ravi Spoorthi, Roopa S. Rao, Premalatha Bidadi Rajashekaraiah, Shankargouda Patil, Sowmya Samudrala Venktesaiah, Preethi Purushothama
M.S. Ramaiah Dental College, Bangalore, India

Abstract

Primary intraosseous mucoepidermoid carcinoma of the jawbones is an extremely rare malignant salivary gland tumour constituting 2-4.3% of all the reported mucoepidermoid carcinomas. We report a case of intraosseous mucoepidermoid carcinoma of the mandible in an 80-year old female patient developing from a previously diagnosed dentigerous cyst. An excisional biopsy was performed and the histopathological features confirmed low grade-cystic intraosseous mucoepidermoid carcinoma. The origin of central mucoepidermoid carcinoma could be suggested to be from the epithelial lining of previously diagnosed dentigerous cyst. Thus, emphasizing the need for careful examination of the entire excision specimen to rule out such neoplastic transformation of epithelial lining of odontogenic cyst and provide appropriate and effective treatment.

Introduction

Mucoepidermoid carcinoma comprises 5-10% of all salivary gland tumors. Aberrant salivary gland neoplasms arising within the jaws as primary central bony lesions are extremely rare, of which most common is central mucoepidermoid carcinoma.¹

Lepp in 1939 first reported an intraosseous mucoepidermoid carcinoma of the mandible in a 66-year old woman.¹ In 1991, the World Health Organization classification recommended that the term *mucoepidermoid tumour* be changed to *mucoepidermoid carcinoma*. Waldron and Mustoe suggested that intraosseous mucoepidermoid carcinoma be included in primary intraosseous carcinoma of jaw as type 4 lesion.² Several case reports are recorded in the literature about neoplastic transformation of epithelial lining of odontogenic cyst.¹⁻⁴

We report a case of central mucoepidermoid carcinoma arising from a previously diagnosed case of dentigerous cyst. Thus, we can suggest the origin of central mucoepidermoid carcinoma to arise from the malignant transformation of epithelial lining of odontogenic cyst.

Case Report

An 80-year old female patient came with a chief complaint of pain and swelling over the left lower half of the face since 3 months. Patient was unaware of the swelling previously. Patient gave a history of impacted mandibular 3rd molar, which was extracted 2 years ago. On extraoral examination, an ill-defined swelling was noted on the lower left side of the face, irregular in shape, measuring about 2×3 cm in size (Figure 1A). Intraorally, on palpation left ramus of mandible was obliterated and on orthopantomograph, a multilocular radiolucent lesion in relation to left angle ramus of mandible was noted. A straw colored fluid was aspirated from the cystic space. A provisional diagnosis of odontogenic keratocyst/ameloblastoma/dentigerous cyst was considered.

Incisional biopsy was performed. On histopathological examination, a non-keratinizing cystic lining epithelium with mucous cell metaplasia and a connective tissue wall was noted. (Figure 2A) Correlating patient's history with the clinical, radiographical and histopathological findings, a diagnosis of long standing case of dentigerous cyst with mucous metaplasia was given.

A surgical excision of the entire lesion was performed and histopathological examination of the excisional specimen revealed numerous microcysts and macrocysts, islands of epidermoid cells and mucous cells, minimal to absence of pleomorphism (Figure 2B) and cholesterol clefts with multinucleated foreign body type giant cells. Foci of the section showed a single layer of non-keratinizing cystic lining epithelium with mucous cell metaplasia, which stained positive with mucicarmine staining (Figure 2C). A final diagnosis of low-grade central mucoepidermoid carcinoma was rendered.

Discussion

Central mucoepidermoid carcinomas (MECs) are extremely rare tumors. According to Pires *et al.*, less than 200 cases have been published.³ In 1939, Lepp described the first case of central MEC (CMEC) in mandible of 66-year old woman. According to Eversole *et al.*, 50% of central MEC are associated with dental cysts and/or impacted teeth.⁴ The incidence of central MEC is estimated to be around

Correspondence: Banavar Ravi Spoorthi, M.S. Ramaiah Dental College, Bangalore, India. E-mail: drspoorthi@gmail.com

Key words: central mucoepidermoid carcinoma, dentigerous cyst, mucous metaplasia, intraosseous mucoepidermoid carcinomas, cholesterol cleft.

Contributions: BRS, histopathological evaluation, manuscript preparation; RSR, PBR, SP, SSV, histopathological evaluation; PP, manuscript preparation.

Received for publication: 6 December 2012.

Revision received: 6 February 2013.

Accepted for publication: 12 March 2013.

This work is licensed under a Creative Commons Attribution NonCommercial 3.0 License (CC BY-NC 3.0).

©Copyright B.R. Spoorthi *et al.*, 2013

Licensee PAGEPress, Italy

Clinics and Practice 2013; 3:e19

doi:10.4081/cp.2013.e19

2-4.3% of all MEC.³ The age of occurrence ranges 1-78 years (peak 4th-5th decade). Females are twice more commonly affected than males and mandible is twice more commonly affected than maxilla.

According to Classification of Primary Intraosseous Carcinoma given by Waldron and Mustoe central MEC comes under type 4 of primary intraosseous carcinoma² (Table 1).

The origin of central mucoepidermoid carcinoma is thought to be from: i) entrapment of retromolar mucous glands within the mandible, which subsequently undergo neoplastic transformation; ii) developmentally included embryonic remnants of the sub maxillary gland within the mandible; iii) neoplastic transformation of the mucous secreting cells commonly found in the pluripotential epithelial lining of dentigerous cysts associated with impacted third molars; iv) neoplastic transformation and invasion from the lining epithelium of the maxillary sinus.¹

According to Bouquot *et al.*, intra-osseous minor salivary gland tissue is seen in 0.3% of bone specimens.⁵ According to Ellis *et al.*, ectopic salivary gland tissue is rare even than the occurrence of central mucoepidermoid carcinoma.⁶ Therefore, the origin from intraosseous minor salivary gland is questionable. According to Eversole *et al.*, approximately 50% of the mandibular tumors were associated with dental cysts and/or impacted teeth.⁴ Brookstone and Huvos, also reported a rate of 32% of central MEC to be associated with odontogenic cysts.⁷ Central MEC and squamous cell carcinoma account for 1-2% of jaw tumors associated with an impacted 3rd molar.⁸

Since the initial report was based on incisional biopsy, it is difficult to elucidate whether the lesion was primarily a dentigerous cyst or a cystic part of mucoepidermoid carcinoma, which was biopsied. In the literature, there are case reports of MEC in predominantly cystic pattern with many mucous cells in lining⁹⁻¹² and there are also reports of dentigerous cyst transforming into MEC.^{1,9}

Thus, taking patient's history into consideration and the fact that the patient had an impacted 3rd molar extracted 2 years back on the same side as the CMEC, we could propose that follicular tissue/part of cyst left around the impacted tooth lead to further development of CMEC. This may be due to the pluripotentiality of the follicular tissue around the 3rd molar or the dentigerous cyst lining epithelium. This may suggest towards the origin of MEC from neoplastic transformation of epithelial lining of odontogenic cyst.

Most common symptoms of CMEC are swelling and pain with trismus, paresthesia and tooth mobility, previous history of impacted tooth or cyst. On Radiograph, it is characterized by well-circumscribed unilocular/multilocular radiolucency with well-defined borders.

The most commonly accepted criteria for diagnosis of central MEC proposed by Alexander *et al.*,¹³ which was modified by Browand and Waldron¹⁴ is as follows:¹ i) presence of intact cortical plates; ii) radiographic evidence of bony destruction; iii) exclusion of another primary tumor; iv) histopathological confirmation; v) detectable intracellular mucin.

Brookstone and Huvos gave the staging system for central mucoepidermoid carcinoma depending up to the condition of the overlying bone (Table 2).⁷

In our case, there was an intact cortical plate with some degree of expansion. Therefore, it can be considered as stage II disease.

The mainstay of treatment of central MEC is surgery. On conservative treatment like enucleation and debridement, the recurrence rate was seen to be around 40% and upon radical treatment such as segmental resection with/without associated adjuvant therapy, a recurrence rate of 4% was noted.¹¹ Metastases are reported to occur in 9% of cases of central MEC. Metastasize mainly to regional lymph node, ipsilateral clavicle, lungs and brains. Maxillary central MEC have worse prognosis due to possibility of local extensions into vital structures.⁶

Differential diagnosis

A differential diagnosis of ameloblastoma, keratinizing cystic odontogenic tumor (KCOT), primary intraosseous carcinoma and metastatic lesions to the jaw was considered. Differentiating features included presence of follicles, anastomosing cords and strands of odontogenic epithelium with ameloblastoma-

tous change for ameloblastoma, parakeratinized stratified squamous epithelium of uniform thickness with typical epithelial features for KCOT, dysplastic epithelial islands with/without keratin pearl formation in the connective tissue stroma for primary intraosseous carcinoma and presence of pri-

mary tumor elsewhere in the body for metastatic lesions to the jaw.

Mucous cells in epithelial lining

Mucous cells are seen in the epithelial lining of odontogenic cysts. They can be present as scattered cells or as continuous rows of

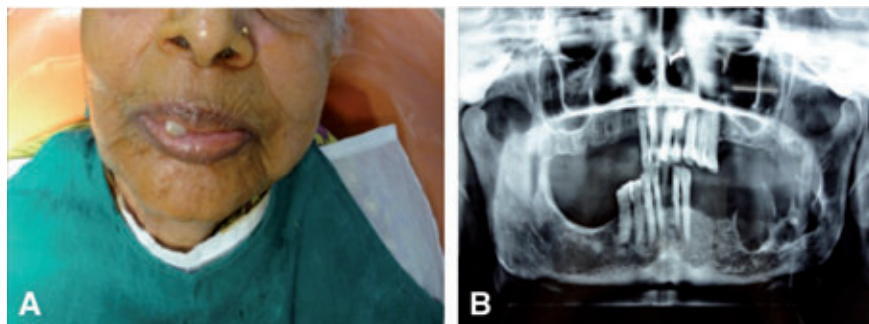


Figure 1. A) A swelling is noted in the left side of the face; B) A multilocular radiolucent lesion in relation to left angle ramus of mandible.

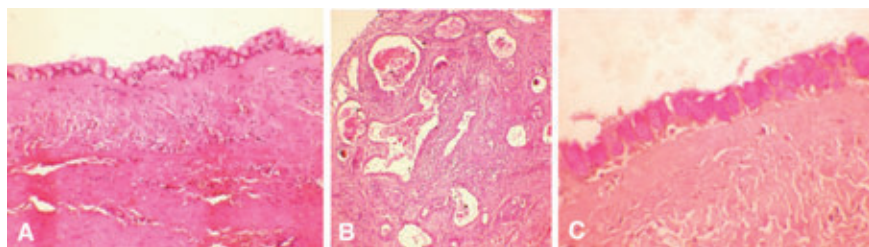


Figure 2. A) Incisional specimen shows, non-keratinizing cystic lining epithelium with mucous cell metaplasia and a connective tissue wall [hematoxylin & eosin (H&E) 10x]; B) Excisional specimen reveals microcysts and macrocysts, islands of epidermoid cells and mucous cells (H&E 20x); C) Foci of the section showed a single layer of non-keratinizing cystic lining epithelium with mucous cell metaplasia which stained positive with mucicarmine staining (Mucicarmine 40x).

Table 1. Classification of Primary Intraosseous Carcinoma.

| | |
|---------|---|
| Type 1 | PIOC ex odontogenic cyst |
| Type 2A | Malignant ameloblastoma |
| Type 2B | Ameloblastic carcinoma arising <i>de novo</i> , ex ameloblastoma or ex odontogenic cyst |
| Type 3 | PIOC arising <i>de novo</i> : i) Keratinising type ii) Non-keratinising type |
| Type 4 | Intraosseous mucoepidermoid carcinoma |

PIOC, Primary Intraosseous Carcinoma.

Table 2. Staging system for central mucoepidermoid carcinoma.

| Stage | Description |
|-------------------|---|
| Stage I disease | Lesions with intact cortical plates with no evidence of bony expansion |
| Stage II disease | Lesion surrounded by intact cortical bone that has undergone some degree of expansion |
| Stage III disease | Any instance of cortical perforation, breakdown of the overlying periosteum or nodal spread |

cells. It is most commonly seen in mandibular than maxillary lesions. Incidence in radicular cyst is 18-39.6% and in dentigerous cyst is 42%. Incidence of ciliated cells along with mucous cells is 11.4%.¹⁵ Presence of mucous and ciliated cells is considered a metaplastic change. Usually around mucous cells, clear cells are seen in chronic long-standing cases. According to Slabbert *et al.*, these clear cells were reported to be stage in the histogenesis of mucous cell metaplasia.¹⁶ According to them, keratinocytes become vacuolated and mucin granules begin to appear and accumulate within the vacuolated cells and mucous cells develop.

Cholesterol clefts

The cyst fluid when examined under light, demonstrates cholesterol crystals, which impart a shimmering appearance to the gold or straw-colored fluid. Unstained smear of cyst fluid under light microscope will show typical rectangular shaped crystals with notched corners. (Figure 3) While stained sections show needle shaped cholesterol cleft surrounded by multinucleated foreign body giant cells. The cholesterol clefts are artefacts in histopathology formed due to the removal of the cholesterol during tissue processing. Cholesterol clefts are usually encountered in lesions such as radicular cysts, dentigerous cyst, keratinizing cystic odontogenic tumor, other inflammatory lesions, salivary gland neoplasms - mucoepidermoid carcinoma and atherosclerotic lesions.

Pathogenesis

According to Thoma, cholesterol clefts accumulate in the tissue as a result of degeneration and disintegration of epithelial cells.¹⁷




Figure 3. Cholesterol crystals showing typical rectangular shaped crystals with notched corner under light microscope.

According to Slabbert *et al.*, circulating plasma lipids are a more likely source for cholesterol clefts.¹⁶ According to Browne, he noted that cholesterol clefts and hemosiderin pigments and postulated that the main source was disintegrated red blood cells.¹⁸ Other sources of cholesterol clefts are degenerated epithelial cells, connective tissue cells, inflammatory cells and plasma lipoproteins. The presence of cholesterol clefts and multinucleated giant cells indicates the long-standing nature of the lesion. The giant cells seen in our case are of reactive foreign body type.

Conclusions

Central mucoepidermoid carcinomas are extremely rare lesions. They are usually low-grade lesions and less aggressive in nature. The clinical significance of malignant tumors arising from odontogenic cysts or *de novo* should never be underestimated. We need to re-emphasize the importance of radical surgery, adjuvant treatment and a careful histopathological evaluation of the entire excised tissue so that such neoplastic transformation may be identified and treated effectively.

References

1. Simon D, Somanathan T, Ramdas K, Pandey M. Central mucoepidermoid carcinoma of mandible - A case report and review of the literature. *World J Surg Oncol* 2003;1:1.
2. Waldron CA, Mustoe TA. Primary intraosseous carcinoma of the mandible with probable origin in an odontogenic cyst. *Oral Surg Oral Med Oral Pathol* 1989; 67:716-24.
3. Pires FR, Paes de Almeida O, Lopes MA, et al. Central mucoepidermoid carcinoma – A report of 4 cases with long term follow up. *Int J Oral Maxillofac Surg* 2003;32:378-82.
4. Eversole LR, Sabes WR, Rovin S. Aggressive growth and neoplastic potential of odontogenic cysts. *Cancer* 1975;35: 270-82.
5. Bouquot JE, Gnepp DR, Dardick I, Hietanen JH. Intraosseous salivary tissue: jawbone examples of choristomas, hamartomas, embryonic rests, and inflammatory entrapment: another histogenetic source

for intraosseous adenocarcinoma. *Oral Surg Oral Med Oral Pathol Oral Radiol Endod* 2000;90:205-17.

6. Ellis GL, Auclair PL, Gnepp DR. Surgical pathology of the salivary glands. Illustrated. University of Michigan: Saunders publication; 1991.
7. Brookstone MS, Huvos AG. Central salivary gland tumors of the maxilla and mandible: a clinicopathologic study of 11 cases with an analysis of the literature. *J Oral Maxillofac Surg* 1992;50:229-36.
8. Guven O, Keskin A, Akal UK. The incidence of cysts and tumors around impacted third molars. *Int J Oral Maxillofac Surg* 2000;29:131-5.
9. Munde A, Karle R, Metgud R, Rudgi BM. Central mucoepidermoid carcinoma of mandible. *Indian J Den Res* 2010;21:609-10.
10. Khan HA, Loya A, Azhar R, et al. Central mucoepidermoid carcinoma, a case report with molecular analysis of the TORC1/MAML2 gene fusion. *Head Neck Pathol* 2010;4:261-4.
11. Tucci R, Matizonkas-Antonio LF, de Carvalho AA, et al. Central mucoepidermoid carcinoma: Report of a case with 11 years' evolution and peculiar macroscopical and clinical characteristics. *Med Oral Patol Oral Cir Bucal* 2009;14:E283-6.
12. Bansal A, Shetty DC, Rai HR, Singh HP. Primary intraosseous mucoepidermoid carcinoma of maxilla - A rare occurrence. *e-J Dentistry* 2011;1:E14-7.
13. Alexander RW, Dupuis RH, Holton H. Central mucoepidermoid tumor (carcinoma) of the mandible. *J Oral Surg* 1974; 32:541-7.
14. Browand BC, Waldron CA. Central mucoepidermoid tumors of the jaws. *Oral Surg Oral Med Oral Pathol* 1975;40:631-43.
15. Takeda Y, Oikawa Y, Furuy I, et al. Mucous and ciliated cell metaplasia in epithelial linings of odontogenic inflammatory and developmental cysts. *J Oral Sci* 2005;47:77-81.
16. Slabbert H, Shear M, Altini M. Vacuolated cells and mucous metaplasia in the epithelial linings of radicular and residual cysts. *J Oral Pathol Med* 1995;24:309-12.
17. Thoma KH, Goldman HM, Gorlin RJ. Thoma's oral pathology. 6th ed. St. Louis, MO: Mosby; 1972.
18. Browne RM. Metaplasia and degeneration in odontogenic cysts in man. *J Oral Pathol Med* 1972;1:145-58.