

Case report

Nocardiosis of the Central Nervous System: A rare complication of COVID management?

Matthew DiMeglio^{a,*}, Hamadullah Shaikh^b, Jennifer Newman^c, Gustavo Vazsquez-Rubio^b

^a Department of Medicine, Thomas Jefferson University Hospital, Philadelphia, PA, the United States of America

^b Division of Infectious Disease, Department of Medicine, Thomas Jefferson University Hospital, Philadelphia, PA, the United States of America

^c Department of Neurology, Thomas Jefferson University Hospital, Philadelphia, PA, the United States of America

ARTICLE INFO

Keywords:

COVID-19
Coronavirus
Nocardiosis
Nocardia farcinica

ABSTRACT

This case report examines a previously immunocompetent male that was treated with a prolonged course of corticosteroids for COVID pneumonia. He then returned with worsening headaches followed by flaccid paralysis of extremities due to cerebral and spinal cord abscesses secondary to *Nocardia farcinica*. A review of the literature on the mechanism of immunosuppression with COVID infection and corticosteroids is provided.

Introduction

Nocardia species are ubiquitous organisms commonly involved in localized and systemic disease in immunocompromised patients [1]. Patient populations at highest risk include solid organ transplant recipients, those with immunodeficiencies such as HIV, and those receiving corticosteroids [2]. The most common species isolated in the United States include *N. nova* complex (28 %), *N. brasiliensis* (14 %), and *N. farcinica* (14 %) [3]. Corticosteroids are often utilized in COVID pneumonia, which sometimes require a prolonged course of tapered doses. To our knowledge, this is the first reported case of cerebral and intramedullary spinal cord abscesses caused by *Nocardia farcinica* without pulmonary involvement in the setting of a recent COVID infection requiring prolonged corticosteroids.

Case report

A 70-year-old male with a past medical history significant for type 2 diabetes mellitus and coronary artery disease that presented as a transfer from a neighboring medical center with a 2-day history of progressively worsening headache and new right sided hemiparesis.

Two months prior to presentation, he was admitted to a different hospital for worsening dyspnea was found to have COVID pneumonia. COVID positivity was determined through PCR testing, and patient reported receipt of two COVID mRNA vaccinations several months prior. Patient was treated with a course of remdesivir, dexamethasone, and

one dose of tocilizumab. He also completed an empiric seven-day course of piperacillin-tazobactam due to concern for superimposed bacterial pneumonia, although evaluation for additional bacterial and viral etiologies was unrevealing. Computed tomography (CT) chest revealed patchy consolidation and ground-glass opacities in bilateral lungs without evidence of nodular lesions or cavitation consistent with multifocal pneumonia. He was also found a small right lower lobe pulmonary embolism for which he was started on therapeutic anticoagulation. Due to persistent hypoxia, patient was restarted on high dose dexamethasone and discharged to home instructions to complete a prolonged dexamethasone taper (Fig. 1).

One month prior to presentation, he returned to the neighboring medical center with acutely worsening of chronic headaches that were present since his discharge as well as reportedly new right-sided hemiparesis. Computed tomography (CT) head revealed a new focal hypodensity in the posterior left frontal lobe. Magnetic resonance imaging (MRI) brain revealed scattered ring enhancing lesions with surrounding vasogenic edema along the grey-white junction as well as a large irregular lesion involving the proximal cervical spinal cord (Fig. 2A–D). Due to the concern for a possible parasitic or atypical neurologic infection, he was started on empiric antibiotics. Lumbar puncture revealed an opening pressure of 12 cm H₂O [reference range 5–20 cm H₂O], white blood cell count of 13/μL [reference range < 5/μL] with 19 % neutrophils, glucose 66 mg/dL, protein 165 mg/dL, red blood cell count of 2/μL, and five oligoclonal bands. Cytology and cultures from cerebrospinal fluid were negative. With an unclear etiology for his

* Correspondence to: Department of Medicine, Thomas Jefferson University Hospital, 111 South 11th Street, Philadelphia, PA 19107, the United States of America.
E-mail address: matthew.dimeglio@jefferson.edu (M. DiMeglio).

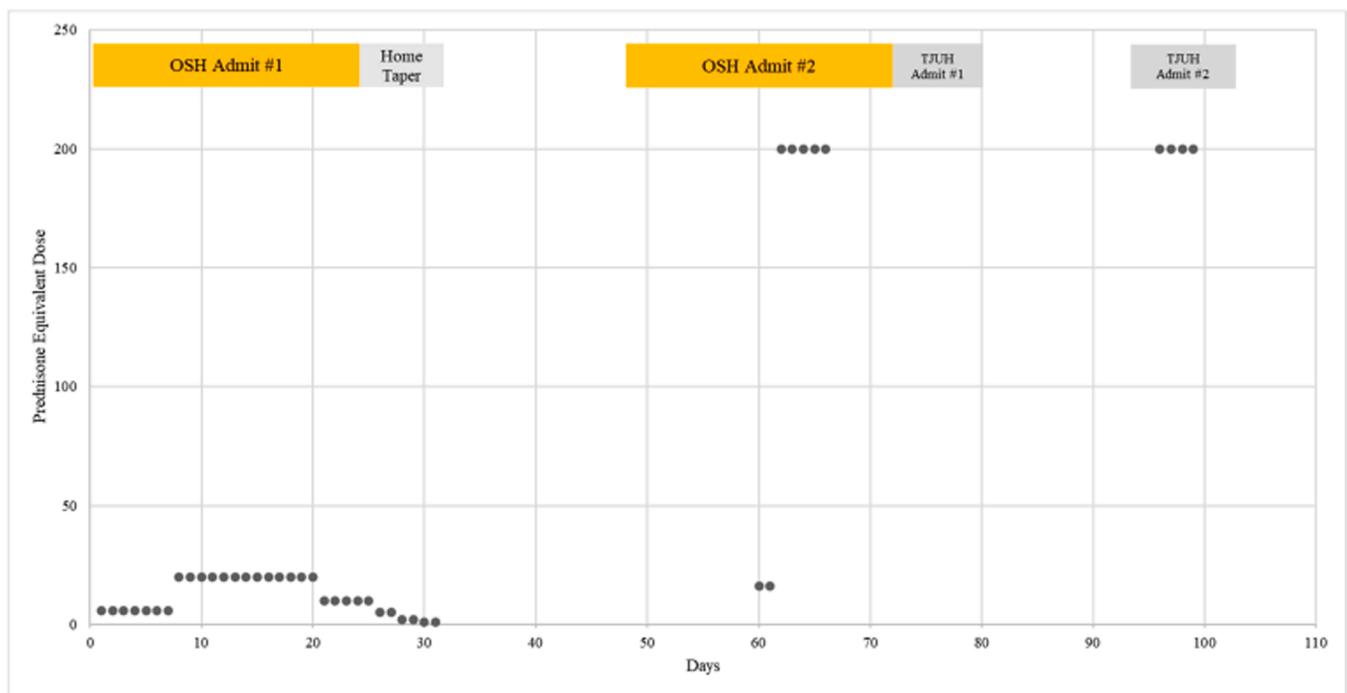


Fig. 1. Daily equivalent doses of prednisone received throughout hospitalizations.

neurologic disease, patient underwent a brain biopsy of a right frontal lobe lesion and pathology revealed a nonspecific reactive gliosis. He was then treated with pulse-dose steroids that resulted in improvement in symptoms and on repeat imaging. Following a discussion with family, the decision was made to transfer the patient to our medical center on the neurology service for further diagnostic workup of his neurologic disease.

On presentation, his MRI was stable from previous, and his lumbar puncture revealed resolution of the pleocytosis. Neurology believed that the improvement in symptoms, imaging, and laboratory data while on high dose steroids supported a resolving neuroinflammatory disease rather than an infectious etiology. Patient was continued on a steroid taper and discharged to a rehabilitation center.

He re-presented approximately two weeks following discharge with a one-day history of acutely worsening bilateral upper and lower extremity weakness. MRI brain at this time showed resolution of ring-enhancing lesions. Cervical spine imaging, however, revealed extension of the cervical spine lesion from the skull base to C7 with peripheral enhancement and internal necrosis at C5 level (Fig. 3A–B). On hospital day four, he underwent an evacuation of an apparent intramedullary abscess with neurosurgery. Staining revealed modified acid-fast branching rods for which he was started on trimethoprim-sulfamethoxazole and imipenem while awaiting susceptibility data. On hospital day five, intramedullary cultures revealed light growth *Nocardia farcinica*. On hospital day six, patient became increasingly febrile, hypoxic, and hypotensive requiring vasopressors for which linezolid was added to his antibiotic regimen. CT chest was obtained to evaluate for possible *Nocardia* lung abscesses that revealed stable ground-glass opacification of bilateral lungs without nodular or cavitory lesions. Patient continued to clinically deteriorate despite supportive measures. Following a family meeting, patient was transitioned to comfort care and expired on hospital day seven.

Discussion

Nocardia is a gram-positive, ubiquitous, soilborne bacterium that belongs to the family of ‘aerobic actinomycetes’ that appear as branching, filamentous rods on microscopy [4]. Protective immune

responses against nocardiosis is predominately driven by cell-mediated immunity through CD8+ T-cells without much contribution of humoral immunity [5]. As such, nocardiosis usually occurs as an opportunistic infection in the immunocompromised host with a special consideration for those with T-cell deficiency or dysfunction such as human immunodeficiency virus (HIV) infection [6,7]. However, at least 15 % of infections occur in immunocompetent patients with no underlying risk factors [8].

N. farcinica gains access to the host through inhalation of dust or traumatic inoculation of infected soil or water [4]. While most commonly presenting as a respiratory illness, *N. farcinica* has also been found to involve brain, surgical wounds, and the genitourinary tract [9]. Diagnosis of *Nocardia* relies on the use of modified-acid fast staining, which aids in differentiation from other genera within the aerobic actinomycetes group. This procedure utilizes a relatively diluted decolorizing agent (such as 0.5–1.0 % sulfuric acid as opposed to standard 20 % sulfuric acid) [10,11]. While there currently is a lack of prospective studies assessing optimal treatment regimens, *N. farcinica* isolates are often sensitive to trimethoprim-sulfamethoxazole (TMP-SMX), amoxicillin-clavulanic acid, linezolid, and imipenem [12]. Thus, TMP-SMX is often utilized as effective prophylaxis against the development of nocardiosis in immunocompromised hosts [4]. The predisposing risk factors for the development of nocardiosis in this patient were the combination of a prolonged course of high-dose steroids and recent COVID pneumonia.

While corticosteroids have been shown to have varying effects on T lymphocytes, high doses can cause a rapid depletion of circulating T-cells by redistribution of circulating cells to other body compartments [13]. In addition, they cause inhibition of interleukin (IL)-2, a cytokine that is essential for function, differentiation, and proliferation of T-cells [14,15]. Lastly, steroids can also induce apoptosis of T-lymphocytes, which further depletes the total pool of mature functioning T-cells [16]. All of these mechanisms result in a profound immunosuppressive state that promotes the development of opportunistic infections.

Likewise, there is now a growing body of evidence that supports that COVID infection can lead to significant dysregulation of the immune system. From a clinical standpoint, severe COVID infections have been characterized by lymphocytopenia, which is currently used as a

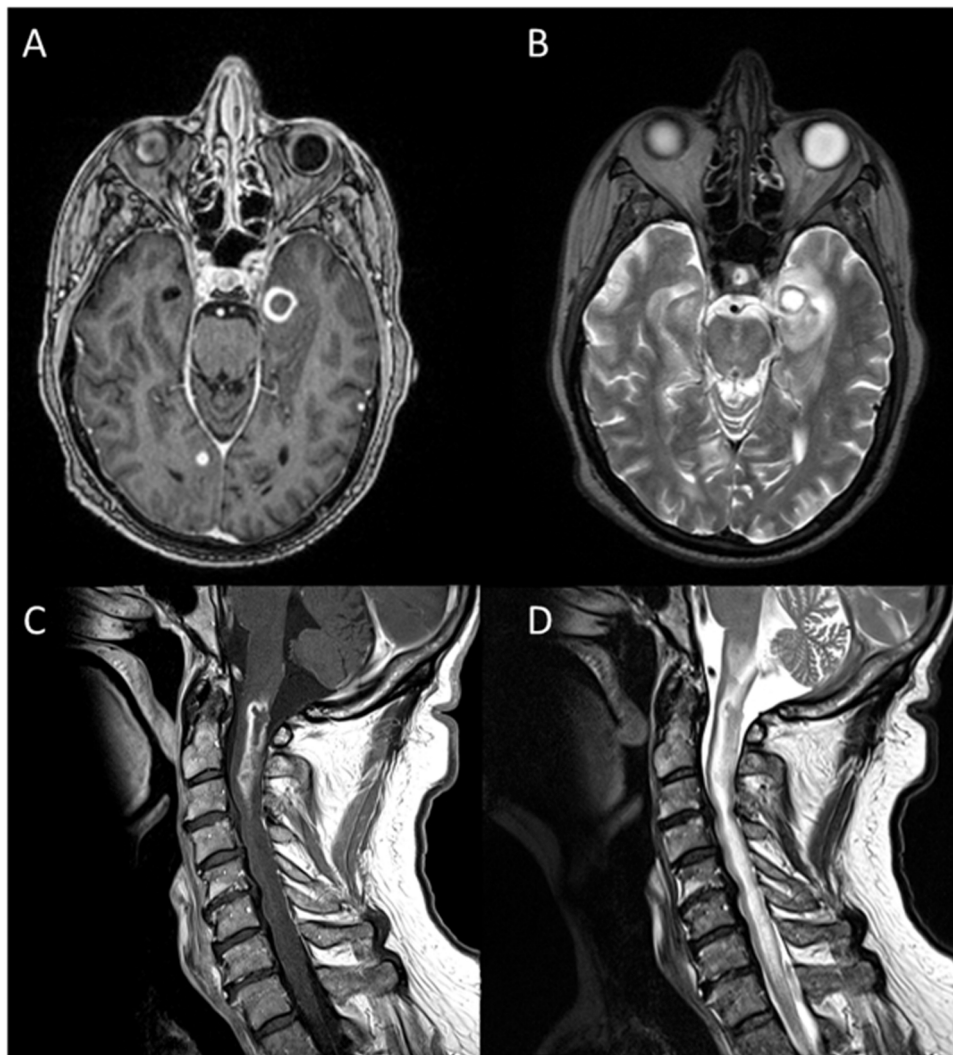


Fig. 2. MRI brain T1 weighted imaging revealed lesion with ring-enhancement (A) with adjacent edema on T2 weighted imaging (B). MRI cervical spine T1 weighted showed diffuse hypoattenuation consistent with internal necrosis (C) and diffuse hyperattenuation of cervical spine cord on T2 weighted imaging (D).

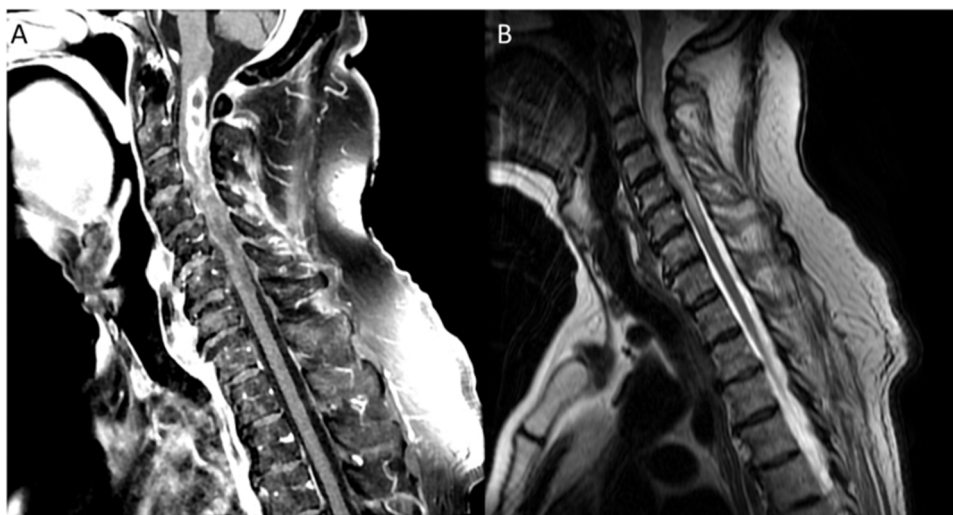


Fig. 3. MRI T1 weighted imaging revealing spinal cord hypoattenuation at the skull base with further extension to C5 concerning for internal necrosis (A) and redemonstration of diffuse hyperattenuation on T2 weighted imaging (B).

prognostic indicator of clinical deterioration and poor outcomes [17]. Much of this is believed to be due to a shift from a hyperinflammatory state during the acute phase of infection towards features of immunologic exhaustion [18]. Cellular and molecular studies have reported overexpression of programmed death 1 (PD-1), IL-2R, and IL-17 in T-cells derived from patients with severe COVID infection [19,20].

In conclusion, we report the first case of disseminated *Nocardia farcinica* infection in a previously immunocompetent patient. The combination of COVID infection as well as prolonged steroid exposure to treat his infection likely induced a transient immunocompromised state. We believe that this case should serve as a cautionary tale to the potential dangers of long-term steroid exposure in this patient population. This case also emphasizes the importance of early consideration of opportunistic infection as patients with recent COVID infections become increasingly common in clinical practice.

CRedit authorship contribution statement

Matthew DiMeglio: Conceptualization, Writing – original draft, Writing – review & editing, Visualization. **Hamadullah Shaikh:** Conceptualization, Writing – original draft, Writing – review & editing. **Jennifer Newman:** Writing – original draft, Writing – review & editing. **Gustavo Vazquez-Rubio:** Conceptualization, writing – review & editing, Supervision.

Consent

Written informed consent was obtained from the patient for publication of this case report and accompanying images. A copy of the written consent is available for review by the Editor-in-Chief of this journal on request.

Funding

This research did not receive any specific grant from funding agencies in the public, commercial, or not-for-profit sectors.

Conflict of Interest

The authors have no potential conflict of interests to report.

References

- [1] Lederman ER, Crum NF. A case series and focused review of nocardiosis: clinical and microbiologic aspects. *Medicine* 2004;83:300–13. <https://doi.org/10.1097/01.md.0000141100.30871.39>.

- [2] Ambrosioni J, Lew D, Garbino J. Nocardiosis: updated clinical review and experience at a tertiary center. *Infection* 2010;38:89–97. <https://doi.org/10.1007/s15010-009-9193-9>.
- [3] Uhde KB, Pathak S, McCullum Jr I, Jannat-Khah DP, Shadomy SV, Dykewicz CA, et al. Antimicrobial-resistant nocardia isolates, United States, 1995–2004. *Clin Infect Dis* 2010;51:1445–8. <https://doi.org/10.1086/657399>.
- [4] Wilson JW. Nocardiosis: updates and clinical overview. *Mayo Clin Proc* 2012;87:403–7. <https://doi.org/10.1016/j.mayocp.2011.11.016>.
- [5] Rico G, Ochoa R, Oliva A, Gonzalez-Mendoza A, Walker SM, Ortiz-Ortiz L. Enhanced resistance to *Nocardia brasiliensis* infection in mice depleted of antigen-specific B cells. *J Immunol* 1982;129:1688–93.
- [6] Beaman BL, Beaman L. *Nocardia* species: host-parasite relationships. *Clin Microbiol Rev* 1994;7:213–64.
- [7] Long PF. A retrospective study of *Nocardia* infections associated with the acquired immune deficiency syndrome (AIDS). *Infection* 1994;22:362–4. <https://doi.org/10.1007/BF01715551>.
- [8] Beaman BL, Burnside J, Edwards B, Causey W. Nocardial infections in the United States, 1972–1974. *J Infect Dis* 1976;134:286–9. <https://doi.org/10.1093/infdis/134.3.286>.
- [9] Torres OH, Domingo P, Pericas R, Boiron P, Montiel JA, Vázquez G. Infection caused by *Nocardia farcinica*: case report and review. *Eur J Clin Microbiol Infect Dis* 2000;19:205–12. <https://doi.org/10.1007/s100960050460>.
- [10] Mohanty S, Mohanty M. Modified acid-fast stain in the diagnosis of *Nocardia* infection: a revisit. *Am J Med Sci* 2021;361:e7–8. <https://doi.org/10.1016/j.amjms.2020.06.022>.
- [11] Mahon C, Lehman D, Manuselis G. *Aerobic gram-positive bacilli*. *Textb. diagn. microbiol.* 5th ed. Missouri: Saunders; 2015. p. 349–71.
- [12] Zhao P, Zhang X, Du P, Li G, Li L, Li Z. Susceptibility profiles of *Nocardia* spp. to antimicrobial and antituberculous agents detected by a microplate Alamar Blue assay. *Sci Rep* 2017;7:43660. <https://doi.org/10.1038/srep43660>.
- [13] Fauci AS, Dale DC, Balow JE. Glucocorticosteroid therapy: mechanisms of action and clinical considerations. *Ann Intern Med* 1976;84:304–15. <https://doi.org/10.7326/0003-4819-84-3-304>.
- [14] Paliogianni F, Ahuja SS, Balow JP, Balow JE, Boumpas DT. Novel mechanism for inhibition of human T cells by glucocorticoids. Glucocorticoids inhibit signal transduction through IL-2 receptor. *J Immunol Baltim Md* 1950 1993;151:4081–9.
- [15] Ross SH, Cantrell DA. Signaling and function of interleukin-2 in T lymphocytes. *Annu Rev Immunol* 2018;36:411–33. <https://doi.org/10.1146/annurev-immunol-042617-053352>.
- [16] Lanza L, Scudeletti M, Puppo F, Bosco O, Peirano L, Filaci G, et al. Prednisone increases apoptosis in in vitro activated human peripheral blood T lymphocytes. *Clin Exp Immunol* 1996;103:482–90. <https://doi.org/10.1111/j.1365-2249.1996.tb08306.x>.
- [17] Wynants L, Calster BV, Bonten MMJ, Collins GS, Debray TPA, Vos MD, et al. Prediction models for diagnosis and prognosis of covid-19 infection: systematic review and critical appraisal. *BMJ* 2020;369. <https://doi.org/10.1136/bmj.m1328>.
- [18] Ramakrishnan RK, Kashour T, Hamid Q, Halwani R, Tleyjeh IM. Unraveling the mystery surrounding post-acute sequelae of COVID-19. *Front Immunol* 2021;12:2574. <https://doi.org/10.3389/fimmu.2021.686029>.
- [19] Mahmoodpoor A, Hosseini M, Soltani-Zangbar S, Sanaie S, Aghebati-Maleki L, Saghaleini SH, et al. Reduction and exhausted features of T lymphocytes under serological changes, and prognostic factors in COVID-19 progression. *Mol Immunol* 2021;138:121–7. <https://doi.org/10.1016/j.molimm.2021.06.001>.
- [20] De Biasi S, Meschiari M, Gibellini L, Bellinazzi C, Borella R, Fidanza L, et al. Marked T cell activation, senescence, exhaustion and skewing towards TH17 in patients with COVID-19 pneumonia. *Nat Commun* 2020;11:3434. <https://doi.org/10.1038/s41467-020-17292-4>.