

## Caecal diverticulitis: Presentation and management<sup>☆</sup>



Adam Cristaudo<sup>a, \*</sup>, Praga Pillay<sup>a, b</sup>, Sanjeev Naidu<sup>a</sup>

<sup>a</sup> The Queen Elizabeth II Hospital, Coopers Plains, Queensland, Australia

<sup>b</sup> University of Queensland, Brisbane, Queensland, Australia

### HIGHLIGHTS

- CD occurs mostly in young Asians, presenting with atypical symptoms of appendicitis.
- With increasing migration, more patients are presenting in Western countries with CD.
- If imaging confirms uncomplicated CD, conservative treatment is recommended.
- In our limited study, diagnosis of CD was superior with computed tomography.

### ARTICLE INFO

#### Article history:

Received 13 November 2014

Received in revised form

6 January 2015

Accepted 12 February 2015

#### Keywords:

Diverticulitis

Caecal

Conservative

General surgery

Colorectal

### ABSTRACT

**Introduction:** While left sided colonic diverticular disease is common in Western countries, right sided colonic diverticular disease is rare. With increasing migration from Asia, many western countries including Australia, are now seeing more right sided diverticular disease, of which caecal diverticulitis is the commonest. This study aims to determine the incidence of caecal diverticulitis in patients presenting with colonic diverticulitis, as well as identify the symptoms and clinical features that may aid in making a pre-operative diagnosis.

**Methods:** Data was collected using the Queen Elizabeth II Hospital medical records database identifying patients diagnosed with colonic diverticulitis and, more specifically, those with caecal diverticulitis from January 2007 to December 2013. Only those patients who had confirmed caecal diverticulitis on imaging studies or at laparoscopy on their first admission were included in this study.

**Results:** A total of 632 patients with colonic diverticulitis were admitted to our institution over a seven-year period, of which 13 patients had caecal diverticulitis (2.06%). Of the 13 patients, twelve were of Asian background and ten were considered young ( $\leq 50$  years of age). The main complaints were right sided abdominal pain ( $n = 11$ , 84.6%) and diarrhoea ( $n = 5$ , 38.5%). Nine were diagnosed using computed tomography ( $n = 9/10$ , 90%), three on laparoscopy and one using ultrasound ( $n = 1/2$ , 50%). Ten patients were treated successfully by conservative means.

**Discussion:** A high index of suspicion in Asian patients with atypical symptoms of appendicitis, especially diarrhoea, may provide the diagnosis of caecal diverticulitis.

Crown Copyright © 2015 Published by Elsevier Ltd on behalf of Surgical Associates Ltd. This is an open access article under the CC BY-NC-ND license (<http://creativecommons.org/licenses/by-nc-nd/4.0/>).

## 1. Introduction

Left sided diverticular disease of the colon is very common in most Western societies and is probably related to diet. However, right sided diverticular disease is relatively uncommon, in particular caecal diverticulitis. It represents 3.6% of all colonic diverticular

disease and is found in one in every 300 appendicectomies [1,2]. Recent studies also indicate that caecal diverticulitis is most common amongst the Asian population and with increasing migration, this is being seen more frequently in the acute setting [3].

The management of caecal diverticulitis is now primarily conservative and most patients respond well to intravenous antibiotics. The exceptions are cases of caecal diverticulitis that have perforated or where malignancy cannot be excluded on imaging studies [4,5].

This study aims to determine the incidence of caecal diverticulitis in patients presenting with colonic diverticulitis, as well as to identify the symptoms and clinical features that may aid surgeons to make a preoperative diagnosis.

<sup>☆</sup> The corresponding author is not a recipient of a research scholarship. This article has been previously presented at the 2013 Royal Australasian College of Surgeons Queensland Meeting and at the 2014 Royal Australasian College of Surgeons Annual Scientific Congress in Singapore.

\* Corresponding author.

E-mail address: [adamcristaudo@bigpond.com](mailto:adamcristaudo@bigpond.com) (A. Cristaudo).

## 2. Methods

A retrospective analysis was performed identifying patients admitted to the Queen Elizabeth II Hospital from January 2007 to December 2013 with colonic diverticulitis. Only those patients with initial presentation and confirmed caecal diverticulitis either by imaging studies (presence of fat stranding around either a single caecal diverticulum or multiple caecal diverticula) or laparoscopy (presence of gross caecal diverticulitis) were included in this study. Patients with multiple presentations and non-diagnostic imaging were excluded.

Data was collected using the Queen Elizabeth II Hospital medical records database. Patient's clinical features, age, sex, ethnic origin and imaging studies were reviewed. Their duration of stay, management and outcomes were also analysed. Student's t-test was used to compare the mean age of patients with caecal diverticulitis with the rest of the patients with colonic diverticulitis.

## 3. Results

During the seven year period from January 27th, 2007 to the 29th of December, 2013, 632 patients were admitted with colonic diverticulitis. Thirteen patients (2.06% of all patients presenting with colonic diverticulitis) had caecal diverticulitis either confirmed on imaging or at laparoscopy.

The mean age of patients with colonic diverticulitis was seen to be 56.23 years, while the mean age of patients with caecal diverticulitis was 44.54 years, which was statistically significant ( $t = 5.736$ ,  $df 12$ ,  $P = 0.000094$ ) (Fig. 1). Of the 13 patients with caecal diverticulitis, there were eight males and five females. Twelve were of Asian descent and one was of Caucasian descent. There was no difference in the smoking status between the patients (smoker:  $n = 8$ , 61.54%; non-smoker:  $n = 5$ , 38.46%).

The main presenting symptoms in patients diagnosed with caecal diverticulitis were right sided abdominal pain ( $n = 11$ , 84.6%) and diarrhoea ( $n = 5$ , 38.5%). Other symptoms included anorexia ( $n = 3$ , 23.08%), constipation ( $n = 2$ , 15.38%), nausea ( $n = 1$ , 7.69%) and fever ( $n = 1$ , 7.69%). None of the patients reported vomiting or sweats (Table 1). The reported abdominal pain was similar to that seen in acute appendicitis, but vague in description and of a longer duration (five to seven days). Those who reported having diarrhoea had symptoms for a week prior to their admission (Table 2).

Blood tests showed an elevated white blood cell count in nine patients (four were normal). The C-reactive protein levels were also elevated in all of the five patients who had the test performed.

**Table 1**

Presenting symptoms of patients with confirmed caecal diverticulitis.

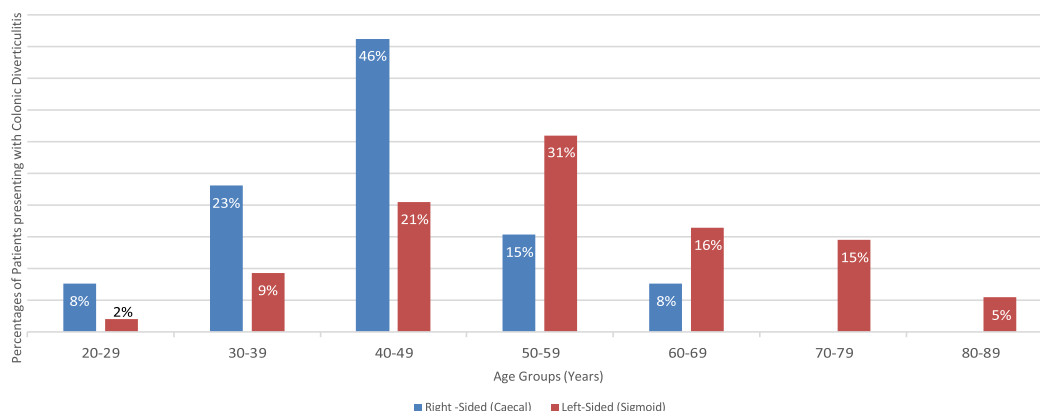
Presenting symptom	Percentage	No. of patients
Right-sided abdominal pain	85%	11
Diarrhoea	38%	5
Anorexia	23%	3
Constipation	15%	2
Nausea	8%	1
Fever	8%	1
Vomiting	0%	0
Sweats	0%	0

Serum lipase was normal in all patients who were tested ( $n = 10/10$ , 100%).

Diagnosis of caecal diverticulitis was confirmed in 10 of the 13 patients on imaging studies alone. An ultrasound scan was useful in one case ( $n = 1/2$ , 50%), while a computed tomography (CT) scan was necessary to detect the pathology in the other nine cases ( $n = 9/10$ , 90%). All ten patients diagnosed with caecal diverticulitis were treated with intravenous antibiotics and intravenous fluids for 4 days (on average) or until complete resolution of their symptoms. None required radiological intervention during this period of conservative treatment.

Three patients were diagnosed with caecal diverticulitis upon surgical intervention. All were provisionally diagnosed with acute appendicitis and underwent diagnostic laparoscopy. Two patients had no prior imaging, whilst one had a pre-operative CT scan suggestive of caecal inflammation involving the appendix. One was converted to an open right hemicolectomy upon discovery of a perforated caecal diverticulum, while the other two underwent precautionary appendectomies with no further bowel resection, drainage or lavage performed. Post-operatively, all patients were continued on intravenous antibiotics until their symptoms resolved (mean time of three days). The intravenous antibiotics regimen consisted of Ampicillin 1 g, every six hours, Metronidazole 500 mg, every eight hours, and an adjusted daily dose of Gentamycin (4–7 mg per kilogram patient weight). Patients with a Penicillin allergy ( $n = 1$ ) received a regimen of Ceftriaxone. All patients, regardless of treatment modality, were also given a course of oral antibiotics (Amoxicillin and Clavulanic Acid 875 mg/125 mg, one tablet, twice daily; Cephalexin 500 mg, one tablet, every six hours, if Penicillin allergy present) on discharge from hospital for 5 days.

Postoperative colonoscopy done on six patients revealed caecal diverticula in four, with two failing to identify any pathology. The other seven patients are awaiting their procedures due to long

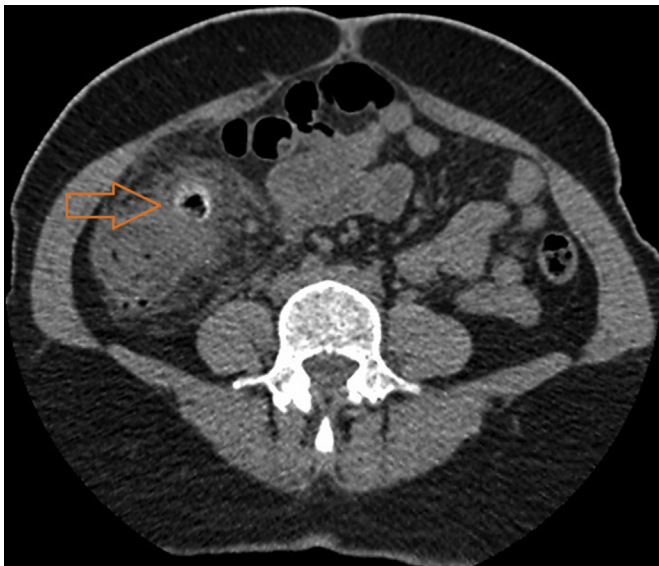


**Fig. 1.** Patients presenting with colonic diverticulitis: right-sided vs. left-sided.

**Table 2**  
Database of patients with confirmed caecal diverticulitis.

ID	Year	Age	Sex	Asian	Symptom Length	WCC	C-reactive protein	Lipase	Imaging findings	Operative findings	Length of stay	Length of IV ABs	Length of PO ABs	Smoker	Colonoscopy
1	2010	46	M	Yes	3	14	29	21	USS – Focal inflammation of ascending colon from caecum to		4	3	5	Yes	Normal
2	2010	34	M	Yes	2	14.8	55	18	N/A	Perforated caecal diverticulum	6	5	5	Yes	Not done
3	2010	64	M	No	14	13.9	N/A	20	CT – Thickened/Inflamed caecal diverticulum; No abscess; Normal appendix		3	3	5	Yes	Not done
4	2011	47	F	Yes	1	10.5	25	36	CT – Large caecal diverticulum with surrounding inflammation inclusive of appendix		4	3	5	Yes	Normal
5	2011	56	F	Yes	1	4.6	N/A	32	N/A	Inflamed caecal pole, No obvious diverticulum; Normal appendix	4	4	5	Yes	Normal
6	2012	47	M	Yes	3	12.7	N/A	21	USS – Normal; CT – Extensive focal area of caecal diverticulitis		5	5	5	No	Pathology confirmed
7	2012	40	M	Yes	14	17.1	N/A	22	CT – Inflammatory change in the RIF ?Appendicitis ? Caecal diverticulitis		3	3	5	Yes	Not done
8	2012	49	F	Yes	3	7.9	N/A	21	CT – Caecal and ascending colon diverticulitis; No collection (Fig. 2)		4	4	4	No	Pathology
9	2012	56	F	Yes	2	6.8	N/A	46	CT – Oedema surrounding a thickened caecal diverticulum		3	2	5	No	Not done
10	2012	37	M	Yes	3	4.7	80	25	CT – Caecal diverticulitis		3	3	5	No	Not done
11	2013	44	M	Yes	4	15	N/A	N/A	CT – Inflammation of caecum and ascending colon; Normal appendix		4	4	5	Yes	Pathology confirmed
12	2013	26	M	Yes	4	13.2	N/A	N/A	CT – Caecal inflammation		3	3	7	No	Pathology
13	2013	33	F	Yes	2	15.6	91	N/A	CT – Inflamed caecum, fat stranding	Inflamed caecum; Normal appendix	4	3	5	Yes	Pathology confirmed

waiting lists for colonoscopies. Patients were followed up within two weeks of their discharge from hospital in the admitting consultant's next available clinic. As of December 2013, no patients diagnosed with caecal diverticulitis in this study have been readmitted for recurrence of their disease.



**Fig. 2.** Computed tomography of 49 year old female patient with a caecal diverticulitis (arrow illustrates inflamed diverticulum of the caecum).

#### 4. Discussion

With an ever increasing migrant population, throughout the Western world, the nature of colonic disease is changing. The increasing incidence of caecal diverticulitis is one such example. The referral pattern of patients to our institution reflects a large (and growing) migrant population. Census data obtained from the Australian Bureau of Statistics shows that in the service area of the Queen Elizabeth II Hospital, the Asian population (namely of Chinese ancestry) has increased from 8.7% in 2006 to 15.1% in 2011 [6,7].

With increased experience in caecal diverticulitis, we are conscious of ensuring that a good history is taken, particularly the presence or absence of diarrhoea, to enable imaging studies to be carried out prior to any surgery for suspected appendicitis. This allows conservative management with antibiotics to be undertaken safely.

The patient's history, when compared to that of appendicitis, symptoms are prolonged (five to seven days), with the pain felt higher than McBurney's point and often milder. Diarrhoea appears to be an important distinguishing feature in our study, occurring in 38% of cases of confirmed caecal diverticulitis ( $n = 5$ ). Diarrhoea may be a presenting symptom in patients presenting with acute appendicitis, however, the percentage appears to be much less (reported in up to 18% of cases only) [4]. This is thought to occur in both instances due to the inflammation from the caecum affecting the nearby terminal ileum.

Smoking has also been suggested as a risk factor for complicating colonic diverticulitis [5]. Patients who smoked were noted to have an increased rate of perforation and postoperative recurrent diverticulitis episodes, as well as a more rapid onset of symptoms.

Subsequently, those who smoked also required surgery at a younger age. In our study, however, smoking was not seen to be a contributing factor, with a similar number of patients with confirmed caecal diverticulitis being smokers ( $n = 8$ ) and non-smokers ( $n = 5$ ).

White cell count and C-reactive protein levels have been shown to be useful adjuncts in diagnosing acute appendicitis [8,9]. However, their role in diagnosing patients with caecal diverticulitis remains unclear. In our study, of the 13 patients with confirmed caecal diverticulitis, C-reactive protein levels were elevated in all of the five patients who had the test performed and nine had elevated white cell counts. However, of the four patients with normal white cell counts, only one had their C-reactive protein level tested, which, in turn, was elevated (80 mg/L). Hence, further studies need to be performed in order to ascertain the validity of these markers in diagnosis of patients with caecal diverticulitis.

Before the availability of imaging, nearly all cases of caecal diverticulitis were diagnosed at laparotomy undertaken for suspected appendicitis. Caecal diverticulitis has been previously noted to be found in one in every 300 appendicectomies [1,2]. This frequency varies depending on the ethnic population with some more recent publications from the Asian literature suggesting that it is even more common than this. One study, in particular, indicated that it represents as much as 17% of all colonic diverticular disease [10]. In a Japanese study, caecal diverticulitis was also noted to be more common in young males [11].

Management of patients with confirmed caecal diverticulitis was mainly conservative ( $n = 10/13$ ; 76.9%) in our study and this approach is supported by a recent study published from Singapore. This study noted that diverticulitis in young (<50 years of age) Asians is also often right-sided and mild in nature, with recurrent episodes an uncommon occurrence [12].

This study is limited to the presentation and management of patients through our institution with confirmed caecal diverticulitis. Further studies could focus on the percentage of Asian patients presenting with right sided in contrast to left sided colonic diverticulitis, as well as ones comparing patients presenting with acute appendicitis in contrast to caecal diverticulitis. This would allow for further delineation between presenting symptoms and underlying pathology.

In conclusion, our experience suggests that in young ( $\leq 50$  years of age), Asian patients presenting with symptoms atypical of appendicitis, especially diarrhoea, a diagnosis of caecal diverticulitis needs to be considered. Patients with imaging diagnosed or clinical suspicion of uncomplicated caecal diverticulitis can be managed conservatively using the previously described intravenous antibiotic regimens. CT scan should be reserved for exclusion of bowel perforation or malignancy, appendicitis, or if ultrasound scans are non-diagnostic.

### Conflict of interest

There are no conflicts of interest.

### Funding

There were no sources of funding for our research.

### Consent

Consents were not obtained as there was no patient contact involved in this research.

### Ethical approval

There was no direct involvement of patients in this research so ethics approval was considered but not sought.

### Author contribution

Dr. Adam Cristaudo – Study design, data collections, data analysis, writing.

A/Prof. Pillay – Study design, writing.

Dr. Sanjeev Naidu – Study design, writing.

### Guarantor

Dr. Adam Cristaudo.

### References

- [1] Fischer MG, Varkas AM. Diverticulitis of the cecum and ascending colon. *Dis Colon Rectum* 1984;27:454–8.
- [2] Ngoi SS, Chia J, Goh MY, Sire E, Rauff A. Surgical management of right colon diverticulitis. *Dis Colon Rectum* 1992;35:799–802.
- [3] Altun H, Mantoglu B, Okuducu M, Onur E, Baskent A, Bora Karip A, et al. Therapy of solitary cecal diverticulitis in a young patient with laparoscopic right hemicolectomy. *Surg Laparosc Endosc Percutan Tech* 2011;21:e176–8.
- [4] Yeh B. Evidence-based emergency medicine/rational clinical examination abstract. Does this adult patient have appendicitis? *Ann Emerg Med* Sep 2008;52(3):301–3.
- [5] Turunen P, Wikström H, Carpelan-Holmström M, Kairaluoma P, Kruuna O, Scheinin T. Smoking increases the incidence of complicated diverticular disease of the sigmoid colon. *Scand J Surg* 2010;99(1):14–7.
- [6] Australian Bureau of Statistics 2006. Sunnybank, Qld (Statistical Local Area): People — cultural & language diversity, viewed 14 January 2014, [http://www.censusdata.abs.gov.au/census\\_services/getproduct/census/2006/quickstat/305111547?opendocument&navpos=220](http://www.censusdata.abs.gov.au/census_services/getproduct/census/2006/quickstat/305111547?opendocument&navpos=220).
- [7] Australian Bureau of Statistics 2011. Sunnybank, Qld (Statistical Local Area): Indigenous Profile, viewed 14 January 2014, [http://www.censusdata.abs.gov.au/census\\_services/getproduct/census/2011/quickstat/305111547?opendocument&navpos=220](http://www.censusdata.abs.gov.au/census_services/getproduct/census/2011/quickstat/305111547?opendocument&navpos=220).
- [8] Al-Abed Yahya A, Alobaid Nasser, Myint Fiona. Diagnostic markers in acute appendicitis. *Am J Surg*. Available online 29 July 2014, ISSN 0002-9610, <http://dx.doi.org/10.1016/j.amjsurg.2014.05.024>. (<http://www.sciencedirect.com/science/article/pii/S0002961014003602>).
- [9] Shogilev D, Duus N, Odom S, Shapiro N. Diagnosing appendicitis: evidence-based review of the diagnostic approach in 2014. *West J Emerg Med* 2014 Nov;15(7):859–71.
- [10] Yau Lo C, Wah Chu K. Acute diverticulitis of the right colon. *Am J Surg* 1996;171:244–6.
- [11] Sugihara K, Muto T, Morioka Y, Asano A, Yamamoto T. Diverticular disease of the colon in Japan: a review of 615 cases. *Dis Colon Rectum* 1984;27:531–7.
- [12] Tan K, Wong J, Yan Z, Chong C, Liu J, Sim R. Colonic diverticulitis in young Asians: a predominately mild and right-sided disease. *ANZ J Surg* 2014 Mar;84(3):181–4.