

Influence of Pneumoperitoneum on the Deep Venous System during Laparoscopy

Gabi Wazz, MD, Frank Branicki, Hakam Taji, Imran Chishty

ABSTRACT

Background: There is widespread concern that laparoscopic procedures that are usually performed under general anesthesia, using muscle relaxation, in a reverse Trendelenberg position and with pneumoperitoneum, may lead to venous stasis in lower limbs.

Objective: To evaluate perioperative changes in the venous system and determine the frequency of deep venous thrombosis associated with minimally invasive surgery.

Design: Prospective consecutive series.

Subjects: Sixty-five patients undergoing elective minimally invasive surgery.

Intervention: Laparoscopic procedures with no thromboprophylaxis.

Results: Sixty-one patients completed the investigations (coagulation profile and lower limb venous duplex scan) on admission and on the first postoperative day. The median duration of pneumoperitoneum was 45 minutes (range: 18-90 minutes). None of postoperative scans revealed thrombosis. No significant changes in the postoperative coagulation profile were identified. Perioperative scans of the left femoral vein revealed an increase in cross-sectional area ($P < 0.05$) and a decrease in peak blood velocity ($P < 0.05$).

Conclusion: In this study of low-risk patients for thromboembolism, laparoscopy with pneumoperitoneum at pressures below 12 mm Hg per se did not increase the prevalence of deep venous thrombosis. This implies that venous hemodynamic changes observed during pneumoperitoneum did not cause deleterious venous stasis.

Still, caution needs to be exercised with regard to the view that no special precautions to prevent deep venous thrombosis are warranted in patients undergoing laparoscopy.

Key Words: Laparoscopy, Deep venous thrombosis, Venous flow.

INTRODUCTION

Minimally invasive surgery has become the procedure of choice for many disorders, laparoscopic cholecystectomy being the most commonly performed operation. It provides tremendous advantages to patients, including smaller wounds, less postoperative discomfort and shorter hospital stay. Nevertheless, the potential complications associated with open surgery may be encountered, to a greater or lesser extent, in a laparoscopic setting. Distinct morbidity associated with laparoscopic surgery includes barotrauma and injuries due to Veress needle insertion and trocars.¹ In addition, it has been shown that the combined effect of general anesthesia, muscle relaxation and pneumoperitoneum can cause significant venous stasis in the lower limbs. The aim of this prospective study was to investigate the effects of pneumoperitoneum on the hemodynamics of the venous system of the lower limbs and the prevalence of deep venous thrombosis following laparoscopic procedures.^{2,3}

PATIENTS AND METHODS

Patients

All patients undergoing minimally invasive procedures at Tawam Hospital between February and October 1998 were included. Seventy-two consecutive patients were recruited, of whom six were considered to be at high risk for deep vein thrombosis (DVT) (**Table 1**). One patient was currently taking aspirin. These seven patients were excluded, leaving 65 patients eligible for the study (**Table 2**).

Method

All laparoscopic procedures were performed in a standardized manner employing general anesthesia, no

FRCS (Dr. Branicki).

FRCS (Ed) (Drs. Taji and Chishty).

From the Division of General Surgery, Department of Surgery, Tawam Hospital, Al-Ain, United Arab Emirates (all authors).

Address reprint request to: Dr. Gabi Wazz, Tawam Hospital, P.O. Box: 15258, Al-Ain, United Arab Emirates. Telephone: +9713677444, Fax: +97137678284, E-mail: gabiw@yahoo.com

© 2000 by JSL, *Journal of the Society of Laparoendoscopic Surgeons*. Published by the Society of Laparoendoscopic Surgeons, Inc.

Table 1.
Excluded patients at high risk for DVT.

	Number of Patients
Previous DVT	3
Oral contraceptive drugs	2
Pregnancy	1

Table 2.
Type of procedure performed.

	Number of Patients
Cholecystectomy	58
Diagnostic for Abdominal Pain	4
Appendectomy	2
Splenectomy	1

thromboprophylaxis, one dose of a second-generation cephalosporin at induction, and 20 mg of intravenous tenoxicam, a nonsteroidal anti-inflammatory, were administered in the recovery room following surgery.

On admission, a coagulation profile was performed, including an international normalized ratio (INR), activated partial thromboplastin time (APTT) and fibrinogen level. Bilateral lower limb duplex scans were performed the day before operation. The same protocol was repeated on the morning of the first postoperative day. Ten consecutive patients underwent an intraoperative duplex scan of the left common femoral vein. All duplex scans were performed by the same experienced vascular technician with the patient supine. Pre and postoperative scans were performed, using the Acuson 128 device (Acuson Corp., USA) with a 7.5 MHz duplex doppler vascular probe. Bilateral common and superficial femoral veins and the popliteal vein distally to mid tibial veins were evaluated. Intraoperative scans were performed, using the Eccocee device, (Toshiba, Japan) with a linear 7.5 MHz duplex doppler probe. The peak systolic venous velocity and femoral vein diameter were measured two centimeters proximal to the common femoral vein bifurcation, at the start of the procedure, at different pneumoperitoneal pressures and after waiting for 30 seconds at each pressure level. The veins were scanned

Table 3.
Peak blood velocities in left femoral vein (cm/sec).

Patient No.	Pressures (mm Hg)				
	0	8	10	12	15
1	21	20	20	10	13
2	27	28	26	13	9
3	24	24	23	16	14
4	26	24	25	14	13
5	27	25	23	10	10
6	34	35	30	22	11
7	26	26	26	24	10
8	25	27	24	9	9
9	33	32	33	15	16
10	26	25	15	14	15
Mean ± SD	26.9 ± 3.9	26.6 ± 4.3	24.5 ± 4.9	14.7 ± 4.9	12 ± 2.5

with the patient in the supine position. Color prints were obtained, and data were stored on video cassette for subsequent analysis.

STATISTICAL ANALYSIS

Comparisons between pre and postoperative coagulation profile values were made using a paired Student *s*-test. Mean systolic velocity and mean femoral vein diameter were compared using the Bonferroni *t*-test. A *P* value < 0.05 was considered to be of statistical significance.

RESULTS

Sixty-one of 65 patients completed all the required investigations. The median duration of pneumoperitoneum was 45 minutes (range: 18-90 minutes). No conversion to open techniques was required. None of the patients received any kind of anticoagulation therapy or compression stockings. No significant differences were evident between the pre and postoperative coagulation profiles (*P*=NS). Postoperative ultrasonic examinations revealed normal venous pulsatility and compressibility in both lower extremities. There was no evidence of deep vein thrombosis in any of the patients examined.

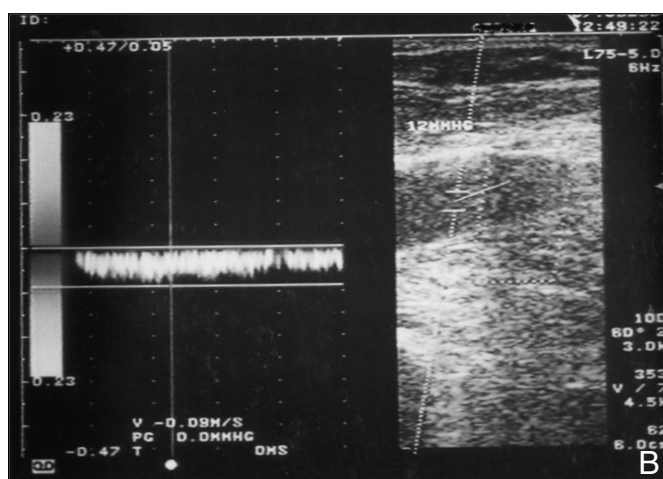
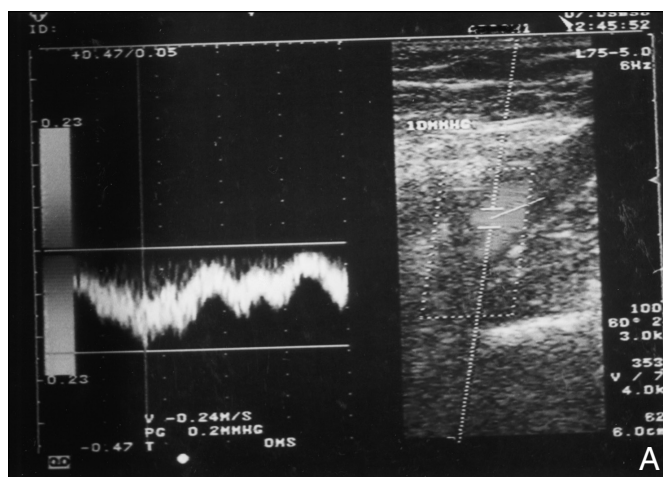


Figure 1. Significant decrease in femoral peak velocity at 12 mm Hg ($p < 0.05$). (A) pressure at 10 mm Hg. (B) pressure at 12 mm Hg.

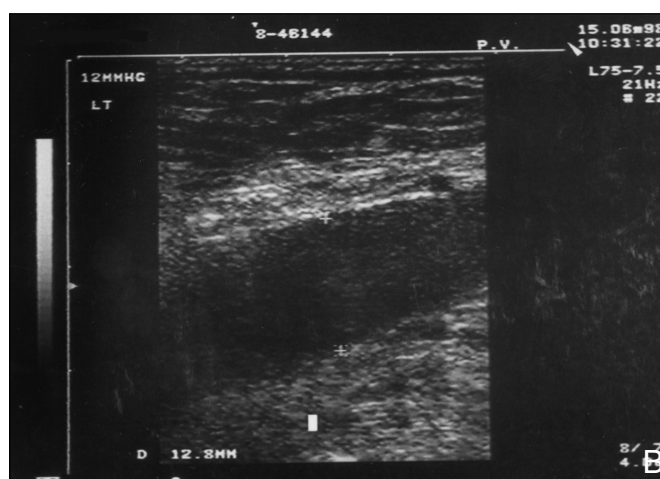
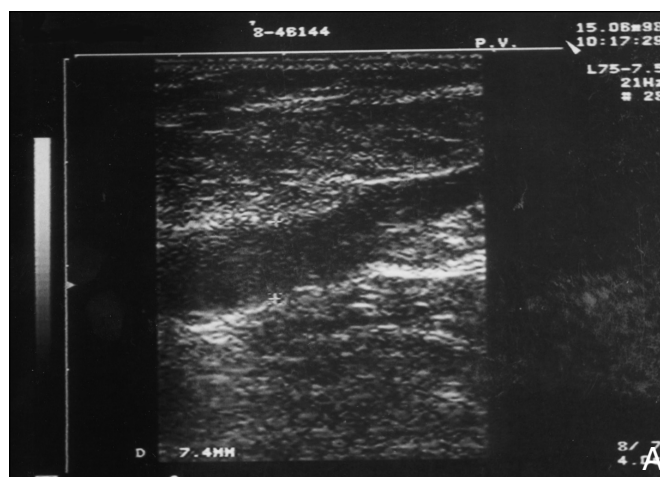
Figure 2. Significant increase in femoral diameter at 12 mm Hg ($p < 0.05$). (A) pressure at 0 mm Hg. (B) pressure at 12 mm Hg.

Perioperative scans revealed that gradual abdominal insufflation from zero to 10 mm Hg caused a small non-significant change in the femoral vein peak blood velocity. When the intra-abdominal pressure reached 12 mm Hg, a significant decrease ($P < 0.05$) was measured (**Table 3**) (**Figure 1**). In contrast, a significant increase ($P < 0.05$) in femoral venous diameter occurred when the intra-abdominal pressure reached 12 mm Hg when compared with lower insufflation pressures (**Table 4**) (**Figure 2**).

DISCUSSION

Virchow postulated three main causes of thrombosis: the slowing down of blood flow or stasis, damage to vessel walls, and an increase in blood coagulability.⁴ Stasis and vascular wall damage are usually acquired conditions. Risk factors include immobilization, surgery, trauma, pregnancy, certain hematological diseases, malignancy and the use of oral contraceptive drugs.⁵ Fifty percent of DVT detected postoperatively occurs during surgery, and significant venous stasis has been documented in association with the decrease in muscle tone during general anaesthesia.⁶

Table 4.
Diameter of left femoral vein (mm).

Patient No.	Pressure (mm Hg)				
	0	8	10	12	15
1	7.2	7.5	8.4	12.0	12.2
2	6.9	7.0	7.2	11.1	11.6
3	7.5	7.2	7.8	8.2	7.9
4	9.1	8.5	9.2	14.1	14.2
5	7.2	7.5	7.5	12.6	13.4
6	6.9	7.1	7.0	13.5	14.1
7	7.8	7.9	7.9	9.0	13.5
8	8.1	7.9	8.0	13.0	13.5
9	7.4	8.0	8.1	17.8	16.0
10	7.2	7.5	13	12.9	14
Mean ± SD	7.5 ± 0.7	7.6 ± 0.2	8.4 ± 1.7	11.9 ± 2.7	12.8 ± 2.2

Minimally invasive procedures have proved to be a major advance in the management of many conditions but carry inherent risks of unique complications.¹ Lindberg et al, 1994,⁷ in a literature review of the prevalence of thromboembolic complications after laparoscopic cholecystectomy, found a reported rate of 0.03% and also found that pulmonary embolism was rare (0.06%). More recently, Catheline et al, 1999,⁸ reported the prevalence of DVT to be 0.33% after laparoscopic cholecystectomy. It was noted, however, that all thromboses occurred in patients deemed to have a moderate risk.

Our study is the first prospective consecutive series, to our knowledge, in which no thromboprophylaxis of any kind, either with heparin or with one of the compression modalities, was used. We have clearly demonstrated that intraoperative stasis in lower limbs is considerably increased when pneumoperitoneum exceeds 12 mm Hg. This stasis was documented in two forms. First, the peak blood velocity fell markedly during laparoscopy. Second, there was significant dilatation of the femoral vein. Those findings are in keeping with the observations of other authors.⁹⁻¹¹ No DVT could be detected postoperatively in our series, and all duplex scans performed postoperatively demonstrated a reversal to normal of the changes seen intraoperatively. Critical review

of other series, excluding patients believed to be at risk for DVT, reveals similar findings.^{7,8} It is, however, difficult to explain the high incidence of DVT (55%) reported by Patel et al, 1996,¹² findings not reproduced in subsequent studies.

Lord et al, 1998,¹³ did not document any significant difference in the prevalence of DVT when a minilaparotomy approach was compared with laparoscopy for cholecystectomy, concluding that the risk of thromboembolic disease due to pneumoperitoneum is largely theoretical. It is noteworthy that other studies have failed to confirm the presence of stasis during laparoscopic procedures.¹⁴ It has been demonstrated that abdominal insufflation up to 20 mm Hg is well tolerated in most patients, causing only minimal effect on pulse or blood pressure^{13,15,16} and a small decrease in cardiac output.¹⁵ This suggests that total blood flow through the inferior vena cava is not significantly affected at intraoperative pressures below 20 mm Hg.^{16,17} Our study highlights the potential for thrombotic complications should intra-abdominal pressure exceeds 12 mm Hg.

CONCLUSION

Conflicting reports in the literature have failed to resolve concerns regarding the need for venous thromboprophylaxis. Until convincing data become evident, we concur with advice from the Society of American Gastrointestinal Endoscopic Surgeons (SAGES)¹⁸ that recommendations for open surgical procedures be followed when the same procedures are to be accomplished via laparoscopic access.

References:

1. Deyo GA. Complication of laparoscopic cholecystectomy. *Surg Laparosc Endosc.* 1992;2:41-48.
2. Caprini JA, Arcelms JI. Prevention of postoperative venous thromboembolism following laparoscopic cholecystectomy. *Surg Endosc.* 1994;8:741-747.
3. Sobolowski AP, Deshmukh RM, Bunson BL, et al. Venous hemodynamic change during laparoscopic cholecystectomy. *J Laparoendosc Surg.* 1995;5:363-369.
4. Virchow R. Phlogse und thrombeseim im gefasssystem. In *Gesammelte Abhandlungen Zur Wissenschaftlichen Medizin.* Frankfurt: Staatsdruckerei; 1856.
5. Rosendaal FR. Venous thrombosis: a multicausal disease. *Lancet.* 1993;353:1167-1173.
6. Cotton LT, Roberts VC. The prevention of deep vein throm-

- bosis, with particular reference to mechanical methods of prevention. *Surgery*. 1977;81:228-235.
7. Lindberg F, Bergqvist D, Rasmussen IB. Incidence of thromboembolic complications after laparoscopic cholecystectomy. *Surg Laparosc Endosc*. 1997;7:324-331.
 8. Catheline JM, Turner R, Gaillard JL, Rizk N, Champaselt G. Thromboembolism in laparoscopic surgery: risk factors and preventive measures. *Surg Laparosc Endosc*. 1999;9:135-139.
 9. Beebe DS, McNevin MP, Crain JM, et al. Evidence of venous stasis after abdominal insufflation for laparoscopic cholecystectomy. *Surg Gynecol Obstet*. 1993;176:443-447.
 10. Jorgenssen JO, Lalak NJ, North L, Hanel K, Hunt DR, Morris DL. Venous stasis during laparoscopic cholecystectomy. *Surg Laparosc Endosc*. 1994;4:128-133.
 11. Millard JA, Hill BB, Cook PS, Fenoglio ME, Stahlgren LH. Intermittent sequential pneumatic compression in prevention of venous stasis associated with pneumoperitoneum during laparoscopic cholecystectomy. *Arch Surg*. 1993;128:914-919.
 12. Patel MI, Hardman DT, Nicholis D, Fisher CM, Appleberg M. The incidence of deep venous thrombosis after laparoscopic cholecystectomy. *Med J Aust*. 1996;164:652-656.
 13. Lord R, Ling J, Hugh T, et al. Incidence of deep vein thrombosis after laparoscopic versus minilaparotomy cholecystectomy. *Arch Surg*. 1998;133:967-973.
 14. Bais JE, Schievreck J, Banga JD, Vroonhoren TJ. Resistance to venous outflow during laparoscopic cholecystectomy and laparoscopic herniorrhaphy. *Surg Laparosc Endosc*. 1998;8:102-107.
 15. Kelman GR, Swapp GH, Smith I. Cardiac output and arterial blood-gas tension during laparoscopy. *Br J Anaesth*. 1972;44:1155-1162.
 16. Wittgen CM, Anrus CH, Fitzgerald SD. Analysis of the hemodynamic and ventilatory effects of laparoscopic cholecystectomy. *Arch Surg*. 1991;126:997-1001.
 17. Kashtan J, Green JF, Parsons EQ, Holcroft JW. Hemodynamic effects of increased abdominal pressure. *J Surg Res*. 1981;30:249-255.
 18. SAGES, Global statement on deep venous thrombosis prophylaxis during laparoscopic surgery. <http://www.sages.org/guidelines/sg.06/sg.06.html>