

Research Article

Antiemetic and Myeloprotective Effects of *Rhus verniciflua* Stoke in a Cisplatin-Induced Rat Model

Hyo-Seon Kim,¹ Hyeong-Geug Kim,¹ Hwi-Jin Im,¹ Jin-Seok Lee,¹ Sung-Bae Lee,¹
Won-Yong Kim,¹ Hye-Won Lee,² Sam-Keun Lee,³ Chang Kyu Byun,³ and Chang-Gue Son¹

¹Liver and Immunology Research Center, Daejeon Oriental Hospital of Daejeon University, 176-9 Daeheung-ro, Jung-gu, Daejeon 34929, Republic of Korea

²TKM-Based Herbal Drug Research Group, Korea Institute of Oriental Medicine, Daejeon 34052, Republic of Korea

³Department of Applied Chemistry, Daejeon University, 62 Daehak-ro, Dong-gu, Daejeon 34520, Republic of Korea

Correspondence should be addressed to Chang-Gue Son; ckson@dju.ac.kr

Received 30 November 2016; Accepted 9 January 2017; Published 8 February 2017

Academic Editor: Nazli B. Sarikahya

Copyright © 2017 Hyo-Seon Kim et al. This is an open access article distributed under the Creative Commons Attribution License, which permits unrestricted use, distribution, and reproduction in any medium, provided the original work is properly cited.

Rhus verniciflua Stoke has been commonly used in traditional medicine to treat gastrointestinal (GI) dysfunction diseases. In order to investigate pharmacological properties of *Rhus verniciflua* Stoke water extract (RVX) on cisplatin-induced amnesia, RVX (0, 25, 50, or 100 mg/kg) was orally administrated for five consecutive days after a single intraperitoneal injection of cisplatin (6 mg/kg) to SD rat. Cisplatin injection significantly increased the kaolin intake (emesis) but reduced the normal diet intake (anorexia) whereas the RVX treatment significantly improved these abnormal diet behaviors at both the acute and delayed phase. The serotonin concentration and the related gene expressions (5-HT₃ receptors and SERT) in small intestine tissue were abnormally altered by cisplatin injection, which were significantly attenuated by the RVX treatment. Histological findings of gastrointestinal tracts, as well as the proteins level of proinflammatory cytokines (TNF- α , IL-6, and IL-1 β), revealed the beneficial effect of RVX on cisplatin-induced gastrointestinal inflammation. In addition, RVX significantly improved cisplatin-induced myelosuppression, as evidenced by the observation of leukopenia and by histological examinations in bone marrow. Our findings collectively indicated *Rhus verniciflua* Stoke improved the resistance of rats to chemotherapy-related adverse effects in the gastrointestinal track and bone marrow.

1. Introduction

A recent study reported that more than 14.1 million people per year are newly diagnosed with various malignancies worldwide [1]. The application of anticancer therapies depends on the status of clinical progression, characteristics of tumors, and patient conditions [2]. Regarding treatments for patients with cancers, various medical modalities, including surgery, radiotherapy, chemotherapy, and immunotherapy, have been developed [3, 4]. Especially for patients with advanced cancers, chemotherapy is the first choice for more than 8 million patients annually in the United States [5, 6]. Chemotherapy, however, inevitably induces diverse adverse effects including emetic symptoms, leukopenia, gastrointestinal toxicity, hair loss, and fatigue [7]. Generally, 70 to 80% of patients undergoing chemotherapy complain mainly of the emetic symptoms,

such as vomiting and nausea [8, 9]. Conventional agents for emesis include 5-hydroxytryptamine 3 (5-HT₃) receptor antagonists, neurokinin 1 (NK1) receptor antagonists, glucocorticoids, and metoclopramide [10]. However, these drugs are only effective in either acute emesis or delayed emesis [11], or they evoke additional adverse effects, including insomnia, constipation, diarrhea, and headache [12, 13].

On the other hand, herbal plants or their derived natural compounds have attracted increasing attention in anticancer drug studies particularly regarding antiadverse effects, such as the emesis which was evoked by gastro enteric dysfunctions. *R. verniciflua* Stoke, called the lacquer tree, belonging to the Anacardiaceae family, has traditionally been described for treating digestive troubles [14]. According to the traditional Chinese medical literature, known as *Ben-cao-gang-mu* (本草綱目), the pharmacological efficacies of *R. verniciflua* on

the gastrointestinal tract problems have been well indicated [15].

Several animal studies have reported that *R. verniciflua* exerted beneficial effects on inflammation and several metabolic diseases [16, 17] and protective effects against drug toxicity [18]. The previous studies suggested that *R. verniciflua* would be a potent candidate for drug development to treat chemotherapy-induced side effects, particularly emesis.

The present study therefore aimed to investigate the effects of *R. verniciflua* water extract (RVX) against chemotherapy-related adverse effects, particularly emesis and gastrointestinal inflammation using a model of rats injected with cisplatin.

2. Methods

2.1. Procedure for Fingerprinting and Sequencing Analysis. *R. verniciflua* was obtained from a local specific farm for *R. verniciflua* in Ok-Cheon (Chung-buk, South Korea). After obtaining *R. verniciflua* water extract (RVX), a final yield of 0.70% (w/w), we conducted fingerprint using a HPLC-DAD instrument (YL9100 series, South Korea) as described in Supplementary Information (see Supplementary Material available online at <https://doi.org/10.1155/2017/9830342>).

Genomic DNA from the leaves of RVX was extracted using a DNeasy Plant Mini kit (Qiagen, Valencia, CA, United States). The internal transcribed spacer (ITS) gene, including 5.8s ribosomal DNA, was amplified by polymerase chain reaction (PCR) using the primers for ITS1 (5'-TAG CGC AGA ACG ACC CGC CAA CCT GTA T-3') and ITS2 (5'-CAC CTG ACC TGG GGT CGC GAT GCG-3'). Amplification of ITS fragments was conducted with the 2X SG Taq Master Mix (LPS solution, Daejeon, South Korea), and PCR conditions were obtained using an IQ5 PCR Thermal Cycler (Bio-Rad, Hercules, CA, United States) in the following steps: predenaturation at 95°C for 5 min, 35 cycles of 95°C/30 s (denaturation), 55°C/40 s (annealing), 72°C/1 min (extension), and final extension at 72°C for 5 min. The PCR products were analyzed on 1% agarose gel and distinguishable bands were purified using QIAQuick Gel extraction kit (Qiagen). The products were sequenced using a BigDye Terminator v3.1 cycle sequencing kit (Applied Biosystems, CA, United States) with an ABI3730XL (Applied Biosystems) automated sequencer. After alignment by ClustalW, the results were analyzed using BioEdit 7.0 version and vector NTI advance software, version 11.

2.2. Chemical Materials. The reagents for the present study were as follows: cisplatin (cis-diammineplatinum (II) dichloride), metoclopramide, protocatechuic acid, fustin, fisetin, sulfuretin, and butein were obtained from Sigma (St. Louis, MO, United States). Arabic gum was purchased from Junsei Chemical Co., Ltd. (Tokyo, Japan). Calci-Clear Rapid was purchased from National Diagnostics (Atlanta, GA, United States). Olive oil was purchased from DC Chemical Co., Ltd. (Seoul, South Korea).

2.3. Kaolin Diet Preparation. Kaolin ($\text{H}_2\text{Al}_2\text{Si}_2\text{O}_8 \cdot \text{H}_2\text{O}$) was prepared according to a previous method [19]. Briefly, pharmacological-grade kaolin (Samchun Pure Chemical Co., Ltd., Pyeongtaek, South Korea) was mixed with 1% acacia or gum Arabic in double-distilled water to form a thick paste. The paste was rolled and cut into small pellets. Pellets were dried completely at room temperature for 3-4 days and were maintained in sterile conditions.

2.4. Animals and Experimental Design. A total of 36 specific pathogen-free Sprague-Dawley male rats (6 weeks old, 160–180 g) were purchased from Dae-Han Bio Link (Chungbuk, South Korea). The rats were housed in a controlled temperature room at $22 \pm 2^\circ\text{C}$, in $55\% \pm 10\%$ relative humidity with a 12 h:12 h light-dark cycle, and they were freely fed commercial standard chow (Dae-Han Bio Link) and were provided tap water ad libitum for 7 days. After acclimation, the rats were housed separately in cages and were familiarized with the testing procedures. In addition to routine rat chow and tap water, a measured quantity of kaolin (5 g) pellets was provided in separate containers for 3 days prior to the experiment to allow the rats to adapt to its presence psychologically. After 3 days of habituation, the animals were subjected to pica experiments.

Acclimatized rats were divided into six groups ($n = 6$): normal and control groups, three dosages of RVX treatment groups (25, 50, or 100), and a Met 25 group. At 0 h, the normal group received saline, while all of the other groups received a single intraperitoneal injection of cisplatin in saline (6 mg/kg). Two hours after cisplatin injection, each group was initially treated with oral administration of water (normal and control groups), RVX (25, 50 or 100 mg/kg), or metoclopramide (25 mg/kg), followed by the same administration at 24 h intervals for 96 h. All of the groups were allowed free access to kaolin diets until 120 h. All of the rats were monitored for their consumption of normal and kaolin diets, and their body weights were measured daily. On the last experimental day, all rats were sacrificed by collection of whole blood via the abdominal vein under ether anesthesia.

This animal experiment was approved by the Institutional Animal Care and Use Committee of Daejeon University (DJUAR2015-041) and was conducted in accordance with the Guide for the Care and Use of Laboratory Animals published by the US National Institutes of Health (Bethesda, MD, United States).

2.5. Hematology and Histopathology. On the final day of the experiment, hematological parameters were measured using a HEMA VET 850 automatic analyzer (CDC Technologies, United States). The white blood cell (WBC), neutrophil, lymphocyte, monocyte, basophil, eosinophil, red blood cell (RBC), hemoglobin, and platelet counts were determined. The spleen and thymus were removed, and their weights were measured. The stomach tissue, small intestine (both proximal and distal), and colon were dissected, washed in ice-cold phosphate buffered saline, and fixed in 10% formalin for 3 days. The paraffin-embedded samples were sectioned (4 μm thickness) and slides stained with H&E or Masson's trichrome

staining. Bone marrow was decalcified with Calci-Clear Rapid (National Diagnostics), then embedded in paraffin, sectioned at 6 μm , and stained with H&E stain. Representative images were obtained using a light microscope (Leica Microsystems, Wetzlar, Germany). The percentage areas of positively stained cells were analyzed using Image J image analysis software (Rasband, Bethesda, MD, United States), version 1.46.

2.6. Quantitative Real-Time PCR Analysis. Total RNA was extracted from small intestine samples using Trizol reagent (Molecular Research Center, Cincinnati, OH, United States). cDNA was synthesized from total RNA (2 μg) in a 20 μL reaction using the High-Capacity cDNA reverse transcription kit (Ambion, Austin, TX, United States). Real-time PCR was performed using SYBR Green PCR Master Mix (Applied Biosystems, Foster City, CA, United States) with PCR amplification performed in accordance with a standard protocol using the IQ5 PCR Thermal Cycler (Bio-Rad, Hercules, CA, United States). The following primers were used (5' \rightarrow 3', forward and reverse): 5-HT3A receptor, GGA CTC CTG AGG ACT TCG ACA A and TTC CCC ACG TCC ACA AAC TC; SERT, CTG TTC ATC ATT TGC AGT TTT CTG A and TCC CTA TGC AGT AGC CCA AGA; and β -actin, AGG CCA ACC GTG AAA AGA TG and CCA GAG GCA TAC AGG GAC AAC.

2.7. Measurement of Serotonin and Proinflammatory Cytokines. Serotonin in the small intestine was measured using a serotonin ELISA kit (LDN, Nordhorn, Germany) and stomach tissue levels of proinflammatory cytokines were analyzed using commercial ELISA kits (TNF- α from BD OptEIA, CA, United States; IL-6 and IL-1 β from R&D Systems, MN, United States).

2.8. Statistical Analysis. The results are expressed as the means \pm standard deviations (SD). The statistical significance of differences between groups was analyzed by one-way analysis of variance (ANOVA), followed by Fisher's least-significant difference (LSD) test, or Student's *t*-test. In all of the analyses, values of $p < 0.05$ were considered statistically significant.

3. Results

3.1. Fingerprint of RVX and Verification of *R. verniciflua*. The chemical constitution analysis of RVX was evaluated by performing HPLC-DAD analysis using four reference components: one phenolic compound (protocatechuic acid) and three flavonoid compounds (fustin, fisetin, and sulfuretin), respectively (Figure 1(a)). The fustin was quantified as the prevalent compound ($61.61 \pm 0.20 \mu\text{g}/\text{mg}$), and it was followed by fisetin, protocatechuic acid, and sulfuretin, respectively (Figure 1(b)). The gene sequences of the ITS1-5.8s-ITS2 region coincided completely with *R. verniciflua* Stoke (AY510151.1, GenBank) ("*Toxicodendron vernicifluum* internal transcribed spacer 1, 5.8S ribosomal RNA gene, and

internal transcribed spacer 2, complete sequence," 2004) (Figure 1(c)).

3.2. Changes in Kaolin Diet Intake. Cisplatin injection (6 mg/kg) considerably increased kaolin diet intake by 2.6- to 3.3-fold, between 24 h and 120 h, compared with the normal group. Kaolin diet intake was significantly decreased by RVX 25 mg/kg (at 72 h and 120 h, $p < 0.01$), RVX 50 mg/kg (from 48 h to 72 h, $p < 0.05$ or $p < 0.001$), and RVX 100 mg/kg (from 24 h to 96 h, $p < 0.05$ or $p < 0.01$, Figure 2(a)). Metoclopramide suppressed kaolin intake to a substantial extent from 72 h to 96 h. When the analysis was conducted on total kaolin intake over 0–120 h, the cisplatin-induced increase in total kaolin intake (3.0-fold) was significantly attenuated by RVX treatment ($p < 0.05$ for 50 mg/kg; $p < 0.01$ for 100 mg/kg, Figure 2(b)).

3.3. Changes of Normal Diet Intake and Body Weight. Cisplatin injection significantly reduced normal diet intake by 0.5- to 0.7-fold, between 24 and 120 h, compared with the normal group, while it was significantly attenuated by administration of RVX 50 mg/kg (from 48 to 96 h, $p < 0.001$) and RVX 100 mg/kg (from 24 to 96 h, $p < 0.01$ or $p < 0.001$, Figure 2(c)). Body weight was also significantly reduced by 47.14 g, compared with normal group (at 120 h, $p < 0.001$). Treatment with RVX (50 and 100 mg/kg), however, significantly ameliorated this weight loss compared with the control group (Figure 2(c)). Metoclopramide showed similar effects to RVX (50 mg/kg) in both normal diet intake and recovery of weight loss.

3.4. Histopathological Findings for Gastrointestinal Damage. Hematoxylin and Eosin (H&E) staining revealed that cisplatin injection induced severe degenerative changes, especially in the small intestine and colon, as characterized by disruption of the epithelial architecture and dilated intercellular spaces. Treatment with RVX remarkably reversed these pathological alterations, compared with control group. In stomach tissue, no marked damage but intensive blue staining was observed, indicating migration of gastric chief cells to the outer layer of the stomach lining, in only control and metoclopramide groups but not in the RVX-treated groups (Figure 3(a)). Masson's trichrome staining confirmed loss of collagen at the submucosal region in the small intestine and colon of the control group, whereas RVX treatments notably reduced these collagen losses (Figure 3(b)).

3.5. Serotonin Concentrations and Related Gene Expressions in Small Intestine Tissue. The concentration of serotonin in small intestine tissue was elevated by 1.8-fold by cisplatin injection compared with the normal group, while RVX treatment (especially 50 mg/kg) significantly attenuated this compared with the control group ($p < 0.05$, Figure 4(a)). Cisplatin injection significantly upregulated mRNA expression of 5-HT3A receptor (2.1-fold) but downregulated serotonin transporter (SERT, 0.5-fold) compared with the normal group in small intestine tissue ($p < 0.001$). Treatment with RVX significantly modulated these alterations of 5-HT3A receptor

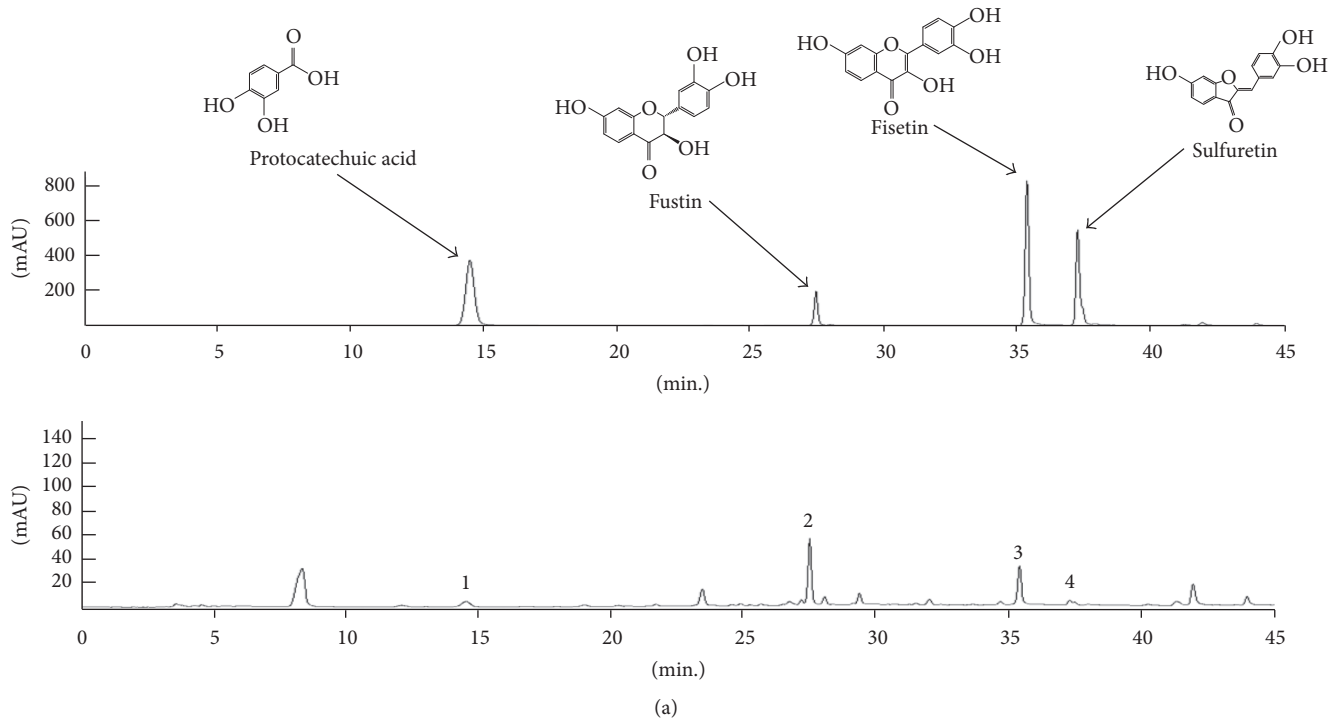


FIGURE 1: HPLC fingerprint and sequencing analysis. RVX and its standard compounds were subjected to HPLC. Chromatogram of reference compounds mixture and RVX (a). The quantitative analysis of each component in RVX (b). The comparative 5.8s rDNA sequences between *R. verniciflua* Stoke and RVX were exhibited (c).

($p < 0.01$ for 50 mg/kg, $p < 0.001$ for 100 mg/kg) and SERT ($p < 0.01$ for 50 mg/kg, $p < 0.05$ for 100 mg/kg) compared with the control group, respectively (Figure 4(b)). Metoclopramide showed similar effects of RVX (50 mg/kg) on the expression of 5-HT_{3A} receptor, but not on the serotonin concentration or SERT gene expression.

3.6. Protein Levels of Proinflammatory Cytokines in Stomach Tissue. Cisplatin injection considerably elevated the protein levels of proinflammatory cytokines, including TNF- α (1.5-fold), IL-6 (3.4-fold), and IL-1 β (3.4-fold) in stomach tissue,

compared with the normal group. These abnormal elevations of the three cytokines were significantly attenuated by RVX treatment compared with the control group ($p < 0.001$, Figure 4(c)). Metoclopramide showed similar effects to RVX treatment.

3.7. Changes in Hematological Parameters. On the final day of the experiment, the control group showed the leukopenia in approximately 57% of the normal group; in particular, lymphocyte counts were decreased in half that of the normal group. These alterations were significantly improved to near

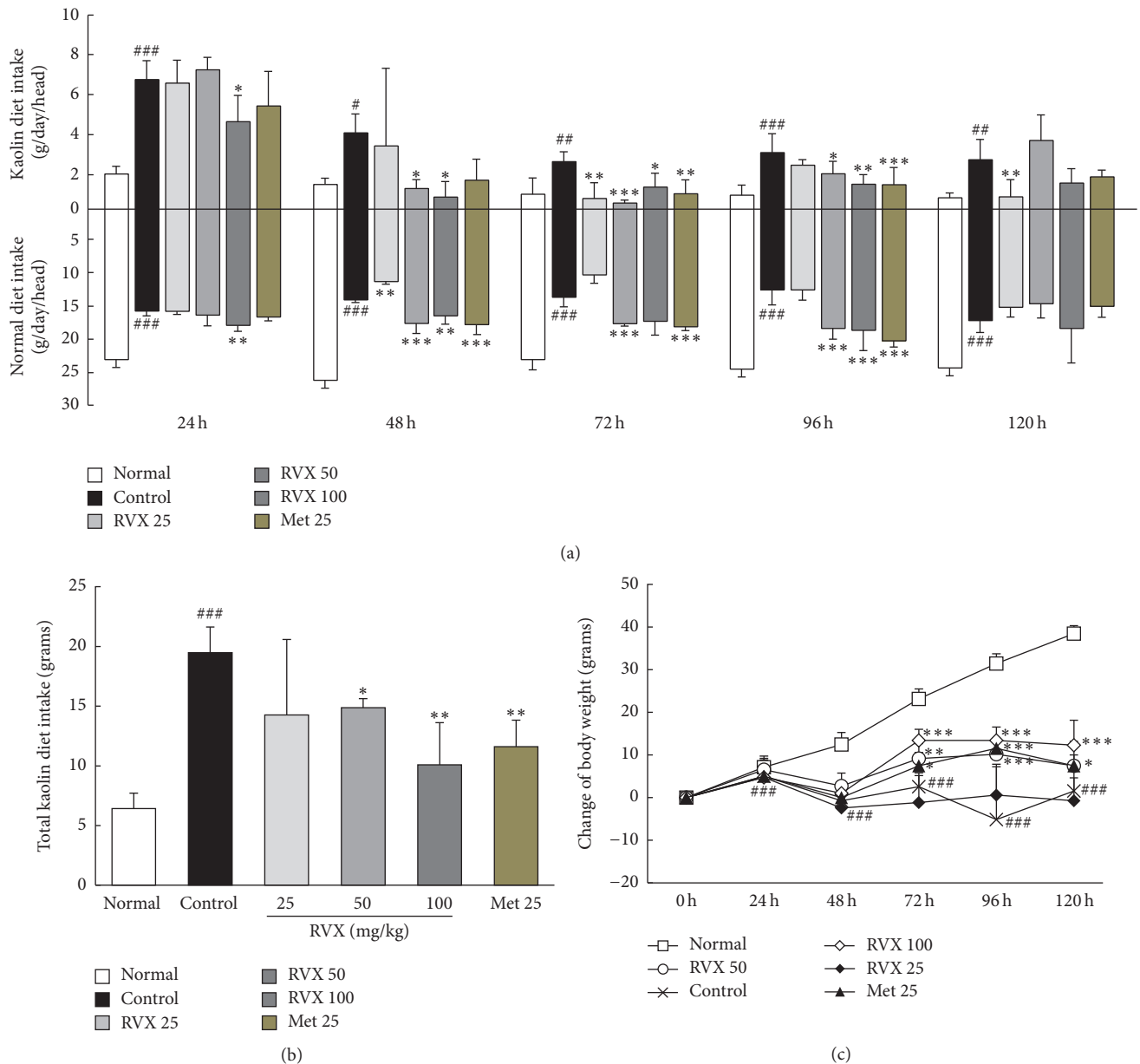


FIGURE 2: Kaolin consumption, normal diet consumption, and body weight change. The consumption of kaolin and a normal diet at different time points (a), total kaolin consumption (b), and body weight change (c) were monitored. Data are expressed as the mean \pm SD ($n = 6$). # $p < 0.05$, ## $p < 0.01$, and ### $p < 0.001$, compared with the normal group; * $p < 0.05$, ** $p < 0.01$, and *** $p < 0.001$, compared with the control group.

to the normal group by RVX treatment (especially 100 mg/kg, $p < 0.001$, Table 1). The counts of red blood cells and platelets and hemoglobin concentration were not notably affected by cisplatin injection. The lymphocyte count was improved by moderate level in the metoclopramide group.

3.8. Histopathological Findings for Bone Marrow Damage. H&E staining revealed that cisplatin injection considerably injured bone marrow tissue, as evidenced by loss of bone marrow cells and thinning of trabecular bone, compared with the normal group. These alterations (especially vacant

spaces in bone marrow) notably attenuated by RVX treatment compared with the control group ($p < 0.01$ or 0.001 , Figures 5(a) and 5(b)). Metoclopramide also improved those pathological alterations of bone marrow compared with the control group.

3.9. Changes of Spleen and Thymus Weights. Cisplatin injection considerably decreased the weights of both the thymus (0.5-fold) and spleen (0.6-fold), compared with the normal group; however, treatment with RVX (50 and 100 mg/kg) significantly attenuated these changes in organ weights

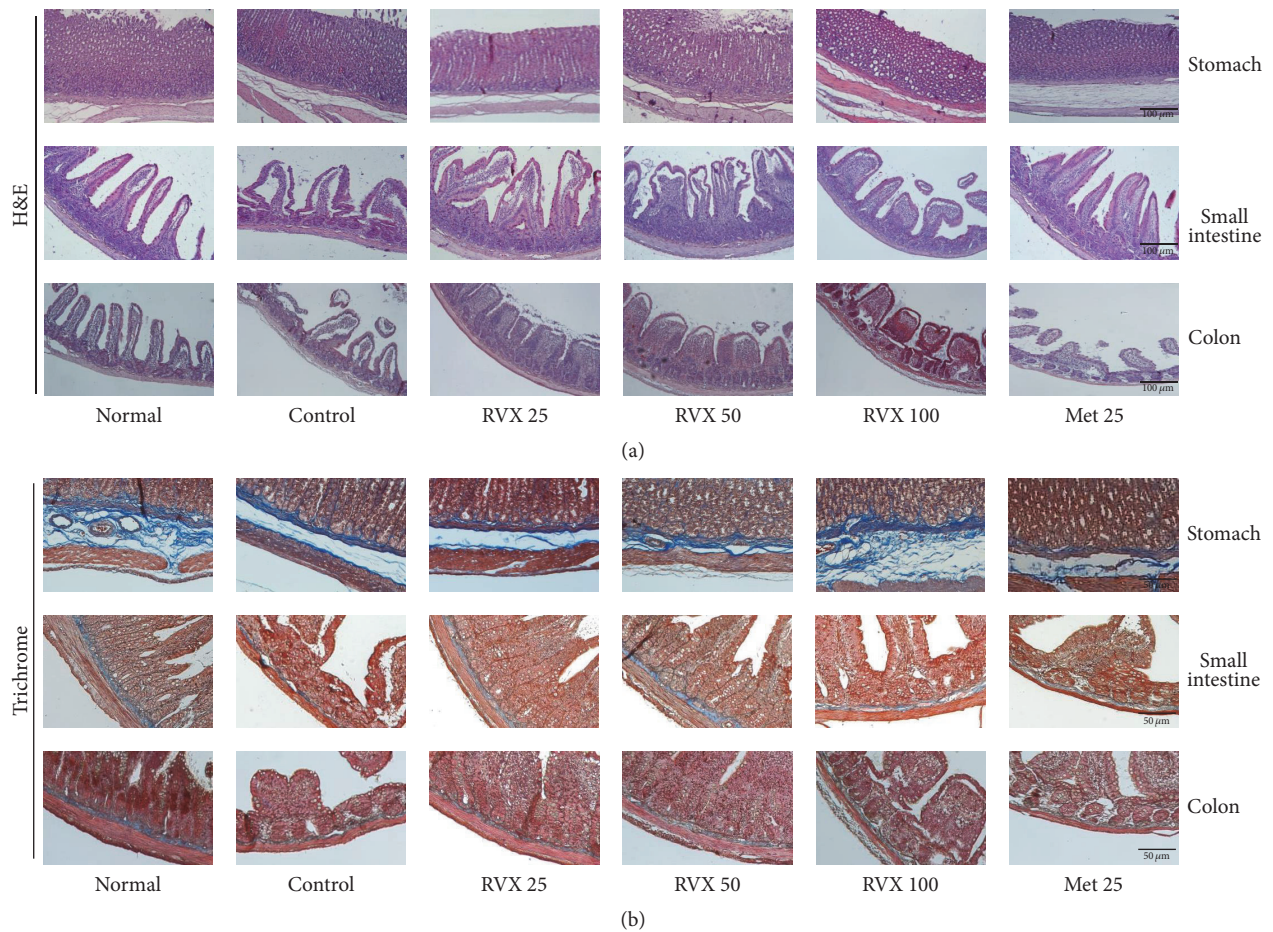


FIGURE 3: Histopathological findings of the gastrointestinal tract. H&E staining was conducted for the stomach, small intestine, and colon (a) and Masson's trichrome staining (b). The stained tissues were examined under a light microscope (200x magnification).

($p < 0.05$, 0.01, or 0.001) compared with the control group (Table 1). This positive finding was observed in the metoclopramide group, for thymus weight, but not spleen weight.

4. Discussion

R. verniciflua has been traditionally used to treat “blood stasis (瘀血)” which is associated with chronic diseases, including pain, stomach problem, and cancer, according to the theory of traditional Oriental medicine [14]. *R. verniciflua* was described in the herbal formulae extract part of traditional Chinese medicine literature (*Ben-cao-gang-mu*) for ameliorating gastro enteric dysfunctions [15]. Besides, *R. verniciflua* has been used to treat digestive troubles by adding it to chicken soup in traditional Korean medicine [20, 21]. Regarding the adverse effect of chemotherapy, particularly emesis, the pharmacological mechanisms of *R. verniciflua* still remain unclear. Herein, thus, we evaluated the pharmaceutical effects of *R. verniciflua* against cisplatin-induced adverse effects, especially gastrointestinal distortion. Cisplatin is an anticancer drug of a platinum-containing class used to treat various types of cancers, including sarcomas,

small cell lung cancer, ovarian cancer, and lymphomas, but it presents a number of side effects [22, 23]. Low reproducibility has frequently become an issue in pharmaceutical studies using herbal materials [24]. To minimize biased results due to poor quality of samples, we conducted fingerprint analysis and gene sequence-based vivification of the plant species, *R. verniciflua*.

As expected, a single injection of cisplatin remarkably increased the kaolin diet intake (increased emesis) and reduced the normal diet intake (increased anorexia) in the control group. Approximately 90% of the patients receiving cisplatin suffer from nausea and vomiting, and anorexia is also often accompanied by emesis in these patients [25]. This study adapted a pica model in which animals responded to emetic stimuli by consuming nonnutritive substances, such as kaolin [26]. The behavioral changes in food intake have frequently been assessed in animals incapable of vomiting [27]. In general, chemotherapy-induced emesis is divided into two phases: acute (24 h) and delayed (24–120 h), respectively [28], and RVX treatment ameliorated phases of emesis and anorexia.

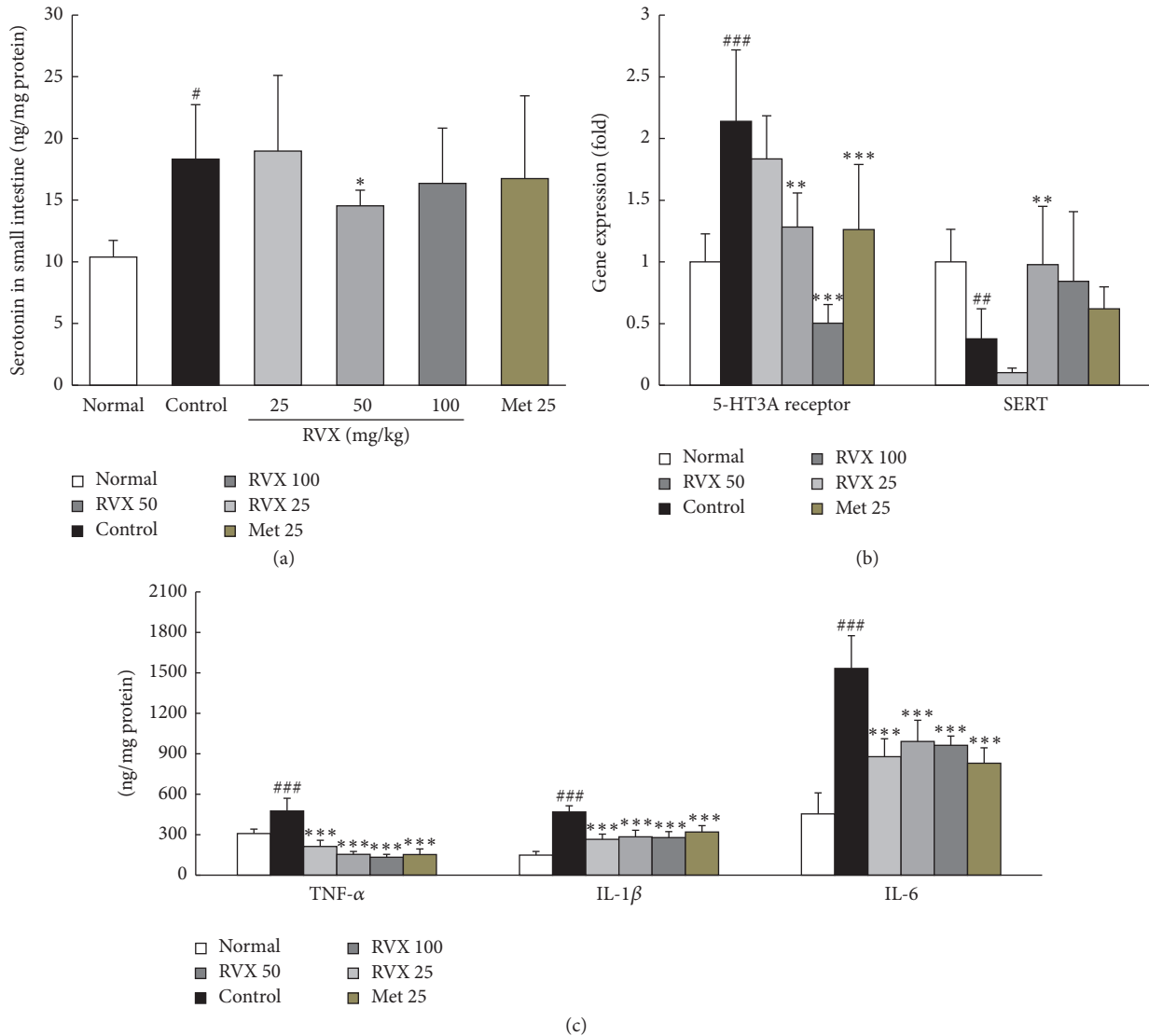


FIGURE 4: Serotonin and its related genes and proinflammatory cytokines. Serotonin concentrations in the small intestine were measured using ELISA (a). The gene expression levels of 5-HT3A receptor and SERT were measured using real-time PCR (b). Protein levels of TNF- α , IL-6, and IL-1 β (c) were performed using ELISA method. Data are expressed as the mean \pm SD ($n = 6$). * $P < 0.05$, ** $p < 0.01$, and *** $p < 0.001$ compared with the normal group; * $p < 0.05$, ** $p < 0.01$, and *** $p < 0.001$ compared with the control group.

The activation of 5-HT3 receptor with serotonin (5-HT) plays a key role in chemotherapy-induced-emesis [29]. Chemotherapy can induce 5-HT release from the enterochromaffin (EC) cells, consequently stimulating 5-HT3 receptor on the vagal nerve and resulting in the activation of the vomiting reflex [30]. As expected, RVX treatment significantly improved the cisplatin-induced upregulation of 5-HT3 receptor gene expression as well as the activated release of 5-HT in the intestine. Intestinal 5-HT is transported via SERT and then is metabolized in the epithelial cells of the gastrointestinal tract; therefore, damage to epithelial cells can impair the 5-HT metabolism, leading to prolonged contact time of 5-HT with 5-HT3 receptor [31]. RVX treatment normalized the downregulated gene expression of SERT in the intestine after cisplatin injection. Metoclopramide

25 mg/kg exerted antiemetic effects in only delayed phase, and it affected the gene expression of 5-HT3 receptor but not of SERT.

Histopathological findings showed severe gastrointestinal tract damage by cisplatin injection in our study, as evidenced by remarkable loss of villus cells, disruption of the epithelial architecture, and considerable reduction in collagen contents via H&E staining as well as trichrome staining. These alterations were more notable in the small intestine and colon than stomach; however, the stomach showed the intensive nuclei in a blue color, supposedly because of migration of gastric chief cells to the outer layer of the stomach lining. Gastric chief cells stain basophilic upon H&E staining owing to the large proportion of rough endoplasmic reticulum in its cytoplasm. These cells are generally located deep in the

TABLE 1: Hematologic parameters and organ weights.

| Parameters | Normal | Control | RVX 25 | RVX 50 | RVX 100 | Met 25 |
|--------------------------|---------------------|-----------------------------------|---------------------|-----------------------------------|----------------------------------|----------------------------------|
| WBC (k/ μ L) | 5.44 \pm 1.19 | 3.12 \pm 0.45 ^{###} | 3.20 \pm 0.61 | 3.87 \pm 0.63 | 5.59 \pm 1.62 ^{***} | 4.14 \pm 0.28 |
| Neutrophils (k/ μ L) | 0.52 \pm 0.12 | 0.68 \pm 0.24 | 0.62 \pm 0.25 | 0.73 \pm 0.18 | 1.01 \pm 0.33 | 0.93 \pm 0.60 |
| Lymphocytes (k/ μ L) | 4.73 \pm 1.06 | 2.27 \pm 0.43 ^{###} | 2.46 \pm 0.48 | 2.97 \pm 0.44 [*] | 4.33 \pm 1.23 ^{***} | 3.06 \pm 0.40 [*] |
| Monocytes (k/ μ L) | 0.03 \pm 0.02 | 0.04 \pm 0.01 | 0.04 \pm 0.04 | 0.05 \pm 0.02 | 0.13 \pm 0.06 ^{***} | 0.08 \pm 0.03 |
| Basophil (k/ μ L) | 0.01 \pm 0.00 | 0.03 \pm 0.02 [#] | 0.02 \pm 0.01 | 0.03 \pm 0.01 | 0.03 \pm 0.01 | 0.03 \pm 0.01 |
| Eosinophil (k/ μ L) | 0.05 \pm 0.05 | 0.08 \pm 0.06 [#] | 0.03 \pm 0.02 | 0.09 \pm 0.03 | 0.08 \pm 0.04 | 0.05 \pm 0.02 |
| RBC (m/ μ L) | 7.58 \pm 0.37 | 7.09 \pm 0.20 [#] | 6.89 \pm 0.67 | 7.31 \pm 0.27 | 7.31 \pm 0.10 | 7.16 \pm 0.23 |
| Hemoglobin (g/dL) | 14.68 \pm 1.17 | 14.45 \pm 0.71 | 14.40 \pm 1.60 | 14.75 \pm 0.55 | 15.35 \pm 0.73 | 14.68 \pm 0.56 |
| Platelet (k/ μ L) | 1091.50 \pm 31.89 | 907.75 \pm 173.30 | 661.00 \pm 302.11 | 1191.75 \pm 330.96 [*] | 1189.50 \pm 46.26 [*] | 1138.75 \pm 139.90 |
| Thymus weight (g) | 0.67 \pm 0.11 | 0.34 \pm 0.08 ^{###} | 0.34 \pm 0.05 | 0.46 \pm 0.06 ^{**} | 0.50 \pm 0.03 ^{***} | 0.48 \pm 0.06 ^{**} |
| (Relative%) | (0.24 \pm 0.04) | (0.15 \pm 0.04 ^{###}) | (0.17 \pm 0.02) | (0.20 \pm 0.02 ^{**}) | (0.22 \pm 0.01 ^{**}) | (0.21 \pm 0.04 ^{**}) |
| Spleen weight (g) | 0.81 \pm 0.10 | 0.50 \pm 0.03 ^{###} | 0.47 \pm 0.02 | 0.59 \pm 0.10 [*] | 0.60 \pm 0.05 [*] | 0.58 \pm 0.07 |
| (Relative%) | (0.31 \pm 0.04) | (0.24 \pm 0.02 ^{###}) | (0.22 \pm 0.02) | (0.24 \pm 0.01) | (0.27 \pm 0.02 [*]) | (0.25 \pm 0.02) |

Data are expressed as the mean SD ($n = 6$). [#] $p < 0.05$ and ^{###} $p < 0.001$, compared with normal group; ^{*} $p < 0.05$, ^{**} $p < 0.01$, and ^{***} $p < 0.001$, compared with control group. WBC: white blood cell; RBC: red blood cell.

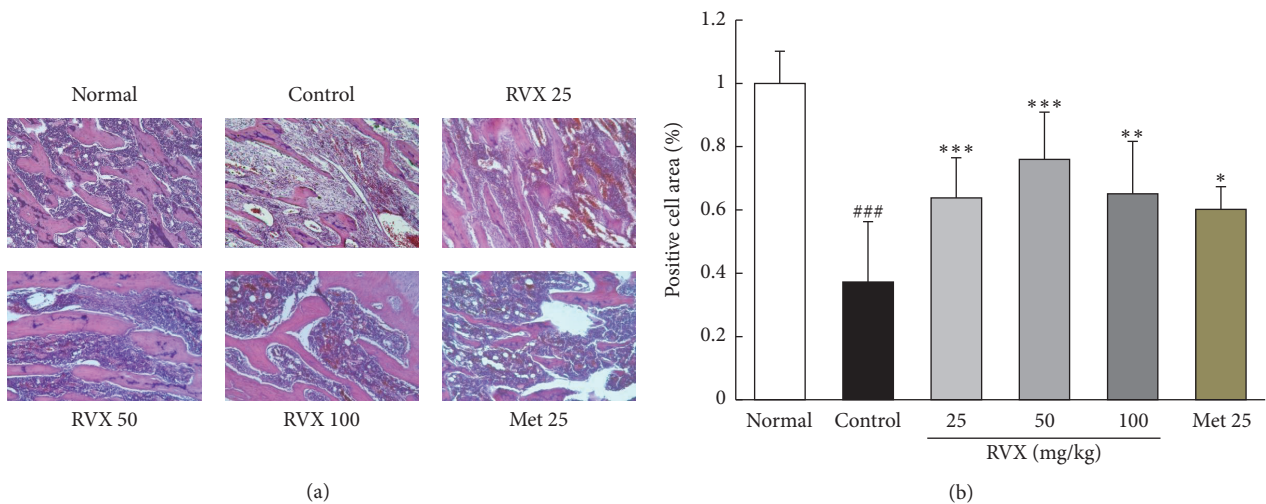


FIGURE 5: Histopathological finding of bone marrow. H&E staining was conducted for bone marrow, and the results were examined under a light microscope (200x magnification) (a). The positive cells area was quantitatively analyzed using Image J software, version 1.64 (b). Data are expressed as the mean \pm SD ($n = 6$). ^{###} $p < 0.001$ compared with the normal group; ^{*} $p < 0.05$, ^{**} $p < 0.01$, and ^{***} $p < 0.001$ compared with control group.

mucosal layer of the stomach lining; the gastric chief cells then move into outer layer in response to inflammation [32]. This alteration was notably attenuated in groups treated with RVX, but not metoclopramide treatment. Chemotherapy treatment with cisplatin is also well known for provoking the gastritis [33]. While proinflammatory cytokines, including TNF- α , IL-6, and IL-1 β , were remarkably elevated in stomach tissue, these abnormal elevations of these three cytokines were significantly improved by RVX treatment in our results.

On the other hand, bone marrow is one of the most fragile organs during chemotherapy. Myelosuppression increases the risk of infection, fatigue, and diminished quality of life (QoL) in patients; thus, it is a major dose-limiting

factor for the clinical use of chemotherapy [34]. Moreover, myelosuppression, for instance, leukopenia, is primarily the reason for the delay, reduction, or cessation of chemotherapy treatment, occurring in approximately 15% of total cases of chemotherapy [35]. Our previous study reported that the most severe leukopenia was observed at 5 days after a single cisplatin injection rat model [36]. As we expected, notable bone marrow suppression and leukopenia were observed 5 days after cisplatin injection, and these pathologic conditions were considerably reserved by RVX treatment, especially at the highest dose of 100 mg/kg. In addition to the bone marrow, the spleen and thymus are representative immune organs, and losses in their weights in experimental models

of cisplatin injection have been widely reported [37], significantly attenuated by RVX treatment in our current study. These findings anticipated that RVX may have potential for use against immunosuppression caused by chemotherapy. The current results are in accordance with previous study, which RVS ameliorated significantly the cisplatin-induced adverse effects on liver and kidney functions in colon cancer cell (CT-26 cell line) injected tumor model [38].

Taken together, the current study reported for the first time comprehensive effects of *R. verniciflua* on the side effects of chemotherapy, mainly focusing on emesis and immunosuppression. In addition, modulation of 5-HT₃ receptor is suggested to be an underlying mechanism of the antiemetic effects of *R. verniciflua*.

Competing Interests

The authors declare no competing financial interests.

Authors' Contributions

Hyo-Seon Kim and Hyeong-Geug Kim mainly wrote the manuscript text and conducted experiments. Sung-Bae Lee and Jin-Seok Lee performed the gene sequencing analysis of the *R. verniciflua* (Figure 1(c)). Hye-Won Lee, Sam-Keun Lee, and Chang Kyu Byun analyzed the fingerprinting analysis in Figures 1(a) and 1(b) (HPLC analysis). Won-Yong Kim prepared the *R. verniciflua* extract and reported behavioral test for kaolin diet and normal diet intake. Hwi-Jin Im supported the histopathological findings such as H&E and Masson's trichrome staining. Chang-Gue Son supervised the manuscript and directed final version of all contents. All authors reviewed and approved this manuscript. Hyo-Seon Kim and Hyeong-Geug Kim equally contributed to the current study.

Acknowledgments

This research was supported by the "Leaders Industry-University Cooperation" Project of the Ministry of Education, Science and Technology and a grant of from the Traditional Korean Medicine R&D Project, Ministry of Health & Welfare, Republic of Korea (H112C-1920-010014 and H115C-0112-000015).

References

- [1] J. Ferlay, I. Soerjomataram, R. Dikshit et al., "Cancer incidence and mortality worldwide: sources, methods and major patterns in GLOBOCAN 2012," *International Journal of Cancer*, vol. 136, no. 5, pp. E359–E386, 2015.
- [2] L. Nunnery, C. C. Maley, M. Breen, M. E. Hochberg, and J. D. Schiffman, "Peto's paradox and the promise of comparative oncology," *Philosophical Transactions of the Royal Society B: Biological Sciences*, vol. 370, no. 1673, 2015.
- [3] C. C. Murphy, L. C. Harlan, J. L. Lund, C. F. Lynch, and A. M. Geiger, "Patterns of colorectal cancer care in the United States: 1990–2010," *Journal of the National Cancer Institute*, vol. 107, no. 10, 2015.
- [4] L. Zitvogel, L. Apetoh, F. Ghiringhelli, and G. Kroemer, "Immunological aspects of cancer chemotherapy," *Nature Reviews Immunology*, vol. 8, no. 1, pp. 59–73, 2008.
- [5] M. T. Halpern and K. R. Yabroff, "Prevalence of outpatient cancer treatment in the United States: Estimates from the Medical Panel Expenditures Survey (MEPS)," *Cancer Investigation*, vol. 26, no. 6, pp. 647–651, 2008.
- [6] Y. H. Yun, M. Kwak, S. M. Park et al., "Chemotherapy use and associated factors among cancer patients near the end of life," *Oncology*, vol. 72, no. 3-4, pp. 164–171, 2008.
- [7] A. M. Griffin, P. N. Butow, A. S. Coates et al., "On the receiving end V: patient perceptions of the side effects of cancer chemotherapy in 1993," *Annals of Oncology*, vol. 7, no. 2, pp. 189–195, 1996.
- [8] K. Jenns, "Importance of nausea," *Cancer Nursing*, vol. 17, no. 6, pp. 488–493, 1994.
- [9] C. Morran, D. C. Smith, D. A. Anderson, and C. S. McArdle, "Incidence of nausea and vomiting with cytotoxic chemotherapy: a prospective randomised trial of antiemetics," *British Medical Journal*, vol. 1, no. 6174, pp. 1323–1324, 1979.
- [10] K. Jordan, C. Sippel, and H.-J. Schmoll, "Guidelines for antiemetic treatment of chemotherapy-induced nausea and vomiting: past, present, and future recommendations," *Oncologist*, vol. 12, no. 9, pp. 1143–1150, 2007.
- [11] R. Mahesh, R. V. Perumal, and P. V. Pandi, "Cancer chemotherapy-induced nausea and vomiting: role of mediators, development of drugs and treatment methods," *Pharmazie*, vol. 60, no. 2, pp. 83–96, 2005.
- [12] S. Goodin and R. Cunningham, "5-HT₃-receptor antagonists for the treatment of nausea and vomiting: a reappraisal of their side-effect profile," *Oncologist*, vol. 7, no. 5, pp. 424–436, 2002.
- [13] U. Haus, M. Späth, and L. Färber, "Spectrum of use and tolerability of 5-HT₃ receptor antagonists," *Scandinavian Journal of Rheumatology*, vol. 33, supplement 117, pp. 12–18, 2009.
- [14] J. H. Kim, Y. C. Shin, and S.-G. Ko, "Integrating traditional medicine into modern inflammatory diseases care: multitargeting by rhus verniciflua stokes," *Mediators of Inflammation*, vol. 2014, Article ID 154561, 17 pages, 2014.
- [15] L. Shizhen, *Compendium of Materia Medica (Bencao Gangmu)*, Foreign Languages Press, Beijing, China, 2006.
- [16] J. E. Moon, J.-H. Shin, O. Kwon, and J. Y. Kim, "A standardized extract of rhus verniciflua stokes protects wistar rats against lipopolysaccharide-induced acute inflammation," *Journal of Medicinal Food*, vol. 18, no. 11, pp. 1223–1230, 2015.
- [17] P.-S. Oh, S.-J. Lee, and K.-T. Lim, "Hypolipidemic and antioxidative effects of the plant glycoprotein (36 kDa) from Rhus verniciflua stokes fruit in triton WR-1339-induced hyperlipidemic mice," *Bioscience, Biotechnology and Biochemistry*, vol. 70, no. 2, pp. 447–456, 2006.
- [18] K.-C. Choi, W.-T. Chung, J.-K. Kwon et al., "Chemoprevention of a flavonoid fraction from Rhus verniciflua Stokes on aflatoxin B1-induced hepatic damage in mice," *Journal of Applied Toxicology*, vol. 31, no. 2, pp. 150–156, 2011.
- [19] H. R. B. Raghavendran, S. Rekha, J.-W. Shin et al., "Effects of Korean ginseng root extract on cisplatin-induced emesis in a rat-pica model," *Food and Chemical Toxicology*, vol. 49, no. 1, pp. 215–221, 2011.
- [20] J. H. Kim, H.-P. Kim, C.-H. Jung et al., "Inhibition of cell cycle progression via p27Kip1 upregulation and apoptosis induction by an ethanol extract of Rhus verniciflua Stokes in AGS gastric cancer cells," *International Journal of Molecular Medicine*, vol. 18, no. 1, pp. 201–208, 2006.

- [21] J.-S. Shin, Y. M. Park, J.-H. Choi et al., "Sulfuretin isolated from heartwood of *Rhus verniciflua* inhibits LPS-induced inducible nitric oxide synthase, cyclooxygenase-2, and pro-inflammatory cytokines expression via the down-regulation of NF- κ B in RAW 264.7 murine macrophage cells," *International Immunopharmacology*, vol. 10, no. 8, pp. 943–950, 2010.
- [22] D. Lebowhl and R. Canetta, "Clinical development of platinum complexes in cancer therapy: an historical perspective and an update," *European Journal of Cancer*, vol. 34, no. 10, pp. 1522–1534, 1998.
- [23] G. Sassi, B. Striano, and U. A. Merlo, "A reporting system for the assessment of chemotherapy toxicity," *Journal of Oncology Pharmacy Practice*, vol. 11, no. 2, pp. 63–67, 2005.
- [24] J. Zhang, B. Wider, H. Shang, X. Li, and E. Ernst, "Quality of herbal medicines: challenges and solutions," *Complementary Therapies in Medicine*, vol. 20, no. 1-2, pp. 100–106, 2012.
- [25] K. Nelson, D. Walsh, and F. Sheehan, "Cancer and chemotherapy-related upper gastrointestinal symptoms: the role of abnormal gastric motor function and its evaluation in cancer patients," *Supportive Care in Cancer*, vol. 10, no. 6, pp. 455–461, 2002.
- [26] N. Takeda, S. Hasegawa, M. Morita, and T. Matsunaga, "Pica in rats is analogous to emesis: an animal model in emesis research," *Pharmacology, Biochemistry and Behavior*, vol. 45, no. 4, pp. 817–821, 1993.
- [27] P. L. R. Andrews and C. C. Horn, "Signals for nausea and emesis: implications for models of upper gastrointestinal diseases," *Autonomic Neuroscience: Basic & Clinical*, vol. 125, no. 1-2, pp. 100–115, 2006.
- [28] S. M. Grunberg, R. R. Deuson, P. Mavros et al., "Incidence of chemotherapy-induced nausea and emesis after modern antiemetics," *Cancer*, vol. 100, no. 10, pp. 2261–2268, 2004.
- [29] L. X. Cubeddu, I. S. Hoffmann, N. T. Fuenmayor, and J. J. Malave, "Changes in serotonin metabolism in cancer patients: its relationship to nausea and vomiting induced by chemotherapeutic drugs," *British Journal of Cancer*, vol. 66, no. 1, pp. 198–203, 1992.
- [30] L. X. Cubeddu, "Serotonin mechanisms in chemotherapy-induced emesis in cancer patients," *Oncology*, vol. 53, supplement 1, pp. 18–25, 1996.
- [31] M. D. Gershon, "Review article: serotonin receptors and transporters—roles in normal and abnormal gastrointestinal motility," *Alimentary Pharmacology & Therapeutics*, vol. 20, supplement 7, pp. 3–14, 2004.
- [32] A. B. Rogers and J. G. Fox, "Inflammation and Cancer. I. Rodent models of infectious gastrointestinal and liver cancer," *American Journal of Physiology—Gastrointestinal and Liver Physiology*, vol. 286, no. 3, pp. G361–G366, 2004.
- [33] S. Sartori, I. Nielsen, A. Maestri, D. Beltrami, L. Trerisani, and P. Pazzi, "Acute gastroduodenal mucosal injury after cisplatin plus etoposide chemotherapy: clinical and endoscopic study," *Oncology*, vol. 48, no. 5, pp. 356–361, 1991.
- [34] L. Montoya, "Managing hematologic toxicities in the oncology patient," *Journal of Infusion Nursing*, vol. 30, no. 3, pp. 168–172, 2007.
- [35] M. Okera, S. Chan, U. Dernede et al., "A prospective study of chemotherapy-induced febrile neutropenia in the South West London Cancer Network. Interpretation of study results in light of NCAG/NCEPOD findings," *British Journal of Cancer*, vol. 104, no. 3, pp. 407–412, 2011.
- [36] J.-Y. Son, J.-W. Shin, J.-H. Wang et al., "Chemotherapy-induced myelotoxicity and incidence of lung metastasis in an animal model," *Human and Experimental Toxicology*, vol. 30, no. 7, pp. 649–655, 2011.
- [37] Y. Kouchi, Y. Maeda, A. Ohuchida, and M. Ohsawa, "Immunotoxic effect of low dose cisplatin in mice," *Journal of Toxicological Sciences*, vol. 21, no. 4, pp. 227–233, 1996.
- [38] J.-H. Lee, H.-J. Lee, H.-J. Lee et al., "*Rhus verniciflua* Stokes prevents cisplatin-induced cytotoxicity and reactive oxygen species production in MDCK-I renal cells and intact mice," *Phytomedicine*, vol. 16, no. 2-3, pp. 188–197, 2009.