

Flap Reconstruction for Esophageal Perforation Complicating Anterior Cervical Spinal Fusion: An 18-year Experience

Philip J. Hanwright, BA
Chad A. Purnell, MD
Gregory A. Dumanian, MD

Background: Esophageal injury following anterior cervical discectomy and fusion (ACDF) poses a significant reconstructive challenge. Buttressing flap repairs have proven beneficial; however, there remains a paucity of evidence to guide optimal flap selection.

Methods: A retrospective chart review was performed for patients who presented to the senior author with esophageal perforations after ACDF from 1995 until present. Demographic, clinical, and postoperative details were collected. Outcomes of omental flap reconstructions were compared against other flap reconstructions.

Results: A total of 13 flap reconstructions were performed in 11 patients with the following distribution: 7 free omental, 1 anterolateral thigh, 1 osteomuscular fibula, 2 radial forearm, and 2 pedicled pectoralis flaps. Patients receiving omental flap reconstructions demonstrated a significantly faster resolution of leak on contrast swallow imaging and earlier return to oral feeding compared with all other flap reconstructions (22.5 versus 268 days, respectively; $P < 0.05$). This relationship remained evident even when calculations excluded an outlying patient from the nonomental cohort (22.5 versus 111 days, respectively; $P < 0.05$). Length of hospital stay, complications, and success rates were also more favorable in the omental cohort but failed to reach statistical significance.

Conclusions: Esophageal perforation after ACDF is an uncommon but devastating complication. The use of free omentum flap reconstruction is associated with a more rapid functional recovery and may prove beneficial in the management of these challenging cases. (*Plast Reconstr Surg Glob Open* 2015;3:e400; doi: 10.1097/GOX.0000000000000350; Published online 15 May 2015.)

Anterior cervical discectomy and fusion (ACDF) is a common surgical intervention in the treatment of traumatic and degenerative changes of the spine. Esophageal injury is a rare but

devastating complication of ACDF, with a reported incidence of approximately 1%.^{1,2} The pattern of esophageal injuries after ACDF is bimodal. Iatrogenic injuries typically present early in the perioperative period, whereas late perforations are generally ascribed to soft-tissue erosion of the posterior esophagus by spinal hardware, bone grafts, or osteophytes.

The management of esophageal perforations remains a significant reconstructive challenge as a poor intrinsic blood supply, contamination, and flow of saliva through the perforation impair wound healing. In the setting of ACDF, treatment is further confounded

From the Division of Plastic and Reconstructive Surgery, Northwestern University, Feinberg School of Medicine, Chicago, Ill. Received for publication September 29, 2014; accepted March 17, 2015.

Copyright © 2015 The Authors. Published by Wolters Kluwer Health, Inc. on behalf of The American Society of Plastic Surgeons. All rights reserved. This is an open-access article distributed under the terms of the Creative Commons Attribution-NonCommercial-NoDerivatives 3.0 License, where it is permissible to download and share the work provided it is properly cited. The work cannot be changed in any way or used commercially.

DOI: 10.1097/GOX.0000000000000350

Disclosure: *The authors have no financial interest to declare in relation to the content of this article. The Article Processing Charge was paid for by the Northwestern University Division of Plastic Surgery.*

as the native soft-tissue surroundings have been replaced by a more hostile postoperative milieu of scar, unyielding bone and bone graft, and exposed metal. In cases where adequate bony fusion has not yet occurred, fixation hardware must often remain in place, which can complicate bacterial eradication and impose repetitive friction and persistent pressure upon an already tenuous posterior esophagus. Finally, unlike head and neck cancer esophageal reconstructions, there is minimal surgical room to maneuver to expose and repair these perforations.

Primary closure has been successful in select cases; however, high rates of recurrence led to the development of reinforced primary repairs with vascularized tissue flaps incorporated into the reconstruction.³⁻⁶ Flap interposition serves to bolster against further erosion, increases antibiotic delivery, contains leaks, and is associated with decreased rates of recurrence and earlier reintroduction of oral feedings.^{3,7-9}

Grillo and Wilkins⁶ first described the concept of a buttressed esophageal repair using vascularized pleural flaps for thoracic perforations, and since this introduction, a myriad of flaps have been utilized, including pedicled pectoralis major,^{8,10-14} sternocleidomastoid (SCM),^{3,4,11,15-19} longus colli,²⁰ free radial forearm,^{8,11,14} and omental¹⁰ flaps. Given the low incidence of this complication, there remains a paucity of data and lack of consensus regarding optimal flap selection. Given the significant nature of esophageal perforations, with reports of up to 18% mortality, it is an important problem to address.⁵

In this article, we present our experience with 18 years of flap reconstruction for perforation in the context of ACDF. We intend to describe our surgical technique, lessons learned, and how our practice has evolved in the care of this challenging problem.

MATERIALS AND METHODS

Study Design

After obtaining ethical approval from the Northwestern Institutional Review Board, we carried out a retrospective chart review of all patients presenting to the senior author (G.A.D.) with an esophageal perforation after ACDF from 1995 to present. Nominal variables were compared using Fisher's exact test. Interval variables were compared using the Mann-Whitney *U* test. All data analyses were performed using IBM SPSS Statistics (IBM Corporation, Armonk, N.Y.).

Preoperative Planning and Management

The presentation and diagnosis of esophageal perforations has previously been described extensively.⁵ Comprehensive management requires a

multidisciplinary team approach comprising spinal surgeons, otolaryngology or thoracic surgeons, plastic surgeons, and infectious disease physicians. Patients presenting with acute infection should initially be managed with incision and drainage, culture-directed antibiotics, and cessation of oral feeding. Early involvement of infectious disease colleagues is paramount, as osteomyelitis and surgical hardware can complicate bacterial clearance. Fever and pain are usually ameliorated with drain placement, although caution is warranted as cultures from drain fluid can be nonspecific secondary to contamination. Prior to flap coverage, it is often helpful to obtain a water-soluble contrast swallow to help to identify the location of the leak. Flap reconstruction is generally performed within the first week after acute infection and local tissue inflammation has begun to resolve.

Surgical Technique and Postoperative Care

Our preferred method of omental free flap harvesting follows previously described techniques.^{21,22} In brief, for patients who do not require a bone reconstruction and do not have a "hostile" abdomen, an upper midline or right paramedian abdominal incision is made. This incision also allows access for gastrostomy tube placement. The omentum is identified and dissected bluntly from the transverse colon and mesocolon. Meticulous attention must be paid to not injure or elevate the middle colic artery with the flap. The size of omentum to be harvested is based in part on the thickness of the omentum and the composition of vascular arcades. Splitting the omentum between vascular arcades and leaving the left side in continuity with the stomach is protective for the abdominal closure and lessens the chance of bleeding from connections to the spleen. Ideally, 2 or 3 omental vascular arcades, and the tissue in between, are taken. The short gastric vessels are identified from the greater curvature of the stomach and divided with clamps and ties. The omentum is then isolated on the right gastroepiploic vessels and readied for microvascular anastomosis (Fig. 1). Concurrently, a second team of otolaryngology and spinal surgeons expose the posterior esophagus and anterior cervical spine. The esophageal defects tend to be small and less than 1 cm in size. All attempts must be made to identify the perforation and to repair it primarily with 3-0 polydioxanone suture. Even smaller pinhole leaks that allow egress of saliva during the high pressure phase of swallowing will not seal despite placement of a flap and need to be identified for suture closure. If necessary, the esophagus should be opened further to completely and unequivocally identify the perforation for suture closure. Methylene blue and esophagoscopy are useful adjuncts for

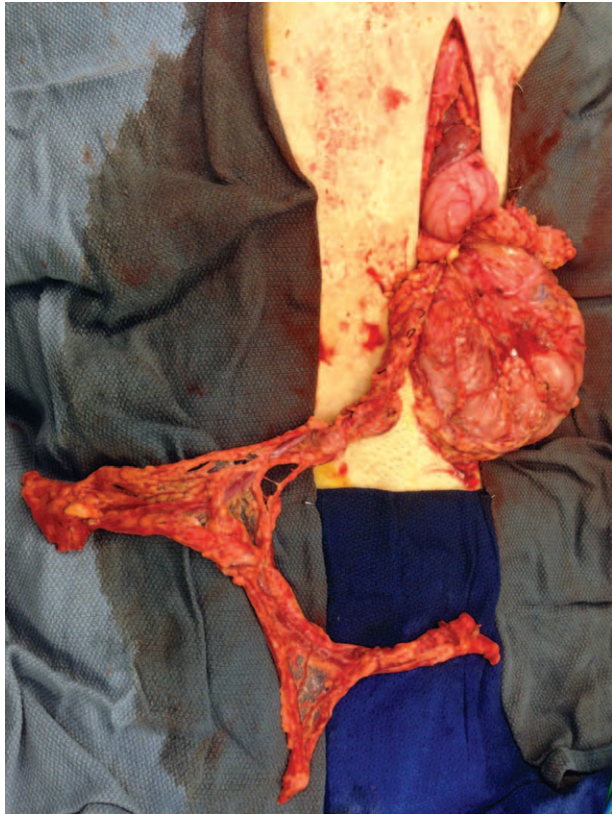


Fig. 1. Omental flap harvest demonstrating the thin, pliable nature of the tissue, which enables surgeons to completely encase esophageal defects.

locating perforations. Only 1 patient (case 5) had a defect large enough (approximately 2 cm in diameter) to permit a “patch” repair with the epithelium of a radial forearm flap. The area is copiously irrigated, and hardware is removed if possible. The omentum is brought into the operative field, and microvascular anastomoses are performed to available recipient vessels. One should proceed on the side of the original spine dissection, and not open the opposite neck, for protection of the unscarred laryngeal nerve. Surgery is more difficult than head and neck reconstructions for cancer, as the vessels are not skeletonized and there is little extra room to place the flap bulk—hence, the reason for a thin small flap. After a cervical spine fusion, neck mobility may not be full, and therefore, the entire patient may need to be angled to allow for positioning of the microscope. Inset is usually performed with omentum wrapping the posterior esophageal repair and separating the esophagus from the cervical spine with vascularized tissue. The omentum should be inset with parachuted sutures placed into the scarred tissues on the side opposite of the leak to ensure complete coverage of the bone. A Penrose or closed suction drain is left in place, and a small portion of omentum can be left

outside the skin for flap monitoring. This monitoring tissue is excised several weeks postoperatively. Venous implantable Dopplers were used for the majority of flaps for monitoring.

Postoperatively, patients are monitored in the intensive care unit for at least 24 hours. The patient is given a suction tube for spitting rather than swallowing saliva. Tube feeds are begun upon the return of bowel function through a gastrostomy tube. A water-soluble contrast swallow with fluoroscopy is scheduled 10–14 days postoperatively if there is no evidence of salivary leakage into the cervical drain. If the swallow study shows no evidence of leak, the patient is begun on a clear liquid diet. A follow-up swallow study is ordered for advancement of a mechanically soft diet 2–3 weeks later. Patients are continued on parenteral antibiotics at the discretion of infectious disease consultants postoperatively. The length of antibiotic treatment depends on the presence or absence of osteomyelitis of the vertebral bodies. Patients with contained leaks are maintained on sips of clear liquids and followed with repeated swallow studies 2–3 weeks later.

RESULTS

A summary of patient data is shown in Table 1. There were 13 flaps performed in a total of 11 patients with esophageal perforation after ACDF. In 2 patients, a second flap was performed due to failure of the first flap to resolve the leak (Fig. 2). Free flaps utilized included omentum (7), anterolateral thigh (1), osteomuscular fibula (1), and radial forearm (2). Two pedicled pectoralis flaps were performed. Mean age at the time of flap reconstruction was 42 ± 19.6 years. There were 3 acute to subacute presentations, and the remaining presented late, ranging from 76 to 1543 days postoperatively from the most recent ACDF, with a mean of 455 days. Patients had a mean of 1 washout between diagnosis of perforation and flap reconstruction. In a majority of cases (11), hardware was removed or had been previously removed. In 1 case (an omental flap), hardware was not removed due to concerns of complete loss of bony stability in an acute perforation. This hardware was successfully salvaged. In 1 case, a vascularized fibula flap was placed with hardware to provide spinal stability after severe vertebral body loss from osteomyelitis. There were no partial or total flap losses, and no patient was returned to the operating room for a microvascular salvage. A comparison of time to oral feeding, hospital length of stay, and nonflap complications is presented in Table 2. In the patient (no. 6) who underwent anterolateral thigh flap reconstruction, oral feeding was not initi-

Table 1. Summary of Patient Characteristics and Management

Patient No.	Age (y)	Sex	ACDF Indication	Fixation Level	Time to Presentation (d)	Flap Type	Complications	Time to Oral Feeding (d)	Length of Hospital Stay (d)	Procedure Success
1	78	Male	Osteoarthritis	C5-7	97	Pedicle pectoralis	—	60	30	Yes
2	18	Male	Trauma	C4-C6	43	Omentum	—	15	17	Yes
3	17	Male	Trauma	C6-7	76	Pedicle pectoralis	—	135	50	Yes
4	19	Male	Trauma	C4-7	210	Omentum	—	10	14	Yes
5	60	Female	Trauma, revision	C3-C6	866	Radial forearm myofascial	Pneumonia	138	35	Yes
6	46	Female	Trauma, revision	C6-T1	518	Fibula osteomuscular	Urinary tract infection	NA	19	No
6 (flap 2)	47	Female	"	"	654	Anterolateral thigh	—	739	6	No
7	41	Female	Osteoarthritis	C5-6	1543	Radial forearm	G-tube leak	NA	7	No
7 (flap 2)	41	Female	"	"	91	Omentum	—	14	4	Yes
8	60	Male	Osteoarthritis, revision	C2-C5	10	Omentum	Pneumonia	47	28	Yes
9	18	Male	Trauma	C3-7	76	Omentum	—	Unknown	13	No
10	45	Male	Osteoarthritis	C5-6	112	Omentum	—	13	6	Yes
11	60	Male	Osteoarthritis	C5-C7	42	Omentum	—	36	10	Yes

Patients are organized chronologically by year of presentation, earliest to most recent. NA, not available. ", same as above

ated until 739 days postoperatively due to a persistent leak. With this outlying patient removed from calculations, the mean time until oral intake in the nonomentum group was 111 days, which is still significantly longer than the omental cohort (111 versus 22.5 days, respectively; $P=0.01$). Nonflap-related complications included a urinary tract infection, a gastrostomy tube leak requiring an exploratory laparotomy, a ventilator-associated pneumonia in the nonomentum group, and a ventilator-associated pneumonia in the omental flap group. Procedure success was defined as the resolution of clinically evident esophageal leaks and the ability to resume oral feeding. Four of the esophageal flap closures (3 patients) were defined to have failed. Case 6 underwent a free fibula flap for bony reconstruction of an osteomyelitic cervical spine due to the esophageal perforation after ACDF. Flexor hallucis longus was used to buttress the esophageal closure. Persistent esophageal drainage led to a subsequent anterolateral thigh flap buttressed esophageal repair that also leaked. This persistent leak eventually walled off into a cavity, allowing the patient to tolerate limited oral feedings on day 739. Case 7 underwent a free radial forearm flap to place vascularized soft tissue against a pinhole leak of the esophagus that could not be identified. The patient continued to leak saliva for 3 additional months until she was reexplored for closure of the esophageal perforation and successful placement of an omental flap. The omental vessels were anastomosed to the pedicle of the radial forearm as a confirmation of the patency of the original flap. Case 9, an omental flap reconstruction, never underwent an esophageal swallow study due to persistent aspiration. This patient was eventually lost to follow-up and definitive healing could not be confirmed. As such, this reconstruction was considered unsuccessful for data analysis purposes.

DISCUSSION

Esophageal perforations in the setting of ACDF continue to pose significant reconstructive challenges, and a lack of consensus remains regarding optimal surgical management. This study reviews our 18-year experience managing these complex cases and represents the largest case series to our knowledge.

The successful management of all types of esophageal leaks is predicated on 3 key factors: the restoration of gastrointestinal integrity, infectious control, and spinal stability. Conservative measures are essential and include the early use of broad-spectrum antibiotics, cessation of oral feeding, and nutritional support.^{5,16} However, conservative treatment alone

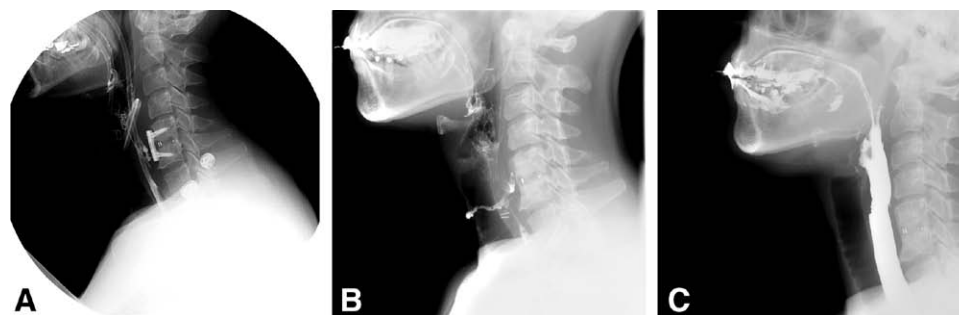

Fig. 2. Lateral preoperative and postoperative fluoroscopic imaging of a late presenting cervical esophageal perforation. A, Preoperative presentation demonstrating an esophageal leak and persistent fluid collection adjacent to the surgical hardware. B, Postoperative imaging attained 2 months after a radial forearm flap reconstruction with evidence of a persistent leak. C, Imaging attained 14 days after a second reconstructive operation using omentum. Definitive closure of the leak is noted.

was found to yield high rates of infectious complications and a 17% mortality rate in the largest review of all-cause esophageal perforations to date.⁵ Comparatively, surgical intervention in addition to conservative measures reduced mortality to 12%, and as such, represents the gold standard.^{3,5,14,23}

Leaks after ACDF are a distinct and separate subset from the larger group of all esophageal perforations. The soft-tissue bed comprised scarred bone and therefore was unlikely to contract against the leaking esophagus to achieve closure over time. Leaks from the esophagus after cancer resections are also quite distinct, due to the wide-open surgical fields present to affect a direct epithelium-to-epithelium closure with the skin paddle of a flap. For these ACDF-related cases, the esophagus should be primarily closed to achieve a closed gastrointestinal lumen, and vascularized tissue placed between the cervical esophagus and cervical vertebrae to buttress the repair, eliminate dead space, improve antibiotic delivery, contain leaks, and shorten the time of a persistent postrepair leak.

The pedicled pectoralis muscle flap represents an appealing nonmicrosurgical option, given its frequent and reliable use in the reconstruction of esophageal defects following cancer resection. Favor-

able reconstructive results have been reported after oncologic resection; however, this patient population differs significantly from our target demographic. Patients with cancer are missing tissue from the anterior cervical esophagus, whereas the patients in this series are leaking from the posterior esophagus. The restricted exposure makes inseting these bulky pedicled muscle flaps challenging. Both pedicled pectoralis flaps in this series were eventually successful, but these 2 patients experienced longer hospital stays and duration until oral feeding. Furthermore, a theoretic functional donor site deficit is created for patients with spinal cord injury, who may use the pectoralis function for arm movement or as an accessory breathing muscle. Although limited, previous published results of pectoralis flap reconstructions following ACDF have also proven less than desirable. Pichler et al¹³ and Kau et al¹² each reported 1 case of successful pectoralis flap repair, but Phommachanh et al⁸ and Dakwar et al¹¹ each described cases of failed pectoralis flaps, requiring reoperation and the use of radial forearm flaps to achieve definitive closure.

The SCM muscular flap offers another local tissue option. Several recent reports have advocated the superiority of the SCM flap citing its proximity, ease

Table 2. Comparison of Outcomes between Omental Flap Reconstruction of Esophageal Perforation and All Other Flaps

Flap Type	Mean Time Until Oral Intake (d)	Mean Length of Hospital Stay (d)	Nonflap-related Complications (No.)	All Complications	Procedure Success (No.)
Omental reconstruction (7 cases)	22.5*	13.1	14.3% (1)	28.6% (2)	85.7% (6)
Nonomental reconstruction (6 cases)	268*	24.5	50% (3)	66.7% (4)	50% (3)

Patients with missing or unknown data were excluded from calculations for that parameter. Patients experiencing >1 complication were counted only once for the “all complications” metric.

*A statistically significant difference between groups ($P < 0.05$).

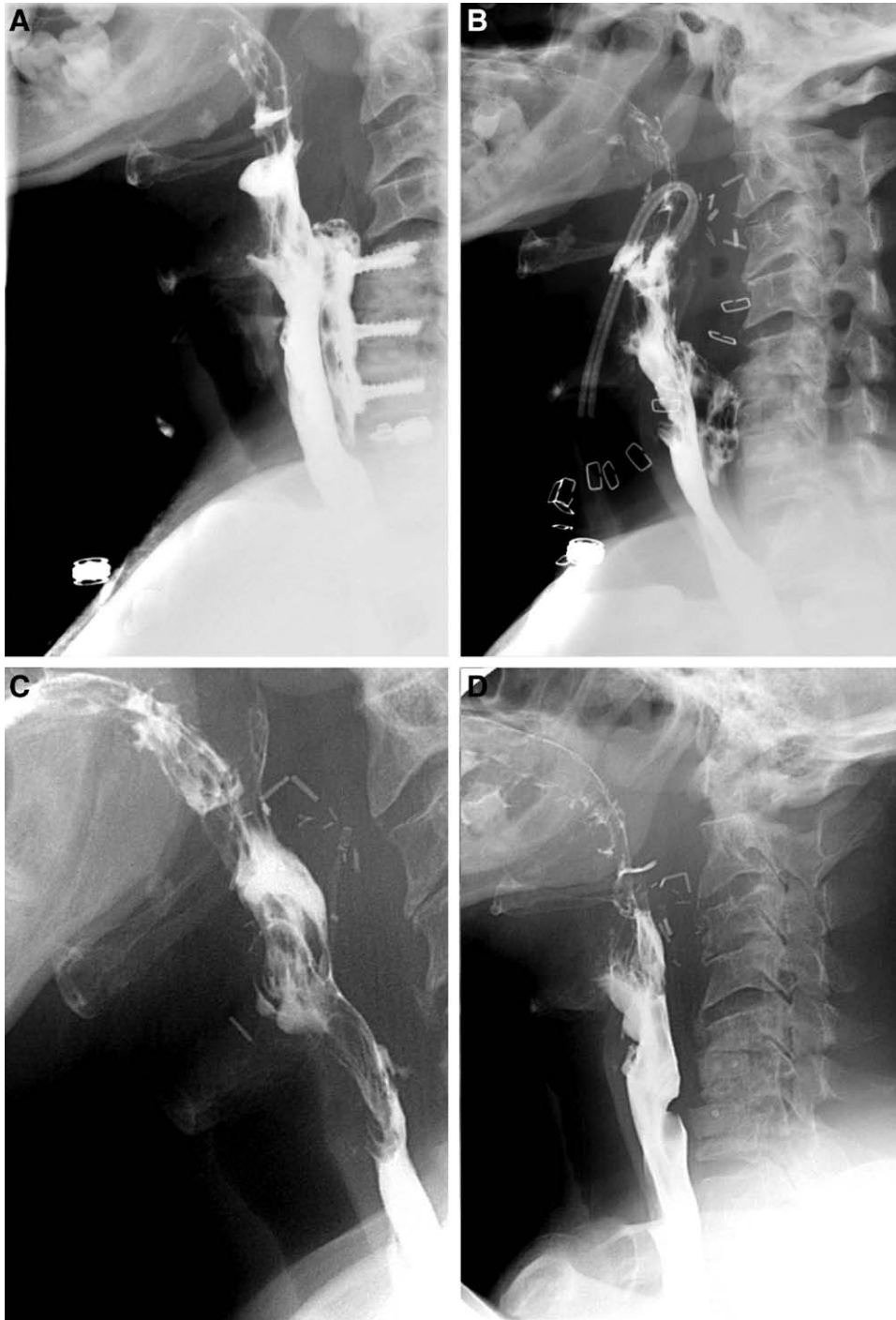

Fig. 3. Oral contrast swallow study depicting a posterior esophageal perforation after C5-7 anterior fusion (A). Seven days after omental flap reconstruction, a large leak contained within the omental soft-tissue envelope is observed (B). The contained leak dramatically shrunk on the follow-up swallow by 3 weeks after surgery (C). By 5 weeks after omental transfer, the esophageal repair was judged healed, and the patient was allowed a regular diet (D).

of mobilization, and minimal donor site morbidity as advantages compared with other tissue flaps.^{3,4,11,15-19} However, debate exists regarding the vascular reliability of the SCM muscle, especially the inferior pedicle, which is of particular concern in patients

who have undergone multiple neck explorations for ACDF.^{24,25} Use of the SCM flap puts the spinal accessory nerve at risk during the dissection, and a neuropraxia/neurotomy of this nerve as a complication has been seen by the senior author after this pro-

cedure. Additionally, the flap tip is small and may not provide adequate soft-tissue coverage for larger esophageal defects.^{3,25,26} We elected not to attempt SCM reconstructions in this series. Nonetheless, previously published studies demonstrate reliable outcomes, suggesting SCM muscular flaps represent a sufficient reconstructive option in esophageal defects. However, we generally believe that free tissue transfer provides more abundant tissue with greater blood supply than any local flap option.

Distant omental tissue presents a reconstructive alternative that may augment esophageal wound healing, given its unique angiogenic and immunogenic qualities.^{27–29} Omental flaps have been used extensively in contaminated fields and are associated with improved mortality and bacterial eradication compared with muscle flaps.^{29–32} On a technical level, the thin, pliable nature of omentum allows an inset that lines the posterior esophagus and isolates it from the cervical spine, contains residual microperforations, and fills associated dead space (Fig. 3). Our results revealed significantly faster recovery of esophageal defects after omental flap repairs compared with other reconstruction types and trends toward shorter hospital stays and higher overall flap success rates. Our findings are consistent with current teaching of treatment of lower esophageal perforations with omental wraps.²⁹ Omental harvesting is not without risks, however, as it requires entry into the peritoneal cavity, predisposing patients to future hernia development. However, a majority of these patients require gastrostomy tube placement to facilitate enteral nutrition, which obviates a “new” incision for the omental flap. Additionally, the increasing popularity of laparoscopic harvesting may mitigate this risk, with reports of hernia rates as low as 1%.³³ The complexity and added risks of an omental free flap reconstruction may deter some surgeons, but we believe that these risks are acceptable, given the potential wound-healing benefits and improved recovery rates.

It is unclear why the nonomental free flaps in our series did not fare as well, with 3 of 4 reconstructions ultimately failing and the other successful case exhibiting delayed closure (138 days). A review of the literature reveals a limited number of cases reporting on this indication for free tissue transfers.^{8,11,14,34,35} In this series, each free flap was selected for its unique advantages. The osteomuscular fibula flap was utilized in a single patient with significant bony destruction secondary to osteomyelitis from the leak. Although the flap helped to achieve complete bony fusion, the esophageal leak persisted. In retrospect, the limited amount of soft tissues harvested with the fibula for this case

was likely inadequate to buttress the primary closure of the esophagus. The radial forearm flap and the anterolateral thigh flap each lack the intrinsic immunogenic qualities of omentum as an explanation for their relative poorer performance in this series. Surgeon experience should not have played a large factor, as the nonomental flaps were interposed with omental flaps for the length of this 18-year series. The predominant reason to choose a nonomental flap was the presence of a hostile abdomen or the ability to use a lower extremity flap in a paraplegic.

Although this study represents the largest case series to date, it remains limited by its retrospective nature and small patient cohort size, precluding more rigorous statistical analyses. Statistical significance was achieved, both with and without the inclusion of an outlying patient; however, these results must be interpreted in the context of a single-surgeon, longitudinal study. It should also be noted that surgeon experience may affect reconstructive outcomes, particularly as omental flaps tended to be performed later in the senior author’s career. Future efforts should focus on a more standardized reporting method and the direct comparison of reconstructive techniques.

CONCLUSIONS

Esophageal perforation after ACDF is an uncommon but devastating complication. The use of free omentum flap reconstruction is associated with a more rapid functional recovery and may prove beneficial in the management of these challenging cases. This has become our flap of choice for these difficult defects, with excellent success rates and short hospital stays.

Gregory A. Dumanian MD,

Division of Plastic and Reconstructive Surgery
Northwestern University, Feinberg School of Medicine
675 North St. Clair Street
Galter Suite 19–250
Chicago, IL 60611

E-mail: gdumania@nmh.org

REFERENCES

1. Nanda A, Sharma M, Sonig A, et al. Surgical complications of anterior cervical discectomy and fusion for cervical degenerative disk disease: a single surgeon’s experience of 1,576 patients. *World Neurosurg*. 2014;82:1380–1387.
2. Kelly MF, Spiegel J, Rizzo KA, et al. Delayed pharyngo-esophageal perforation: a complication of anterior spine surgery. *Ann Otol Rhinol Laryngol*. 1991;100:201–205.
3. Navarro R, Javahery R, Eismont F, et al. The role of the sternocleidomastoid muscle flap for esophageal fistula repair in anterior cervical spine surgery. *Spine (Phila Pa 1976)* 2005;30:E617–E622.

4. Ahn SH, Lee SH, Kim ES, et al. Successful repair of esophageal perforation after anterior cervical fusion for cervical spine fracture. *J Clin Neurosci*. 2011;18:1374–1380.
5. Brinster CJ, Singhal S, Lee L, et al. Evolving options in the management of esophageal perforation. *Ann Thorac Surg*. 2004;77:1475–1483.
6. Grillo HC, Wilkins EW Jr. Esophageal repair following late diagnosis of intrathoracic perforation. *Ann Thorac Surg*. 1975;20:387–399.
7. Russell RC, Graham DR, Feller AM, et al. Experimental evaluation of the antibiotic carrying capacity of a muscle flap into a fibrotic cavity. *Plast Reconstr Surg*. 1988;81:162–170.
8. Phommachanh V, Patil YJ, McCaffrey TV, et al. Otolaryngologic management of delayed pharyngo-esophageal perforation following anterior cervical spine surgery. *Laryngoscope* 2010;120:930–936.
9. Gouge TH, Depan HJ, Spencer FC. Experience with the Grillo pleural wrap procedure in 18 patients with perforation of the thoracic esophagus. *Ann Surg*. 1989;209:612–617.
10. Reid RR, Dutra J, Conley DB, et al. Improved repair of cervical esophageal fistula complicating anterior spinal fusion: free omental flap compared with pectoralis major flap. Report of four cases. *J Neurosurg*. 2004;100(1 Suppl Spine):66–70.
11. Dakwar E, Uribe JS, Padhya TA, et al. Management of delayed esophageal perforations after anterior cervical spine surgery. *J Neurosurg Spine* 2009;11:320–325.
12. Kau RL, Kim N, Hinni ML, et al. Repair of esophageal perforation due to anterior cervical spine instrumentation. *Laryngoscope* 2010;120:739–742.
13. Pichler W, Maier A, Rappl T, et al. Delayed hypopharyngeal and esophageal perforation after anterior spinal fusion: primary repair reinforced by pedicled pectoralis major flap. *Spine (Phila Pa 1976)* 2006;31:E268–E270.
14. Kim YJ, Glazer PA. Delayed esophageal perforation and abscess formation after cervical vertebrectomy and fusion. *Orthopedics* 2002;25:1091–1093.
15. Solerio D, Ruffini E, Gargiulo G, et al. Successful surgical management of a delayed pharyngo-esophageal perforation after anterior cervical spine plating. *Eur Spine J*. 2008;17(Suppl 2):S280–S284.
16. Benazzo M, Spasiano R, Bertino G, et al. Sternocleidomastoid muscle flap in esophageal perforation repair after cervical spine surgery: concepts, techniques, and personal experience. *J Spinal Disord Tech*. 2008;21:597–605.
17. Fuji T, Kuratsu S, Shirasaki N, et al. Esophagocutaneous fistula after anterior cervical spine surgery and successful treatment using a sternocleidomastoid muscle flap. A case report. *Clin Orthop Relat Res*. 1991;267:8–13.
18. Zdichavsky M, Blauth M, Bosch U, et al. Late esophageal perforation complicating anterior cervical plate fixation in ankylosing spondylitis: a case report and review of the literature. *Arch Orthop Trauma Surg*. 2004;124:349–353.
19. Orlando ER, Caroli E, Ferrante L. Management of the cervical esophagus and hypopharynx perforations complicating anterior cervical spine surgery. *Spine (Phila Pa 1976)* 2003;28:E290–E295.
20. Haku T, Okuda S, Kanematsu F, et al. Repair of cervical esophageal perforation using longus colli muscle flap: a case report of a patient with cervical spinal cord injury. *Spine J*. 2008;8:831–835.
21. Barrow DL, Nahai F, Tindall GT. The use of greater omentum vascularized free flaps for neurosurgical disorders requiring reconstruction. *J Neurosurg*. 1984;60:305–311.
22. Harii K. Clinical application of free omental flap transfer. *Clin Plast Surg*. 1978;5:273–281.
23. Lu X, Guo Q, Ni B. Esophagus perforation complicating anterior cervical spine surgery. *Eur Spine J*. 2012;21:172–177.
24. Kierner AC, Aigner M, Zelenka I, et al. The blood supply of the sternocleidomastoid muscle and its clinical implications. *Arch Surg*. 1999;134:144–147.
25. Larson DL, Goepfert H. Limitations of the sternocleidomastoid musculocutaneous flap in head and neck cancer reconstruction. *Plast Reconstr Surg*. 1982;70:328–335.
26. Kierner AC, Zelenka I, Gstöettner W. The sternocleidomastoid flap—its indications and limitations. *Laryngoscope* 2001;111:2201–2204.
27. Cartier R, Brunette I, Hashimoto K, et al. Angiogenic factor: a possible mechanism for neovascularization produced by omental pedicles. *J Thorac Cardiovasc Surg*. 1990;99:264–268.
28. Mathisen DJ, Grillo HC, Vlahakes GJ, et al. The omentum in the management of complicated cardiothoracic problems. *J Thorac Cardiovasc Surg*. 1988;95:677–684.
29. Shrager JB, Wain JC, Wright CD, et al. Omentum is highly effective in the management of complex cardiothoracic surgical problems. *J Thorac Cardiovasc Surg*. 2003;125:526–532.
30. Shah S, Sinno S, Vandevender D, et al. Management of thoracic aortic graft infections with the omental flap. *Ann Plast Surg*. 2013;70:680–683.
31. Chittithavorn V, Rergkliang C, Chetpaophon A, et al. Single-stage omental flap transposition: modality of an effective treatment for deep sternal wound infection. *Interact Cardiovasc Thorac Surg*. 2011;12:982–986.
32. van Wingerden JJ, Lapid O, Boonstra PW, et al. Muscle flaps or omental flap in the management of deep sternal wound infection. *Interact Cardiovasc Thorac Surg*. 2011;13:179–187.
33. Zaha H, Inamine S. Laparoscopically harvested omental flap: results for 96 patients. *Surg Endosc*. 2010;24:103–107.
34. von Rahden BH, Stein HJ, Scherer MA. Late hypopharyngo-esophageal perforation after cervical spine surgery: proposal of a therapeutic strategy. *Eur Spine J*. 2005;14:880–886.
35. Küntscher MV, Erdmann D, Boltze WH, et al. Use of a free jejunal graft for oesophageal reconstruction following perforation after cervical spine surgery: case report and review of the literature. *Spinal Cord* 2003;41:543–548.