

[ CASE REPORT ]

## Non-aneurysmal Subarachnoid Hemorrhaging: A Rare Cause of Death in a Patient with Multiple System Atrophy

Hisanori Kinoshita<sup>1</sup>, Takashi Ayaki<sup>1</sup>, Takakuni Maki<sup>1</sup>, Naoki Goda<sup>2</sup>,  
Akihiko Yoshizawa<sup>2</sup> and Ryosuke Takahashi<sup>1</sup>

### Abstract:

Sudden death as a result of multiple system atrophy (MSA) is usually attributed to vocal cord paralysis or disruption of breathing owing to the degeneration of the brainstem respiratory centers. However, the exact pathophysiology of sudden death is still unclear. In addition, specific causes of sudden death are not always investigated by an autopsy. We herein report a patient with MSA and non-aneurysmal subarachnoid hemorrhaging, which is believed to be a rare cause of death in this setting. Without an autopsy, our case would likely have been diagnosed as sudden death due to vocal cord paralysis. To develop effective strategies to prevent sudden death, a post-mortem investigation is important in order to exclude known structural causes of death.

**Key words:** multiple system atrophy, subarachnoid hemorrhaging, sudden death

(Intern Med 58: 1643-1644, 2019)

(DOI: 10.2169/internalmedicine.1567-18)

### Introduction

Sudden death is commonly seen in patients with multiple system atrophy (MSA). According to a recent retrospective study of 131 patients with MSA in China, sudden death is the second leading cause of death (14.5%) after respiratory infection (65.6%) in this patient population (1). Furthermore, sudden death occurs more frequently in patients with nocturnal stridor than in those without (42.9% vs. 9.1%) (1).

Sudden death as a result of MSA is usually attributed to vocal cord paralysis or disruption of breathing owing to the degeneration of the brainstem respiratory centers (2). Therefore, tracheostomy and non-invasive positive pressure ventilation (NPPV) are typical therapeutic approaches. However, the exact pathophysiology of sudden death is still unclear (3). In addition, specific causes of sudden death are not always investigated at an autopsy or by post-mortem imaging (3). Sudden death from other causes may also be important in MSA.

We herein report a patient with MSA and non-aneurysmal subarachnoid hemorrhaging (SAH), which is believed to be

a rare cause of death in this setting.

### Case Report

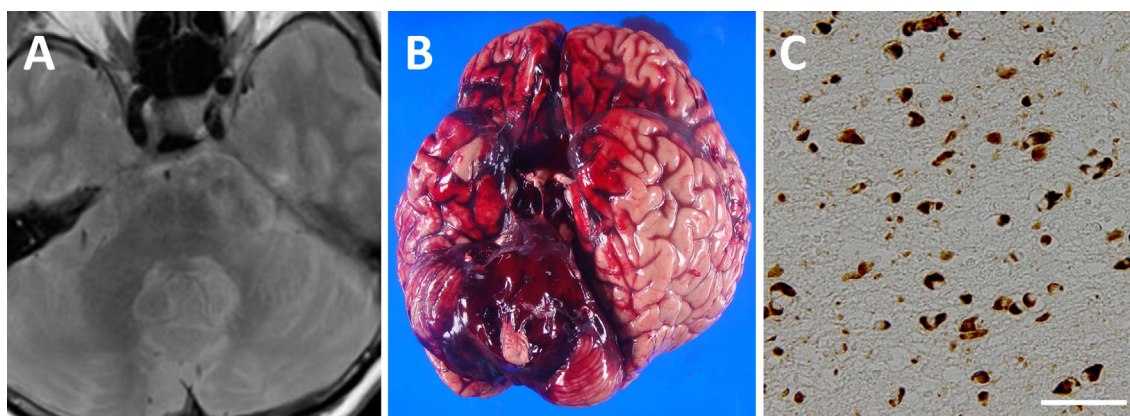
A 66-year-old woman with a 4-year history of MSA was found dead in her bed one morning. The patient had a history of nocturnal stridor and had been treated with NPPV. However, her condition had been stable the night before. Her medications consisted of fludrocortisone (0.1 mg/day) and amezinium metilsulfate (10 mg/day) for orthostatic hypotension. A previous neurological examination had revealed cerebellar ataxia, bradykinesia, rigidity, and postural instability. Furthermore, autonomic failure, including urinary incontinence and orthostatic hypotension, was observed. Although home blood pressure monitoring data were lacking, supine hypertension had been observed in the outpatient clinic (systolic blood pressure >160 mmHg). Previous magnetic resonance imaging of the brain revealed a “hot cross bun” sign and atrophy of the cerebellum and pons (Figure A).

An autopsy revealed hematoma formation secondary to SAH at the base of the brain (Figure B). Although no aneurysm or bleeding source was found, the hematoma was most

<sup>1</sup>Department of Neurology, Kyoto University Graduate School of Medicine, Japan and <sup>2</sup>Department of Diagnostic Pathology, Kyoto University Hospital, Japan

Received: May 18, 2018; Accepted: November 20, 2018; Advance Publication by J-STAGE: February 1, 2019

Correspondence to Dr. Takashi Ayaki, ayaki520@kuhp.kyoto-u.ac.jp



**Figure.** (A) “Hot cross bun” sign on proton density-weighted imaging of the brain. (B) Brain with subarachnoid hemorrhaging. (C) Phosphorylated alpha-synuclein-positive inclusions in the cytoplasm of the glial cells in the pons. Scale bar: 50  $\mu$ m.

extensive at the top of the basilar artery. An additional histopathological examination revealed phosphorylated alpha-synuclein-positive inclusions in the cytoplasm of the glial cells, consistent with MSA (Figure C). Neither deposition of  $\beta$ -amyloid peptide nor neurofibrillary tangles, which are characteristic of amyloid angiopathy or Alzheimer’s disease, were detected. No other identifiable cause of death was found in any other organ, including the heart and lungs. Although the possibility that vocal cord paralysis or disruption of the respiratory centers as a cause of death was not ruled out, her unexpected death was attributed to SAH.

## Discussion

This case suggests the importance of the post-mortem investigation after unexpected death in patients with MSA. This patient’s course was consistent with sudden death, which is defined as death of an otherwise unknown etiology occurring less than 24 hours from the onset of symptoms (4). Furthermore, the patient’s history of nocturnal stridor with the use of NPPV suggested the likelihood of sudden death caused by vocal cord paralysis or abnormal breathing owing to brainstem degeneration. However, the autopsy revealed SAH.

Without a thorough post-mortem investigation, unexpected death in MSA can easily be misclassified as sudden death due to vocal cord paralysis or neurodegenerative disruption of breathing, especially if the patient has a history of nocturnal stridor or the use of ventilatory assistance. A post-mortem investigation is also important in the development of effective strategies to prevent sudden death in MSA. Clinical studies of sudden death in MSA have been performed but are often without comprehensive post-mortem investigations (3). However, patients with MSA often have supine hypertension, which is a risk factor for neurovascular complications, including SAH (5, 6). Sudden death even after

tracheostomy or NPPV may be caused by neurovascular complications of autonomic failure in MSA. To develop effective strategies to prevent sudden death in MSA, excluding possible known structural causes of death is important.

As suggested by this case, a possible association between MSA and SAH requires further investigation. The clinical and pathological assessment in this case were insufficient to explain the mechanism of bleeding. At the autopsy, aneurysm was not detected macroscopically. In addition, amyloid angiopathy was not pathologically observed. Further investigations as to whether or not structural vulnerabilities may occur within the cerebrovascular system in patients with MSA are necessary.

In conclusion, this case suggests the importance of the post-mortem investigation of unexpected death in patients with MSA.

**The authors state that they have no Conflict of Interest (COI).**

## References

- Zhang L, Cao B, Zou Y, Wei QQ, Ou R, Liu W, Zhao B, Yang J, Wu Y, Shang H. Causes of death in Chinese patients with multiple system atrophy. *Aging Dis* **9**: 102-108, 2018.
- Fanciulli A, Wenning GK. Multiple-system atrophy. *N Engl J Med* **372**: 249-263, 2015.
- Shimohata T, Ozawa T, Nakayama H, Tomita M, Shinoda H, Nishizawa M. Frequency of nocturnal sudden death in patients with multiple system atrophy. *J Neurol* **255**: 1483-1485, 2008.
- World Health Organization. International statistical classification of diseases and related health problems 10th revision. World Health Organization, Geneva, 2010.
- Fanciulli A, Göbel G, Ndayisaba JP, et al. Supine hypertension in Parkinson’s disease and multiple system atrophy. *Clin Auton Res* **26**: 97-105, 2016.
- Feigin VL, Rinkel GJ, Lawes CM, et al. Risk factors for subarachnoid hemorrhage: an updated systematic review of epidemiological studies. *Stroke* **36**: 2773-2780, 2005.

The Internal Medicine is an Open Access journal distributed under the Creative Commons Attribution-NonCommercial-NoDerivatives 4.0 International License. To view the details of this license, please visit (<https://creativecommons.org/licenses/by-nc-nd/4.0/>).