

Clinical image quality evaluation for panoramic radiography in Korean dental clinics

Bo-Ram Choi, Da-Hye Choi, Kyung-Hoe Huh, Won-Jin Yi*, Min-Suk Heo, Soon-Chul Choi, Kwang-Hak Bae**, Sam-Sun Lee*

Department of Oral and Maxillofacial Radiology and Dental Research Institute, School of Dentistry, Seoul National University, Seoul, Korea

*Department of Oral and Maxillofacial Radiology, BK21 Craniomaxillofacial Life Science, and Dental Research Institute, School of Dentistry, Seoul National University, Seoul, Korea

**Department of Preventive and Public Health Dentistry and Dental Research Institute, School of Dentistry, Seoul National University, Seoul, Korea

ABSTRACT

Purpose: The purpose of this study was to investigate the level of clinical image quality of panoramic radiographs and to analyze the parameters that influence the overall image quality.

Materials and Methods: Korean dental clinics were asked to provide three randomly selected panoramic radiographs. An oral and maxillofacial radiology specialist evaluated those images using our self-developed Clinical Image Quality Evaluation Chart. Three evaluators classified the overall image quality of the panoramic radiographs and evaluated the causes of imaging errors.

Results: A total of 297 panoramic radiographs were collected from 99 dental hospitals and clinics. The mean of the scores according to the Clinical Image Quality Evaluation Chart was 79.9. In the classification of the overall image quality, 17 images were deemed 'optimal for obtaining diagnostic information,' 153 were 'adequate for diagnosis,' 109 were 'poor but diagnosable,' and nine were 'unrecognizable and too poor for diagnosis'. The results of the analysis of the causes of the errors in all the images are as follows: 139 errors in the positioning, 135 in the processing, 50 from the radiographic unit, and 13 due to anatomic abnormality.

Conclusion: Panoramic radiographs taken at local dental clinics generally have a normal or higher-level image quality. Principal factors affecting image quality were positioning of the patient and image density, sharpness, and contrast. Therefore, when images are taken, the patient position should be adjusted with great care. Also, standardizing objective criteria of image density, sharpness, and contrast is required to evaluate image quality effectively. (*Imaging Sci Dent* 2012; 42 : 183-90)

KEY WORDS: Quality Control; Radiography, Panoramic; Image Quality Enhancement, Quality Assurance

Introduction

Dental societies in the U.S. and Europe stress the importance of using a panoramic radiograph for surveying patients,^{1,2} and quality assurance guidelines for panoramic radiography are continuously being published and revised.^{3,4}

In 2001 in South Korea, a special law to establish a legal basis for medical imaging quality control was enacted. Based on the law, regulation on the installation and operation of special medical instruments including computed tomography, magnetic resonance imaging, and mammography was enacted and published, which provided the legal groundwork for medical imaging quality control.⁵ However, continuous quality control of panoramic radiography, a frequently performed exam in dentistry, is in its beginning stage. In 2009, the Korea Food and Drug Administration initiated a study on the recommended radiation

Received June 12, 2012; Revised June 23, 2012; Accepted June 25, 2012
Correspondence to : Prof. Sam-Sun Lee
Department of Oral and Maxillofacial Radiology, School of Dentistry, Seoul National University, 28 Yeongseon-dong, Jongno-gu, Seoul 110-768, Korea
Tel) 82-2-2072-3978, Fax) 82-2-744-3919, E-mail) raylee@snu.ac.kr

dose in panoramic radiography, and it is considered the first step in dental imaging quality control.⁶

Quality assurance of dental radiography consists of the inspection of the personnel and facility, as well as image quality assurance. The image quality assurance inspection consists of a clinical imaging evaluation and a standard phantom image test.⁷ Among the various types of image quality evaluation, clinical imaging evaluation is the most important inspection that enables actual and comprehensive evaluation since it reflects the entire quality assurance process, and it must be performed continuously.⁸

The panoramic radiographic unit uses both the principle of tomography and the principle of scanning. Characteristically, it may produce images that lack diagnostic value if the mandible and maxilla of interest are not correctly positioned in the focal trough.⁹

Recently, with the development of the image transmission system and the wide use of digital panoramic radiographic equipment, the quality of panoramic radiographic equipment has improved¹⁰ and consequently, a quality image can be obtained.

As no appropriate guidelines on quality control have been prepared in South Korea, related studies are required. A certified inspection method is required to appropriately and effectively maintain and control the image quality, and studies on the current status of the panoramic radiography of local dental hospitals and clinics are prerequisites for such a certified inspection method.⁷

The purpose of this study was to investigate the level of clinical image quality for panoramic radiograph and to provide a basis for clinical image evaluation, which is the most important part of quality assurance in South Korea.

Materials and Methods

Collection of images

Among the approximately 13,000 dental hospitals and clinics in South Korea, 260 (about 2%) were selected using the random sampling method, with the help of the Korean Dental Association. The 260 dental hospitals and clinics were asked to cooperate in the clinical image evaluation of panoramic radiographs.

Each dental hospital or clinic was asked to provide three randomly selected radiographs. The image identification such as the name and sex did not accompany the radiograph to protect the patient's privacy. The file format of the radiographs was limited to JPG or DICOM and they were sent by email as an attachment.

Training of clinical image evaluators

To ensure a professional and efficient evaluation, oral and maxillofacial radiology specialists or clinicians who had been working in a hospital's Department of Oral and Maxillofacial Radiology for five years or more evaluated the clinical images. During meetings for the pilot study, 14 evaluators were trained to evaluate panoramic images, and an agreement on the objective criteria for the qualitative evaluation of the images was forged among the evaluators.¹¹

Clinical image evaluation using a clinical image quality evaluation chart

A chart was used to evaluate the image quality of a panoramic radiograph (Table 1). It was prepared during multiple meetings of evaluators. The perfect score in the clinical image evaluation was 100 points: 8 points for patient identification, 6 for artificial shadow, 8 for image coverage, 30 for patient positioning, 38 for image density, resolution, and contrast, and 10 for image quality grade.

One of the 14 evaluators evaluated an image using the aforementioned chart and calculated the total score. Since all of the information on the patients, hospitals or clinics, and equipment were excluded during the data collection process, all of the images got a full mark for the parameter of patient identification.

Classification of the overall image quality grade

Three clinical image evaluators classified the overall image quality of the panoramic radiographs. The evaluators evaluated the image quality while viewing the images; and if there was any inconsistency between their evaluations, an agreement was made through discussion. The image quality grade was classified into the following 4 grades: 1. optimal for obtaining diagnostic information, 2. adequate for diagnosis, 3. poor but diagnosable/unrecognizable, and 4. too poor for diagnosis. The detailed criteria are shown in Table 2.

For each image quality grade, the score was calculated according to the Clinical Image Quality Evaluation Chart, and scores of images that could be diagnosed were calculated according to the image quality evaluation chart by comparing the maximum and minimum scores.

Causes of imaging errors

Apart from the scores calculated by the three clinical image evaluators based on the image quality grade, the

Table 1. Clinical image quality evaluation chart

		Score	
		yes	no
1. Identification	Name of patient	1	0
	Sex	1	0
	Age	1	0
	Registration number	1	0
	Date of taking	1	0
	Time of taking	1	0
	Operator (name or mark)	1	0
	Mark for left or right	1	0
2. Artifacts	Internal artifacts or artifacts of unknown origin (record any stains, scratches, static electricity, or detector error, etc.): Not present/present but don't interfere with diagnosis/ may interfere with diagnosis)	4	2/0
	Artifacts caused by external factors (the patient's earrings, removable prosthesis, etc.): Not present/present but don't interfere with diagnosis/ may interfere with diagnosis)	2	1/0
3. Coverage area	Top: include the inferior border of the orbit	2	0
	Left: include outside of 0.5 mm to temporomandibular joint	2	0
	Right: include outside of 0.5 mm to temporomandibular joint	2	0
	Bottom: include underside of 0.5 mm to inferior cortical border of the mandible	2	0
4. Patient positioning	Bite block existence	2	0
	Occlusal plane: appropriate/flat/steep downward V-shape/ inverted V-shape	6	4/2/0
	Antero-posterior positioning: adequate/former or rear but diagnosis is possible/ unclear anterior portion	4	2/0
	Right-left symmetry: symmetry/The discrepancy is less than half of the width in M-D of mandibular 1st molar/ above half of the width in M-D of mandibular 1st molar	4	2/0
	Hyoid bone overlapped the mandible	2	0
	Patient movement (up and down): continuity on the inferior border of mandible (under 2 mm)	2	0
	Patient movement (up and down): continuity on the occlusal plane (under 2 mm)	2	0
	Patient movement (right and left): none of dual images	2	0
	Patient movement (right and left): none of disappeared images	2	0
No soft tissue movement (evaluation of the soft palate, tongue and hyoid bone)	2	0	
5. Density, sharpness, and contrast of image	Distinguishable dentinoenamel junction: almost distinguishable/indistinguishable in 2 of 6 of the regions/indistinguishable in 4 of 6 of the regions	4	2/0
	Distinguishable PDL space and lamina dura: almost distinguishable/indistinguishable in 2 of 6 of the regions/indistinguishable in 4 of 6 of the regions	4	2/0
	Accuracy of root shape: almost distinguishable/indistinguishable in 2 of 6 of the regions/ indistinguishable in 4 of 6 of the regions	4	2/0
	Metal artifact: distinguishable with secondary caries/ indistinguishable	4	0
	Extent of the proximal overlap: overlapped under the DEJ/ over the DEJ	4	0
	Homogeneity of the background density: homogeneous/heterogeneous	4	0
	Distinguishable alveolar crest in alveolar bone: almost distinguishable/ indistinguishable in 2 of 6 of the regions/ indistinguishable in 4 of 6 of the regions	4	2/0
	Distinguishable trabecular pattern in alveolar bone: almost distinguishable/ indistinguishable in 2 of 6 of the regions/ indistinguishable in 4 of 6 of the regions	4	2/0
	Regional contrast-TMJ area	2	0
	Regional contrast-maxillary sinus	2	0
	Regional contrast-mandibular area	2	0
	Noise: not present/present	2	0
	6. Overall image quality grade	Optimal for obtaining diagnosis information/adequate for diagnosis/poor, but diagnosable/unrecognizable, too poor for diagnosis	10
Total Score		100	
7. Cause of the errors	Positioning errors during the radiograph taking (patient preparation, position of the mandible and maxilla, patient movement, and angle of the cervical spine) Errors from the radiographic unit and other mechanical errors accessories (irregularity of the exposure roller and error of the sensor and reader) Pre- and post-processing errors (enhancement errors, noise, and abnormal density and contrast) Errors due to anatomic abnormality (malformation of the mandible and maxilla, and congenital dental anomaly)		

Table 2. Overall image quality grade of clinical panoramic radiographs

Optimal for obtaining diagnosis information	High quality image providing sufficient information, with no errors from image taking procedure.
Adequate for diagnosis	Quality image providing sufficient information, with 1 to 2 error(s) from image taking procedure that does not affect the diagnosis.
Poor, but diagnosable	Diagnosable image, with some errors and partially unreadable region.
Unrecognizable, too poor for diagnosis	Poor quality image, with definite errors rendering the image diagnostically unacceptable.

cause of the error observed on the image was determined and marked. The errors were classified into positioning errors during radiography (patient preparation, position of the mandible and maxilla, patient movement, and angle of the cervical spine), errors from the radiographic unit and other mechanical errors (irregularity of the exposure roller and error of the sensor and reader), pre- and post-processing errors (enhancement errors, noise, and abnormal density and contrast), and errors due to anatomic abnormality (malformation of the mandible and maxilla, and congenital dental anomaly).

Results

Image collection

The images were collected from a total of 99 dental hospitals and clinics. The response rate was 38.1% and a total of 297 panoramic radiographs were collected, from which nine were excluded due to transmission error and 288 were included.

Clinical image evaluation and classification of overall image quality grade

The mean of the scores given by a single specialist according to the Clinical Image Quality Evaluation Chart was 79.9 (maximum possible: 100), with the highest and lowest scores 98 and 35, respectively. The mean and representative scores of each group based on the overall image quality grade, the last parameter, are shown in Table 3.

In the classification of the overall image quality by the three evaluators, 17 images were deemed ‘optimal for obtaining diagnostic information,’ 153 were ‘adequate for diagnosis,’ 109 were ‘poor but diagnosable,’ and nine were ‘unrecognizable and too poor for diagnosis’ (Figs. 1-4).

About 59.0% (170) of all the images were rated ‘optimal for obtaining diagnostic information’ or ‘adequate for diagnosis’ (Table 4). About 96.9% (279) of the images had a ‘poor but diagnosable’ or better image quality.

The mean scores of the images with the image quality of ‘optimal for obtaining diagnostic information’ and ‘ade-

Table 3. Representative values according to the overall image quality grade

	Mean value	Maximum value	Minimum value	Standard deviation
1	94.6	98	91	1.9
2	85.6	95	74	3.8
3	71.6	80	61	4.7
4	53.6	70	35	9.5
1+2	86.5	98	74	
1+2+3	80.7	98	61	
1+2+3+4	79.9	98	35	

1: optimal for obtaining diagnosis information, 2: adequate for diagnosis, 3: poor, but diagnosable, 4: unrecognizable, too poor for diagnosis

quate for diagnosis’ were 15 points higher than that of the images with ‘poor but diagnosable’ image quality, and the lowest score (74 points) of the images with the ‘adequate for diagnosis’ image quality was higher than the mean scores of the images with a ‘poor but diagnosable’ image quality.

Some images scored higher than the mean score of the images with an ‘adequate for diagnosis’ image quality but were graded with a ‘poor but diagnosable’ image quality because of the difference in their left and right contrasts due to inappropriate posture, a too dark or too white image, and an intensive burnt-out spot in the area of the inferior border of the mandible or soft tissue due to the intense contrast, though the image could be interpreted (Fig. 5).

In particular, the panoramic images that scored 80 points, the highest for the images with a ‘poor but diagnosable’ image quality, were graded to have a poorer than ‘adequate for diagnosis’ image quality despite their higher score since it was impossible to evaluate the condylar area and the inferior area of the mandible because the top and bottom and the left and right of the image coverage were all not imaged, despite the good image quality of the teeth area (Fig. 6).

Causes of the clinical image errors

The results of the analysis of the causes of the errors in all the images are as follows (Table 5). There were 139

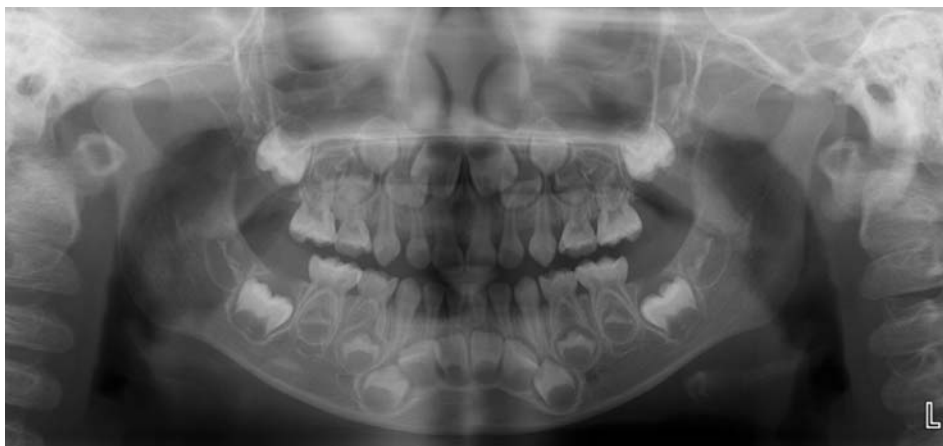

Fig. 1. An example of the image from 'optimal for obtaining diagnosis information' group.

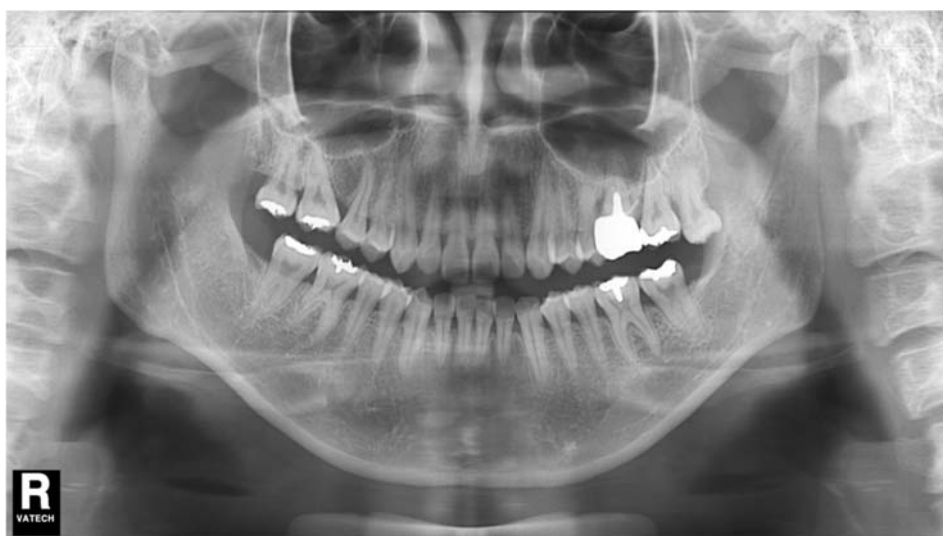

Fig. 2. An example of the image from 'adequate for diagnosis' group.

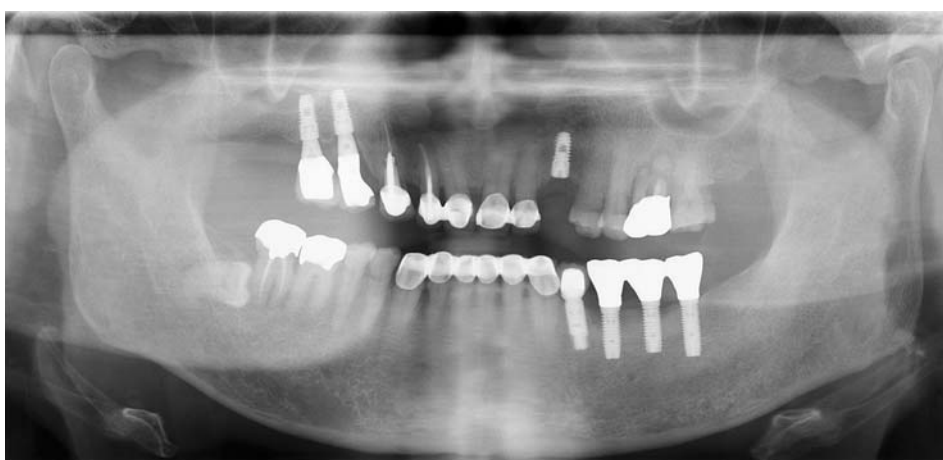

Fig. 3. An example of the image from 'poor, but diagnosable' group.

errors in the positioning, such as the patient positioning, patient movement, and angle of the cervical spine; 135 errors in the processing such as an abnormal density, contrast, and resolution; 50 errors from the radiographic unit

and other mechanical problems; and 13 errors due to anatomic abnormality. The total number of errors is not the same as the total number of images because some images had multiple errors and some had no errors at all.

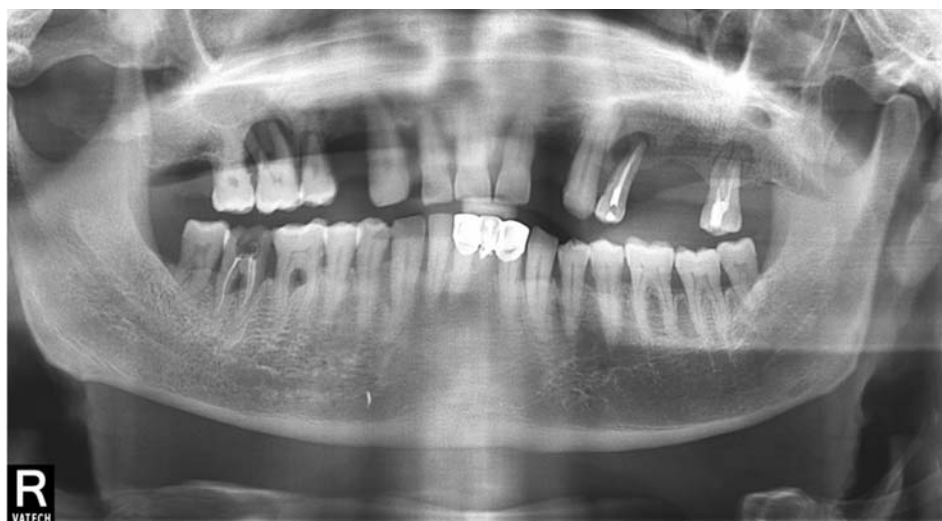

Fig. 4. An example of the images from 'unrecognizable, too poor for diagnosis' group.

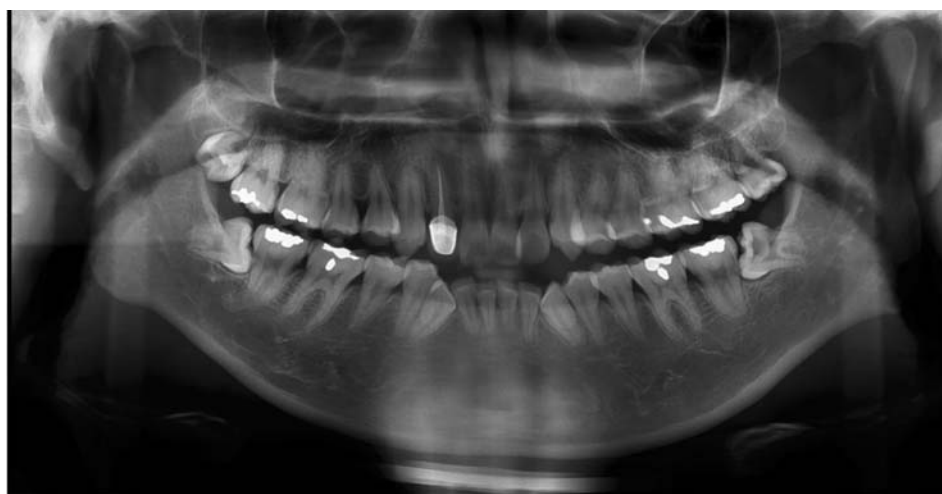


Fig. 5. An example of the high score image of the 'poor, but diagnosable' image quality group.

Table 4. Image quality grade classification

Image quality grade	Number of images
Optimal for obtaining diagnosis information	17
Adequate for diagnosis	153
Poor, but diagnosable	109
Unrecognizable, too poor for diagnosis	9

The most common errors in the images with an 'adequate for diagnosis' image quality were errors in positioning and errors of image taking, followed by processing errors, mechanical errors of the radiographic unit, and errors due to anatomic abnormality. In contrast, images with a 'poor but diagnosable' image quality had more preprocessing errors than positioning errors.

Nine images with an 'unrecognizable, too poor for diagnosis' image quality had image errors due to the causes shown in Table 5; i.e., four images had positioning errors

alone in the image taking, five images had both mechanical errors of the radiographic equipment and processing errors, and no image had errors due to anatomic abnormality.

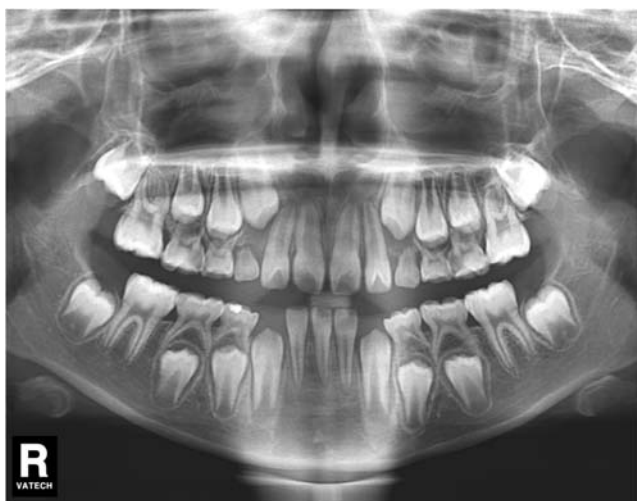The errors in image taking mostly involved considerable deviation of the patient posture from the normal patient posture. The mechanical and processing errors were caused by the irregularity in the image due to the irregular roller speed, abnormal exposure, and density abnormality (such as a too dark or too light image) that occurred all together.

Discussion

This study investigated the image quality of panoramic radiographs taken at dental hospitals and clinics across Korea. Clinical images were evaluated and scored using a Clinical Image Quality Evaluation Chart. The mean score of the images was 79.9 out of the highest possible score

Table 5. Causes of errors according to image quality grades

Image quality grade	Number of errors	Positioning errors	Errors from radiographic equipment	Pre-, post-processing errors	Errors due to anatomic abnormalities
Optimal for obtaining diagnosis information	0	0	0	0	0
Adequate for diagnosis	83	19	19	67	8
Poor, but diagnosable	52	52	26	63	5
Unrecognizable, too poor for diagnosis	4	4	5	5	0
Total	139	139	50	135	13

**Fig. 6.** The highest scored image of the 'poor, but diagnosable' image quality group.

of 100. Considering that 75% of the reference dose was used, the score would be 88, and thus, 88 points can be recommended.

In addition to the evaluation using the Clinical Image Quality Evaluation Chart, the images were also classified into four grades, and 59.0% of the images had a normal or higher-level image quality. Considering that the mean score of the panoramic radiographs taken at local dental hospitals and clinics based on the image quality evaluation was 79.9 points, which is higher than the lowest score (74 points) of the images with a normal image quality, and that more than half of the images had a normal or higher-level image quality, the image quality of the panoramic radiographs taken at local dental hospitals and clinics had a normal or higher-level image quality.

On the Clinical Image Quality Evaluation Chart, the necessary parameters to be fulfilled should be pointed out clearly in order to prevent 'unrecognizable, or too poor for diagnosis' images from achieving scores above the reference level. The parameters that need to be met must be selected, and the images should be graded as 'unrecognizable and too poor for diagnosis' when the necessary

parameters are not met regardless of the results for the other parameters. In this study, we tried to solve this problem by including the overall image quality grade in the Clinical Image Quality Evaluation Chart.

The images with an overall image quality grade that was lower than the scores based on the Clinical Image Quality Evaluation Chart had errors due to the following: as described in the Results section, the top and bottom and the left and right sides cut from the area of the image; the interpretation of the anterior teeth area was impossible due to malpositioning; and there was severe contrast abnormality due to a too dark or too white image. These factors have greater influence on the image quality than other factors and can thus be considered parameters that need to be met.

Also, in many cases, the cause of the error was not consistent among the three images sent from each hospital or clinic. The causes were as follows: (1) the patient age and body condition were different; (2) the patient positioning was not uniform during the image taking; and (3) even if the patient positioning was appropriate, the conditions of the radiographic unit could have been different if the images were taken on different days.

The cause of the error differed by grade. For the images with an 'adequate for diagnosis' image quality, positioning errors in the image taking were most common, followed by preprocessing errors, radiographic camera errors, and errors due to anatomic abnormality. In contrast, for the images with a 'poor but diagnosable' image quality, preprocessing errors were more common than positioning errors. This could have been due to the following: during the image taking, such devices as the bite block, chin rest, and head rest were used to fix the patient's head so as to minimize the possibility of a positioning error, whereas the processing error is attributable to mechanical and software problems and thus, the range of problems is unlimited.

This indicates that processing problems have a worse effect on the interpretation of the image than positioning errors. As such, the results of the analysis of the errors indicated that management and training of relevant personnel and inspection of facilities are required.

This study is meaningful because it is the first study that investigated the current status of panoramic radiographs taken at local dental hospitals and clinics and that evaluated the quality of clinical images to promote quality assurance in panoramic radiography.

In conclusion, panoramic radiographs taken at local dental hospitals and clinics generally have a normal or higher-level image quality. Principal factors affecting image quality were, namely, positioning of the patient and image density, sharpness, and contrast. Therefore, when images are taken, patient position should be adjusted with great care. Also, standardizing objective criteria of image density, sharpness, and contrast would be required to evaluate image quality effectively. Images with a below-normal image quality are not adequately addressed, however, because of lack of regulations on equipment and image quality assurance in panoramic radiography. Currently, in the beginning stage of panoramic radiography, quality assurance systems for dental radiography are being prepared, and specialists of the Korean Academy of Oral and Maxillofacial Radiology, the main body for dental radiography, are actively participating in quality assurance development and implementation. Guidelines are needed on image quality management for panoramic radiography to promote public health and reduce medical costs.

References

1. American Dental Association, United States Department of Health and Human Services. The selection of patients for dental radiographic examinations. Revised 2004. Chicago: American Dental Association; 2004.
2. Parsons DM, Kim Y, Haynor DR. Quality control of cathode-ray tube monitors for medical imaging using a simple photometer. *J Digit Imaging* 1995; 8 : 10-20.
3. National Council on Radiation Protection & Measurements. NCRP report No. 145 - Radiation protection in dentistry. Bethesda: NCRP; 2003.
4. European Commission [Internet]. Radiation protection 136: European guidelines on radiation protection in dental radiology [cited June 10]. Available from: http://ec.europa.eu/energy/nuclear/radiation_protection/publications_en.htm.
5. Enforcement regulations of the installation and operation of special medical equipments. Enforcement regulation No.65 of Ministry of Health and Welfare, 2003.
6. Kim EK. Development of diagnostic reference level in dental x-ray examination in Korea. Final report. Seoul: Korea Food & Drug Administration; 2009 Nov. Report No. 09142Radiology510.
7. Choi JI, Na DG, Kim HH, Shin YM, Ahn KJ, Lee JY. Quality control of medical imaging. *J Korean Radiol Soc* 2004; 50 : 317-31.
8. Lee SH, Choe YH, Chung SY, Kim MH, Kim EK, Oh KK, et al. Establishment of quality assessment standard for mammographic equipments: evaluation of phantom and clinical images. *J Korean Radiol Soc* 2005; 53 : 117-27.
9. White SC, Pharoah MJ. *Oral Radiology. Principles and Interpretation*. 6th ed. St. Louis: Mosby-Year Book Inc; 2009. p. 175-90.
10. Kim HJ. A study on guidance for medical radiation safety. Final report: Korea Food & Drug Administration; 2010 Dec. Report No. 10171Radiology457.
11. Choi DH. A study of clinical evaluation reference and imaging standardization for panoramic imaging [dissertation]. Seoul: Seoul National University; 2012.