

EDITOR'S  
CHOICE

# Inherited mitochondrial optic neuropathies

P Yu-Wai-Man,<sup>1,2</sup> P G Griffiths,<sup>2</sup> G Hudson,<sup>1</sup> P F Chinnery<sup>1,3</sup>

<sup>1</sup> Mitochondrial Research Group, The Medical School, Newcastle University, Newcastle upon Tyne, UK; <sup>2</sup> Department of Ophthalmology, Royal Victoria Infirmary, Newcastle upon Tyne, UK; <sup>3</sup> Institute of Human Genetics, Newcastle University, Newcastle upon Tyne, NE1 3BZ, UK

Correspondence to: Professor P F Chinnery, Mitochondrial Research Group, The Medical School, Newcastle University, Newcastle upon Tyne, NE2 4HH, UK; P.F. Chinnery@ncl.ac.uk

Received 8 September 2008  
Revised 8 September 2008  
Accepted 7 October 2008  
Published Online First  
17 November 2008

## ABSTRACT

Leber hereditary optic neuropathy (LHON) and autosomal dominant optic atrophy (DOA) are the two most common inherited optic neuropathies and they result in significant visual morbidity among young adults. Both disorders are the result of mitochondrial dysfunction: LHON from primary mitochondrial DNA (mtDNA) mutations affecting the respiratory chain complexes; and the majority of DOA families have mutations in the *OPA1* gene, which codes for an inner mitochondrial membrane protein critical for mtDNA maintenance and oxidative phosphorylation. Additional genetic and environmental factors modulate the penetrance of LHON, and the same is likely to be the case for DOA which has a markedly variable clinical phenotype. The selective vulnerability of retinal ganglion cells (RGCs) is a key pathological feature and understanding the fundamental mechanisms that underlie RGC loss in these disorders is a prerequisite for the development of effective therapeutic strategies which are currently limited.

Mitochondrial disorders are a major cause of chronic human disease with an estimated prevalence of 1 in 10 000 in the UK and a further 1 in 200 individuals being at-risk mutational carriers.<sup>1,2</sup> Ocular involvement is a prominent feature in this group and often points towards the underlying mitochondrial aetiology, which allows for a more targeted diagnostic approach. Optic nerve dysfunction can be the presenting and only ophthalmological manifestation causing the two most common inherited optic neuropathies encountered in clinical practice, Leber hereditary optic neuropathy (LHON) and autosomal dominant optic atrophy (DOA), which are the focus of this review. In the majority of cases, the pathology in LHON and DOA is limited to a highly specialised group of cells within the eye, the retinal ganglion cells (RGCs), but the phenotype associated with these two conditions is expanding, providing important insights into possible disease pathways leading to optic nerve degeneration and visual failure.

## LEBER HEREDITARY OPTIC NEUROPATHY

### LHON mutations

LHON (OMIM 535000) was first described as a distinctive clinical entity in 1871 by the German ophthalmologist Theodore Leber (1840–1917).<sup>3</sup> He reported a characteristic pattern of visual loss among members of four families and his observations were subsequently confirmed in pedigrees from different populations.<sup>4–6</sup> These early studies highlighted several of the salient features of LHON including the maternal transmission of the disease, the predilection of males to lose vision, and the almost exclusive involvement of the optic nerve. The non-Mendelian pattern of inheritance was

only fully explained in 1988 when LHON became the first human disease proven to be caused by a point mutation (m.11778G>A) within the mitochondrial genome.<sup>7</sup> Over 95% of LHON pedigrees are now known to harbour one of three mitochondrial DNA (mtDNA) point mutations: m.3460G>A, m.11778G>A and m.14484T>C, which all involve genes encoding complex I subunits of the mitochondrial respiratory chain.<sup>8</sup> In a meta-analysis of 159 pedigrees from Northern Europe and Australia, m.11778G>A was the most prevalent mutation but there is considerable variation in the relative frequency of these three primary LHON mutations worldwide (table 1). The predominance of m.11778G>A is even more pronounced in the Far East where it accounts for ~90% of all cases,<sup>9,10</sup> and although m.14484T>C is relatively rare, it is the most common mutation found among French Canadians (87%) as a result of a founder event.<sup>11,12</sup> Primary mutations have not been identified in a small minority of clinically diagnosed LHON patients, the most likely explanation being that rare pathogenic mtDNA variants are segregating in these families.<sup>13</sup> Disease causing mutations have been identified in a proportion of these cases, while other putative LHON mutations require further confirmation as they have only been found in singletons or a single family (table 1).

### Epidemiology

LHON is the most common of the primary mtDNA diseases, with a minimum prevalence of 1 in 31 000 affected individuals in the North East of England and 1 in 8500 carriers being at-risk of visual loss.<sup>14</sup> Fairly similar figures have been reported in other Caucasian populations, with an LHON prevalence of 1 in 39 000 in the Netherlands and 1 in 50 000 in Finland.<sup>15,16</sup> About 2% of visually impaired people on the blind register in Australia are also reported to suffer from LHON.<sup>17</sup> The peak age of onset in LHON is between the age of 15–30 years and 95% of carriers who will experience visual failure will do so before the age of 50 years (table 2). However, visual deterioration can occur anytime during the first to the seventh decade of life and LHON should be part of the differential diagnosis for all cases of bilateral, simultaneous or sequential optic neuropathy, irrespective of age and especially in male patients.<sup>18,19</sup> Except for one report which found a slight increase in the age of onset in females carrying the m.11778G>A mutation,<sup>20</sup> it is generally accepted that neither gender nor mutational status significantly influences the timing and severity of the initial visual loss.<sup>11,21–23</sup> Affected individuals are often aware of other affected family members, but up to 40% have no family history. These most likely represent cases



This paper is freely available online under the BMJ Journals unlocked scheme, see <http://jmg.bmj.com/info/unlocked.dtl>

**Table 1** Pathogenic mtDNA mutations associated with Leber hereditary optic neuropathy

	Mutation	Gene	Prevalence (%)	Reference
Primary	m.3460G>A	<i>MT-ND1</i>	13	220, 221
	m.11778G>A	<i>MT-ND4</i>	69	7
	m.14484T>C	<i>MT-ND6</i>	14	32, 222
Rare			<5	
	m.3376G>A	<i>MT-ND1</i>		45
	m.3697G>A			46
	m.3733G>A			223
	m.4160T>C			41
	m.4171C>A			224
	m.11696G>A	<i>MT-ND4</i>		40
	m.11253T>C			225
	m.10663T>C	<i>MT-ND4L</i>		226
	m.12848C>T	<i>MT-ND5</i>		227
	m.13730G>A			228
	m.14568C>T	<i>MT-ND6</i>		229
	m.14279G>A			230
	m.14459G>A			42–44
	m.14482C>G			231
	m.14495A>G			232
	m.14498C>T			233
m.14568C>T			234	
m.14596A>T			40	

where family history is difficult to trace back, given that de novo mutations are rare in LHON.<sup>14 24</sup>

## Clinical features

### Pre-symptomatic phase

Fundal abnormalities such as telangiectatic vessels around the optic discs and variable degrees of retinal nerve fibre layer oedema have been documented in some asymptomatic carriers, and these can fluctuate with time. Using optical coherence tomography imaging, thickening of the temporal retinal nerve fibre layer was found in a proportion of unaffected LHON carriers, which provides further evidence that the papillomacular bundle is particularly vulnerable in this disorder.<sup>25 26</sup> On more detailed psychophysical testing, some individuals also exhibited subtle impairment of optic nerve function including loss of colour vision affecting mostly the red–green system, reduced contrast sensitivity, and subnormal visual electrophysiological parameters.<sup>27</sup>

### Acute phase

LHON carriers remain asymptomatic until they experience blurring or clouding of vision in one eye. In the vast majority of

**Table 2** Lifetime risk of visual failure for Leber hereditary optic neuropathy carriers and recovery rates

	Pedigrees (n)	Median onset	Male: female ratio	Visual recovery (%)	Reference
m.3460G>A	9	29 years	2.3:1	22	22
	8	20 years	4.3:1	25	20
m.11778G>A	49	28 years	4.5:1	4	21
	66	24 years	3.7:1	25	20
	10	29 years	5.3:1	25	28
m.14484T>C	17	27 years	2.1:1	37	23
	23	19 years	7.7:1	58	11

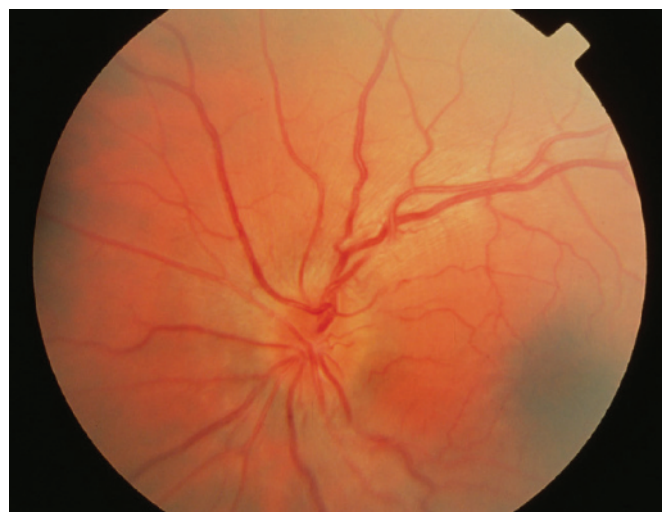
cases, visual dysfunction is bilateral, the fellow eye becoming affected either simultaneously (25%) or sequentially (75%), with a median inter-eye delay of 6–8 weeks.<sup>20</sup> Rare cases of unilateral optic neuropathy in LHON have been reported, with the fellow eye remaining unaffected over a follow-up period of up to 16 years.<sup>28 29</sup> Visual acuity reaches a nadir 4–6 weeks after disease onset and it is severely reduced to 6/60 or less. The characteristic field defect is a steep-sided central or centrocaecal scotoma and this can be formally documented using Goldmann or kinetic perimetry. Other clinical features include the early impairment of colour perception but, importantly, pupillary reflexes are preserved and patients usually report no pain on eye movement. Ocular examination during the acute stage provides other diagnostic clues and in classical cases the following abnormalities can be observed: vascular tortuosity of the central retinal vessels, swelling of the retinal nerve fibre layer, and a circumpapillary telangiectatic microangiopathy (fig 1). However, it must be stressed that in ~20% of LHON cases, the optic disc looks entirely normal in the acute phase.<sup>30 31</sup>

### Chronic phase

The retinal nerve fibre layer gradually degenerates and after 6 months, optic atrophy is a universal feature. If a patient is only seen at this stage, it can be difficult to exclude other compressive, infiltrative and inflammatory causes of a bilateral optic neuropathy, especially if there is no clear maternal family history. In these cases, neuroimaging of the anterior visual pathways is mandatory while awaiting the results of molecular genetic testing.

### Visual recovery

Visual recovery is observed in some patients even several years following disease onset. but the chances of improvement are influenced by the patient's mutational status, being least with the m.11778G>A mutation, highest with the m.14484T>C mutation, and the m.3460G>A mutation having an intermediate visual prognosis (table 2). The recovery in visual parameters is not only restricted to visual acuity, but can also include the development of small islands of normal field (fenestrations) within the central scotoma or a reversal of dyschromatopsia.<sup>28 32 33</sup> Positive prognostic factors for visual improvement are

**Figure 1** Acute fundal appearance in Leber hereditary optic neuropathy showing disc hyperaemia, swelling of the parapapillary retinal nerve fibre layer and retinal vascular tortuosity.

an early age of onset (<20 years), subacute presentation with slow progression of the visual deficits, and large optic nerve head surface area.<sup>28–34</sup> However, LHON is a devastating disorder with the majority of patients showing no functional improvement and remaining within the legal requirement for blind registration.

### Associated features

Although visual failure is the defining feature in this mitochondrial disorder, cardiac arrhythmias and neurological abnormalities such as postural tremor, peripheral neuropathy, non-specific myopathy and movement disorders have been reported to be more common in LHON compared to controls.<sup>35–39</sup> These are rarely clinically significant but a small number of LHON pedigrees do have severe neurological deficits (spastic dystonia, ataxia and juvenile onset encephalopathy) in addition to the optic neuropathy. These “LHON plus” syndromes have been linked to various mtDNA mutations in isolated pedigrees from Holland, Australia and North America: A11696G and/or T14596A,<sup>40</sup> T4160C,<sup>41</sup> and G14459A,<sup>42–44</sup> respectively. Two mtDNA complex I mutations point mutations, m.3376G>A<sup>45</sup> and m.3697G>A,<sup>46</sup> have also recently been identified in individuals with overlap clinical features of both LHON and MELAS (mitochondrial encephalomyopathy, lactic acidosis, and stroke-like episodes). Interestingly, a significant minority of Caucasian LHON carriers, predominantly females with the m.11778G>A mutation, develop clinical and neuroimaging features indistinguishable from multiple sclerosis (MS), including unmatched oligoclonal bands in the cerebrospinal fluid (Harding’s disease).<sup>47–50</sup> It is currently not known whether the prevalence of this MS-like illness in LHON is higher than expected due to the chance occurrence of these two disorders, and although controversial, some investigators have argued for a potential role of autoimmunity in the pathophysiology of this mitochondrial disorder.<sup>51–55</sup>

### Diagnosis

A tentative diagnosis of LHON can usually be made on clinical grounds, especially if classical ophthalmological features are present and a clear maternal history is elicited. Molecular genetic testing on a blood DNA sample, however, remains the gold standard and will confirm that the patient harbours one of the three primary mtDNA LHON mutations, with implications for future genetic counselling. If indicated, electrophysiological studies, including pattern electroretinograms (PERGs) and visual evoked potentials (VEPs), can be carried out to exclude retinal pathology and confirm optic nerve dysfunction.<sup>56</sup> An electrocardiogram is also recommended to exclude a pre-excitation syndrome which has been documented in LHON, although such a finding is rare and does not require any intervention in the absence of cardiac symptoms.<sup>30–31</sup> Computed

tomography (CT) and magnetic resonance imaging (MRI) scans are usually normal in LHON, but there are reports of non-enhancing high signals within the optic nerve and sheath distension, secondary to slight oedema or gliosis in the atrophic phase.<sup>57–62</sup>

### Biochemical features

Oxidative phosphorylation (OXPHOS) provides for most of the cell’s adenosine triphosphate (ATP) requirements and this is achieved by a chain of five respiratory complexes situated on the inner mitochondrial membrane. Since all three primary LHON mutations involve complex I subunits, one would expect respiratory chain function to be compromised, leading to a deficit in ATP synthesis and RGC degeneration as a consequence of energy failure. However, both *in vitro* and *in vivo* biochemical studies have produced conflicting results regarding the extent of respiratory chain dysfunction in LHON (table 3). In a small number of *in vivo* studies using phosphorus magnetic resonance spectroscopy (<sup>31</sup>P-MRS), the most consistent defect of mitochondrial function was identified in persons with the m.11778G>A mutation and none among those with the m.3460G>A mutation.<sup>63–67</sup> A striking conclusion from all these biochemical studies is that no significant difference between affected and unaffected individuals with a disease causing LHON mutation could be demonstrated. But as none of these studies have been performed directly on RGCs and the causative biochemical mechanisms could be highly tissue-specific, further studies are warranted.

### Neuropathology

These functional studies also raise important issues regarding the cell specific ocular pathology in LHON which is limited to the RGC layer, with sparing of the retinal pigment epithelium and photoreceptors. There is pronounced cell body and axonal degeneration, with associated demyelination and atrophy observed from the optic nerves to the lateral geniculate bodies. Experimental data indicate impaired glutamate transport,<sup>68</sup> oxidative stress<sup>69–70</sup> and increased mitochondrial reactive oxygen species (ROS)<sup>71</sup> within RGCs and support an apoptotic mechanism of cell death.<sup>72–73</sup> LHON patients also have reduced  $\alpha$ -tocopherol/lipid ratios and high levels of 8-hydroxy-2-deoxyguanosine in blood leucocytes, both biological markers of increased free radical production.<sup>74–75</sup> However, the selective vulnerability of RGCs in LHON still remains unexplained, and this area of research has been greatly hampered by the lack of access to diseased human tissues, the retina and optic nerve not being amenable to biopsies.

### Animal models

The development of faithful animal models in LHON is therefore critical but there is still no murine model where the primary LHON mutations have been successfully introduced within the mitochondrial genome. In spite of these technical challenges, significant advances have been made over the past decade and there are currently three experimental paradigms, all of which disrupt OXPHOS and recapitulate the optic nerve degeneration seen in LHON: (1) intravitreal injection of a respiratory chain poison such as rotenone<sup>76</sup>; (2) downregulation of nuclear encoded complex I subunits (for example, NFUFA1) with specific mRNA-degrading ribozymes<sup>77</sup>; and (3) allotropic expression of mutant subunits (for example, MTND4) which are then imported into the mitochondria.<sup>78</sup>

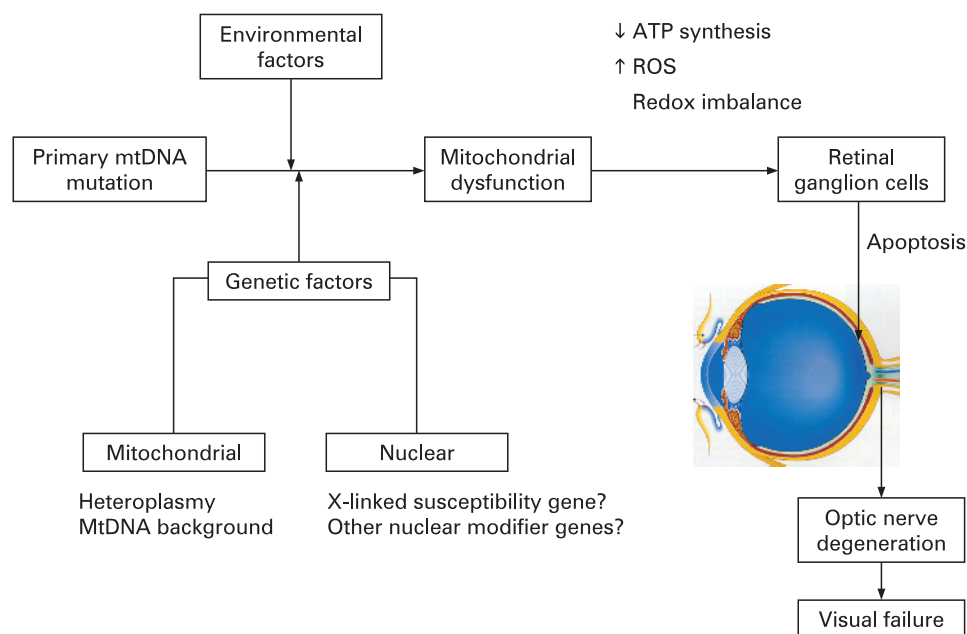
**Table 3** Respiratory chain dysfunction in Leber hereditary optic neuropathy

MtDNA mutation	In vitro <sup>88 235–249</sup>			In vivo <sup>63–67</sup>
	Complex I activity (%)	Respiratory rate (%)	ATP synthesis (%)	<sup>31</sup> P MRS (%)
m.3460G>A	60–80	30–35	90	0–40
m.11778G>A	0–50	30–50	35	75
m.14484T>C	0–65	10–20	90	50

ATP, adenosine triphosphate; <sup>31</sup>P-MRS, phosphorus magnetic resonance spectroscopy.

% decrease relative to controls.

**Figure 2** Secondary factors interacting with the primary mtDNA Leber hereditary optic neuropathy mutation to precipitate visual loss. ATP, adenosine triphosphate; ROS, reactive oxygen species.



### Incomplete penetrance

An intriguing feature of LHON is that only ~50% of males and ~10% of females who harbour one of the three primary mutations actually develop the optic neuropathy. This incomplete penetrance and predilection for males to lose vision imply that additional genetic and/or environmental factors must modulate the phenotypic expression of LHON (fig 2). Alternatively, the gender bias could also result from a combination of subtle anatomical, hormonal and physiological variations between males and females.

### Mitochondrial genetic factors

#### Heteroplasmy

Depending on their metabolic demands, cells can contain anywhere between 100–10 000 mitochondria, and with 2–10 mtDNA molecules in each mitochondrion, this results in a very high copy number per cell. In most LHON pedigrees, the primary mutation is homoplasmic—that is, every mtDNA molecule harbours the mutant allele. By contrast, 10–15% of LHON carriers are thought to be heteroplasmic, with one mtDNA sub-population carrying the wild type allele.<sup>14 20 79</sup> Although limited and retrospective, the available data suggest that heteroplasmy contributes to incomplete penetrance, with the risk of blindness being minimal if the mutational load is <60%.<sup>80</sup> However, quantifying the level of heteroplasmy for the purpose of pre-symptomatic testing is limited as the majority of individuals with a LHON mutation are homoplasmic.

#### MtDNA haplogroups

MtDNA accumulates mutations ~10 times faster than nuclear genome, resulting in a high degree of polymorphism.<sup>81</sup> Because human mtDNA is strictly maternally inherited and does not recombine, polymorphisms have accumulated sequentially along radiating female lineages as women migrated out of Africa into the different continents ~150 000 years ago.<sup>82</sup> Reflecting its evolution, a number of stable polymorphic variants cluster together in specific combinations referred to as haplogroups, with individuals of European ancestry belonging to one of nine haplogroups: H, I, J, K, T, U, V, W and X.<sup>83 84</sup>

A recent meta-analysis of 159 European LHON pedigrees indicated that the risk of visual loss for the three primary LHON mutations is influenced by the mtDNA background.<sup>85</sup> The risk of visual failure was greater when the m.11778G>A and m.14484T>C mutations arose on haplogroup J, whereas individuals with the m.3460G>A mutation were more likely to experience visual loss if they belonged to haplogroup K. On the other hand, individuals with the m.11778G>A mutation had a lower risk of visual loss when the mutation arose on haplogroup H. Haplogroups H, J and K are all defined by non-synonymous, polymorphic substitutions in the *MT-CYB* gene which codes for cytochrome *b*, the only mitochondrially encoded subunit of complex III. Recent experimental data support the existence of stable respiratory chain supercomplexes, one of which consists of a complex I monomer physically interacting with a complex III dimer. Although speculative, the haplogroup associated amino acid substitutions within cytochrome *b* could therefore influence the risk of visual failure by modulating the biochemical consequences of the primary LHON mutations through an effect on the stability of these putative I-III supercomplexes.<sup>85–87</sup> In support of this hypothesis, cybrid cell lines carrying the m.11778AG>A mutation on a haplogroup J background had a lower oxygen consumption and a longer doubling time compared to non-haplogroup J cell lines.<sup>88</sup> However, haplogroup J was not found to further impair mitochondrial OXPHOS in the brain and skeletal muscle of patients harbouring the m.11778G>A mutation with <sup>31</sup>P-MRS measurements,<sup>66</sup> and a study of South-East Asian LHON pedigrees found no association between specific mtDNA haplogroups and the risk of visual loss.<sup>89</sup> These contradictory findings reflect the need for additional studies to clarify the significance of the mtDNA background on LHON penetrance.

### Nuclear genetic factors

The predominance of affected males in LHON cannot be explained by mitochondrial inheritance and segregation analysis suggests the existence of a recessive X-linked susceptibility gene acting in synergy with the mtDNA mutation to precipitate the optic neuropathy.<sup>90–92</sup> In the *Bu and Rotter* model, the

development of blindness in males is consistent with the simultaneous inheritance of an X-linked visual loss allele and the primary LHON mutation, whereas females are affected either if they are homozygous at the susceptibility locus (40%) or heterozygous with skewed X chromosome inactivation of the wild-type allele (60%). Several studies have, however, failed to demonstrate any skewed X chromosome inactivation in affected female carriers, albeit in blood leucocytes and not in RGCs which are the affected tissues in LHON.<sup>93-95</sup> Initial attempts to identify this X-linked susceptibility locus by standard linkage analysis were unsuccessful,<sup>96-99</sup> but two recent studies using a larger number of more extensively defined LHON pedigrees found two overlapping disease loci with highly significant LOD scores at Xp21–Xq21<sup>100</sup> and Xq25–27.2.<sup>101</sup> Although the actual causative gene in this region of interest has not yet been identified, a high risk haplotype [DXS8090(166)-DXS1068(268)] at Xp21 was defined which increased the risk of visual failure ~35-fold for the m.11778G>A and m14484T>C mutations but not for m.3460G>A.<sup>100</sup> The possibility of other autosomal nuclear modifier genes in LHON has not been excluded and the genetic aetiology of LHON might prove even more complex, with epistatic interaction of these multiple nuclear susceptibility loci and genetic heterogeneity.

### Environmental factors

Five pairs of monozygotic twins harbouring a primary LHON mutation have been reported in the literature, and in two cases the twins have remained discordant.<sup>20 21 24 102-104</sup> Although there is always the possibility that the unaffected sibling will lose vision later on in life, the existence of discordant monozygotic twins strongly suggests that environmental factors also contribute to penetrance. There are several reports of an increased risk of visual loss among LHON carriers with high tobacco and alcohol consumption,<sup>105-108</sup> but the largest case-control study to date has failed to confirm this association.<sup>109</sup> There are also anecdotal reports of nutritional deprivation, exposure to industrial toxins, antiretroviral drugs, psychological stress or acute illness precipitating the onset of blindness in LHON.<sup>108 110-112</sup> Of note, in some pedigrees the penetrance of LHON seems to be decreasing, falling to 1% and 9% in younger generations of two large, multi-generational pedigrees from Australia<sup>113</sup> and Brazil,<sup>108 114</sup> respectively. Both carry homoplasmic levels of the m.11778G>A mutation and this phenomenon has been ascribed to improved environmental and socio-economic factors. However, a much larger epidemiological study of 3613 LHON carriers from multi-generational pedigrees failed to detect a change in the penetrance of the three primary LHON mutations. The role of environmental triggers in LHON remains largely unanswered and more robust epidemiological data are needed, which will necessitate a multicentre collaborative effort in order to collect sufficient number of subjects for analysis.

### Treatment

No generally accepted measures have been shown to either prevent or delay the onset of blindness in LHON, but for general health reasons LHON carriers should be advised to moderate their alcohol intake and stop smoking. In two small case series, oral administration of idebenone, a synthetic analogue of coenzyme Q10, and vitamin B12 and C supplementation led to faster and greater visual recovery among affected individuals.<sup>115 116</sup> However, a recent study has not found any improved visual prognosis from idebenone and multivitamin

supplementation, and properly conducted treatment trials are needed before such a regimen can be advocated.<sup>117</sup> The use of brimonidine eye drops, which is thought to have anti-apoptotic properties, was also unsuccessful in preventing second eye involvement in recently affected patients with unilateral optic neuropathy.<sup>118</sup> The long term management of visually impaired patients remains supportive, with provision of visual aids and registration with the relevant social services.

### Genetic counselling

It is important to stress to LHON carriers that it is not possible to predict accurately whether or when they will become affected. Despite these caveats, the two main predictive factors for visual failure remain age and gender, with males having about a 50% lifetime risk of blindness compared to only 10% for females, and these approximate figures can be further refined based upon the patient's age. From published age dependent penetrance data, most patients experience visual loss in their late teens and 20s and the probability of becoming affected decreases with increasing age, being minimal once past the age of 50 years (table 2). Once a primary LHON mutation has been identified in a proband, other maternally related family members can be offered molecular genetic testing to exclude the possibility of a de novo mutation, which is rare. Since LHON shows strict maternal inheritance, male carriers can be reassured that none of their children will inherit the mtDNA mutation whereas female carriers will transmit the pathogenic mutation to all of their offspring. Since most mothers are homoplasmic, their children will only harbour the mutant species, but the situation is more complex for a heteroplasmic mother as she could transmit a higher or a lower level of the mutation to a particular offspring, which will impact on the latter's risk of visual failure. Although the mutant level can be determined and there is evidence that a mutational threshold of ~60% in blood is necessary for disease expression, genetic counselling for these unaffected heteroplasmic carriers remains difficult. For similar reasons, the prenatal genetic testing of heteroplasmic women with amniocentesis or chorionic villus sampling (CVS) would be difficult to interpret.

## DOMINANT OPTIC ATROPHY

### Clinical features

The clinical features of DOA (OMIM 165500) were first described in one British family by Batten in 1896<sup>119 120</sup>; the phenotype was further clarified by Kjer in his extensive study of Dutch families in the 1950s,<sup>119 120</sup> distinguishing it from LHON with which the disease was often confused. The prevalence of DOA is not well established and robust estimates based on molecular confirmation are not available, although a historical figure of 1 in 50 000 among Caucasians is often quoted in the literature.<sup>121</sup> It is thought to be the most common inherited optic neuropathy in the Netherlands, with a population frequency of 1 in 12 000, and this much higher prevalence has been linked to a mutational founder event.<sup>122</sup>

The onset of symptoms in DOA is relatively insidious. In pre-molecular case series, 13–25% of patients with optic atrophy were visually asymptomatic and were only identified through contact tracing via other affected family members.<sup>123 124</sup> Classically, the visual decline starts in the first two decades of life, but there is a pronounced inter- and intra-familial variability in the severity of visual symptoms, which makes genetic counselling difficult. Visual acuity can range from 6/6 to the detection of hand movement only, and the rate of

progression of visual loss is not easy to predict, with 19–50% of patients experiencing further, albeit slow, deterioration on long term follow up.<sup>125–129</sup> Although the overall visual prognosis is better when compared to LHON, with a mean visual acuity of 6/24–6/36, DOA results in significant visual impairment with about half of all affected individuals failing the driving standards and 13–46% registered as legally blind.<sup>130–132</sup>

The predominant colour defect in DOA is a generalised dyschromatopsia, involving both the blue–yellow and red–green axes, with a minority of patients having pure tritanopia (<10%), which was once considered to be a pathognomonic feature of DOA.<sup>133</sup> Central, centrocaecal and paracentral scotomas are the most common field abnormalities with sparing of the periphery, findings consistent with the primary involvement of the papillomacular bundle in this condition. Interestingly, as in LHON, there is usually no afferent pupillary defect, suggesting that the retino-tectal fibres sub-serving the pupillary light reflex are less susceptible to the downstream effects of both the LHON mtDNA mutations and the causative nuclear genetic defects in DOA.<sup>134</sup> However, both magnocellular and parvocellular RGC pathways seem to be similarly affected, although this requires further investigation.<sup>127 131</sup>

The optic disc pallor in DOA falls into two main categories: diffuse pallor involving the entire neuro-retinal rim in about half of all cases, and a temporal wedge in the remainder (fig 3).<sup>123 135</sup> However, disc pallor can be subtle and 29% of affected patients had normal looking optic discs in one case series, highlighting the need to look carefully for other features of optic nerve dysfunction when assessing patients with a possible diagnosis of DOA.<sup>132</sup> Other common optic disc findings include saucerisation (79%), peripapillary atrophy (69%) and a cup to disc ratio >0.5 (48%).<sup>131 135 136</sup> The measurement of circumpapillary retinal nerve fibre layer thickness using optical coherence tomography (OCT) could also prove a useful adjunct in the diagnostic work-up of DOA, with recent studies showing a typical profile with bilateral symmetrical thinning around the optic disc, most pronounced in the temporal quadrant.<sup>137 138</sup>

### Ocular pathology

Postmortem studies of two patients with DOA identified similar histopathological changes, with diffuse atrophy of the RGC layer, loss of myelin and fibrillary gliosis along the anterior visual pathways extending to the lateral geniculate body.<sup>139 140</sup> More recent MRI data from patients with DOA have also confirmed significant tissue loss and thinning of the optic nerve along its entire length.<sup>141</sup> Although less pronounced, the

underlying ocular pathology in DOA is therefore remarkably similar to LHON, with the primary loss of RGCs leading to ascending optic atrophy.

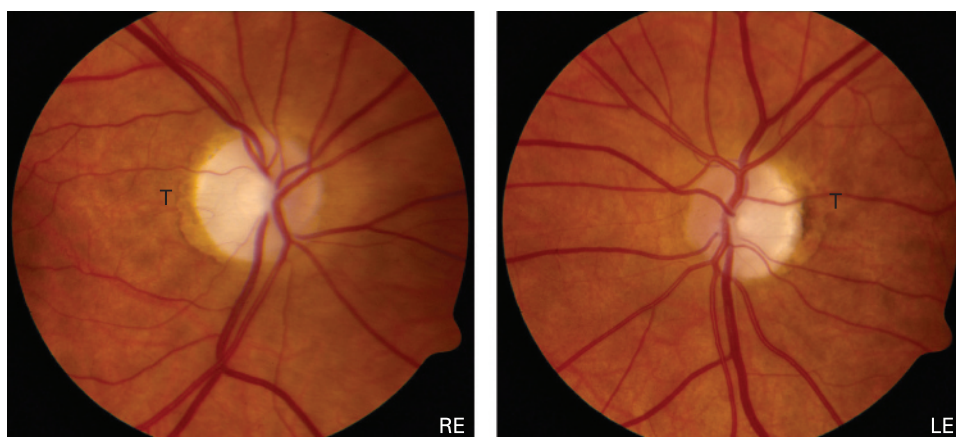
Visual electrophysiological findings are well documented in DOA and provide additional evidence for the primary loss of RGCs and the sparing of the outer retinal layers.<sup>133 142 143</sup> It can therefore be a useful ancillary test when determining affected status in borderline DOA cases and also in excluding a primary retinal process such as early cone dystrophy. VEPs are either absent or, if traces are recordable, they are of low amplitudes with abnormal latencies. PERGs can be within the normal range in up to 40% of clinically affected individuals but usually demonstrate an abnormal P50:N95 ratio, with selective depression of the N95 negative wave amplitude confirming a primary optic nerve pathology. Additional involvement of the P50 component correlates with the severity of visual loss, but PERGs are not extinguished even in cases where visual acuity is reduced to detection of hand movements or worse.

### Molecular genetics

The majority of DOA families show linkage to the *OPA1* locus at 3q28–q29, and in 2000 two independent research groups identified pathogenic mutations in the *OPA1* gene.<sup>144 145</sup> The proportion of *OPA1* positive families is ~60% (range 32–89%), the lower detection rates in some of these case series reflecting the inclusion of singleton cases, a heterogeneous group that is more likely to include non-inherited forms of optic neuropathy, and the use of less sensitive mutation screening protocols such as single strand conformational polymorphism (SSCP) analysis.<sup>146 147</sup> Interestingly, a recent report suggested that large scale rearrangements of entire *OPA1* coding regions could account for up to 20% of all *OPA1* negative cases.<sup>148</sup>

The causative nuclear defects in the remaining families with DOA have not yet been identified, but a small number of families have been mapped to other chromosomal loci—*OPA3*, *OPA4*, *OPA5* and *OPA7*, of which only the *OPA3* gene has been characterised (table 4). The *OPA3* gene was originally identified in eight Iraqi Jewish families with an autosomal recessive form of optic atrophy, associated with neurocognitive deficits, elevated urinary excretion of 3-methyl glutaconic acid, and increased plasma 3-methylglutaric acid levels (type III 3-methylglutaconic aciduria or Costeff syndrome).<sup>149–151</sup> However, pathogenic mutations in the *OPA3* gene have also been identified in two French families segregating both DOA and premature cataract in an autosomal dominant mode of inheritance (ADOAC).<sup>152 153</sup> The *Opa3* protein is located in the

**Figure 3** Typical fundal appearance in dominant optic atrophy showing bilateral optic disc pallor more marked in the temporal quadrant (LE, left eye; RE, right eye; T, temporal quadrant).



**Table 4** Dominant optic atrophy loci reported in *OPA1* negative families

	OMIM	Reported locus	Causative gene	Families (n)	Clinical features	Reference
OPA-3	606580	19q13.2–q13.3	<i>OPA3</i>	2	Optic atrophy + premature cataract	152
OPA-4	605293	18q12.2–q12.3	Unknown	1	Optic atrophy*	250
OPA-5	610708	22q12.1–q13.1	Unknown	2	Optic atrophy*	251
OPA-7	–	16q21–q22	Unknown	1	Optic atrophy + deafness	252

\*Similar clinical phenotype to *OPA1* positive families.

mitochondrial inner membrane but its exact function remains to be clarified. Preliminary findings in cultured fibroblasts from a patient with ADOAC indicate an increased susceptibility to apoptosis, and one can speculate that a similar mechanism is leading to RGC dysfunction via disruption of the mitochondrial respiratory chain.<sup>152 154 155</sup>

### **OPA1 mutations**

The *OPA1* gene consists of 30 exons spanning over 100 Kb of genomic DNA and it codes for a 960 amino acid, dynamin related GTPase protein located within the inner mitochondrial membrane. Alternative splicing of exons 4, 4b and 5b result in eight different mRNA isoforms, and both their functional relevance and subcellular localisation are currently being investigated.<sup>156</sup> Over 140 pathogenic mutations have been identified and these cluster in two specific regions: the GTPase region (exons 8–15) and the C-terminus which is the proposed site of the GTPase effector domain. The majority of *OPA1* mutations (~50%) lead to premature termination codons (PTCs) as a result of nonsense mutations or frameshifts from small insertions, deletions or splice site mutations (*eOPA1* database at <http://lbbma.univ-angers.fr/lbbma.php?id=9>).<sup>157</sup> These truncated mRNAs are unstable and get degraded by specific pathways (nonsense mediated mRNA decay), which are in-built protective cellular mechanisms against mutant proteins with possible dominant negative effects.<sup>158–160</sup> The reduced Opa1 protein expression levels observed in these cases support the role of haploinsufficiency in DOA and this is further substantiated by one family with a microdeletion resulting in complete loss of one copy of the *OPA1* gene.<sup>161</sup> However, ~30% of *OPA1* mutations are missense mutations within or close to the GTPase domain and these could exert their pathogenic effect via a deleterious, gain of function mechanism.<sup>162–164</sup>

### **Gene expression**

The spatial localisation and expression pattern of the Opa1 protein have been examined in a wide range of post-mitotic human and murine tissues. The Opa1 protein is highly expressed in the RGC layer but it is also found at comparable levels in the photoreceptor, inner and outer plexiform retinal layers.<sup>165 166</sup> In the human optic nerve, Opa1 was detected along the axonal tracts both in the pre- and post-lamina cribosa regions.<sup>167 168</sup> The Opa1 protein is ubiquitous and abundant levels have been identified in non-ocular tissues such as the inner ear and various areas of the human brain, with a similar distribution pattern of the different isoforms.<sup>169 170</sup> Overall, these immunohistochemical studies indicate that differential tissue expression of the *OPA1* gene or its isoforms do not seem to underlie the selective vulnerability of RGCs in DOA.

### **Protein function**

The Opa1 protein is part of the large, dynamin GTPase family of mechanoenzymes and it was first identified in a screen for

nuclear genes required for mtDNA maintenance in the budding yeast *Saccharomyces cerevisiae*. Both the human and yeast (Mgm1+) homologues show a high degree of evolutionary conservation and functional studies in DOA have revealed several other important cellular roles in addition to mtDNA maintenance.<sup>171 172</sup>

### **Mitochondrial maintenance**

Opa1 is an important pro-fusion protein and works in tandem with other members of the dynamin related mitofusin family (*mfn-1* and *mfn-2*) to balance the pro-fission effects of other GTPases such as *Drp1* and *Fis-1*.<sup>173 174</sup> It is therefore not surprising that mitochondrial network disruption is a key pathological feature seen in fibroblasts from DOA patients and other tissue cultures, including RGCs, where the expression of the Opa1 protein has been disrupted—for example, by small interfering RNAs.<sup>162 170 175 176</sup> Instead of a typical elongated, filamentous mitochondrial network, the latter becomes highly fragmented, with isolated mitochondria showing aberrant balloon-like enlargements. Transmission electron microscopy (TEM) also confirms altered mitochondrial ultrastructure with abnormal mitochondrial cristae organisation and paracrystalline inclusion bodies.<sup>162</sup>

Fusion is postulated to subserve a protective biological function by allowing the exchange and complementation of mitochondrial contents.<sup>177 178</sup> In this respect, neuronal cells with deficient mitochondrial fusion show a loss of mtDNA nucleoids and this important finding provides a possible disease mechanism, with the reduced expression of essential, mtDNA encoded, respiratory chain subunits resulting in a bioenergetic deficit, increased ROS levels and a greater susceptibility to undergo apoptosis.<sup>179 180</sup> These deleterious consequences could also contribute to the formation and clonal expansion of secondary mtDNA abnormalities such as mtDNA deletions, which have recently been identified in a subgroup of DOA families with a more complex multi-system involvement in addition to the optic neuropathy.<sup>162–164</sup>

### **Oxidative phosphorylation**

Impaired mitochondrial biogenesis is central to the pathophysiology in DOA and there is good experimental evidence to support a predominant complex I defect. There is reduced mitochondrial membrane potential and ATP synthesis in fibroblast cultures carrying pathogenic *OPA1* mutations,<sup>181 182</sup> and in vivo disturbance of oxidative metabolism was evident in the calf muscle of patients with DOA using <sup>31</sup>P-MRS.<sup>183</sup> Immunoprecipitation studies also suggest that the Opa1 protein, in conjunction with other structural proteins such as the apoptosis inducing factor (AIF), interacts directly with complexes I, II and III and plays an important role in the assembly and stabilisation of their various component subunits.<sup>176</sup> This provides another causal link between *OPA1* mutations and the resulting mitochondrial respiratory chain defect in DOA.

## Apoptosis

Apoptosis is the final common pathway leading to RGC loss in DOA and cell death is likely to be complex, being triggered by a combination of several interacting factors. Opa1 is processed by various, inner membrane proteases which include the presenilin associated rhomboid-like protein (Parl) and paraplegin, and this proteolytic cleavage results in a soluble, intermembrane form in addition to the integral, membrane bound form.<sup>184–186</sup> These two proteins combine into oligomers which modulate the morphology of the inner mitochondrial membrane and the tightness of the cristae junctions, a process independent of the role of Opa1 in controlling fusion.<sup>187</sup> Downregulation of Opa1 leads to aberrant cristae remodelling and the release of cytochrome *c* which is normally sequestered in the narrow junctions within the cristae.<sup>175–188</sup> This will either be sufficient on its own to induce the apoptotic cascade or will sensitise the cell to other pro-apoptotic stimuli such as AIF, increased ROS or the dissipation of the mitochondrial membrane potential.

## Animal models

There are now two established mouse models of DOA, with heterozygous mutations in exon 8 (c.1051C>T) and intron 10 (c.1065+5g>a) of the *OPA1* gene.<sup>189–190</sup> These two mutations are truncative, resulting in a 50% reduction in the expression of the Opa1 protein, and therefore represent a haploinsufficiency disease mechanism. In both models, homozygous mutant mice (*OPA1*−/−) died in utero during embryogenesis, highlighting the central role played by the Opa1 protein in early development. Heterozygous *OPA1*+/− mice faithfully replicated the human phenotype exhibiting a slowly progressive optic neuropathy and demonstrating objective reduction in visual function on psychophysical testing. There was a gradual loss of RGCs, leading to thinning of the retinal nerve fibre layer, and the surviving optic nerve axons had an abnormal morphology with swelling, distorted shapes, irregular areas of demyelination and myelin aggregates. Mitochondria within these axons showed disorganised cristae structures on TEM and cultured fibroblasts showed fragmentation of the mitochondrial network. These two *OPA1* mouse models represent powerful tools for dissecting the pathways mediating the preferential loss of RGCs in DOA, by allowing functional studies to be performed directly on these specialised cells, something which is not possible in humans given the lack of ocular tissues. These mutant mice will also prove useful when investigating the potential therapeutic benefit of future biological agents which could be injected into the vitreous cavity, allowing direct access with the RGC layer.

## Expanding phenotype

The hallmark of DOA is bilateral visual failure, but sensorineural deafness is a well reported association which is more commonly observed with some pathogenic mutations such as the p.R445H mutation.<sup>191–195</sup> In his original description, Kjer also documented neurodevelopmental abnormalities in 10% of his

Dutch cohort, although this has not been reported in other populations.<sup>120–125</sup> More recently, DOA families have been described where the optic atrophy was segregating with additional ocular and extraocular features such as progressive external ophthalmoplegia, ptosis, myopathy, ataxia, neuropathy, and an MS-like disorder.<sup>162–164–194</sup> These syndromal variants of DOA, so-called “DOA plus”, have been linked with the accumulation of multiple mtDNA deletions, a finding consistent with the presence of cytochrome *c* oxidase (COX) deficient fibres in limb muscle biopsies from affected individuals.<sup>195</sup> All of the causative *OPA1* mutations in these families were missense mutations with most, but not all of them, within the catalytic GTPase site of the protein. Although the actual proportion of families with these “DOA plus” phenotypes is as yet unknown, clinicians need to be aware of these additional clinical features as these can be subtle and therefore easily missed if not looked for specifically.

## Genetic counselling

There is currently no treatment to influence the disease process in DOA and clinical management, as for LHON, is supportive. Despite DOA being an autosomal dominant Mendelian disorder, genetic counselling for mutational carriers is difficult because of the pronounced inter- and intra-familial variability in the visual phenotype. There are no definite genotype–phenotype correlations but missense mutations within the GTPase protein domain are more likely to result in a complex, multi-systemic involvement, although it must be stressed that this observation requires further investigation in a larger cohort of DOA families.

With the availability of molecular testing for *OPA1* becoming more accessible, an increasing number of individuals with pathogenic mutations are being identified who are otherwise visually unaffected. The penetrance is >80% in well characterised, multi-generational families but figures as low as 43% have been reported, probably reflecting the different assessment criteria used (range 43–100%).<sup>132–196–197</sup> This incomplete penetrance together with the variable clinical expressivity in both pure DOA and “DOA plus” families clearly imply that other, as yet unidentified, secondary factors are potentiating the deleterious effects of the *OPA1* mutations.

## MITOCHONDRIAL OPTIC NEUROPATHIES

The concept of inherited mitochondrial optic neuropathies is expanding with evidence of impaired mitochondrial function in other genetic diseases where optic nerve dysfunction is a recognised clinical feature (table 5). These include: (1) Friedreich's ataxia where up to a third of cases have an optic neuropathy<sup>198–199</sup>; (2) hereditary motor and sensory neuropathy type 6 (HMSN-6), a variant of Charcot–Marie–Tooth (CMT) disease defined by the presence of both optic atrophy and peripheral neuropathy<sup>200–201</sup>; and (3) the hereditary spastic paraplegia (HSP).<sup>202–204</sup>

**Table 5** Other inherited optic neuropathies linked to mitochondrial dysfunction

Disease	OMIM	Inheritance	Gene (protein)	Protein function	References
Friedreich's ataxia	229300	Ar	<i>FXN</i> (frataxin)	Component of iron-sulfur clusters: regulation of mitochondrial respiratory chain activity and anti-oxidant properties	253, 254
HMSN-6	601152	Ad	<i>MFN2</i> (mitofusin-2)	Mitochondrial outer membrane GTPase: pro-fusion protein involved in maintenance of the mitochondrial network and mtDNA nucleoids (cf Opa1)	216, 217, 255
HSP-7	607259	Ar	<i>SPG7</i> (paraplegin)	Mitochondrial inner membrane protease: cleavage of Opa-1, control of mitochondrial ribosomal assembly and degradation of misfolded proteins	219, 256

Ar, autosomal recessive; Ad, autosomal dominant.



Glaucoma is the second most common cause of blindness in developed countries and accounts for about 10% of all blind registration in the UK.<sup>205</sup> It is a primary, acquired optic neuropathy with a strong genetic component and *OPA1* mutations have been identified in a number of patients initially diagnosed with normal tension glaucoma, highlighting the similarities in optic disc features shared with DOA.<sup>206–207</sup> It is of note therefore that some studies have shown an association between the risk of developing glaucoma and certain *OPA1* polymorphic variants,<sup>208–210</sup> with other investigators reporting mtDNA abnormalities in their glaucoma cohorts, such as an increased mtDNA copy number and reduced respiratory chain activities in peripheral blood lymphocytes.<sup>211</sup> Although further studies are needed, these findings suggest a possible mitochondrial influence on the pathogenesis of glaucoma.

### UNIFYING HYPOTHESIS

The common theme in the various optic neuropathies described in this review is the vulnerability of RGCs to mitochondrial dysfunction. Although there is a high level of mitochondrial enzyme activity in RGCs,<sup>212</sup> this phenomenon cannot be explained by a simple energetic deficit since photoreceptors have a much higher oxidative demand than RGCs and other mitochondrial disorders characterised by more severe complex I defects do not universally cause optic atrophy. It is possible that RGCs are preferentially involved because they are more sensitive to subtle imbalances in cellular redox state or increased ROS levels, but an attractive hypothesis implicates the differential mitochondrial concentration observed at the lamina cribosa.<sup>213</sup> The lamina cribosa is a perforated collagen plate that marks the anatomical transition from the unmyelinated (pre-laminar) to the myelinated (post-laminar) segment of the human optic nerve. The pre-laminar section has a much higher concentration of mitochondria to support the higher energy demands of unmyelinated nerve conduction and it is likely that active processes involving the cytoskeletal architecture are needed to maintain this sharp mitochondrial gradient.<sup>214–215</sup> Pathological mechanisms which disrupt this unique structural feature would lead to impaired axonal transport, as seen in CMT<sup>179–216–217</sup> and HSP,<sup>218–219</sup> and set up a vicious circle with fragmentation of the mitochondrial network at the lamina cribosa exacerbating even subtle mitochondrial energy deficits and eventually precipitating apoptotic cell death.

### CONCLUSION

LHON and DOA show an intriguing degree of clinical and mechanistic overlap, with both disorders caused by the selective degeneration of the RGC layer. They are the two most common inherited optic neuropathies and they provide strong evidence that the maintenance of RGCs is heavily dependent upon normal mitochondrial function. This is further substantiated by recent studies pointing towards a mitochondrial link in sporadic glaucoma and other genetic disorders where optic nerve dysfunction is a prominent clinical feature. Although major advances have been achieved in the two decades since the primary LHON mutations were identified, several key questions remain unanswered. What secondary factors account for the notable incomplete penetrance and male bias in LHON? What explains the variable disease expression in DOA, and why is there no gender bias in this disorder, given the similarity to LHON? What are the causative nuclear genes in *OPA1*-negative families and will they also involve mitochondrial dysfunction? What mechanisms underpin the preferential loss of RGCs in

these mitochondrial optic neuropathies? The characterisation of recently developed animal models and future genetic and functional studies will hopefully reveal important pathophysiological pathways amenable to therapeutic interventions.

**Acknowledgements:** PFC is a Wellcome Trust Senior Fellow in Clinical Science and PYWM is an MRC Clinical Research Fellow.

**Competing interests:** None.

### REFERENCES

1. **Schaefer AM**, McFarland R, Blakely EL, He L, Whittaker RG, Taylor RW, Chinnery PF, Turnbull DM. Prevalence of mitochondrial DNA disease in adults. *Ann Neurol* 2008;**63**:35–9.
2. **Elliott HR**, Samuels DC, Eden JA, Relton CL, Chinnery PF. Pathogenic mitochondrial DNA mutations are common in the general population. *Am J Hum Genet* 2008;**83**:254–60.
3. **Leber T**. Ueber hereditaere und congenital angelegte sehnervenleiden. *Graefes Arch Ophthalm* 1871;**17**:249–91.
4. **Bell J**. Hereditary optic atrophy (Leber's disease). In: Pearson K, ed. *The treasury of human inheritance*. Cambridge: Cambridge University Press, 1931:345–423.
5. **Imai Y**, Moriaki D. A probable case of cytoplasmic inheritance in man: a critique of Leber's disease. *J Genet* 1936;**33**:163–7.
6. **Lundsgaard R**. A genealogic, genetic and clinical study of 101 cases of retrobulbar optic neuritis in 20 Danish families. *Acta Ophthalmol* 1944;**21**:1–306.
7. **Wallace DC**, Singh G, Lott MT, Hodge JA, Schurr TG, Lezza AM, Elsas LJD, Nikoskelainen EK. Mitochondrial DNA mutation associated with Leber's hereditary optic neuropathy. *Science* 1988;**242**:1427–30.
8. **Mackey DA**, Oostra RJ, Rosenberg T, Nikoskelainen E, Bronte-Stewart J, Poulton J, Harding AE, Govan G, Bolhuis PA, Norby S. Primary pathogenic mtDNA mutations in multigeneration pedigrees with Leber hereditary optic neuropathy. *Am J Hum Genet* 1996;**59**:481–5.
9. **Mashima Y**, Yamada K, Wakakura M, Kigasawa K, Kudoh J, Shimizu N, Oguchi Y. Spectrum of pathogenic mitochondrial DNA mutations and clinical features in Japanese families with Leber's hereditary optic neuropathy. *Curr Eye Res* 1998;**17**:403–8.
10. **Yen MY**, Wang AG, Chang WL, Hsu WM, Liu JH, Wei YH. Leber's hereditary optic neuropathy—the spectrum of mitochondrial DNA mutations in Chinese patients. *Jpn J Ophthalmol* 2002;**46**:45–51.
11. **Macmillan C**, Kirkham T, Fu K, Allison V, Andermann E, Chitayat D, Fortier D, Gans M, Hare H, Quercia N, Zackon D, Shoubridge EA. Pedigree analysis of French Canadian families with T14484C Leber's hereditary optic neuropathy. *Neurology* 1998;**50**:417–22.
12. **Macmillan C**, Johns TA, Fu K, Shoubridge EA. Predominance of the T14484C mutation in French-Canadian families with Leber hereditary optic neuropathy is due to a founder effect [letter]. *Am J Hum Genet* 2000;**66**:332–5.
13. **Taylor RW**, Jobling MS, Turnbull DM, Chinnery PF. Frequency of rare mitochondrial DNA mutations in patients with suspected Leber's hereditary optic neuropathy. *J Med Genet* 2003;**40**:e85.
14. **Man PY**, Griffiths PG, Brown DT, Howell N, Turnbull DM, Chinnery PF. The epidemiology of Leber hereditary optic neuropathy in the North East of England. *Am J Hum Genet* 2003;**72**:333–9.
15. **Spruijt L**, Kolbach DN, de Coo RF, Plomp AS, Bauer NJ, Smeets HJ, de Die-Smulders CEM. Influence of mutation type on clinical expression of Leber hereditary optic neuropathy. *Am J Ophthalmol* 2006;**141**:676–82.
16. **Puomila A**, Hamalainen P, Kivioja S, Savontaus ML, Koivumaki S, Huoponen K, Nikoskelainen E. Epidemiology and penetrance of Leber hereditary optic neuropathy in Finland. *Eur J Hum Genet* 2007;**15**:1079–89.
17. **Mackey DA**, Buttery RG. Leber hereditary optic neuropathy in Australia. *Aust N Z J Ophthalmol* 1992;**20**:177–84.
18. **Yu-Wai-Man P**, Bateman DE, Hudson G, Griffiths PG, Chinnery PF. Leber hereditary optic neuropathy presenting in a 75-year-old man. *J Neuroophthalmol* 2008;**28**:155.
19. **Dagi LR**, Rizzo JF, 3rd, Cestari DM. Leber hereditary optic neuropathy in an octogenarian. *J Neuroophthalmol* 2008;**28**:156.
20. **Harding AE**, Sweeney MG, Govan GG, Riordan-Eva P. Pedigree analysis in Leber hereditary optic neuropathy families with a pathogenic mtDNA mutation. *Am J Hum Genet* 1995;**57**:77–86.
21. **Newman NJ**, Lott MT, Wallace DC. The clinical characteristics of pedigrees of Leber's hereditary optic neuropathy with the 11778 mutation. *Am J Ophthalmol* 1991;**111**:750–62.
22. **Johns DR**, Smith KH, Miller NR. Leber's hereditary optic neuropathy. Clinical manifestations of the 3460 mutation. *Arch Ophthalmol* 1992;**110**:1577–81.
23. **Johns DR**, Heher KL, Miller NR, Smith KH. Leber's hereditary optic neuropathy. Clinical manifestations of the 14484 mutation. *Arch Ophthalmol* 1993;**111**:495–8.
24. **Biousse V**, Brown MD, Newman NJ, Allen JC, Rosenfeld J, Meola G, Wallace DC. De novo 14484 mitochondrial DNA mutation in monozygotic twins discordant for Leber's hereditary optic neuropathy. *Neurology* 1997;**49**:1136–8.
25. **Savini G**, Barboni P, Valentino ML, Montagna P, Cortelli P, De Negri AM, Sadun F, Bianchi S, Longanesi L, Zanini M, Carelli V. Retinal nerve fiber layer evaluation by optical coherence tomography in unaffected carriers with Leber's hereditary optic neuropathy mutations. *Ophthalmology* 2005;**112**:127–31.

26. **Quiros PA**, Torres RJ, Salomao S, Berezovsky A, Carelli V, Sherman J, Sadun F, De Negri A, Belfort R, Sadun AA. Colour vision defects in asymptomatic carriers of the Leber's hereditary optic neuropathy (LHON) mtDNA 11778 mutation from a large Brazilian LHON pedigree: a case-control study. *Br J Ophthalmol* 2006;**90**:150-3.
27. **Sadun AA**, Salomao SR, Berezovsky A, Sadun F, Denegri AM, Quiros PA, Chicani F, Ventura D, Barboni P, Sherman J, Sutter E, Belfort R Jr, Carelli V, Patsi J, Kervinen M, Finel M, Hassinen IE. Subclinical carriers and conversions in Leber hereditary optic neuropathy: a prospective psychophysical study. *Trans Am Ophthalmol Soc* 2006;**104**:51-61.
28. **Nikoskelainen EK**, Huoponen K, Juvonen V, Lamminen T, Nummelin K, Savontaus ML. Ophthalmologic findings in Leber hereditary optic neuropathy, with special reference to mtDNA mutations. *Ophthalmology* 1996;**103**:504-14.
29. **Sugisaka E**, Ohde H, Shinoda K, Mashima Y. Woman with atypical unilateral Leber's hereditary optic neuropathy with visual improvement. *Clin Exp Ophthalmol* 2007;**35**:868-70.
30. **Nikoskelainen EK**. Clinical picture of LHON. *Clin Neurosci* 1994;**2**:115-20.
31. **Riordan-Eva P**, Harding AE. Leber's hereditary optic neuropathy: the clinical relevance of different mitochondrial DNA mutations. *J Med Genet* 1995;**32**:81-7.
32. **Mackey D**, Howell N. A variant of Leber hereditary optic neuropathy characterized by recovery of vision and by an unusual mitochondrial genetic etiology. *Am J Hum Genet* 1992;**51**:1218-28.
33. **Stone EM**, Newman NJ, Miller NR, Johns DR, Lott MT, Wallace DC. Visual recovery in patients with Leber's hereditary optic neuropathy and the 11778 mutation. *J Clin Neuroophthalmol* 1992;**12**:10-4.
34. **Barboni P**, Savini G, Valentino ML, La Morgia C, Bellusci C, De Negri AM, Sadun F, Carta A, Carbonelli M, Sadun AA, Carelli V. Leber's hereditary optic neuropathy with childhood onset. *Invest Ophthalmol Vis Sci* 2006;**47**:5303-9.
35. **Bower SP**, Hawley I, Mackey DA. Cardiac arrhythmia and Leber's hereditary optic neuropathy [letter]. *Lancet* 1992;**339**:1427-8.
36. **Nikoskelainen EK**, Savontaus ML, Huoponen K, Antila K, Hartiala J. Pre-excitation syndrome in Leber's hereditary optic neuropathy. *Lancet* 1994;**344**:857-8.
37. **Nikoskelainen EK**, Marttila RJ, Huoponen K, Juvonen V, Lamminen T, Sonninen P, Savontaus ML. Leber's "plus": neurological abnormalities in patients with Leber's hereditary optic neuropathy. *J Neurol Neurosurg Psychiatry* 1995;**59**:160-4.
38. **Meire FM**, Van Coster R, Cochaux P, Obermaier-Kusser B, Candaele C, Martin JJ. Neurological disorders in members of families with Leber's hereditary optic neuropathy (LHON) caused by different mitochondrial mutations. *Ophthalmol Genet* 1995;**16**:119-26.
39. **Mashima Y**, Kigasawa K, Hasegawa H, Tani M, Oguchi Y. High incidence of pre-excitation syndrome in Japanese families with Leber's hereditary optic neuropathy. *Clin Genet* 1996;**50**:535-7.
40. **De Vries DD**, Went LN, Bruyn GW, Scholte HR, Hofstra RM, Bolhuis PA, van Oost BA. Genetic and biochemical impairment of mitochondrial complex I activity in a family with Leber hereditary optic neuropathy and hereditary spastic dystonia. *Am J Hum Genet* 1996;**58**:703-11.
41. **Howell N**, Kubacka I, Xu M, McCullough DA. Leber hereditary optic neuropathy: involvement of the mitochondrial ND1 gene and evidence for an intragenic suppressor mutation. *Am J Hum Genet* 1991;**48**:935-42.
42. **Jun AS**, Brown MD, Wallace DC. A mitochondrial DNA mutation at nucleotide pair 14459 of the NADH dehydrogenase subunit 6 gene associated with maternally inherited Leber hereditary optic neuropathy and dystonia. *Proc Natl Acad Sci USA* 1994;**91**:6206-10.
43. **Gropman A**, Chen TJ, Perng CL, Krasnewich D, Chernoff E, Tiff C, Wong LJ. Variable clinical manifestation of homoplasmic G14459A mitochondrial DNA mutation. *Am J Med Genet Part A* 2004;**124**:377-82.
44. **Tarnopolsky MA**, Baker SK, Myint T, Maxner CE, Robitaille J, Robinson BH. Clinical variability in maternally inherited Leber hereditary optic neuropathy with the G14459A mutation. *Am J Med Genet Part A* 2004;**124**:372-6.
45. **Blakely EL**, de Silva R, King A, Schwarzer V, Harrower T, Dawidek G, Turnbull DM, Taylor RW. LHON/MELAS overlap syndrome associated with a mitochondrial MTND1 gene mutation. *Eur J Hum Genet* 2005;**13**:623-7.
46. **Spruijt L**, Smeets HJ, Hendrickx A, Bettink-Remeijer MW, Maat-Kievit A, Schoonderwoerd KC, Sluiter W, de Coo IF, Hintzen RQ. A MELAS-associated ND1 mutation causing Leber hereditary optic neuropathy and spastic dystonia. *Arch Neurol* 2007;**64**:890-3.
47. **Harding AE**, Sweeney MG, Miller DH, Mumford CJ, Kellar-Wood H, Menard D, McDonald WI, Compston DA. Occurrence of a multiple sclerosis-like illness in women who have a Leber's hereditary optic neuropathy mitochondrial DNA mutation. *Brain* 1992;**115**:979-89.
48. **Kellar-Wood H**, Robertson N, Govan GG, Compston DA, Harding AE. Leber's hereditary optic neuropathy mitochondrial DNA mutations in multiple sclerosis. *Ann Neurol* 1994;**36**:109-12.
49. **Jansen PH**, van der Knaap MS, de Coo IF. Leber's hereditary optic neuropathy with the 11778 mtDNA mutation and white matter disease resembling multiple sclerosis: clinical, MRI and MRS findings. *J Neurol Sci* 1996;**135**:176-80.
50. **Vanopdenbosch L**, Dubois B, D'Hooghe MB, Meire F, Carton H. Mitochondrial mutations of Leber's hereditary optic neuropathy: a risk factor for multiple sclerosis. *J Neurol* 2000;**247**:535-43.
51. **Govan GG**, Smith PR, Kellar-Wood H, Schapira AH, Harding AE. HLA class II genotypes in Leber's hereditary optic neuropathy. *J Neurol Sci* 1994;**126**:193-6.
52. **Smith PR**, Cooper JM, Govan GG, Riordan-Eva P, Harding AE, Schapira AH. Antibodies to human optic nerve in Leber's hereditary optic neuropathy. *J Neurol Sci* 1995;**130**:134-8.
53. **Chalmers RM**, Govan GG, Schapira AH, Harding AE. HLA class I genotypes in Leber's hereditary optic neuropathy. *J Neurol Sci* 1996;**135**:173-5.
54. **Sapey E**, Burdon MA, Nightingale S. Evidence of active demyelination in a man with Leber's hereditary optic neuropathy mtDNA 14484 genotype. *Neuro-Ophthalmology* 2001;**26**:119-26.
55. **Kovacs GG**, Hoftberger R, Majtenyi K, Horvath R, Barsi P, Komoly S, Lassmann H, Budka H, Jakab G. Neuropathology of white matter disease in Leber's hereditary optic neuropathy. *Brain* 2005;**128**:35-41.
56. **Sherman J**, Kleiner L. Visual-system dysfunction in Lebers hereditary optic neuropathy. *Clin Neurosci* 1994;**2**:121-9.
57. **Smith JL**, Tse DT, Byrne SF, Johns DR, Stone EM. Optic nerve sheath distention in Leber's optic neuropathy and the significance of the "Wallace mutation". *J Clin Neuroophthalmol* 1990;**10**:231-8.
58. **de Gottrau P**, Buchi ER, Daicker B. Distended optic nerve sheaths in Leber's hereditary optic neuropathy. *J Clin Neuroophthalmol* 1992;**12**:89-93.
59. **Dotti MT**, Caputo N, Signorini E, Federico A. Magnetic resonance imaging findings in Leber's hereditary optic neuropathy. *Eur Neurol* 1992;**32**:17-9.
60. **Mashima Y**, Oshitari K, Imamura Y, Momoshima S, Shiga H, Oguchi Y. Orbital high resolution magnetic resonance imaging with fast spin echo in the acute stage of Leber's hereditary optic neuropathy. *J Neurol Neurosurg Psychiatry* 1998;**64**:124-7.
61. **Vaphiades MS**, Newman NJ. Optic nerve enhancement on orbital magnetic resonance imaging in Leber's hereditary optic neuropathy. *J Neuroophthalmol* 1999;**19**:238-9.
62. **Inglese M**, Rovaris M, Bianchi S, Mancardi GL, Ghezzi A, Salvi F, Cortelli P, Filippi M. MRI, MTI, and DWI study of the optic nerve, brain, and cervical cord from patients with Leber hereditary optic neuropathy. *Neurology* 2000;**54**:A320-A.
63. **Barbiroli B**, Montagna P, Cortelli P, Iotti S, Lodi R, Barboni P, Monari L, Lugaresi E, Frassinetti C, Zaniol P. Defective brain and muscle energy metabolism shown by in vivo 31P magnetic resonance spectroscopy in nonaffected carriers of 11778 mtDNA mutation. *Neurology* 1995;**45**:1364-9.
64. **Cortelli P**, Montagna P, Pierangeli G, Lodi R, Barboni P, Liguori R, Carelli V, Iotti S, Zaniol P, Lugaresi E, Barbiroli B. Clinical and brain bioenergetics improvement with idebenone in a patient with Leber's hereditary optic neuropathy: a clinical and 31P-MRS study. *J Neurol Sci* 1997;**148**:25-31.
65. **Lodi R**, Taylor DJ, Tabrizi SJ, Kumar S, Sweeney M, Wood NW, Styles P, Radda GK, Schapira AHV. In vivo skeletal muscle mitochondrial function in Leber's hereditary optic neuropathy assessed by P-31 magnetic resonance spectroscopy. *Ann Neurol* 1997;**42**:573-9.
66. **Lodi R**, Montagna P, Cortelli P, Iotti S, Cevoli S, Carelli V, Barbiroli B. 'Secondary' 4216/ND1 and 13708/ND5 Leber's hereditary optic neuropathy mitochondrial DNA mutations do not further impair in vivo mitochondrial oxidative metabolism when associated with the 11778/ND4 mitochondrial DNA mutation. *Brain* 2000;**123**:1896-902.
67. **Lodi R**, Carelli V, Cortelli P, Iotti S, Valentino ML, Barboni P, Pallotti F, Montagna P, Barbiroli B. Phosphorus MR spectroscopy shows a tissue specific in vivo distribution of biochemical expression of the G3460A mutation in Leber's hereditary optic neuropathy. *J Neuro Neurosurg Psychiatry* 2002;**72**:805-7.
68. **Beretta S**, Mattavelli L, Sala G, Tremolizzo L, Schapira AH, Martinuzzi A, Carelli V, Ferrarese C. Leber hereditary optic neuropathy mtDNA mutations disrupt glutamate transport in cybrid cell lines. *Brain* 2004;**127**:2183-92.
69. **Beretta S**, Wood JPM, Derham B, Sala G, Tremolizzo L, Ferrarese C, Osborne NN. Partial mitochondrial complex I inhibition induces oxidative damage and perturbs glutamate transport in primary retinal cultures. Relevance to Leber hereditary optic neuropathy (LHON). *Neurobiol Dis* 2006;**24**:308-17.
70. **Florenzi M**, Napoli E, Martinuzzi A, Pantano G, De Riva V, Trevisan R, Bisetto E, Valente L, Carelli V, Dabbeni-Sala F. Antioxidant defences in cybrids harboring mtDNA mutations associated with Leber's hereditary optic neuropathy. *Febs J* 2005;**272**:1124-35.
71. **Carelli V**, Rugolo M, Sgarbi G, Ghelli A, Zanna C, Baracca A, Lenaz G, Napoli E, Martinuzzi A, Solaini G. Bioenergetics shapes cellular death pathways in Leber's hereditary optic neuropathy: a model of mitochondrial neurodegeneration. *Biochim Biophys Acta Bioenerg* 2004;**1658**:172-9.
72. **Danielson SR**, Wong A, Carelli V, Martinuzzi A, Schapira AH, Cortopassi GA. Cells bearing mutations causing Leber's hereditary optic neuropathy are sensitized to Fas-induced apoptosis. *J Biol Chem* 2002;**277**:5810-5.
73. **Zanna C**, Ghelli A, Porcelli AM, Martinuzzi A, Carelli V, Rugolo M. Caspase-independent death of Leber's hereditary optic neuropathy cybrids is driven by energetic failure and mediated by AIF and endonuclease G. *Apoptosis* 2005;**10**:997-1007.
74. **Klivenyi P**, Karg E, Rozsa C, Horvath R, Komoly S, Nemeth I, Turi S, Vecsei L. alpha-Tocopherol/lipid ratio in blood is decreased in patients with Leber's hereditary optic neuropathy and asymptomatic carriers of the 11778 mtDNA mutation. *J Neurol Neurosurg Psychiatry* 2001;**70**:359-62.
75. **Yen MY**, Kao SH, Wang AG, Wei YH. Increased 8-hydroxy-2'-deoxyguanosine in leukocyte DNA in Leber's hereditary optic neuropathy. *Invest Ophthalmol Vis Sci* 2004;**45**:1688-91.
76. **Zhang X**, Jones D, Gonzalez-Lima F. Mouse model of optic neuropathy caused by mitochondrial complex I dysfunction. *Neurosci Lett* 2002;**326**:97-100.
77. **Qi XP**, Lewin AS, Hauswirth WW, Guy J. Suppression of complex I gene expression induces optic neuropathy. *Ann Neurol* 2003;**53**:198-205.
78. **Qi XP**, Sun L, Lewin AS, Hauswirth WW, Guy J. The mutant human ND4 subunit of complex I induces optic neuropathy in the mouse. *Invest Ophthalmol Vis Sci* 2007;**48**:1-10.

79. **Smith KH**, Johns DR, Heher KL, Miller NR. Heteroplasmy in Leber's hereditary optic neuropathy. *Arch Ophthalmol* 1993;**111**:1486–90.
80. **Chinnery PF**, Andrews RM, Turnbull DM, Howell NN. Leber hereditary optic neuropathy: does heteroplasmy influence the inheritance and expression of the G11778A mitochondrial DNA mutation? *Am J Med Genet* 2001;**98**:235–43.
81. **Brown WM**, George M Jr, Wilson AC. Rapid evolution of animal mitochondrial DNA. *Proc Natl Acad Sci USA* 1979;**76**:1967–71.
82. **Wallace DC**, Brown MD, Lott MT. Mitochondrial DNA variation in human evolution and disease. *Gene* 1999;**238**:211–30.
83. **Torroni A**, Huoponen K, Francalacci P, Petrozzi M, Morelli L, Scozzari R, Obinu D, Savontaus ML, Wallace DC. Classification of European mtDNAs from an analysis of three European populations. *Genetics* 1996;**144**:1835–50.
84. **Hofmann S**, Jaksch M, Bezold R, Mertens S, Aholt S, Paprotta A, Gerbitz KD. Population genetics and disease susceptibility: characterization of central European haplogroups by mtDNA gene mutations, correlation with D loop variants and association with disease. *Hum Mol Genet* 1997;**6**:1835–46.
85. **Hudson G**, Carelli V, Spruijt L, Gerards M, Mowbray C, Achilli A, Pyle A, Elson J, Howell N, La Morgia C, Valentino ML, Huoponen K, Savontaus ML, Nikoskelainen E, Sadun AA, Salomao SR, Belfort R, Griffiths P, Man PYW, de Coe RFM, Horvath R, Zeviani M, Smeets HJT, Torroni A, Chinnery PF. Clinical expression of Leber hereditary optic neuropathy is affected by the mitochondrial DNA-haplogroup background. *Am J Hum Genet* 2007;**81**:228–33.
86. **Dudkina NV**, Eubel H, Keegstra W, Boekema EJ, Braun HP. Structure of a mitochondrial supercomplex formed by respiratory-chain complexes I and III. *Proc Natl Acad Sci USA* 2005;**102**:3225–9.
87. **Carelli V**, Achilli A, Valentino ML, Rengo C, Semino O, Pala M, Olivieri A, Mattiazzi M, Pallotti F, Carrara F, Zeviani M, Leuzzi V, Carducci C, Valle G, Simionati B, Mendietta L, Salomao S, Belfort R Jr, Sadun AA, Torroni A. Haplogroup effects and recombination of mitochondrial DNA: novel clues from the analysis of Leber hereditary optic neuropathy pedigrees. *Am J Hum Genet* 2006;**78**:564–74.
88. **Vergani L**, Martinuzzi A, Carelli V, Cortelli P, Montagna P, Schievano G, Carrozzo R, Angelini C, Lugaresi E. MtDNA mutations associated with Leber's hereditary optic neuropathy: studies on cytoplasmic hybrid (cybrid) cells. *Biochem Biophys Res Commun* 1995;**210**:880–8.
89. **Tharaphan P**, Chuenkongkaew WL, Luangtrakool K, Sanpachudayan T, Suktipat B, Suphavitai R, Srisawat C, Sura T, Lertrit P. Mitochondrial DNA haplogroup distribution in pedigrees of Southeast Asian G11778A Leber hereditary optic neuropathy. *J Neuroophthalmol* 2006;**26**:264–7.
90. **Bu XD**, Rotter JL. X chromosome-linked and mitochondrial gene control of Leber hereditary optic neuropathy: evidence from segregation analysis for dependence on X chromosome inactivation. *Proc Natl Acad Sci USA* 1991;**88**:8198–202.
91. **Bu X**, Rotter JL. Leber hereditary optic neuropathy: estimation of number of embryonic precursor cells and disease threshold in heterozygous affected females at the X-linked locus. *Clin Genet* 1992;**42**:143–8.
92. **Nakamura M**, Fujiwara Y, Yamamoto M. The two locus control of Leber hereditary optic neuropathy and a high penetrance in Japanese pedigrees. *Hum Genet* 1993;**91**:339–41.
93. **Pegoraro E**, Carelli V, Zeviani M, Cortelli P, Montagna P, Barboni P, Angelini C, Hoffman EP. X-inactivation patterns in female Leber's hereditary optic neuropathy patients do not support a strong X-linked determinant. *Am J Med Genet* 1996;**61**:356–62.
94. **Oostra RJ**, Kemp S, Bolhuis PA, Bleeker-Wagemakers EM. No evidence for 'skewed' inactivation of the X-chromosome as cause of Leber's hereditary optic neuropathy in female carriers. *Hum Genet* 1996;**97**:500–5.
95. **Hudson G**, Carelli V, Horvath R, Zeviani M, Smeets HJ, Chinnery PF. X-inactivation patterns in females harboring mtDNA mutations that cause Leber hereditary optic neuropathy. *Mol Vis* 2007;**13**:2339–43.
96. **Chen JD**, Cox I, Denton MJ. Preliminary exclusion of an X-linked gene in Leber optic atrophy by linkage analysis. *Hum Genet* 1989;**82**:203–7.
97. **Carvalho MR**, Muller B, Rotzer E, Berninger T, Kommerell G, Blankenagel A, Savontaus ML, Meitinger T, Lorenz B. Leber's hereditary optic neuroretinopathy and the X-chromosomal susceptibility factor: no linkage to DXs7. *Hum Hered* 1992;**42**(5):316–20.
98. **Sweeney MG**, Davis MB, Lashwood A, Brockington M, Toscano A, Harding AE. Evidence against an X-linked locus close to DXS7 determining visual loss susceptibility in British and Italian families with Leber hereditary optic neuropathy. *Am J Hum Genet* 1992;**51**:741–8.
99. **Handoko HY**, Wirapati PJ, Sudoyo HA, Sitepu M, Marzuki S. Meiotic breakpoint mapping of a proposed X linked visual loss susceptibility locus in Leber's hereditary optic neuropathy. *J Med Genet* 1998;**35**:668–71.
100. **Hudson G**, Keers S, Man PYW, Griffiths P, Huoponen K, Savontaus ML, Nikoskelainen E, Zeviani M, Carrara F, Horvath R, Karcagi V, Spruijt L, de Coe IFM, Smeets HJM, Chinnery PF. Identification of an X-chromosomal locus and haplotype modulating the phenotype of a mitochondrial DNA disorder. *Am J Hum Genet* 2005;**77**:1086–91.
101. **Shankar SP**, Fingert JH, Carelli V, Valentino ML, King TM, Daiger SP, Salomao SR, Berezovsky A, Belfort R Jr, Braun TA, Sheffield VC, Sadun AA, Stone EM. Evidence for a novel x-linked modifier locus for Leber hereditary optic neuropathy. *Ophthalmic Genet* 2008;**29**:17–24.
102. **Nikoskelainen EK**, Savontaus ML, Wanne OP, Katila MJ, Nummelin KU. Leber's hereditary optic neuroretinopathy, a maternally inherited disease. A genealogic study in four pedigrees. *Arch Ophthalmol* 1987;**105**:665–71.
103. **Johns DR**, Smith KH, Miller NR, Sulewski ME, Bias WB. Identical twins who are discordant for Leber's hereditary optic neuropathy. *Arch Ophthalmol* 1993;**111**:1491–4.
104. **Lam BL**. Identical twins no longer discordant for Leber's hereditary optic neuropathy [letter]. *Arch Ophthalmol* 1998;**116**:956–7.
105. **Riordan-Eva P**, Sanders MD, Govan GG, Sweeney MG, Da Costa J, Harding AE. The clinical features of Leber's hereditary optic neuropathy defined by the presence of a pathogenic mitochondrial DNA mutation. *Brain* 1995;**118**:319–37.
106. **Charlmers RM**, Harding AE. A case-control study of Leber's hereditary optic neuropathy. *Brain* 1996;**119**:1481–6.
107. **Tsao K**, Aitken PA, Johns DR. Smoking as an aetiological factor in a pedigree with Leber's hereditary optic neuropathy. *Br J Ophthalmol* 1999;**83**:577–81.
108. **Sadun AA**, Carelli V, Salomao SR, Berezovsky A, Quiros PA, Sadun F, DeNegri AM, Andrade R, Moraes M, Passos A, Kjaer P, Pereira J, Valentino ML, Schein S, Belfort R. Extensive investigation of a large Brazilian pedigree of 11778/haplogroup J Leber hereditary optic neuropathy. *Am J Ophthalmol* 2003;**136**:231–8.
109. **Kerrison JB**, Miller NR, Hsu F, Beaty TH, Maumenee IH, Smith KH, Savino PJ, Stone EM, Newman NJ. A case-control study of tobacco and alcohol consumption in Leber hereditary optic neuropathy. *Am J Ophthalmol* 2000;**130**:803–12.
110. **Mackey DA**, Fingert JH, Luzhansky JZ, McCluskey PJ, Howell N, Hall AJH, Pierce AB, Hoy JF. Leber's hereditary optic neuropathy triggered by antiretroviral therapy for human immunodeficiency virus. *Eye* 2003;**17**:312–7.
111. **Sanchez RN**, Smith AJ, Carelli V, Sadun AA, Keltner JL. Leber hereditary optic neuropathy possibly triggered by exposure to tire fire. *J Neuroophthalmol* 2006;**26**:268–72.
112. **Carelli V**, Franceschini F, Venturi S, Barboni P, Savini G, Barbieri G, Pirro E, La Morgia C, Valentino ML, Zanardi F, Violante FS, Mattioli S. Grand rounds: could occupational exposure to n-hexane and other solvents precipitate visual failure in Leber hereditary optic neuropathy? *Environ Health Perspect* 2007;**115**:113–5.
113. **Howell N**, Mackey DA. Low-penetrance branches in matrilineal pedigrees with Leber hereditary optic neuropathy. *Am J Hum Genet* 1998;**63**:1220–4.
114. **Sadun F**, De Negri AM, Carelli V, Salomao SR, Berezovsky A, Andrade R, Moraes M, Passos A, Belfort R, Da Rosa AB, Quiros P, Sadun AA. Ophthalmologic findings in a large pedigree of 11778/Haplogroup J Leber hereditary optic neuropathy. *Am J Ophthalmol* 2004;**137**:271–7.
115. **Mashima Y**, Kigasawa K, Wakamura M, Oguchi Y. Do idebenone and vitamin therapy shorten the time to achieve visual recovery in Leber hereditary optic neuropathy? *J Neuroophthalmol* 2000;**20**:166–70.
116. **Carelli V**, Valentino ML, Liguori R, Meletti S, Vetrugno R, Provini F, Mancardi GL, Bandini F, Baruzzi A, Montagna P. Leber's hereditary optic neuropathy (LHON/11778) with myoclonus: report of two cases. *J Neurol Neurosurg Psychiatry* 2001;**71**:813–6.
117. **Barnils N**, Mesa E, Munoz S, Ferrer-Artola A, Arruga J. Response to idebenone and multivitamin therapy in Leber's hereditary optic neuropathy. *Arch Soc Esp Ophthalmol* 2007;**82**:377–80.
118. **Newman NJ**, Biousse V, David R, Bhatti MT, Hamilton SR, Farris BK, Lesser RL, Newman SA, Turbin RE, Chen K, Keane RP. Prophylaxis for second eye involvement in Leber hereditary optic neuropathy: an open-labeled, nonrandomized multicenter trial of topical brimonidine purite. *Am J Ophthalmol* 2005;**140**:407–15.
119. **Batten B**. A family suffering from hereditary optic atrophy. *Transactions of the Ophthalmological Society UK* 1896;**16**:125.
120. **Kjer B**. Infantile optic atrophy with dominant transmission. *Dan Med Bull* 1956;**3**:135–41.
121. **Lyle WM**. *Genetic risks. A reference for eye care practitioners*. Waterloo, Ontario, Canada: University of Waterloo Press, 1990.
122. **Thiselton DL**, Alexander C, Morris A, Brooks S, Rosenberg T, Eiberg H, Kjer B, Kjer P, Bhattacharya SS, Votruba M. A frameshift mutation in exon 28 of the OPA1 gene explains the high prevalence of dominant optic atrophy in the Danish population: evidence for a founder effect. *Hum Genet* 2001;**109**:498–502.
123. **Kline LB**, Glaser JS. Dominant optic atrophy – clinical profile. *Arch Ophthalmol* 1979;**97**:1680–6.
124. **Hoyt CS**. Autosomal dominant optic atrophy – a spectrum of disability. *Ophthalmology* 1980;**87**:245–51.
125. **Kjer P**. Infantile optic atrophy with dominant mode of inheritance: a clinical and genetic study of 19 Danish families. *Acta Ophthalmol* 1959;(Suppl 54):1–146.
126. **Elliott D**, Traboulsi EI, Maumenee IH. Visual prognosis in autosomal dominant optic atrophy (Kjer type). *Am J Ophthalmol* 1993;**115**:360–7.
127. **Votruba M**, Moore AT, Bhattacharya SS. Clinical features, molecular genetics, and pathophysiology of dominant optic atrophy. *J Med Genet* 1998;**35**:793–800.
128. **Puomila A**, Huoponen K, Mantylajarvi M, Hamalainen P, Paananen R, Sankila EM, Savontaus ML, Somer M, Nikoskelainen E. Dominant optic atrophy: correlation between clinical and molecular genetic studies. *Acta Ophthalmol Scandinavica* 2005;**83**:337–46.
129. **Cohn AC**, Toomes C, Hewitt AW, Kearns LS, Inglehearn CF, Craig JE, Mackey DA. The natural history of OPA1-related autosomal dominant optic atrophy. *Br J Ophthalmol* 2008;**24**:24.
130. **Kjer B**, Eiberg H, Kjer P, Rosenberg T. Dominant optic atrophy mapped to chromosome 3q region. II. Clinical and epidemiological aspects. *Acta Ophthalmol Scandinavica* 1996;**74**:3–7.
131. **Votruba M**, Fitzke FW, Holder GE, Carter A, Bhattacharya SS, Moore AT. Clinical features in affected individuals from 21 pedigrees with dominant optic atrophy. *Arch Ophthalmol* 1998;**116**:351–8.

132. **Cohn AC**, Toomes C, Potter C, Towns KV, Hewitt AW, Inglehearn CF, Craig JE, Mackey DA. Autosomal dominant optic atrophy: penetrance and expressivity in patients with OPA1 mutations. *Am J Ophthalmol* 2007;**143**:656–62.
133. **Berninger TA**, Jaeger W, Krastel H. Electrophysiology and color perimetry in dominant infantile optic atrophy. *Br J Ophthalmol* 1991;**75**:49–52.
134. **Bremner FD**, Tomlin EA, Shallo-Hoffmann J, Votruba M, Smith SE. The pupil in dominant optic atrophy. *Invest Ophthalmol Vis Sci* 2001;**42**:675–8.
135. **Votruba M**, Thiselton D, Bhattacharya SS. Optic disc morphology of patients with OPA1 autosomal dominant optic atrophy. *Br J Ophthalmol* 2003;**87**:48–53.
136. **Fournier AV**, Damji KF, Epstein DL, Pollock SC. Disc excavation in dominant optic atrophy. *Ophthalmology* 2001;**108**:1595–602.
137. **Ito Y**, Nakamura M, Yamakoshi T, Lin J, Yatsuya H, Terasaki H. Reduction of inner retinal thickness in patients with autosomal dominant optic atrophy associated with OPA1 mutations. *Invest Ophthalmol Vis Sci* 2007;**48**:4079–86.
138. **Kim TW**, Hwang JM. Stratus OCT in dominant optic atrophy: features differentiating it from glaucoma. *J Glaucoma* 2007;**16**:655–8.
139. **Johnston PB**, Gaster RN, Smith VC, Tripathi RC. Clinicopathologic study of autosomal dominant optic atrophy. *Am J Ophthalmol* 1979;**88**:868–75.
140. **Kjer P**, Jensen OA, Klinken L. Histopathology of eye, optic-nerve and brain in a case of dominant optic atrophy. *Acta Ophthalmol* 1983;**61**:300–12.
141. **Votruba M**, Leary S, Losseff N, Bhattacharya SS, Moore AT, Miller DH, Moseley IF. MRI of the intraorbital optic nerve in patients with autosomal dominant optic atrophy. *Neuroradiology* 2000;**42**:180–3.
142. **Delperto G**, Vingolo EM, Steindl K, Forte R, Iannaccone A, Rispoli E, Pannarale MR. Clinical heterogeneity of dominant optic atrophy – the contribution of visual function investigations to diagnosis. *Graefes Arch Clin Exp Ophthalmol* 1994;**232**:717–27.
143. **Holder GE**, Votruba M, Carter AC, Bhattacharya SS, Fitzke FW, Moore AT. Electrophysiological findings in dominant optic atrophy (DOA) linking to the OPA1 locus on chromosome 3q 28-pter. *Doc Ophthalmol* 1998;**95**:217–28.
144. **Alexander C**, Votruba M, Pesch UEA, Thiselton DL, Mayer S, Moore A, Rodriguez M, Kellner U, Leo-Kottler B, Auburger G, Bhattacharya SS, Wissinger B. OPA1, encoding a dynamin-related GTPase, is mutated in autosomal dominant optic atrophy linked to chromosome 3q28. *Nat Genet* 2000;**26**:211–5.
145. **Delettre C**, Lenaers G, Griffon JM, Gigarel N, Lorenzo C, Belenguer P, Pelloquin L, Grosgeorge J, Turc-Carel C, Perret E, Astarie-Dequeker C, Lasquellac L, Arnaud B, Duccommun B, Kaplan J, Hamel CP. Nuclear gene OPA1, encoding a mitochondrial dynamin-related protein, is mutated in dominant optic atrophy. *Nat Genet* 2000;**26**:207–10.
146. **Davies V**, Votruba M. Focus on molecules: the OPA1 protein. *Exp Eye Res* 2006;**83**:1003–4.
147. **Newman NJ**, Bioussé V. Hereditary optic neuropathies. *Eye* 2004;**18**:1144–60.
148. **Fuhrmann N**, Alavi MV, Wissinger B. Genomic rearrangements in the OPA1 gene are frequent in patients with autosomal dominant optic atrophy (poster 5387). *The Association for Research in Vision and Ophthalmology (ARVO) Annual Meeting*. Fort Lauderdale, Florida, 2008.
149. **Costeff H**, Gadoth N, Apter N, Prialnic M, Savir H. A familial syndrome of infantile optic atrophy, movement disorder, and spastic paraplegia. *Neurology* 1989;**39**:595–7.
150. **Anikster Y**, Kleta R, Shaag A, Gahl WA, Elpeleg O. Type III 3-methylglutaconic aciduria (optic atrophy plus syndrome, or Costeff optic atrophy syndrome): identification of the OPA3 gene and its founder mutation in Iraqi Jews. *Am J Hum Genet* 2001;**69**:1218–24.
151. **Kleta R**, Skovby F, Christensen E, Rosenberg T, Gahl WA, Anikster Y. 3-methylglutaconic aciduria type III in a non-Iraqi-Jewish kindred: clinical and molecular findings. *Mol Genet Metab* 2002;**76**:201–6.
152. **Reynier P**, Amati-Bonneau P, Verny C, Olichon A, Simard G, Guichet A, Bonnemains C, Malecaze F, Malinge MC, Pelletier JB, Calvas P, Dollfus H, Belenguer P, Malthiery Y, Lenaers G, Bonneau D. OPA3 gene mutations responsible for autosomal dominant optic atrophy and cataract. *J Med Genet* 2004;**41**e110.
153. **Verny C**, Amati-Bonneau P, Dubas F, Malthiery Y, Reynier P, Bonneau D. An OPA3 gene mutation is responsible for the disease associating optic atrophy and cataract with extrapyramidal signs. *Revue Neurologique* 2005;**161**:451–4.
154. **Davies VJ**, Powell KA, White KE, Yip W, Hogan V, Hollins AJ, Davies JR, Piechota M, Brownstein DG, Moat SJ, Nichols PP, Wride MA, Boulton ME, Votruba M. A missense mutation in the murine Opa3 gene models human Costeff syndrome. *Brain* 2008;**131**:368–80.
155. **Leipnitz G**, Seminotti B, Amaral AU, de Bertoli G, Solano A, Schuck PF, Wyse ATS, Wannmacher CMD, Latini A, Wajner M. Induction of oxidative stress by the metabolites accumulating in 3-methylglutaconic aciduria in cerebral cortex of young rats. *Life Sci* 2008;**82**:652–62.
156. **Olichon A**, Guillou E, Delettre C, Landes T, Arnaune-Pelloquin L, Emorine LJ, Mils V, Daloyau M, Hamel C, Amati-Bonneau P, Bonneau D, Reynier P, Lenaers G, Belenguer P. Mitochondrial dynamics and disease, OPA1. *Biochim Biophys Acta Mol Cell Res* 2006;**1763**:500–9.
157. **Ferre M**, Amati-Bonneau P, Tourmen Y, Malthiery Y, Reynier P. eOPA1: an online database for OPA1 mutations. *Hum Mutat* 2005;**25**:423–8.
158. **Pesch UEA**, Leo-Kottler B, Mayor S, Jurklics B, Kellner U, Apfelstedt-Sylla E, Zrenner E, Alexander C, Wissinger B. OPA1 mutations in patients with autosomal dominant optic atrophy and evidence for semi-dominant inheritance. *Hum Mol Genet* 2001;**10**:1359–68.
159. **Schimpf S**, Schaich S, Wissinger B. Activation of cryptic splice sites is a frequent splicing defect mechanism caused by mutations in exon and intron sequences of the OPA1 gene. *Hum Genet* 2006;**118**:767–71.
160. **Schimpf S**, Fuhrmann N, Schaich S, Wissinger B. Comprehensive cDNA study and quantitative transcript analysis of mutant OPA1 transcripts containing premature termination codons. *Hum Mutat* 2008;**29**:106–12.
161. **Marchbank NJ**, Craig JE, Leek JP, Toohey M, Churchill AJ, Markham AF, Mackey DA, Toomes C, Inglehearn CF. Deletion of the OPA1 gene in a dominant optic atrophy family: evidence that haploinsufficiency is the cause of disease. *J Med Genet* 2002;**39**:e47.
162. **Amati-Bonneau P**, Valentino ML, Reynier P, Gallardo ME, Bornstein B, Boissiere A, Campos Y, Rivera H, de la Aleja JG, Carroccia R, Iommarini L, Labauge P, Figarella-Branger D, Marcocelles P, Furby A, Beauvais K, Letournel F, Liguori R, La Morgia C, Montagna P, Liguori M, Zanna C, Rugolo M, Cossarizza A, Wissinger B, Verny C, Schwarzenbacher R, Martin MA, Arenas J, Ayuso C, Garesse R, Lenaers G, Bonneau D, Carelli V. OPA1 mutations induce mitochondrial DNA instability and optic atrophy plus phenotypes. *Brain* 2008;**131**:338–51.
163. **Ferraris S**, Clark S, Garelli E, Davidson G, Moore SA, Kardon RH, Bienstock RJ, Longley MJ, Mancuso M, Rios PG, Hirano M, Copeland WC, DiMauro S. Progressive external ophthalmoplegia and vision and hearing loss in a patient with mutations in POLG2 and OPA1. *Arch Neurol* 2008;**65**:125–31.
164. **Hudson G**, Amati-Bonneau P, Blakely EL, Stewart JD, He LP, Schaefer AM, Griffiths PG, Ahlqvist K, Suomalainen A, Reynier P, McFarland R, Turnbull DM, Chinnery PF, Taylor RW. Mutation of OPA1 causes dominant optic atrophy with external ophthalmoplegia, ataxia, deafness and multiple mitochondrial DNA deletions: a novel disorder of mtDNA maintenance. *Brain* 2008;**131**:329–37.
165. **Ajz S**, Erskine L, Jeffery G, Bhattacharya SS, Votruba M. Developmental expression profile of the optic atrophy gene product: OPA1 is not localized exclusively in the mammalian retinal ganglion cell layer. *Invest Ophthalmol Vis Sci* 2004;**45**:1667–73.
166. **Pesch UEA**, Fries JE, Bette S, Kalbacher H, Wissinger B, Alexander C, Kohler K. OPA1, the disease gene for autosomal dominant optic atrophy, is specifically expressed in ganglion cells and intrinsic neurons of the retina. *Invest Ophthalmol Vis Sci* 2004;**45**:4217–25.
167. **Ju WK**, Misaka T, Kushnareva Y, Nakagomi S, Agarwal N, Kubo Y, Lipton SA, Bossy-Wetzell E. OPA1 expression in the normal rat retina and optic nerve. *J Comp Neurol* 2005;**488**:1–10.
168. **Wang AG**, Fann MJ, Yu HY, Yen MY. OPA1 expression in the human retina and optic nerve. *Exp Eye Res* 2006;**83**:1171–8.
169. **Bette S**, Schlasz H, Wissinger B, Meyerermann R, Mittelbronn M. OPA1, associated with autosomal dominant optic atrophy, is widely expressed in the human brain. *Acta Neuropathol* 2005;**109**:393–9.
170. **Kamei S**, Chen-Kuo-Chang M, Cazeville C, Lenaers G, Olichon A, Belenguer P, Roussignol G, Renard N, Eybalin M, Michelin A, Delettre C, Brabet P, Hamel CP. Expression of the Opa1 mitochondrial protein in retinal ganglion cells: its downregulation causes aggregation of the mitochondrial network. *Invest Ophthalmol Vis Sci* 2005;**46**:4288–94.
171. **Guan KL**, Farh L, Marshall TK, Deschenes RJ. Normal mitochondrial structure and genome maintenance in yeast requires the dynamin-like product of the Mgm1 gene. *Curr Genet* 1993;**24**:141–8.
172. **Wong ED**, Wagner JA, Scott SV, Okreglak V, Holewinski TJ, Cassidy-Stone A, Nunnari J. The intramitochondrial dynamin-related GTPase, Mgm1p, is a component of a protein complex that mediates mitochondrial fusion. *J Cell Biol* 2003;**160**:303–11.
173. **Praefcke GJK**, McMahon HT. The dynamin superfamily: universal membrane tubulation and fission molecules? *Nat Rev Mol Cell Biol* 2004;**5**:133–47.
174. **Chan DC**. Mitochondrial fusion and fission in mammals. *Annu Rev Cell Dev Biol* 2006;**22**:79–99.
175. **Olichon A**, Landes T, Arnaune-Pelloquin L, Emorine LJ, Mils V, Guichet A, Delettre C, Hamel C, Amati-Bonneau P, Bonneau D, Reynier P, Lenaers G, Belenguer P. Effects of OPA1 mutations on mitochondrial morphology and apoptosis: relevance to ADOA pathogenesis. *J Cell Physiol* 2007;**211**:423–30.
176. **Zanna C**, Ghelli A, Porcelli AM, Karbowski M, Youle RJ, Schimpf S, Wissinger B, Pinti M, Cossarizza A, Vidoni S, Valentino ML, Rugolo M, Carelli V. OPA1 mutations associated with dominant optic atrophy impair oxidative phosphorylation and mitochondrial fusion. *Brain* 2008;**131**:352–67.
177. **Chen H**, Chan DC. Critical dependence of neurons on mitochondrial dynamics. *Curr Opin Cell Biol* 2006;**18**:453–9.
178. **Chan DC**. Mitochondrial dynamics in disease. *N Engl J Med* 2007;**356**:1707–9.
179. **Chen H**, McCaffery JM, Chan DC. Mitochondrial fusion protects against neurodegeneration in the cerebellum. *Cell* 2007;**130**:548–62.
180. **Kanazawa T**. The *C. elegans* Opa1 homologue EAT-3 is essential for resistance to free radicals. *PLoS Genet* 2008;**4**:e1000022.
181. **Amati-Bonneau P**, Guichet A, Olichon A, Chevrollier A, Viala F, Miot S, Ayuso C, Odent S, Arrouet C, Verny C, Calmels MN, Simard G, Belenguer P, Wang J, Puel JL, Hamel C, Malthiery Y, Bonneau D, Lenaers G, Reynier P. OPA1 R445H mutation in optic atrophy associated with sensorineural deafness. *Ann Neurol* 2005;**58**:958–63.
182. **Chevrollier A**. Hereditary optic neuropathies share a common mitochondrial coupling defect. *Ann Neurol* 2008;**63**:794–8.
183. **Lodi R**, Tonon C, Valentino ML, Iotti S, Clementi V, Malucelli E, Barboni P, Longanesi L, Schimpf S, Wissinger B, Baruzzi A, Barbiroli B, Carelli V. Deficit of in vivo mitochondrial ATP production in OPA1-related dominant optic atrophy. *Ann Neurol* 2004;**56**:719–23.
184. **Cipolat S**, Rudka T, Hartmann D, Costa V, Serneels L, Craessaerts K, Metzger K, Frezza C, Annaert W, D'Adamo L, Derks C, Dejaegere T, Pellegrini L, D'Hooge R, Scorrano L, De Strooper B. Mitochondrial rhomboid PARL regulates cytochrome c

- release during apoptosis via OPA1-dependent cristae remodeling. *Cell* 2006;**126**:163–75.
185. **Ishihara N**, Fujita Y, Oka T, Mihara K. Regulation of mitochondrial morphology through proteolytic cleavage of OPA1. *Embo J* 2006;**25**:2966–77.
186. **Griparic L**, Kanazawa T, van der Bleek AM. Regulation of the mitochondrial dynamin-like protein Opa1 by proteolytic cleavage. *J Cell Biol* 2007;**178**:757–64.
187. **Frezza C**, Cipolat S, de Brito OM, Micaroni M, Beznoussenko GV, Rudka T, Bartoli D, Polishuck RS, Danial NN, De Strooper B, Scorrano L. OPA1 controls apoptotic cristae remodeling independently from mitochondrial fusion. *Cell* 2006;**126**:177–89.
188. **Olichon A**, Baricault L, Gas N, Guillou E, Valette A, Belenguer P, Lenaers G. Loss of OPA1 perturbs the mitochondrial inner membrane structure and integrity, leading to cytochrome c release and apoptosis. *J Biol Chem* 2003;**278**:7743–6.
189. **Alavi MV**, Bette S, Schimpf S, Schuettauf F, Schraermeyer U, Wehr HF, Ruttiger L, Beck SC, Tonagel F, Pichler BJ, Knipper M, Peters T, Laufs J, Wissinger B. A splice site mutation in the murine Opa1 gene features pathology of autosomal dominant optic atrophy. *Brain* 2007;**130**:1029–42.
190. **Davies VJ**, Hollins AJ, Piechota MJ, Yip W, Davies JR, White KE, Nicols PP, Boulton ME, Votruba M. Opa1 deficiency in a mouse model of autosomal dominant optic atrophy impairs mitochondrial morphology, optic nerve structure and visual function. *Hum Mol Genet* 2007;**16**:1307–18.
191. **Amati-Bonneau P**, Odent S, Derrien C, Pasquier L, Malthiery Y, Reynier P, Bonneau D. The association of autosomal dominant optic atrophy and moderate deafness may be due to the R445H mutation in the OPA1 gene. *Am J Ophthalmol* 2003;**136**:1170–1.
192. **Li CM**, Kosmorsky G, Zhang K, Katz BJ, Ge J, Traboulsi EI. Optic atrophy and sensorineural hearing loss in a family caused by an R445H OPA1 mutation. *Am J Med Genet Part A* 2005;**138A**:208–11.
193. **Liguori M**. A phenotypic variation of dominant optic atrophy and deafness (ADOAD) due to a novel OPA1 mutation. *J Neurol* 2008;**255**:127–9.
194. **Verny C**. Multiple sclerosis-like disorder in OPA1-related autosomal dominant optic atrophy. *Neurology* 2008;**70**:1152–3.
195. **Stewart JD**, Hudson G, Yu-Wai-Man P, Horvath R, Maddison P, Wright A, Blakely EL, He LP, Griffiths PG, Turnbull DM, Taylor RW, Chinnery PF. OPA1 in multiple mitochondrial DNA deletion disorders. *Neurology* 2008;**71**:1829–31.
196. **Toomes C**, Marchbank NJ, Mackey DA, Craig JE, Newbury-Ecob RA, Bennett CP, Vize CJ, Desai SP, Black GCM, Patel N, Teimory M, Markham AF, Inglehearn CF, Churchill AJ. Spectrum, frequency and penetrance of OPA1 mutations in dominant optic atrophy. *Hum Mol Genet* 2001;**10**:1369–78.
197. **Thiselton DL**, Alexander C, Taanman JW, Brooks S, Rosenberg T, Eiberg H, Andreasson S, Van Regemorter N, Munier FL, Moore AT, Bhattacharya SS, Votruba M. A comprehensive survey of mutations in the OPA1 gene in patients with autosomal dominant optic atrophy. *Invest Ophthalmol Vis Sci* 2002;**43**:1715–24.
198. **Carroll WM**, Kriss A, Baraitser M, Barrett G, Halliday AM. The incidence and nature of visual pathway involvement in Friedreich's ataxia. A clinical and visual evoked potential study of 22 patients. *Brain* 1980;**103**:413–34.
199. **Livingstone IR**, Mastaglia FL, Edis R, Howe JW. Visual involvement in Friedreich's ataxia and hereditary spastic ataxia. A clinical and visual evoked response study. *Arch Neurol* 1981;**38**:75–9.
200. **Chalmers RM**, Riordan-Eva P, Wood NW. Autosomal recessive inheritance of hereditary motor and sensory neuropathy with optic atrophy. *J Neurol Neurosurg Psychiatry* 1997;**62**:385–7.
201. **Zuchner S**, De Jonghe P, Jordanova A, Claeys KG, Guergueltcheva V, Chernikova S, Hamilton SR, Van Stavern G, Krajewski KM, Stajich J, Tourneir I, Verhoeven K, Langerhorst CT, de Visser M, Baas F, Bird T, Timmerman V, Shy M, Vance JM. Axonal neuropathy with optic atrophy is caused by mutations in mitofusin 2. *Ann Neurol* 2006;**59**:276–81.
202. **Livingstone IR**, Mastaglia FL, Edis R, Howe JW. Pattern visual evoked responses in hereditary spastic paraplegia. *J Neurol Neurosurg Psychiatry* 1981;**44**:176–8.
203. **Miyama S**, Arimoto K, Kimiya S, Miyama S. Complicated hereditary spastic paraplegia with peripheral neuropathy, optic atrophy and mental retardation. *Neuropediatrics* 2000;**31**:214–7.
204. **Makhoul J**, Cordonnier M, Van Nechel C. Optic neuropathy in Strumpell-Lorrain disease: presentation of a clinical case and literature review. *Bull Soc Belge Ophthalmol* 2002;**286**:9–14.
205. **Bunce C**, Wormald R. Leading causes of certification for blindness and partial sight in England & Wales. *Bmc Public Health* 2006;**6**.
206. **Wiggs JL**. Genetic etiologies of glaucoma. *Arch Ophthalmol* 2007;**125**:30–7.
207. **Buono LM**, Foroozan R, Sergott RC, Savino PJ. Is normal tension glaucoma actually an unrecognized hereditary optic neuropathy? New evidence from genetic analysis. *Curr Opin Ophthalmol* 2002;**13**:362–70.
208. **Aung T**, Ocaka L, Ebenezer ND, Morris AG, Krawczak M, Thiselton DL, Alexander C, Votruba M, Brice G, Child AH, Francis PJ, Hitchings RA, Lehmann OJ, Bhattacharya SS. A major marker for normal tension glaucoma: association with polymorphisms in the OPA1 gene. *Hum Genet* 2002;**110**:52–6.
209. **Powell B**, Toomes C, Scott S, Yeung A, Marchbank N, Spry P, Lumb R, Inglehearn C, Churchill A. Polymorphisms in OPA1 are associated with normal tension glaucoma. *Mol Vis* 2003;**9**:460–4.
210. **Mabuchi F**, Tang S, Kashiwagi K, Yamagata Y, Iijima H, Tsukahara S. The OPA1 gene polymorphism is associated with normal tension and high tension glaucoma. *Am J Ophthalmol* 2007;**143**:125–30.
211. **Abu-Amro KK**, Morales J, Bosley TM. Mitochondrial abnormalities in patients with primary open-angle glaucoma. *Invest Ophthalmol Vis Sci* 2006;**47**:2533–41.
212. **Andrews RM**, Griffiths PG, Johnson MA, Turnbull DM. Histochemical localisation of mitochondrial enzyme activity in human optic nerve and retina. *Br J Ophthalmol* 1999;**83**:231–5.
213. **Yu Wai Man CY**, Chinnery PF, Griffiths PG. Optic neuropathies – importance of spatial distribution of mitochondria as well as function. *Med Hypotheses* 2005;**65**:1038–42.
214. **Bristow EA**, Griffiths PG, Andrews RM, Johnson MA, Turnbull DM. The distribution of mitochondrial activity in relation to optic nerve structure. *Arch Ophthalmol* 2002;**120**:791–6.
215. **Barron MJ**, Griffiths P, Turnbull DM, Bates D, Nichols P. The distributions of mitochondria and sodium channels reflect the specific energy requirements and conduction properties of the human optic nerve head. *Br J Ophthalmol* 2004;**88**:286–90.
216. **Baloh RH**, Schmidt RE, Pestronk A, Milbrandt J. Altered axonal mitochondrial transport in the pathogenesis of Charcot-Marie-Tooth disease from mitofusin 2 mutations. *J Neurosci* 2007;**27**:422–30.
217. **Detmer SA**, Velde CV, Cleveland DW, Chan DC. Hindlimb gait defects due to motor axon loss and reduced distal muscles in a transgenic mouse model of Charcot-Marie-Tooth type 2A. *Hum Mol Genet* 2008;**17**:367–75.
218. **Ferreirinha F**, Quattrini A, Pirozzi M, Valsecchi V, Dina G, Broccoli V, Auricchio A, Piemonte F, Tozzi G, Gaeta L, Casari G, Ballabio A, Rugari EI. Axonal degeneration in paraplegin-deficient mice is associated with abnormal mitochondria and impairment of axonal transport. *J Clin Invest* 2004;**113**:231–42.
219. **Rugarli EI**, Langer T. Translating m-AAA protease function in mitochondria to hereditary spastic paraplegia. *Trends Mol Med* 2006;**12**:262–9.
220. **Huoponen K**, Vilki J, Aula P, Nikoskelainen EK, Savontaus ML. A new mtDNA mutation associated with Leber hereditary optic neuroretinopathy. *Am J Hum Genet* 1991;**48**:1147–53.
221. **Howell N**, Bindoff LA, McCullough DA, Kubacka I, Poulton J, Mackey D, Taylor L, Turnbull DM. Leber hereditary optic neuropathy: identification of the same mitochondrial ND1 mutation in six pedigrees. *Am J Hum Genet* 1991;**49**:939–50.
222. **Johns DR**, Neufeld MJ, Park RD. An ND-6 mitochondrial DNA mutation associated with Leber hereditary optic neuropathy. *Biochem Biophys Res Commun* 1992;**187**:1551–7.
223. **Valentino ML**, Barboni P, Ghelli A, Bucchi L, Rengo C, Achilli A, Torroni A, Liguori M, Lodi R, Barbiroli B, Dotti M, Federico A, Baruzzi A, Carelli V. The ND1 gene of complex I is a mutational hot spot for Leber's hereditary optic neuropathy. *Ann Neurol* 2004;**56**:631–41.
224. **Kim JY**, Hwang JM, Park SS. Mitochondrial DNA C4171A/ND1 is a novel primary causative mutation of Leber's hereditary optic neuropathy with a good prognosis. *Ann Neurol* 2002;**51**:630–4.
225. **Leo-Kottler B**, Lubrichs J, Besch D, Christ-Adler M, Fauser S. Leber's hereditary optic neuropathy: clinical and molecular genetic results in a patient with a point mutation at np T11253C (isoleucine to threonine) in the ND4 gene and spontaneous recovery. *Graefes Arch Clin Exp Ophthalmol* 2002;**240**:758–64.
226. **Brown MD**, Starikovskaya E, Derbeneva O, Hosseini S, Allen JC, Mikhailovskaya IE, Sukernik RI, Wallace DC. The role of mtDNA background in disease expression: a new primary LHON mutation associated with Western Eurasian haplogroup J. *Hum Genet* 2002;**110**:130–8.
227. **Mayorov V**, Biousse V, Newman NJ, Brown MD. The role of the ND5 gene in LHON: characterization of a new, heteroplasmic LHON mutation. *Ann Neurol* 2005;**58**:807–11.
228. **Howell N**, Halvorson S, Burns J, McCullough DA, Poulton J. When does bilateral optic atrophy become Leber hereditary optic neuropathy? *Am J Hum Genet* 1993;**53**:959–63.
229. **Besch D**, Leo-Kottler B, Zrenner E, Wissinger B. Leber's hereditary optic neuropathy: clinical and molecular genetic findings in a patient with a new mutation in the ND6 gene. *Graefes Arch Clin Exp Ophthalmol* 1999;**237**:745–52.
230. **Zhadanov SI**, Atamanov NV, Zhadanov NI, Oleinikov OV, Osipova LP, Schurr TG. A novel mtDNA ND6 gene mutation associated with LHON in a Caucasian family. *Biochem Biophys Res Commun* 2005;**332**:1115–21.
231. **Howell N**, Bogolin C, Jamieson R, Marendra DR, Mackey DA. mtDNA mutations that cause optic neuropathy: how do we know? *Am J Hum Genet* 1998;**62**:196–202.
232. **Chinnery PF**, Brown DT, Andrews RM, Singh-Kler R, Riordan-Eva P, Lindley J, Applegarth DA, Turnbull DM, Howell N. The mitochondrial ND6 gene is a hot spot for mutations that cause Leber's hereditary optic neuropathy. *Brain* 2001;**124**:209–18.
233. **Wissinger B**, Besch D, Baumann B, Fauser S, Christ-Adler M, Jurkies B, Zrenner E, Leo-Kottler B. Mutation analysis of the ND6 gene in patients with Lebers hereditary optic neuropathy. *Biochem Biophys Res Commun* 1997;**234**:511–5.
234. **Fauser S**, Leo-Kottler B, Besch D, Lubrichs J. Confirmation of the 14568 mutation in the mitochondrial ND6 gene as causative in Leber's hereditary optic neuropathy. *Ophthalmic Genet* 2002;**23**:191–7.
235. **Parker WD Jr**, Oley CA, Parks JK. A defect in mitochondrial electron-transport activity (NADH-coenzyme Q oxidoreductase) in Leber's hereditary optic neuropathy. *N Engl J Med* 1989;**320**:1331–3.
236. **Majander A**, Huoponen K, Savontaus ML, Nikoskelainen E, Wikstrom M. Electron transfer properties of NADH:ubiquinone reductase in the ND1/3460 and the ND4/11778 mutations of the Leber hereditary optic neuroretinopathy (LHON). *FEBS Lett* 1991;**292**:289–92.
237. **Larsson NG**, Andersen O, Holme E, Oldfors A, Wahlstrom J. Leber's hereditary optic neuropathy and complex I deficiency in muscle. *Ann Neurol* 1991;**30**:701–8.
238. **Smith PR**, Cooper JM, Govan GG, Harding AE, Schapira AH. Platelet mitochondrial function in Leber's hereditary optic neuropathy. *J Neural Sci* 1994;**122**:80–3.

239. **Degli Esposti M**, Carelli V, Ghelli A, Ratta M, Crimi M, Sangiorgi S, Montagna P, Lenaz G, Lugaresi E, Cortelli P. Functional alterations of the mitochondrially encoded ND4 subunit associated with Leber's hereditary optic neuropathy. *FEBS Lett* 1994;**352**:375–9.
240. **Cock HR**, Cooper JM, Schapira AH. The 14484 ND6 mtDNA mutation in Leber hereditary optic neuropathy does not affect fibroblast complex I activity [letter]. *Am J Hum Genet* 1995;**57**:1501–2.
241. **Oostra RJ**, Van Galen MJ, Bolhuis PA, Bleeker-Wagemakers EM, Van den Bogert C. The mitochondrial DNA mutation ND6\*14,484C associated with Leber hereditary optic neuropathy, leads to deficiency of complex I of the respiratory chain. *Biochem Biophys Res Commun* 1995;**215**:1001–5.
242. **Montagna P**, Plazzi G, Cortelli P, Carelli V, Lugaresi E, Barboni P, Focchi M. Abnormal lactate after effort in healthy carriers of Leber's hereditary optic neuropathy [letter]. *J Neurol Neurosurg Psychiatry* 1995;**58**:640–1.
243. **Majander A**, Finel M, Savontaus ML, Nikoskelainen E, Wikstrom M. Catalytic activity of complex I in cell lines that possess replacement mutations in the ND genes in Leber's hereditary optic neuropathy. *Eur J Biochem* 1996;**239**:201–7.
244. **Hofhaus G**, Johns DR, Hurko O, Attardi G, Chomyn A. Respiration and growth defects in trans-mitochondrial cell lines carrying the 11778 mutation associated with Leber's hereditary optic neuropathy. *J Biol Chem* 1996;**271**:13155–61.
245. **Carelli V**, Ghelli A, Ratta M, Bacchilega E, Sangiorgi S, Mancini R, Leuzzi V, Cortelli P, Montagna P, Lugaresi E, Degli Esposti M. Leber's hereditary optic neuropathy: biochemical effect of 11778/ND4 and 3460/ND1 mutations and correlation with the mitochondrial genotype. *Neurology* 1997;**48**:1623–32.
246. **Cock HR**, Tabrizi SJ, Cooper JM, Schapira AH. The influence of nuclear background on the biochemical expression of 3460 Leber's hereditary optic neuropathy. *Ann Neurol* 1998;**44**:187–93.
247. **Cock HR**, Cooper JM, Schapira AH. Functional consequences of the 3460-bp mitochondrial DNA mutation associated with Leber's hereditary optic neuropathy. *J Neurol Sci* 1999;**165**:10–7.
248. **Brown MD**, Trounce IA, Jun AS, Allen JC, Wallace DC. Functional analysis of lymphoblast and cybrid mitochondria containing the 3460, 11778, or 14484 Leber's hereditary optic neuropathy mitochondrial DNA mutation. *J Biol Chem* 2000;**275**:39831–6.
249. **Baracca A**, Solaini G, Sgarbi G, Lenaz G, Baruzzi A, Schapira AH, Martinuzzi A, Carelli V. Severe impairment of complex I-driven adenosine triphosphate synthesis in Leber hereditary optic neuropathy cybrids. *Arch Neurol* 2005;**62**:730–6.
250. **Kerrison JB**, Arnould VJ, Sallum JMF, Vagefi MR, Barmada MM, Li YY, Zhu DP, Maumenee IH. Genetic heterogeneity of dominant optic atrophy, Kjer type - Identification of a second locus on chromosome 18q12.2–12.3. *Arch Ophthalmol* 1999;**117**:805–10.
251. **Barbet F**, Hakiki S, Orssaud C, Gerber S, Perrault I, Hanein S, Ducroq D, Dufier JL, Munnich A, Kaplan J, Rozet JM. A third locus for dominant optic atrophy on chromosome 22q. *J Med Genet* 2005;**42**:e1.
252. **Carelli V**, Schimpf S, Valentino ML, Fuhrmann N, Papke M, Schaich S, Tippmann S, Baumann B, Barboni P, Ghelli A, Bucchi L, Lodi R, Barbiroli B, Liguori R, Carroccia R, Villanova M, Montagna P, Baruzzi A, Wissinger B. Dominant optic atrophy (DOA) and sensorineural hearing loss: clinical, biochemical, spectroscopic and molecular genetic study of a large Italian pedigree linked to a new locus on chromosome 16. *Neurology* 2007;**68**:A42.
253. **Puccio H**, Koenig M. Friedreich ataxia: a paradigm for mitochondrial diseases. *Curr Opin Genet Dev* 2002;**12**:272–7.
254. **Rouault TA**, Tong WH. Iron-sulphur cluster biogenesis and mitochondrial iron homeostasis. *Nat Rev Mol Cell Biol* 2005;**6**:345–51.
255. **Zuchner S**, Vance JM. Mechanisms of disease: a molecular genetic update on hereditary axonal neuropathies. *Nat Clin Pract Neurol* 2006;**2**:45–53.
256. **Casari G**, Rugarli E. Molecular basis of inherited spastic paraplegias. *Curr Opin Genet Dev* 2001;**11**:336–42.

### Drug and Therapeutics Bulletin (DTB)

#### Your key source of unbiased, independent advice

For over 45 years DTB has been an independent, indispensable part of evidence-based clinical practice. DTB offers healthcare professionals detailed assessment of, and practical advice on, individual medicines and other treatments, groups of treatment and the overall management of disease.

DTB is now also available online at <http://dtb.bmj.com>:

- ▶ browse or search all DTB content from the latest issue back to 1994
- ▶ email alerting, sophisticated searching, RSS feeds and full text links from cited references
- ▶ interactive services such as My Folders for quick access to articles that you have viewed previously and My Searches to save and re-use useful searches
- ▶ comment online on any DTB article

To subscribe, or for further information, please visit <http://dtb.bmj.com>

