

A Case of Adult Orbital Intraconal Lymphangioma

Abstract

Orbital lymphangioma is an intra-orbital, nonencapsulated, congenital vascular tumor with a propensity for recurrent hemorrhage. It is a common vascular tumor in children below 10 years of age. Adult orbital intraconal lymphangiomas are very rare. The authors present a case of 68-year-old male patient presented with left eye symptoms of decreased vision, proptosis, restricted eye movement, and diplopia. The symptoms started following a trauma to the left eye 6 months back. Contrast magnetic resonance imaging scan showed a contrast enhancing well-defined 2.2 cm × 1.8 cm × 1.8 cm fairly rounded, slightly lobulated intraconal tumor in the retrobulbar region inferior to optic nerve. Patient underwent the left fronto-temporo-orbital-zygomatic (FTOZ) craniotomy. The tumor was moderately vascular, firm in consistency with lobulated surface. Few foci of hemorrhages were seen. Near total excision of the tumor was done. Histopathology and immunohistochemistry confirmed the diagnosis of orbital lymphangioma. Although rare, intraconal orbital lymphangioma should be kept in the differential diagnosis of orbital tumors presenting in adult patients following a trauma. It can radiologically mimic other intraorbital tumors. It is a surgical challenge and FTOZ craniotomy provides direct access to the orbital intraconal compartment.

Keywords: Intraconal, lymphangioma, orbital

Introduction

Orbital lymphangioma is a rare vascular malformation. It is a benign but severe anomaly because of its infiltrative, diffuse, and hemorrhagic nature, and its high morbidity rate. Surgical resection is a real challenge on account of the intricate architecture of the lesion. It constitutes 0.3% to 4% of all orbital tumors.^[1]

Case Report

A 68-year-old male patient presented with a history of decreased vision in the left eye and diplopia. The symptoms started following a trauma to the left eye 6 months back. He is a known case of coronary artery disease on antiplatelet medications. Examination showed restricted movements of the left eye, proptosis, and decreased vision of 6/60 on Snellen chart. Contrast magnetic resonance imaging (MRI) scan showed a well-defined 2.2 cm × 1.8 cm × 1.8 cm fairly rounded, slightly lobulated intraconal tumor in the retrobulbar region inferior to optic nerve. The optic nerve is displaced superiorly. Moderate heterogeneous contrast enhancement of the tumor was

noted [Figure 1]. A provisional diagnosis of optic nerve sheath meningioma was made.

Antiplatelet medication clopidogrel was stopped before surgery. Patient underwent the left fronto-temporo-orbital-zygomatic (FTOZ) craniotomy using three piece technique [Figure 2]. Zygomatic arch was cut at two ends and separated along with its attached masseter muscle. Fronto-temporal craniotomy was done and the orbital wall was removed separately. Intraconal tumor was accessed through the window between levator muscle and lateral rectus muscle [Figure 3]. The tumor was grayish red in color, firm in consistency, moderately vascular with lobulated surface. Few foci of hemorrhages were also seen. Near total excision was done [Figure 4]. Small parts of the tumor adhering to the optic nerve and surrounding structures were left behind. FTOZ bones fixed back [Figure 5]. Patient's vision improved in the postoperative period. Diplopia and proptosis were subsided. On the postoperative day 3, patient developed desaturation of oxygen with myocardial infarction. Patient was kept on ventilator,

This is an open access journal, and articles are distributed under the terms of the Creative Commons Attribution-NonCommercial-ShareAlike 4.0 License, which allows others to remix, tweak, and build upon the work non-commercially, as long as appropriate credit is given and the new creations are licensed under the identical terms.

For reprints contact: reprints@medknow.com

Binoy Damodar Thavara, Bijukrishnan Rajagopalawarrier, Sunitha Balakrishnan¹, Geo Senil Kidangan

Departments of Neurosurgery and ¹Pathology, Government Medical College, Thrissur, Kerala, India

Address for correspondence:
Dr. Binoy Damodar Thavara,
Department of Neurosurgery,
Government Medical College,
Thrissur - 680 596, Kerala,
India.
E-mail: drbinoytd@gmail.com

Access this article online

Website: www.asianjns.org

DOI: 10.4103/ajns.AJNS_282_19

Quick Response Code:



How to cite this article: Thavara BD, Rajagopalawarrier B, Balakrishnan S, Kidangan GS. A case of adult orbital intraconal lymphangioma. Asian J Neurosurg 2020;15:168-71.

Submission: 10-09-2019 **Accepted:** 17-12-2019
Published: 25-02-2020

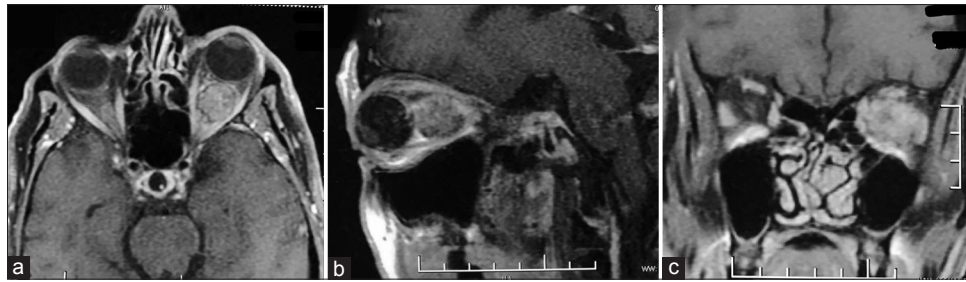


Figure 1: Axial (a), sagittal (b), and coronal (c) contrast magnetic resonance imaging scan showing an intraorbital intraconal tumor in the retrobulbar region. (MRI- Magnetic resonance imaging)

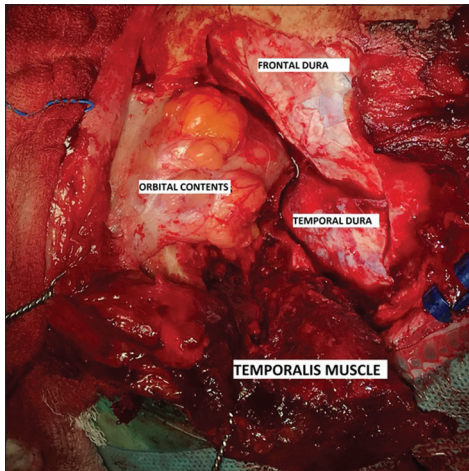


Figure 2: Exposed orbital contents, frontal and temporal dura following left fronto-temporo-orbito-zygomatic craniotomy

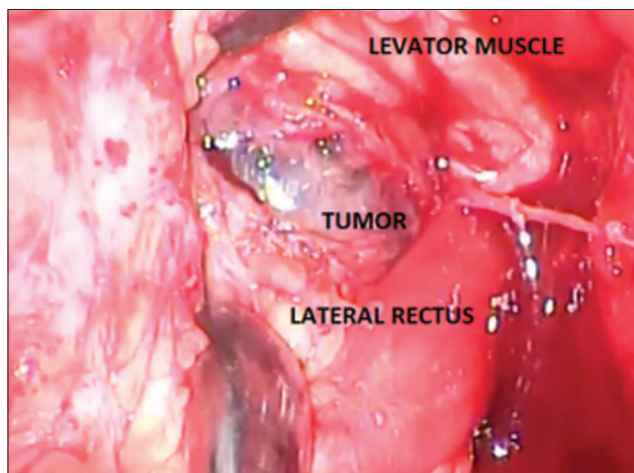


Figure 3: Intraconal tumor was exposed through the window between levator muscle and lateral rectus muscle

and injection heparin infusion was started. Following this, patient developed extradural and intraorbital bleeding with subgaleal and periorbital swelling. Aspiration of the blood under the scalp flap was done. After stabilization of the patient, vision was assessed and found to be deteriorated to become perception of light only.

Histopathology showed a fibrocollagenous tissue composed of congested blood vessels and dilated lymphatic channels

with lymphoid cell aggregates. Focal areas showed lymphoid follicles. Lymphatic channels of varying sizes were noted [Figure 6a and b]. Immunohistochemistry showed epithelial membrane antigen [Figure 7] and vimentin negative. CD34 showed strong positivity in the vascular and lymphatic channels [Figure 8]. These features were suggestive of lymphangioma.

Discussion

A study evaluated retrospective data of 26 orbital lymphangioma patients managed over 16 years. At presentation, proptosis was present in 85%, ptosis in 73%, and restrictive eye movements in 46% of patients. Most patients developed symptoms in the first (77%) or second decades (15%) of life. Two lymphangiomas were diagnosed during adult life, at 48 and 64-year-old, respectively. The accuracy of the initial radiology interpretations was 77%. Only two patients had an isolated intraconal lesion. Twenty-four cases required one or more surgeries. The mean follow-up was 9.2 years (range 1–14 years). Recurrence was noted in 58% of patients.^[2]

Park *et al.*, reviewed the experience of 19 patients with orbital tumors. The surgical approaches used were transcranial in 17 patients. Tumors located in the intraconal or perioptic space were surgically excised using a frontoorbital approach (8 cases), whereas pterional (3 cases), orbital (2 cases), and combined approaches (6 cases) were used for tumors in other sites. Total resection of tumors was achieved in 12 of 19 patients. In 4 patients with glioma and lymphoma, only diagnostic biopsy was done. Three patients experienced visual deterioration postoperatively. Surgical treatment could be the mainstay of therapy for the majority of symptomatic orbital tumors. Many orbital tumors can be treated safely via a transcranial approach. Frontoorbital approach allows the surgeon to reach both the intraorbital and intracranial structures.^[3]

Orbital lymphangioma may be difficult to diagnose in young patients who present with sudden proptosis due to hemorrhage into a previously unrecognized lesion. MRI should be ideally suited for evaluating lymphangiomas due to its unique ability to characterize hemorrhage because of the paramagnetic qualities of hemoglobin. It differentiates hemorrhagic

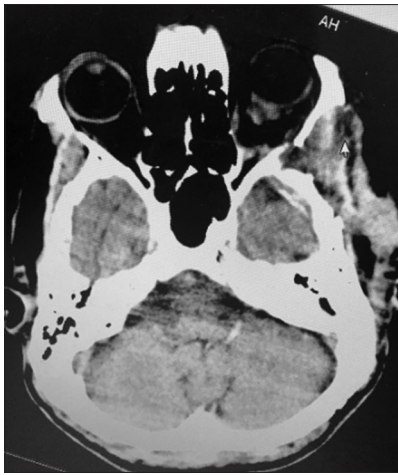

Figure 4: Computed tomography scan showing near total excision of left orbital intraconal tumor (CT – Computed tomography)

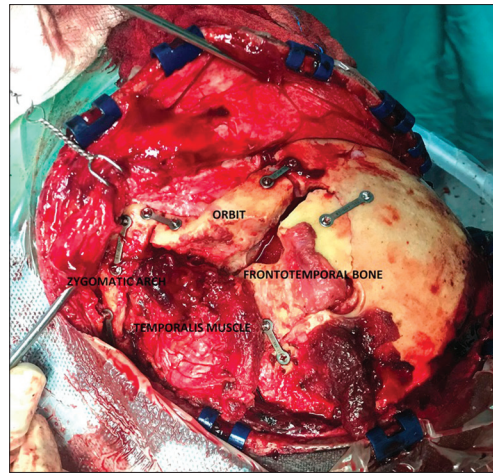


Figure 5: Left fronto-temporo-orbito-zygomatic bones fixed with mini plates and screws

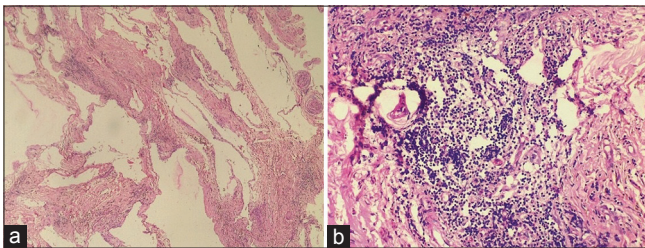


Figure 6: Hematoxylin and Eosin stain showing dilated lymphatic channels of varying sizes (a) and dense lymphoid aggregates forming lymphoid follicles (b). (H and E – Hematoxylin and Eosin)

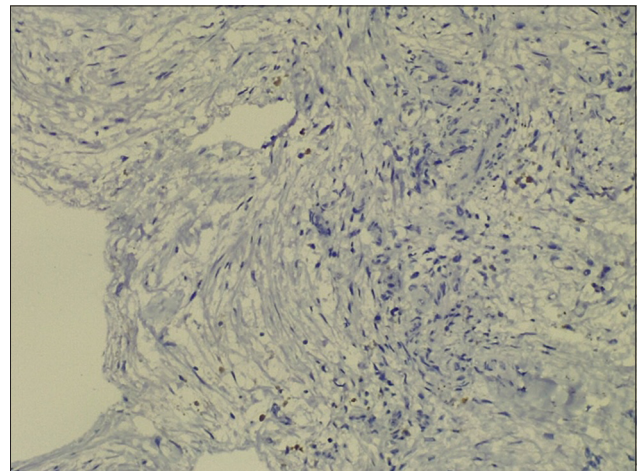


Figure 7: Immunohistochemistry showing epithelial membrane antigen negative cells (EMA – Epithelial membrane antigen)

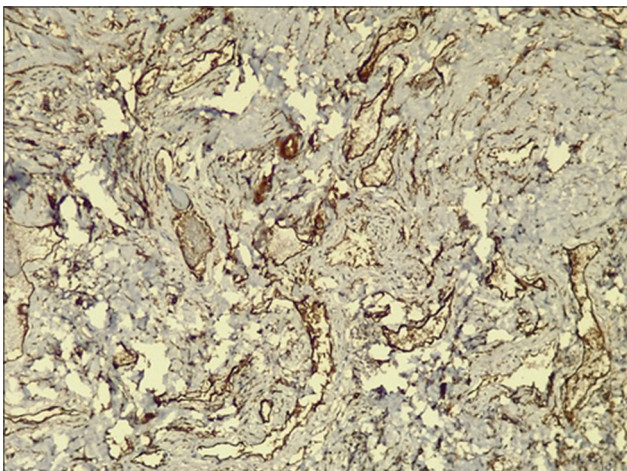


Figure 8: Immunohistochemistry showing CD 34 positive cells in lymphatic channels

cysts, and has unique ability to detect tumor feeding vessels by the flow void phenomenon.^[4]

Orbital lymphangioma is a disease of children and constitutes 0.3%–4% of all orbital tumors. Adult orbital lymphangioma and isolated intraconal lymphangioma are rare. Authors reported a very rare case of isolated intraconal orbital lymphangioma which has occurred in an adult patient of 68 years old.

Conclusion

Although rare, intraconal orbital lymphangioma should be kept in the differential diagnosis of orbital tumors presenting in adult patients following a trauma. It can radiologically mimic other intraorbital tumors. Intraconal orbital lymphangioma is a surgical challenge and FTOZ craniotomy provides direct access to the intraconal orbital compartment. FTOZ is an ideal technique for the neurosurgeon for accessing the intraconal compartment due to the familiarity with the technique.

Declaration of patient consent

The authors certify that they have obtained all appropriate patient consent forms. In the form the patient has given his consent for his images and other clinical information to be reported in the journal. The patients understand that their names and initials will not be published and due efforts will be made to conceal their identity, but anonymity cannot be guaranteed.

Acknowledgment

The study was done with the support from the Department of Neurosurgery and Pathology, Government Medical College, Thrissur - 680 596, Kerala, India.

Financial support and sponsorship

Nil.

Conflicts of interest

There are no conflicts of interest.

References

1. Berthout A, Jacomet PV, Putterman M, Galatoire O, Morax S. Surgical treatment of diffuse adult orbital lymphangioma: Two case studies. *J Fr Ophtalmol* 2008;31:1006-17.
2. Tunç M, Sadri E, Char DH. Orbital lymphangioma: An analysis of 26 patients. *Br J Ophthalmol* 1999;83:76-80.
3. Park HJ, Yang SH, Kim IS, Sung JH, Son BC, Lee SW. Surgical treatment of orbital tumors at a single institution. *J Korean Neurosurg Soc* 2008;44:146-50.
4. Bond JB, Haik BG, Taveras JL, Francis BA, Numaguchi Y, Mihara F, *et al.* Magnetic resonance imaging of orbital lymphangioma with and without gadolinium contrast enhancement. *Ophthalmology* 1992;99:1318-24.