

Evaluation of Successful and Failed Filtering Blebs after Trabeculectomy Using Anterior Segment Optical Coherence Tomography

Serek Tekin¹, Erbil Seven¹, Muhammed Batur¹, Muhammet Derda Özer¹, Tekin Yasar²

¹Department of Ophthalmology, Faculty of Medicine, Yuzuncu Yil University, Van, Turkey, ²Department of Ophthalmology, Beyoglu Eye Research and Training Hospital, Istanbul, Turkey

Abstract

Purpose: To evaluate filtering bleb characteristics using anterior segment optical coherence tomography (AS-OCT) and analyze correlations between these parameters and intraocular pressure (IOP).

Methods: The study included 54 eyes of 43 patients who underwent trabeculectomy with mitomycin-C. The patients were divided into two groups based on mean postoperative IOP. The criterion for surgical success was mean unmedicated postoperative IOP ≤ 18 mmHg. Patients with IOP values >18 mmHg were prescribed anti-glaucoma drops and classified as a surgical failure. All patients underwent AS-OCT, and maximum bleb height, maximum bleb wall thickness, and maximum fluid-filled cavity height were measured. AS-OCT bleb parameters were compared between the successful and failed groups.

Results: Of the 54 eyes, 37 (68.5%) were in the successful group, and 17 (31.5%) were in the failed group. Mean preoperative IOP values in the successful and failed groups were 26.9 ± 6.5 mmHg and 22.9 ± 4.9 mmHg, preoperatively, versus postoperative values of 13.3 ± 2.1 mmHg and 22.8 ± 2.8 mmHg, respectively. Mean postoperative follow-up time was 17.4 ± 9.5 months in the successful group and 19.1 ± 10.1 months in the failed group ($P = 0.22$). In the successful and failed groups, mean bleb height was 1473.7 ± 150.6 μm and 1165.4 ± 217 μm ($P < 0.001$), bleb wall thickness was 670.5 ± 119.9 μm and 538.8 ± 144.3 μm ($P = 0.001$), and fluid-filled cavity height was 736.5 ± 196.8 μm versus 532.5 ± 226.2 μm ($P = 0.001$), respectively.

Conclusions: The results of this study showed that higher AS-OCT values for bleb height, wall thickness, and fluid-filled cavity height were associated with greater functional success. These parameters may be helpful in determining bleb functionality.

Keywords: Anterior segment optical coherence tomography, Filtrating bleb, Trabeculectomy

Address for correspondence: Serek Tekin, Department of Ophthalmology, Faculty of Medicine, Yuzuncu Yil University, 65080, Tusba, Van, Turkey.

E-mail: drserektekin091@gmail.com

Submitted: 26-Mar-2020; **Revised:** 10-Jul-2020; **Accepted:** 04-Aug-2020; **Published:** 26-Mar-2021

INTRODUCTION

Glaucoma is among the leading causes of preventable blindness worldwide. High intraocular pressure (IOP) can lead to irreversible optic nerve damage and blindness. The only treatment method with proven efficacy in glaucoma is IOP reduction.¹ However, desired IOP levels cannot be achieved in some patients despite the use of multiple medications, while other patients cannot tolerate the drugs due to side

effects.² Surgical interventions are required to lower IOP in these patients. Trabeculectomy, which was described by Cairns in 1968, is the most common and effective penetrating surgical procedure and is accepted as the gold standard.³ In this procedure, a conjunctival space called a filtering bleb is created. Aqueous humor drains through this bleb from the anterior chamber to the subconjunctival space. A functioning bleb is essential for postoperative IOP control.⁴⁻⁶ Lowered IOP

This is an open access journal, and articles are distributed under the terms of the Creative Commons Attribution-NonCommercial-ShareAlike 4.0 License, which allows others to remix, tweak, and build upon the work non-commercially, as long as appropriate credit is given and the new creations are licensed under the identical terms.

For reprints contact: WKHLRPMedknow_reprints@wolterskluwer.com

How to cite this article: Tekin S, Seven E, Batur M, Özer MD, Yasar T. Evaluation of successful and failed filtering blebs after trabeculectomy using anterior segment optical coherence tomography. J Curr Ophthalmol 2021;33:1-5.

Access this article online

Quick Response Code:



Website:
www.jcurrophthalmol.org

DOI:
10.4103/JOCO.JOCO_112_20

is the indicator of trabeculectomy success and depends on bleb morphology. Aqueous humor drainage can be insufficient in cases with bleb wall fibrosis.⁷

In addition to histology, biomicroscopy, and ultrasound biomicroscopy (UBM), new diagnostic imaging methods such as anterior segment optical coherence tomography (AS-OCT) and *in vivo* confocal biomicroscopy have recently been used to evaluate bleb morphology.⁸⁻¹³

The use of new methods has facilitated the differentiation of functional and non-functional blebs. These imaging methods allow the detection of bleb fibrosis before it manifests clinically.

Modification of surgical techniques has been shown to make differences in bleb morphology.¹⁴ In this study, we performed trabeculectomy with fornix-based conjunctival flap and rectangle scleral flap, and we used AS-OCT to evaluate trabeculectomy blebs and investigate differences in bleb morphology between patients with successful and failed trabeculectomy.

METHODS

In this prospective study, the blebs of glaucoma patients who underwent trabeculectomy in the ophthalmology outpatient clinic of Van Yüzüncü Yıl University were evaluated using AS-OCT. The study was approved by the Yüzüncü Yıl University Faculty of Medicine Ethics Committee and conducted in accordance with the Declaration of Helsinki.

Sixty-two eyes of 48 patients who underwent trabeculectomy in our clinic were initially included. To standardize the study group, we selected only patients who underwent trabeculectomy with mitomycin-C. Eight eyes were excluded because they had other conjunctival surgeries (due to possible effects on conjunctival thickness), were operated <6 months earlier, or the patient was non-compliant during AS-OCT imaging. As a result, the study was completed with 54 eyes of 43 patients.

For all patients, the same surgeon (T. Y.) created a fornix-based conjunctival flap and cauterized the superficial scleral vessels. Using 45° blade, a 4 mm × 3 mm limbal-based scleral flap was prepared. The scleral flap was deepened with a crescent blade. Sponges soaked with 0.2 mg/ml mitomycin-C were placed between the scleral and conjunctival flaps for approximately 2 min. After 2 min, the region was washed thoroughly. A second flap 3 mm × 2 mm in size was created under the scleral flap, and trabeculum tissue was excised, followed by peripheral iridectomy. The first scleral flap was closed at the edges with 2 sutures using 10-0 nylon. Drainage was tested by irrigating through a side port. The conjunctiva was then closed tightly using 10-0 nylon suture. Fluid was administered again through the side port, and the procedure was concluded after observing that conjunctival bleb had been created, and there was no leakage from the conjunctiva.

All patients underwent a complete ophthalmologic examination. IOP was measured using Goldmann applanation tonometry. As preoperative IOP values, IOP values measured 1 day before trabeculectomy were included in the study. As the postoperative IOP value, the IOP values measured while performing AS-OCT were included in the study. Blebs were evaluated through biomicroscopy.

All patients underwent AS-OCT (Spectralis® OCT, Heidelberg Engineering GmbH, Heidelberg, Germany) imaging for bleb evaluation. AS-OCT imaging was performed by the same experienced technician in a room with standard illumination.

The patient was asked to look down during imaging. Another technician lifted the patients' upper eyelid during image acquisition. Multiple horizontal cross-sections were obtained starting at the limbus and continuing upward for 10 mm to visualize the bleb, which was placed 3–5 mm from the limbus.

According to the IOP values measured when performing AS-OCT at the final visit, the patients were classified as surgical success or failure. Postoperative IOP measurements were performed in the 1st month, 2nd month, 4th month, and 6th month. After the 6th month, measurements were continued at 2-month intervals. Bleb massage was performed in patients with high IOP after surgery. Bleb needling was performed in five patients. Then IOPs were evaluated. The criterion for surgical success was unmedicated postoperative IOP ≤18 mmHg. Patients with a postoperative IOP >18 mmHg were considered failed and prescribed anti-glaucomatous drops. Patients with IOP >21 were followed closely.

AS-OCT was evaluated by a single clinician. Maximum bleb height, maximum bleb wall thickness, and maximum fluid-filled cavity height were measured (Spectralis® OCT, Heidelberg Engineering GmbH, Heidelberg, Germany own software). Bleb height was measured as the longest distance between the outer surface of the sclera and conjunctiva; bleb wall thickness was measured as the longest distance between the upper border of the fluid-filled space and outer conjunctiva; fluid-filled cavity height was evaluated based on wall-to-wall longest distance between the superior and inferior wall of the fluid-fill cavity. Eyes for which the region of interest for AS-OCT measurements was not available due to a tight eyelid and/or a narrow lid fissure and images in which the image clarity was not good were excluded from the study. The successful and failed groups were compared in terms of bleb height, bleb wall thickness, and fluid-filled cavity height. AS-OCT images of the bleb from a patient in the successful group are shown in Figure 1.

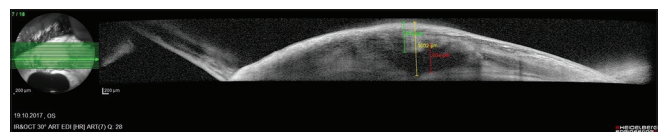


Figure 1: Anterior segment optical coherence tomography image of a bleb in a patient from the successful group

Statistical analysis

SPSS version 23.0 software (IBM Corporation, Armonk, NY, USA) was used for statistical analyses. The normality of the data distributions was assessed using Shapiro–Wilk test. Descriptive statistics were used to calculate the mean values for patient age, gender, follow-up period, pre and postoperative IOP values, and bleb parameters. Wilcoxon test was used to compare the patients' pre and postoperative IOP values. Mann–Whitney *U*-test was used to compare bleb parameters between the successful and failed groups.

Since both eyes of some patients were included in the study, generalized estimating equations (GEE) analysis was performed to eliminate the effect of the fellow eyes on statistical analysis in these patients.

In our study, logistic regression analysis was used to reveal the relationship between success in trabeculectomy and numerical variables such as age, bleb height, bleb wall thickness, fluid-filled cavity height, and preoperative and postoperative IOP values.

RESULTS

Thirty-seven (68.5%) of 54 eyes were in the successful group, and 17 (31.5%) were in the failed group. The demographic findings and clinical characteristics of the patients are shown in Table 1. Of the eyes with detectable glaucoma type, 38 were primary open-angle glaucoma and 12 were pseudoexfoliation glaucoma.

Preoperative mean IOP values were 26.9 ± 6.5 mmHg in the successful group and 22.9 ± 4.9 mmHg in the failed group. Postoperatively, mean IOP was 13.3 ± 2.1 mmHg in the successful group and as 22.8 ± 2.8 mmHg in the failed group. The difference in postoperative mean IOP was statistically significant ($P < 0.001$). Mean postoperative follow-up time was 17.4 ± 9.5 months in successful group and 19.1 ± 10.1 in the failed group ($P = 0.22$).

There were significant differences between the successful and failed groups in terms of bleb height, bleb wall thickness, and fluid-filled cavity height measurements. Parametric values are summarized in Table 2 and Figure 2.

In GEE analysis, 32 (74.4%) of 43 patients were in the successful group, and 11 (25.6%) were in the failed group. There were

statistically significant differences between successful and failed groups in terms of bleb height ($P = 0.001$), bleb wall thickness ($P = 0.027$), and fluid-filled cavity height ($P = 0.049$).

Postoperative bleb needling was performed on two patients (5.1%) in the successful group and on three patients (20%) in the failed group ($P = 0.35$).

In the logistic regression analysis between successful blebs and age, bleb height, bleb wall thickness, fluid-filled cavity height, and preoperative and postoperative IOP, no statistically significant differences were found.

DISCUSSION

Low IOP, the indicator of a successful trabeculectomy, depends on bleb morphology. A functioning bleb is essential for postoperative IOP control.^{4,5} To date, biomicroscopy was predominantly used in the evaluation of blebs. However, biomicroscopic evaluation can lead to errors because it does not enable visualization of inner bleb structure and can be influenced by the knowledge and experience of the clinician. Therefore, researchers have employed *in vivo* confocal microscopy and AS-OCT in recent years for a more detailed and objective evaluation.⁸⁻¹⁰

Our AS-OCT evaluation of bleb parameters in the successful and failed trabeculectomy groups revealed greater total bleb

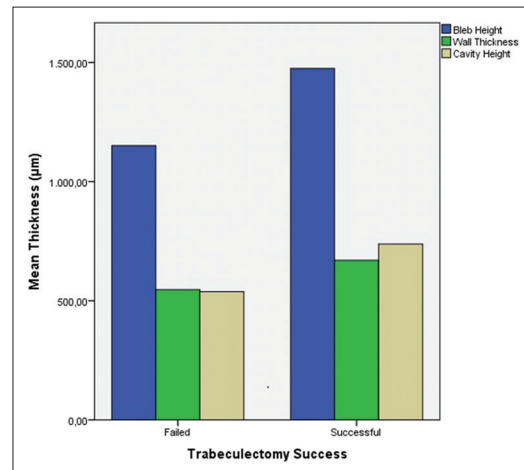


Figure 2: Bleb parameters in the successful and failed trabeculectomy groups

Table 1: Patients' demographic and clinical characteristics

Patients	Successful group	Failed group	<i>P</i>
Number of eyes	37 (68.5%)	17 (31.5%)	
Side	Right-left (%): 24 (64.9) - 13 (35.1)	Right-left (%): 10 (58.8) - 7 (41.2)	0.15
Age (years)	64.2±10.1 (27-76)	70.1±7.4 (55-85)	0.14
Sex	Male/female (%): 65.2/34.8	Male/female (%): 75/25	0.43
Preoperative mean IOP (mmHg)	26.9±6.5 (18-50)	22.9±4.9 (13-30)	0.02
Postoperative mean IOP (mmHg)	13.3±2.1 (9-16)	22.8±2.8 (19-27)	<0.001
Postoperative time (months)	17.4±9.5 (6-44)	19.1±10.1 (6-34)	0.22

IOP: Intraocular pressure, POAG: Primary open-angle glaucoma, PXG: Pseudoexfoliation glaucoma, LEFT:

Table 2: Anterior segment optical coherence tomography results in the successful and failed trabeculectomy groups

	Successful (μm)	Failed (μm)	P	Corrected P*
Bleb height (mean \pm SD)	1473.7 \pm 150.6	1165.4 \pm 217	<0.001	0.001
Bleb wall thickness (mean \pm SD)	670.5 \pm 119.9	538.8 \pm 144.3	0.001	0.027
Fluid-fill cavity height (mean \pm SD)	736.5 \pm 196.8	532.5 \pm 226.2	0.001	0.049

*Corrected P values in terms of generalized estimating equations. SD: Standard deviation

height, bleb wall thickness, and fluid-filled cavity height in the patients in the successful group than in the failed group.

There are various grading systems in the literature for bleb classification, including the Pitch and Grehn classification,^{10,15} Indiana bleb appearance grading system (IBAGS),¹⁶ Moorfields bleb grading system (MBGS),¹⁷ and the Wuerzburg bleb classification system (WBCS), which is based on the Pitch and Grehn classification.^{18,19} In the Pitch and Grehn classification^{10,15} and WBCS, the biomicroscopic examination is used to grade bleb vascularization, tortuous vessels on the bleb surface, microcysts, and encapsulation from 0 to 3, and bleb morphology is evaluated based on the resulting scores. In the IBAGS, blebs are photographed postoperatively and classified according to evaluations of height, extent, vascularity, and Seidel test from these images.¹⁶ In the MBGS, blebs are classified by assessing bleb vascularity and morphology (wall thickness, height, and width) based on comparisons of slit-lamp examination findings to standard mono and stereo bleb photographs.¹⁷ In our study, AS-OCT was used to evaluate bleb morphological parameters such as height, wall thickness, and fluid-filled cavity height in the bleb. Our use of objective data distinguishes our study from those using other classification methods.

Sarcaoğlu *et al.*²⁰ conducted UBM assessment of bleb features in 12 open-angle glaucoma patients who underwent trabeculectomy in one eye and deep sclerectomy in the fellow eye and detected subconjunctival bleb in all eyes of both groups. UBM formed the basis for the non-invasive methods for assessing postoperative anatomical changes and aqueous outflow dynamics in eyes that underwent glaucoma surgery. In recent years, AS-OCT has become common in evaluating bleb properties.^{21,22}

Caglar *et al.*²³ evaluated filtering bleb functions using *in vivo* confocal microscopy and reported a significant correlation between biomicroscopic and *in vivo* confocal microscopic examination.

Using AS-OCT, Narita *et al.*²¹ evaluated filtering blebs in 99 eyes of 94 trabeculectomy patients and showed that patients with greater bleb height and wall thickness had better IOP control. Similarly, we observed in our study that patients with greater total bleb height and wall thickness had lower IOP values compared to the group with lower bleb height and thinner bleb wall. In this study, unlike our study, hyporeflexive areas in the bleb wall were measured. In our study, the fluid-filled cavity height under the bleb wall was measured.

Nakashima *et al.*²⁴ also reported that patients who underwent trabeculectomy with mitomycin-C, as in our study, had greater

total bleb height, and thicker bleb wall and lower bleb wall density were associated with lower IOP. Unlike their study, however, we did not measure bleb wall density in our study.

Güven Yılmaz *et al.*²⁵ evaluated blebs in 28 eyes using biomicroscopy, AS-OCT, and *in vivo* confocal microscopy and assessed biometric parameters such as bleb height, length, and wall thickness using AS-OCT. Biometric parameters were superior in functional blebs when compared to the non-functional blebs. Consistent with previous studies, bleb height and wall thickness were significantly higher in the successful group compared to the failed group in our study.

In another study, Kawana *et al.*²⁶ used AS-OCT to evaluate the blebs in 38 eyes of 31 patients based on maximum and minimum bleb wall thickness, total bleb height, fluid-filled cavity volume, and microcysts. They determined that IOP was significantly correlated with all four of these parameters. Although their results are similar to ours, we did not evaluate the number of microcysts.

Leung *et al.*²⁷ also used AS-OCT to assess bleb wall thickness and amount of subconjunctival fluid in the blebs of 14 patients. They found that diffuse filtering blebs had a greater amount of subconjunctival fluid, while encapsulated blebs had thicker walls.

Hamanaka *et al.*²⁸ analyzed the correlation between IOP and bleb height and width, wall thickness in limbal-based, and fornix-based trabeculectomies. Unlike our study, they detected no correlation in fornix-based trabeculectomy while there was a correlation in limbal-based trabeculectomy. In a similar study, Tominaga *et al.*²⁹ analyzed 49 eyes with trabeculectomy and, unlike our results, found no correlation between IOP and bleb height or fluid-filled cavity volume. However, consistent with our findings, they demonstrated a negative correlation between wall thickness and IOP.

Meziani *et al.*³⁰ used *en face* spectral domain OCT to evaluate intraepithelial microcyst density, fluid-filled space, and bleb vascularization in 22 functional and 19 non-functional filtering blebs and showed that microcyst density was higher in functional blebs compared with non-functional blebs, but there was no difference in terms of the fluid-filled cavity or bleb vascularization. Microcyst density and vascularization were not evaluated in our study, but we found that cystic space was correlated with low IOP.

Unlike our study, Nakano *et al.*³¹ and Khamar *et al.*³² compared bleb wall reflectivity and bleb success using AS-OCT and showed that blebs with multiform reflectivity had greater success.

Limitations of this study are that bleb wall reflectivity was not assessed, fluid-filled space was measured using the deepest point in a single dimension instead of calculating fluid volume, and the correlation between bleb microcysts and IOP was not investigated.

In conclusion, AS-OCT is an important non-invasive method for the evaluation of anatomical changes after glaucoma surgery. In our study analyzing blebs using AS-OCT, we found that low IOP level after trabeculectomy was correlated with total bleb height, bleb wall thickness, and size of the fluid-filled space. We demonstrated that bleb parameters measured using AS-OCT were associated with functional success. However, we believe that evaluating bleb functions is not possible only with AS-OCT device. Larger studies evaluating bleb wall reflectivity, fluid volume, and other indicators of bleb functions (number and amount of microcysts, bleb vascularization, etc.) compared with the parameters we have measured will be more useful for the evaluation of bleb functions.

Financial support and sponsorship

Nil.

Conflicts of interest

There are no conflicts of interest.

REFERENCES

1. The Advanced Glaucoma Intervention Study (AGIS): 7. The relationship between control of intraocular pressure and visual field deterioration. The AGIS Investigators. *Am J Ophthalmol* 2000;130:429-40.
2. Friedman DS, Okeke CO, Jampel HD, Ying GS, Plyler RJ, Jiang Y, et al. Risk factors for poor adherence to eyedrops in electronically monitored patients with glaucoma. *Ophthalmology* 2009;116:1097-105.
3. Cairns JE. Trabeculectomy. Preliminary report of a new method. *Am J Ophthalmol* 1968;66:673-9.
4. Abrams GW, Thomas MA, Williams GA, Burton TC. Management of postoperative suprachoroidal hemorrhage with continuous-infusion air pump. *Arch Ophthalmol* 1986;104:1455-8.
5. D'Ermo F, Bonomi L, Doro D. A critical analysis of the long-term results of trabeculectomy. *Am J Ophthalmol* 1979;88:829-35.
6. Levene RZ. Glaucoma filtering surgery factors that determine pressure control. *Trans Am Ophthalmol Soc* 1984;82:282-301.
7. Azuara-Blanco A, Katz LJ. Dysfunctional filtering blebs. *Surv Ophthalmol* 1998;43:93-126.
8. Addicks EM, Quigley HA, Green WR, Robin AL. Histologic characteristics of filtering blebs in glaucomatous eyes. *Arch Ophthalmol* 1983;101:795-8.
9. Powers TP, Stewart WC, Stroman GA. Ultrastructural features of filtration blebs with different clinical appearances. *Ophthalmic Surg Lasers* 1996;27:790-4.
10. Picht G, Grehn F. Classification of filtering blebs in trabeculectomy: Biomicroscopy and functionality. *Curr Opin Ophthalmol* 1998;9:2-8.
11. Sharma R, Sharma A, Arora T, Sharma S, Sobti A, Jha B, et al. Application of anterior segment optical coherence tomography in glaucoma. *Surv Ophthalmol* 2014;59:311-27.
12. Mastropasqua L, Agnifili L, Mastropasqua R, Fasanella V. Conjunctival modifications induced by medical and surgical therapies in patients with glaucoma. *Curr Opin Pharmacol* 2013;13:56-64.
13. Ciancaglini M, Carpineto P, Agnifili L, Nubile M, Fasanella V, Mattei PA, et al. Conjunctival characteristics in primary open-angle glaucoma and modifications induced by trabeculectomy with mitomycin C: An *in vivo* confocal microscopy study. *Br J Ophthalmol* 2009;93:1204-9.
14. Wells AP, Cordeiro MF, Bunce C, Khaw PT. Cystic bleb formation and related complications in limbus- versus fornix-based conjunctival flaps in pediatric and young adult trabeculectomy with mitomycin C. *Ophthalmology* 2003;110:2192-7.
15. Picht G, Grehn F. Development of the filtering bleb after trabeculectomy. Classification, histopathology, wound healing process. *Ophthalmologie* 1998;95:W380-7.
16. Cantor LB, Mantravadi A, WuDunn D, Swamynathan K, Cortes A. Morphologic classification of filtering blebs after glaucoma filtration surgery: The Indiana Bleb Appearance Grading Scale. *J Glaucoma* 2003;12:266-71.
17. Wells AP, Crowston JG, Marks J, Kirwan JF, Smith G, Clarke JC, et al. A pilot study of a system for grading of drainage blebs after glaucoma surgery. *J Glaucoma* 2004;13:454-60.
18. Klink J, Schmitz B, Lieb WE, Klink T, Grein HJ, Sold-Darseff J, et al. Filtering bleb function after clear cornea phacoemulsification: A prospective study. *Br J Ophthalmol* 2005;89:597-601.
19. Furrer S, Menke MN, Funk J, Töteberg-Harms M. Evaluation of filtering blebs using the 'Wuerzburg bleb classification score' compared to clinical findings. *BMC Ophthalmol* 2012;12:24.
20. Sarıcaoğlu MS, Aktaş ZP, Karakurt A, Önel M, Hasırıpı H. Trabekülektomi ve nonpenetran derin sklerektomide ultrason biyomikroskopik değerlendirme. *Glokom Katarakt J Glaucoma Cataract* 2007;2:99-102.
21. Narita A, Morizane Y, Miyake T, Seguchi J, Baba T, Shiraga F. Characteristics of early filtering blebs that predict successful trabeculectomy identified via three-dimensional anterior segment optical coherence tomography. *Br J Ophthalmol* 2018;102:796-801.
22. Wen JC, Stinnett SS, Asrani S. Comparison of anterior segment optical coherence tomography bleb grading, Moorfields bleb grading system, and intraocular pressure after trabeculectomy. *J Glaucoma* 2017;26:403-8.
23. Caglar C, Karpuzoglu N, Batur M, Yasar T. *In vivo* Confocal Microscopy and Biomicroscopy of Filtering Blebs After Trabeculectomy. *J Glaucoma* 2016;25:e377-83.
24. Nakashima K, Inoue T, Fukushima A, Hirakawa S, Kojima S, Tanihara H. Evaluation of filtering blebs exhibiting transconjunctival oozing using anterior segment optical coherence tomography. *Graefes Arch Clin Exp Ophthalmol* 2015;253:439-45.
25. Güven Yılmaz S, Değirmenci C, Palamar M, Yağcı A. Evaluation of filtering bleb function after trabeculectomy with mitomycin c using biomicroscopy, anterior segment optical coherence tomography and *In vivo* confocal microscopy. *Turk J Ophthalmol* 2015;45:132-7.
26. Kawana K, Kiuchi T, Yasuno Y, Oshika T. Evaluation of trabeculectomy blebs using 3-dimensional cornea and anterior segment optical coherence tomography. *Ophthalmology* 2009;116:848-55.
27. Leung CK, Yick DW, Kwong YY, Li FC, Leung DY, Mohamed S, et al. Analysis of bleb morphology after trabeculectomy with Visante anterior segment optical coherence tomography. *Br J Ophthalmol* 2007;91:340-4.
28. Hamanaka T, Omata T, Sekimoto S, Sugiyama T, Fujikoshi Y. Bleb analysis by using anterior segment optical coherence tomography in two different methods of trabeculectomy. *Invest Ophthalmol Vis Sci* 2013;54:6536-41.
29. Tominaga A, Miki A, Yamazaki Y, Matsushita K, Otori Y. The assessment of the filtering bleb function with anterior segment optical coherence tomography. *J Glaucoma* 2010;19:551-5.
30. Mezziani L, Tahiri Joutei Hassani R, El Sanharawi M, Brasnu E, Liang H, Hamard P, et al. Evaluation of blebs after filtering surgery with en-face anterior-segment optical coherence tomography: A pilot study. *J Glaucoma* 2016;25:e550-8.
31. Nakano N, Hangai M, Nakanishi H, Inoue R, Unoki N, Hirose F, et al. Early trabeculectomy bleb walls on anterior-segment optical coherence tomography. *Graefes Arch Clin Exp Ophthalmol* 2010;248:1173-82.
32. Khamar MB, Soni SR, Mehta SV, Srivastava S, Vasavada VA. Morphology of functioning trabeculectomy blebs using anterior segment optical coherence tomography. *Indian J Ophthalmol* 2014;62:711-4.