

RESEARCH ARTICLE

Open Access

Renal function during rofecoxib therapy in patients with metastatic cancer: retrospective analysis of a prospective phase II trial

Stephan W Reinhold^{1*}, Albrecht Reichle², Sonja Leiminger¹, Tobias Bergler¹, Ute Hoffmann¹, Bernd Krüger^{1,3}, Bernhard Banas¹, Bernhard K Krämer^{1,3}

Abstract

Background: Angiostatic/antiinflammatory therapy with COX-II inhibitors and pioglitazone seems to be a well tolerated and promising regimen in patients with metastatic cancer. COX-II inhibitors may have less gastrointestinal side effects than conventional non-steroidal antiinflammatory drugs, but their impact on renal function seems to be similar.

Methods: 87 patients with metastatic/advanced cancer were treated up to 12 months (mean 19.5 weeks) with rofecoxib, pioglitazone and either capecitabine (group A with gastrointestinal and urological cancer, n = 50) or trofosfamide (group B with non-gastrointestinal/non-urological cancer, n = 37) and followed for further 6 months.

Results: Baseline serum creatinine concentration was 0.81 ± 0.28 mg/dl, and increased by about 0.15 mg/dl during months 1-3. Accordingly estimated glomerular filtration rate (eGFR) decreased from 90.3 ml/min \pm 3.6 ml/min at baseline by about 10 ml/min during months 1-3. Renal function decreased in 75 patients (86%) in the first month ($p < 0.0001$). This decrease went along with clinical signs of volume expansion. Renal function tended to recover after discontinuation of the study medication.

Conclusions: Therapy with rofecoxib in an antiangiogenic/antiinflammatory setting results in a decrease of renal function in nearly every patient.

Trial registration number: German Clinical Trials Register DRKS: DRKS00000119

Background

Cyclooxygenases (both isoforms, COX-I and COX-II) oxidize arachidonic acid to prostaglandin H₂, which is converted by different synthases to prostaglandin-E₂, -D₂, -I₂, -F₂ α , and thromboxane A₂. These prostaglandins inhibit apoptosis and promote cell division, metastasis and angiogenesis leading to increased tumor growth [1]. An antiangiogenic/antiinflammatory therapy with COX-II inhibitors and pioglitazone combined with metronomic low-dose chemotherapy with either capecitabine or trofosfamide seems to be well tolerated and promising in patients with advanced carcinomas [2,3]. However, in one study in patients with colorectal cancer increased gastrointestinal

toxicity was reported [4]. Since COX-II inhibitors are known to elicit renal side effects to a similar extent than conventional non-steroidal antiinflammatory drugs [5], the detailed analysis of any change in serum creatinine concentrations and glomerular filtration rate in a prospective trial of antiangiogenic/antiinflammatory therapy in advanced cancer was our primary objective.

Methods

Patient Characteristics

The study was approved by the local ethics committee, and all patients gave their written informed consent for study participation. Patients with either gastrointestinal/urological cancer (group A, see Table 1) or with non-gastrointestinal/non-urological cancer (group B, see Table 1) were included in the study and treated with rofecoxib, pioglitazone and either capecitabine in a dose of 1.0 g bid

* Correspondence: stephan.reinhold@klinik.uni-regensburg.de

¹Klinik und Poliklinik für Innere Medizin II, University of Regensburg, Franz-Josef-Strauß-Allee 11, Regensburg, 93053, Germany

Full list of author information is available at the end of the article

Table 1 Baseline patient characteristics and underlying malignancy

Age in years (range)	60.5 (30 - 81)	
Gender		
Male	56 (64%)	
Female	31 (36%)	
Baseline serum creatinine concentration in mg/dl (\pm SEM)	0.81 (\pm 0.28)	
Arterial hypertension	21 (24%)	
Concomitant nephrotoxic/volume depleting or blood pressure lowering medication		
- NSAIDs	18 (21%)	
- Loop diuretics	14 (16%)	
- Thiazides	8 (9%)	
- ACE inhibitor	6 (7%)	
- AT2 blocker	4 (5%)	
- Aldosterone antagonists	2 (2%)	
Preceding chemotherapy	45 (52%)	
Liver metastasis	45 (52%)	
	Group A (treated with capecitabine, rofecoxib and pioglitazone)	Group B (treated with trofosfamid, rofecoxib and pioglitazone)
Melanoma		16
Gastric carcinoma	13	
Colorectal carcinoma	12	
Renal cell carcinoma	9	
Hepatic carcinoma/Klatskin	7	
Sarcoma		5
Pulmonary adenocarcinoma/SCLC		3
Pancreatic cancer	3	
Urothelium carcinoma	3	
Gall bladder carcinoma	3	
Breast cancer		2
Histiozytosis X		2
Hodgkin/Non-Hodgkin-Lymphoma		2
Ovarial carcinoma		2
TNE		2
Chronic lymphatic leukemia		1
Cervix carcinoma		1

SCLC = small cell lung cancer; TNE = throat nose ear.

(group A) or trofosfamide 50 mg tid (group B). Additional eligibility criteria have already been published [3].

Patients were recruited between 2000 and 2004. Treatment was administered up to 12 months and patients were followed up for further 6 months. 25 mg rofecoxib/day was administered to 75 patients, and a reduced dose (12.5 mg/day) was administered to 12 patients with pre-existing renal impairment. Renal impairment, that triggered a dose reduction of rofecoxib in the prospective phase II trial, had been defined as any serum creatinine concentration that exceeded the normal range. Serum creatinine concentrations were measured before inclusion of a patient and every month thereafter. The normal range of serum creatinine

concentration in our institution is 0.5-0.8 mg/dl for women and 0.8-1.1 mg/dl for men.

Glomerular filtration rate was estimated using the method of Cockcroft and Gault [6].

Provisions were made to reduce rofecoxib dose in case of a rise in serum creatinine concentration above 1.3 mg/dl or WHO grade >1 edema.

The study was stopped because of withdrawal of rofecoxib from the market.

Statistics

We used the Wilcoxon signed rank test for the retrospective data analysis. Data are given as mean \pm standard error of the mean.

Results

Serum creatinine concentration and glomerular filtration rate

Serum creatinine concentration increased in 75 patients (86%) during the first month of the treatment phase ($p < 0.0001$). This significant increase was sustained during the first six months (Figure 1). After the end of treatment, creatinine concentration significantly decreased during months 1-3, but did not reach baseline concentrations again (Figure 2).

Mean baseline eGFR decreased accordingly from 90.3 ml/min \pm 3.6 ml/min at baseline to a minimum of 76 ml/min \pm 5.4 ml/min in the fifth month ($p = 0.0195$) (Figure 3). Two months after end of treatment with rofecoxib, mean eGFR reached baseline values again (96.6 ml/min \pm 7.6 ml/min) (Figure 4).

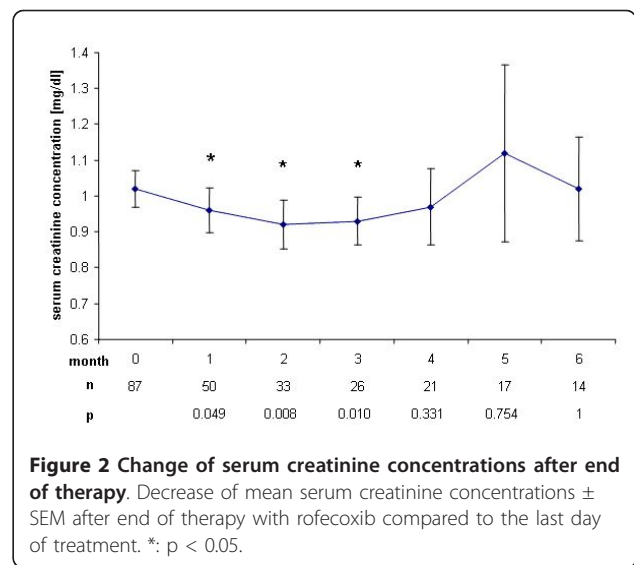
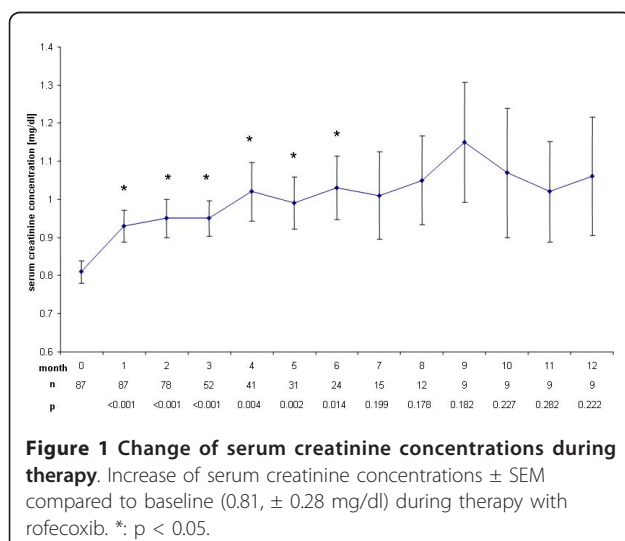
In patients with pre-existing renal impairment, treated with a reduced dose of rofecoxib the average serum creatinine concentration rose from 1.01 mg/dl \pm 0.1 mg/dl to a maximum of 1.25 mg/dl \pm 0.27 mg/dl in the fifth month ($p = 0.0058$).

Serum sodium concentrations

Serum sodium concentrations during rofecoxib therapy remained unchanged. A decrease from 139.8 mmol/l \pm 0.39 mmol/l to 137.0 mmol/l \pm 1.28 mmol/l in month nine ($p = 0.006$) appears to be a chance finding due to low numbers of patients remaining in the study. Serum sodium concentration remained stable after treatment stop.

Body weight and edema formation

Mean body weight before treatment was 73.7 kg \pm 1.7 kg, fluctuated from month to month with a lower mean body weight on month 2, 5 and 7, but increased significantly during therapy with rofecoxib up to the eighth month with

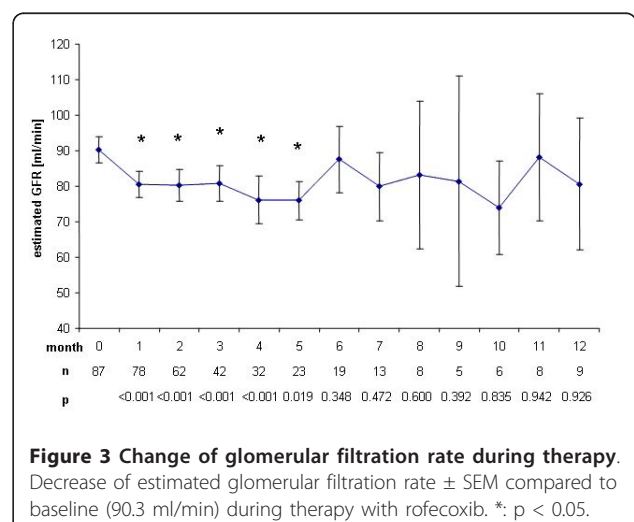


10 patients remaining at risk. The highest increase in mean body weight of 4.1 kg was noted in the eleventh month after start of rofecoxib treatment with only 8 patients remaining in the study. The increase in body weight went along with edema formation in 30 patients (34%).

Immediately after discontinuation of treatment mean body weight fell significantly from 74.2 kg \pm 1.7 kg to 72.1 kg \pm 2.5 kg.

Blood pressure

Mean systolic blood pressure rose during therapy from 130.1 mmHg \pm 2.1 mmHg to 137.8 mmHg \pm 6.2 mmHg after twelve months except in months 2, 6, 7 and 10, where the mean systolic blood pressure was at or lower than baseline. In the first, second and fourth month after cessation of rofecoxib therapy, mean systolic blood pressure was significantly lower than during therapy.

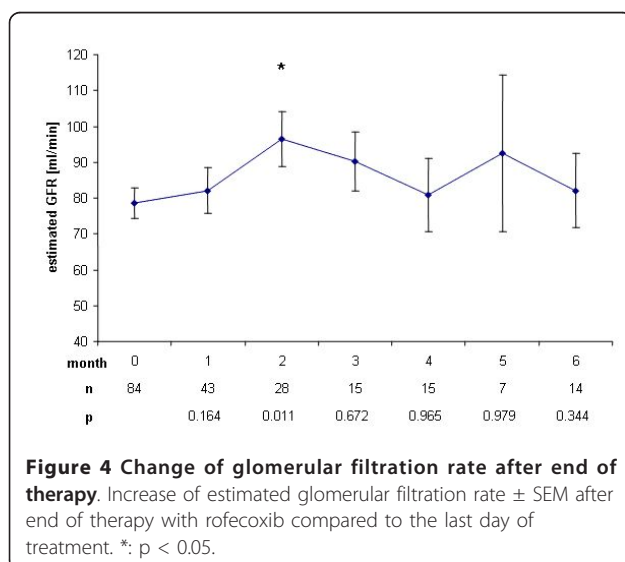


Mean diastolic blood pressure remained unchanged throughout the trial.

Discussion

We found a significant increase in mean serum creatinine concentration ($p < 0.0001$) already in the first month after initiation of treatment with rofecoxib. This increase was sustained during treatment and ranged around 0.15 mg/dl, corresponding to a decrease of eGFR of around 10 ml/min, reaching up to 14 ml/min in month 4. However, mean serum creatinine concentration remained within the normal range during and after end of the trial and no dialysis treatment was needed. Rofecoxib is known to cause acute renal failure at a rate of 1.2 to 1.5% in trials studying several thousands of patients [7,8], but even a single dose of rofecoxib can cause severe acute renal failure [9]. Furthermore, the half life of COX-II inhibitors rofecoxib and celecoxib is prolonged in liver failure [10]. Though patients with severe hepatic failure were excluded from the present study, 52% of the patients presented with liver metastasis and thus might have been subjected to a higher exposure of rofecoxib due to prolonged half life. Progressive underlying malignant disease may as well have contributed to functional prerenal failure i.e. due to decreased fluid intake. The decreased renal function however tended to normalize within 2 months after cessation of rofecoxib therapy (Figure 2 and 4), suggesting rofecoxib as the more likely cause of decreased renal function, especially as we observed no severe nausea, vomiting or diarrhea during the treatment phase.

We observed edema formation in 30 patients (34%), which is above the rate observed in large studies ranging between 7.7 and 23.3% [8,11,12] and which is possibly due to the persistent decrease in renal function, the



well-known sodium- and/or fluid retaining properties of COX-2 inhibitors and thiazolidindiones, and the underlying malignant disease with hypoproteinemia.

The rise in mean systolic blood pressure during therapy corresponds to published data [13,14] and went along with increasing body weight, probably both reflecting renal impairment and subsequent fluid retention. Weight gain is often seen in patients with diabetes treated with pioglitazone [15] and pioglitazone may have contributed to edema formation and the observed increase in body weight in our study, but weight gain in our study population is even more astonishing in regard of the underlying malignancy which usually leads to progressive weight loss as demonstrated after end of treatment.

Limitations

The antiinflammatory antiangiogenic therapy with a COX-II inhibitor in combination with pioglitazone and either trofosfamide or capecitabine seems to be both well tolerated and promising with primary disease response rates reaching up to 19% [3].

This study was stopped because of withdrawal of rofecoxib from the market, but the concept of an antiinflammatory antiangiogenic therapy with COX-II inhibitors proves to be true also for other COX-II inhibitors like celecoxib, still available on the market [16-18]. There are also clearly class effects like prolonged half life in liver failure [10] or decreasing renal function, which have been shown for rofecoxib as well as for celecoxib [19].

The decrease in renal function in our study has to be seen in the clinical context. A rise in mean serum creatinine concentration of 0.15 mg/dl is of limited importance to young patients with normal body weight and normal renal function. However, a mean fall in eGFR of up to 14 ml/min nevertheless may urge the physician to adapt the dose of concomitant medications or even stop the treatment with a COX-II inhibitor especially in the elderly patient with reduced body weight and pre-existing renal failure, suggesting the report of our results to be of persistent importance even in the light of withdrawal of rofecoxib from the market.

Conclusion

We recommend close monitoring of renal function and blood pressure of patients with cancer treated with COX-II inhibitors, especially in a setting with pre-existing renal and hepatic failure.

Acknowledgements

The authors thank all patients and the study nurses that participated in the study.

Author details

¹Klinik und Poliklinik für Innere Medizin II, University of Regensburg, Franz-Josef-Strauß-Allee 11, Regensburg, 93053, Germany. ²Abteilung für

Hämatologie und Internistische Onkologie, University of Regensburg, Franz-Josef-Strauß-Allee 11, Regensburg, 93053, Germany. ³V. Medizinische Klinik, Universitätsklinikum Mannheim, University of Heidelberg, Theodor-Kutzer-Ufer 1-3, Mannheim, 68167, Germany.

Authors' contributions

AR and BKK shared the conception and design of the study. SWR, UH, AR, BKK and SL were involved in data acquisition. SWR, BK, UH, BB and BKK were involved in statistical analysis and interpretation of the data. SWR, TB, BK, BB, AR and BKK participated in drafting and revision of the manuscript. All authors read and approved the final version of the manuscript.

Competing interests

The authors declare that they have no competing interests.

Received: 29 June 2010 Accepted: 5 January 2011

Published: 5 January 2011

References

1. Grösch S, Maier TJ, Schiffmann S, Geisslinger G: Cyclooxygenase-2 (COX-2)-independent anticarcinogenic effects of selective COX-2 inhibitors. *J Natl Cancer Inst* 2006, **98**:736-48.
2. Reichle A, Vogt T: Systems biology: A therapeutic target for tumor therapy. *Cancer Microenvironment* 2008, **1**:159-170.
3. Reichle A, Bross K, Vogt T, Bataille F, Wild P, Berand A, Krause SW, Andreesen R: Pioglitazone and rofecoxib combined with angiostatically scheduled trofosfamide in the treatment of far-advanced melanoma and soft tissue sarcoma. *Cancer* 2004, **101**:2247-56.
4. Becerra CR, Frenkel EP, Ashfaq R, Gaynor RB: Increased toxicity and lack of efficacy of Rofecoxib in combination with chemotherapy for treatment of metastatic colorectal cancer: A phase II study. *Int J Cancer* 2003, **105**:868-72.
5. Krämer BK, Kammerl MC, Kömhoff M: Renal Cyclooxygenase-2 (Cox-2). *Kidney Blood Press Res* 2004, **27**:43-62.
6. Cockcroft DW, Gault MH: Prediction of creatinine clearance from serum creatinine. *Nephron* 1976, **16**:31-41.
7. Bombardier C, Laine L, Reicin A, Shapiro D, Burgos-Vargas R, Davis B, Day R, Ferraz MB, Hawkey CJ, Hochberg MC, Kvien TK, Schnitzer TJ, for the VIGOR Study Group: Comparison of upper gastrointestinal toxicity of rofecoxib and naproxen in patients with rheumatoid arthritis. *N Engl J Med* 2000, **343**:1520-8.
8. Whelton A, Fort JG, Puma JA, Normandin D, Bello AE, Verburg KM, for the SUCCESS VI Study Group: Cyclooxygenase-2-specific inhibitors and cardiorenal function: A randomised, controlled trial of celecoxib and rofecoxib in older hypertensive osteoarthritis patients. *Am J Ther* 2001, **8**:85-95.
9. Reinhold SW, Fischereder M, Riegger GA, Krämer BK: Acute renal failure after administration of a single dose of a highly selective COX-2 inhibitor. *Clin Nephrol* 2003, **60**:295-6.
10. FitzGerald GA, Patrono C: The coxibs, selective inhibitors of cyclooxygenase-2. *N Engl J Med* 2001, **345**:433-42.
11. Whelton A, White WB, Bello AE, Puma JA, Fort JG, the SUCCESS-VII investigators: Effects of celecoxib and rofecoxib on blood pressure and edema in patients > 65 years of age with systemic hypertension and osteoarthritis. *Am J Cardiol* 2002, **90**:959-63.
12. Wolfe F, Zhao S, Pettitt D: Blood pressure destabilization and edema among 8538 users of celecoxib, rofecoxib, and nonselective nonsteroidal antiinflammatory drugs (NSAID) and nonusers of NSAID receiving ordinary clinical care. *J Rheumatol* 2004, **31**:1143-51.
13. Wolfe F, Michaud K, Zhao SZ: Patient perception of the burden of weight gain and blood pressure increase among RA patients using celecoxib, rofecoxib and non-specific NSAIDs. *J Clin Rheumatol* 2003, **9**:344-53.
14. Sowers JR, White WB, Pitt B, Whelton A, Simon LS, Winer N, Kivitz A, van Ingen H, Brabant T, Fort JG, Celecoxib Rofecoxib Efficacy and Safety in Comorbidities Evaluation Trial (CRESCENT) Investigators: The effects of cyclooxygenase-2 inhibitors and nonsteroidal anti-inflammatory therapy on 24-hour blood pressure in patients with hypertension, osteoarthritis, and type 2 diabetes mellitus. *Arch Intern Med* 2005, **165**:161-8.
15. Derosa G, Tinelli C, Maffioli P: Effects of pioglitazone and rosiglitazone combined with metformin on body weight in people with diabetes. *Diabetes Obes Metab* 2009, **11**:1091-9.
16. Lipton A, Campbell-Baird C, Witters L, Harvey H, Ali S: Phase II trial of gemcitabine, irinotecan, and celecoxib in patients with advanced pancreatic cancer. *J Clin Gastroenterol* 2010, **44**:286-8.
17. Bhatt RS, Merchan J, Parker R, Wu HK, Zhang L, Seery V, Heymach JV, Atkins MB, McDermott D, Sukhatme VP: A phase 2 pilot trial of low-dose, continuous infusion, or "metronomic" paclitaxel and oral celecoxib in patients with metastatic melanoma. *Cancer* 2010, **116**:1751-6.
18. Noberasco C, Spitaleri G, Mancuso P, Zorzino L, Radice D, Milani A, Rocca A, Bertolini F, Sandri MT, Curigliano G, de Pas T, Jemos C, Omodeo Salè E, Boselli S, de Braud F: Safety, tolerability and biological effects of long-term metronomic administration of non-cytotoxic anti-angiogenic agents. *Oncology* 2009, **77**:358-65.
19. Rossat M, Maillard J, Nussberger J, Brunner HR, Burnier M: Renal effects of cyclooxygenase-2 inhibition in normotensive salt-depleted subjects. *Clin Pharmacol Ther* 1999, **66**:76-84.

doi:10.1186/1756-0500-4-2

Cite this article as: Reinhold et al.: Renal function during rofecoxib therapy in patients with metastatic cancer: retrospective analysis of a prospective phase II trial. *BMC Research Notes* 2011 **4**:2.

Submit your next manuscript to BioMed Central
and take full advantage of:

- Convenient online submission
- Thorough peer review
- No space constraints or color figure charges
- Immediate publication on acceptance
- Inclusion in PubMed, CAS, Scopus and Google Scholar
- Research which is freely available for redistribution

Submit your manuscript at
www.biomedcentral.com/submit

