

Functional assessment of sequential coronary artery fistula and coronary artery stenosis with fractional flow reserve and stress adenosine myocardial perfusion imaging



Kuan Leong Yew^{a,*}, Poh Siang Ooi^a, Chiong Soon Law^b

^a Cardiology Department, Sarawak General Hospital Heart Center, Kota Samarahan, 94300 Sarawak

^b Nuclear Medicine Department, Sarawak General Hospital, Kuching, 93586 Sarawak

^{a,b}Malaysia

Coronary artery fistula is an abnormal connection between one coronary artery to another coronary artery or cardiac chambers. The coronary artery fistula may cause significant shunting of blood and cause “pseudo-stenosis” or “steal phenomenon”. This will also accentuate pre-existing mild-moderate de novo coronary lesions with resultant greater pressure gradient difference across the lesions. Thus, fractional flow reserve can be a useful tool to guide intervention decision on the coronary artery fistula. There are very few published reports regarding the use of FFR to assess coronary artery fistula. In fact, there is no outcome data regarding the deferment of coronary artery fistula intervention when the FFR is not physiologically significant. This case highlighted the use of FFR to evaluate the functional significance of coronary fistula in the setting of ischemia evaluation and it was proven to be safe to defer intervention with good 3 year clinical outcome. Stress adenosine myocardial perfusion imaging correlated with the FFR result.

© 2015 The Authors. Production and hosting by Elsevier B.V. on behalf of King Saud University. This is an open access article under the CC BY-NC-ND license (<http://creativecommons.org/licenses/by-nc-nd/4.0/>).

Keywords: Coronary artery fistula, Sequential coronary artery stenosis, Fractional flow reserve, Functional assessment, Stress adenosine myocardial perfusion imaging

A 37-year-old man had frequent left upper chest wall pain with inconclusive exercise stress test result. He was an obese man with type II diabetes mellitus, hypertension and dyslipidemia. The echocardiography study was normal. He subsequently underwent coronary angiography which revealed angiographically smooth right

coronary artery, left circumflex artery (LCX) and left main stem (LMS). However, there was an incidental fistula arising from the body of the LMS, and it appeared to drain into the main pulmonary artery. There was a concomitant moderate 50–60% stenosis in the mid left anterior descending artery (LAD) occurring just after the main diagonal branch (Fig. 1). We decided to assess

Disclosure: Authors have nothing to disclose with regard to commercial support.

Received 17 December 2014; accepted 21 March 2015.
Available online 30 March 2015

* Corresponding author. Tel.: +60 82 668111; fax: +60 82 455451.
E-mail address: yewkuanleong@yahoo.com (K.L. Yew).



P.O. Box 2925 Riyadh – 11461KSA
Tel: +966 1 2520088 ext 40151
Fax: +966 1 2520718
Email: sha@sha.org.sa
URL: www.sha.org.sa



1016–7315 © 2015 The Authors. Production and hosting by Elsevier B.V. on behalf of King Saud University. This is an open access article under the CC BY-NC-ND license (<http://creativecommons.org/licenses/by-nc-nd/4.0/>).

Peer review under responsibility of King Saud University.
URL: www.ksu.edu.sa
<http://dx.doi.org/10.1016/j.jsha.2015.03.008>



Production and hosting by Elsevier

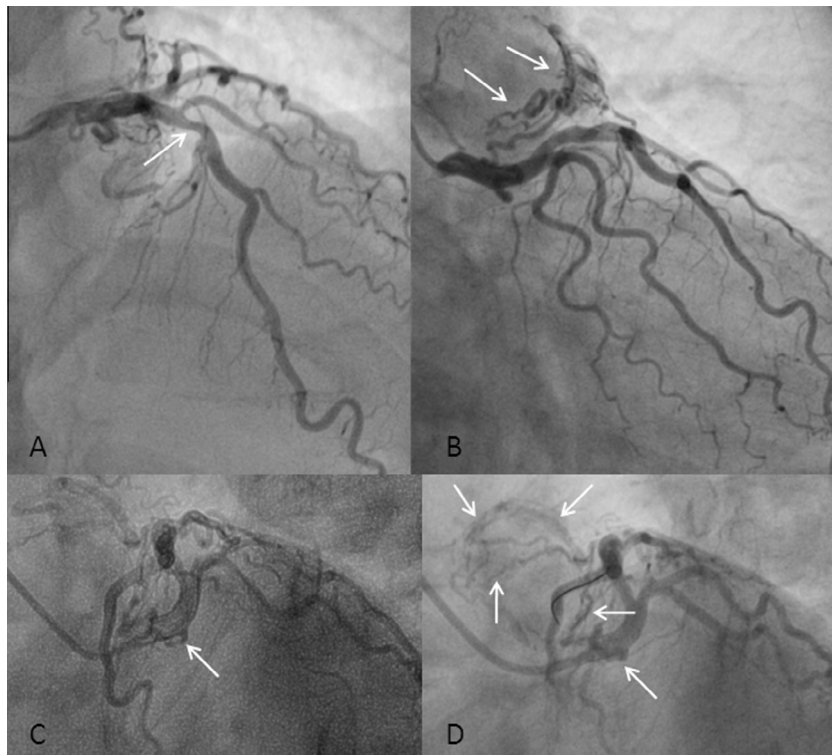


Figure 1. Coronary angiography showing the moderate mid left anterior descending artery lesion (white arrow) (A). Coronary angiography showing the coronary artery fistula arising from the left main artery and draining into the main pulmonary artery (white arrows) (B, C). Assessment of the functional significance of the coronary artery fistula (white arrows) with fractional flow reserve wire (D).

the functional significance of the fistula and LAD stenosis with fractional flow reserve (FFR) method. First, a PressureWire Certus (St. Jude Medical, Plymouth, USA) was placed in the LAD, with resting FFR value of 0.96. The lowest FFR reading after intracoronary 200 mcg glyceryl trinitrate (GTN) and incremental 300 mcg adenosine was 0.91. Then, the FFR wire was positioned in LCX which yielded a reading of 0.98 after administration of intracoronary 300 mcg adenosine.

We deemed that no intervention was necessary for either fistula or LAD lesion. Elective esophagogastroduodenoscopy found that he had gastritis with positive CLO test. He completed a treatment course for *Helicobacter pylori* eradication and has remained symptom free for the past three years. Stress myocardial perfusion scan with technetium-99 tetrofosmin and adenosine infusion revealed no evidence of inducible myocardial ischemia.

The mid-LAD lesion was not a critical lesion and would not warrant percutaneous coronary intervention (PCI). Moreover, coronary angiography would only give anatomical and luminal information. We did not know the additional impact of the coronary artery fistula (CAF) in the context of ischemia burden in this patient. The CAF has

been attributed to shortness of breath, angina, arrhythmias, myocardial infarction and heart failure [1–3]. The CAF may theoretically cause steal phenomenon or functional pseudo-stenosis by accentuating the pressure gradient across the erstwhile insignificant mid-LAD lesion. As the CAF originated from the LM, it may place the whole myocardium supplied by the left coronary system at risk of ischemia if the steal phenomenon was truly reducing the perfusion pressure downstream of LAD and LCX, with significant amount of blood shunted to the pulmonary artery. Thus, both true coronary stenosis conferring flow resistance and coronary blood shunting through the fistula can reduce the perfusion pressure distally and can ultimately cause myocardial infarction, as in a case described by Härle et al. [3,4]. Härle et al. further demonstrated that the FFR improved in the donor vessel when the fistula was temporary occluded [3]. In this respect, it is the coronary segment distal to the fistula that will be affected by the reduction in perfusion pressure with more proximal originating fistula placing more myocardium at risk of ischemia.

Hence, FFR would be a suitable and valuable adjunctive intracoronary physiology tool to detect any perfusion pressure difference caused by the stenotic lesion and CAF, either individually or in

tandem. For this clinical scenario, the ideal utilization of FFR would be pullback measurement of the FFR wire along the LAD to LM to separately identify the functional significance of both the stenosis and the fistula with a continuous infusion of adenosine.

However, the economic reality is that the cost of adenosine infusion prohibits its widespread usage. Instead, we performed the FFR with incremental intracoronary bolus dose of 60, 180 and 300 mcg adenosine. Hence, the obtained FFR reading in the LAD was a summation of the pathological coronary stenosis and fistula. The placement of the FFR wire in the LCX was an important step as it gave an indirect assessment of the LM originating fistula and provided a rough guide to its overall contribution to the obtained FFR value in the LAD.

In fact, our case is preceded by other reported cases of FFR use to assess the functional severity of the CAF alone or in combination with co-existing de novo mild-moderate coronary lesion [3–6]. Thus, the use of FFR to interrogate the functional significance of coronary fistula is not new. Intervention was considered for the coronary lesion and CAF in those cases with proven functional ischemia [3,6]. For this case, the operator decided to provisionally PCI the LAD lesion if the FFR reading was significant. If the FFR reading was still significant post PCI, he would have then proceeded to coil the CAF.

From landmark FFR studies, we know that FFR has prognostic value in guiding coronary revascularization decisions and that it is relatively reassuring to defer PCI when the FFR is ≥ 0.75 [7–9]. Sasi et al and Oh et al reported using FFR to interrogate the CAF and did not intervene further as the FFR values were not significant [4,5]. There are only limited similar cases described in the literature. Furthermore, we do not have long term data on the outcome of FFR guided deferment of CAF intervention and its validation with other forms of non-invasive stress testing. Cardiac magnetic resonance imaging or myocardial perfusion imaging with pharmacological

stressor and higher sensitivity and specificity in detecting inducible myocardial ischemia is a better option than the traditional treadmill stress test. The negative adenosine myocardial perfusion scan result correlated well with the obtained FFR assessment of the affected coronary artery.

Thus, this case is a very timely one, highlighting the utility of using a proven and simple tool to measure the functional significance of a sequential de novo coronary lesion and a CAF with clinical follow-up after non-interventional decision and negative adenosine myocardial perfusion scan. The FFR revealed that there was no steal phenomenon induced by the CAF with a reassuring three-year cardiac event free outcome. In conclusion, FFR can be a potentially useful tool to guide intervention decisions on the CAF.

References

- [1] Gowda RM, Vasavada BC, Khan IA. Coronary artery fistulas: clinical and therapeutic considerations. *Int J Cardiol* 2006;107(1):7–10.
- [2] Said SA, van der Werf T. Dutch survey of coronary artery fistulas in adults: congenital solitary fistulas. *Int J Cardiol* 2006;106(3):323–32.
- [3] Härle T, Kronberg K, Elsässer A. Coronary artery fistula with myocardial infarction due to steal syndrome. *Clin Res Cardiol* 2012;101(4):313–5.
- [4] Sasi V, Nemes A, Forster T, Ungi I. Functional assessment of a left coronary-pulmonary artery fistula by coronary flow reserve. *Postepy Kardiol Interwencyjnej* 2014;10(2):141–3.
- [5] Oh JH, Lee HW, Cha KS. Hemodynamic significance of coronary cameral fistula assessed by fractional flow reserve. *Korean Circ J* 2012;42(12):845–8.
- [6] Hollenbeck RD, Salloum JG. Sequential moderate coronary artery fistula and moderate coronary artery stenosis causing ischemia demonstrated by fractional flow reserve and relieved following percutaneous coronary intervention. *Catheter Cardiovasc Interv* 2014;83(3):443–7.
- [7] Tonino PA, De Bruyne B, Pijls NH, Siebert U, Ikeno F, van't Veer M, et al. Fractional flow reserve versus angiography for guiding percutaneous coronary intervention. *N Engl J Med* 2009;360(3):213–24.
- [8] De Bruyne B, Pijls NH, Kalesan B, Barbato E, Tonino PA, Piroth Z, et al. Fractional flow reserve-guided PCI versus medical therapy in stable coronary disease. *N Engl J Med* 2012;367(11):991–1001.
- [9] Pijls NH, van Schaardenburgh P, Manoharan G, Boersma E, Bech JW, van't Veer M, et al. Percutaneous coronary intervention of functionally nonsignificant stenosis: 5-year follow-up of the DEFER study. *J Am Coll Cardiol* 2007;49(21):2105–11.