



Case report

Severe dyspnea in a patient with neurofibromatosis type 1

P.B. Poble^{a,*}, J.C. Dalphin^a, B. Degano^b^a Department of Respiratory Diseases, University Hospital of Besançon, Besançon, France^b Department of Physiology and Respiratory Investigation, University Hospital of Besançon, Besançon, France

ARTICLE INFO

Article history:

Received 2 June 2017

Received in revised form

13 June 2017

Accepted 14 June 2017

ABSTRACT

Neurofibromatosis type 1 (NF1) is a genetic disease in which pulmonary complications are rare, but severe, especially pulmonary hypertension (PH). The mechanisms underlying the onset of PH in patients with NF1 are unclear and might be multifactorial. In particular, the frequent presence of pulmonary parenchymal lesions makes etiological diagnosis of PH difficult. We describe here the case of a patient with NF1 admitted to our clinic with dyspnea and right heart failure revealing severe pre-capillary PH. Parenchymal lesions were mild and PH was attributed to pulmonary vascular involvement. Clinical and hemodynamic conditions of the patient improved under pulmonary arterial hypertension-specific combination therapy. This case suggests that treatment of PH due to pulmonary vascular involvement in NF1 may be aligned with recommendations for PAH treatment.

© 2017 The Authors. Published by Elsevier Ltd. This is an open access article under the CC BY-NC-ND license (<http://creativecommons.org/licenses/by-nc-nd/4.0/>).

1. Background

Von Recklinghausen disease, also called neurofibromatosis type 1 (NF1), is an inherited autosomal-dominant genetic disorder with complete penetrance [1,2] caused by mutations in the *NF1* gene that is localized on the long arm of chromosome 17 on 17q11.2. NF1 has a birth incidence of about 1 in 2,700, and a prevalence of 1 in 4560 [3]. The most frequent pulmonary involvements of NF1 are nodal and cystic parenchymal lesions [4,5] and interstitial lung diseases [6,7]. Pulmonary hypertension due to pulmonary vascular involvement is an uncommon, but well-recognized complication of NF1 [8,9].

2. Case presentation

Here, we report the case of a 55-year-old Caucasian woman with a personal and family history of neurofibromatosis type 1 (according to National Institutes of Health Consensus Bethesda criteria) [10]. She had many café-au-lait spots and cutaneous neurofibromas. She was a former smoker and had never taken anorexigens, toxins or drugs. She was referred to our hospital for progressive dyspnea on exercise lasting for one year. At initial assessment, she was in NYHA functional class III. Clinical evaluation revealed peripheral edema and crackles at auscultation. Blood

pressure was 125/80 mmHg and heart rate was 118/min. Oxygen saturation was 95% breathing room air (pH = 7.50; PaO₂ = 9.1 kPa; PaCO₂ = 3.3 kPa), and BNP was 1360 pg.mL⁻¹. At this stage, treatment with diuretics was initiated.

3. Investigations

High resolution computed tomography (HRCT) of the chest revealed bilateral cystic lesions mostly in the tops of the lungs, without lesions of fibrosis (Fig. 1). There was also dilation of the right cardiac cavities and an increase in the diameter of the pulmonary artery (PA), with a PA/aorta ratio greater than one (Fig. 2). There was no evidence of pulmonary embolism on the HRCT or V/Q lung scan. Transthoracic echocardiography showed dilated right heart chambers, normal left ventricular systolic and diastolic function, no pericardial effusion and an estimated systolic pulmonary artery pressure of 65 mmHg. The main results of right heart catheterization (RHC) are given in Table 1. Acute vasodilator test was negative. Pulmonary function tests (PFTs) revealed decreased lung transfer for carbon monoxide (TLCO; 49% of predicted value [pred]), and normal lung volumes and airflow (total lung capacity: 104% pred, FVC: 93% pred and FEV₁: 104% pred). Serology for HIV, hepatitis B and C virus, and autoantibodies were all negative. Six-minute walk distance (6MWD) was 402 m, without significant oxygen desaturation. Cardiopulmonary exercise testing (CPET) showed a peak VO₂ greater than 15 ml/min/kg, without ventilatory limitation. Unfortunately, the BMPR2 mutation was not available.

All these results were consistent with severe pre-capillary

* Corresponding author.

E-mail address: paul.benoit.poble@gmail.com (P.B. Poble).

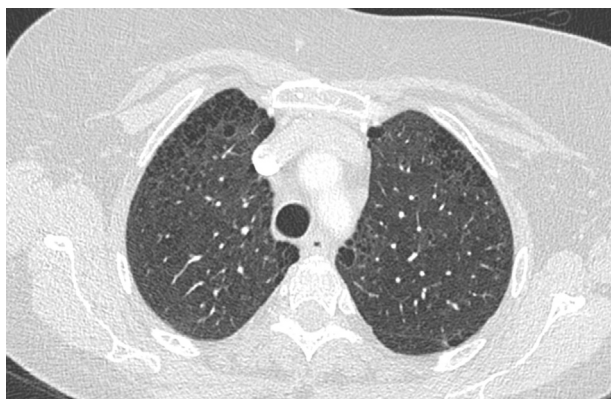


Fig. 1. HRCT of the chest revealing bilateral cystic lesions.

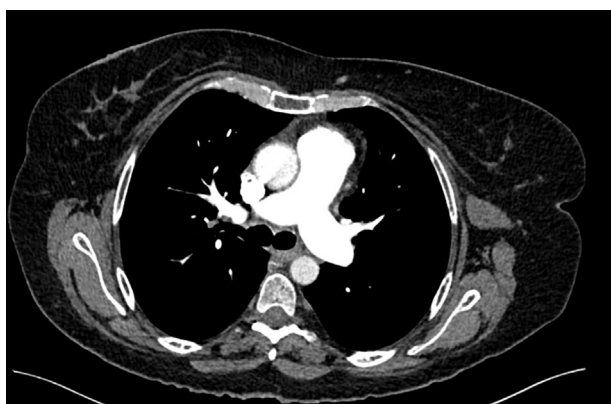

Fig. 2. HRCT of the chest showing PA/aorta ratio > 1.

pulmonary hypertension without a left heart failure component; lung parenchymal involvement was considered not to contribute to PH. The treatment algorithm for group 1 PH in the Nice classification was applied. The patient was classified in the intermediate-risk group. Treatment with a phosphodiesterase type 5 inhibitor (PDE5i) (tadalafil) in association with general measures and supportive therapy (diuretics and oral anticoagulation) was initiated. At 3 months follow-up, the patient was still in NYHA functional class III, but no longer had signs of right heart failure. 6MWD had increased to 470 m, BNP was <10 pg/mL. Peak VO_2 was 18 ml/min/

kg (77% predicted). RHC showed hemodynamic improvement (Table 1). Despite these positive findings, a combined sequential treatment strategy was chosen due to the persistence of significant symptoms. An endothelin receptor antagonist (ERA) (ambrisentan) was added. At 6 months follow-up, all therapeutic goals were achieved (Table 1). Currently, 9 months after diagnosis, the patient's condition is stable under double combination therapy.

4. Discussion

Appropriate classification of pulmonary hypertension is at the basis of the choice of an appropriate treatment strategy. In some conditions, including NF1, the potential causes of PH are multiple, and each has to be examined. In our patient, left heart failure and thromboembolic disease were ruled out. In addition, we concluded that parenchymal lesions were not responsible for dyspnea or pulmonary hypertension because lung volumes and airflow were preserved, and because there was no ventilatory limitation during CPET. Nevertheless, the etiological diagnosis of PH in NF1 may be difficult in the presence of lung parenchymal lesions. These lesions are frequent in NF1, and may combine upper lobe cystic and/or bullous disease with basilar fibrosis, most often resulting in an obstructive pattern on PFTs [6]. The confrontation of HRCT and PFTs could help to differentiate PH due to lung diseases from PAH associated NF1. CPET may also be helpful in order to differentiate between cardiovascular and ventilatory limitations of exercise in these patients.

NF1-PAH is an extremely severe complication of NF1 characterized by late onset, female predominance, severe hemodynamic impairment, poor response to PAH-specific therapy and poor outcome [11]. To the best of our knowledge, only twenty-one cases of NF1-associated PAH have been reported [11–19]. As these cases are rare and the underlying mechanisms are unclear and multifactorial, this entity has been listed in group 5 of the PH clinical classification [20]. Although there are currently no specific therapeutic guidelines in NF1-PAH, optimal management requires the advice of an expert referral centre [21]. The histological lesions of pulmonary arteries occurring in NF1-PAH are not specific and the literature is very poor regarding this issue. As reported in some cases, plexogenic arteriopathy and complex plexiform lesions similar to those observed in idiopathic PAH have been observed on autopsy specimens in NF1-PAH [12], suggesting that treatment of NF1-PAH might be modeled on treatment of Group 1 PAH. In the series reported by Montani et al., every patient underwent sequential combination therapy (except one who was referred for

Table 1

Risk assesment and right heart catheterization data at initial assessment, three and six months follow-up.

	Diagnosis	3 months follow-up	6 months follow-up
Clinical signs of right heart failure	Present	Absent	Absent
WHO functional class	III	III	II
6MWD	402 m	>440 m	>440 m
Cardiopulmonary exercise testing	Peak VO_2 > 15 ml/min/kg (>65% pred.)	Peak VO_2 > 15 ml/min/kg (>65% pred.)	Peak VO_2 > 15 ml/min/kg (>65% pred.)
BNP plasma levels	1360 pg/mL	<10 pg/mL	<10 pg/mL
Haemodynamics	mPAP 41 mmHg PCWP 3 mmHg RAP < 8 mmHg CI 2L/min/m ² PVRi 19 mmHg/L/min per m ² SvO2 56%	mPAP 39 mmHg PCWP 8 mmHg RAP < 8 mmHg CI 2,6 L/min/m ² PVRi 11,9 mmHg/L/min per m ² SvO2 66%	mPAP 33 mmHg PCWP 9 mmHg RAP < 8 mmHg CI 2,7 L/min/m ² PVRi 8,9 mmHg/L/min per m ² SvO2 68%

mPAP = mean pulmonary arterial pressure.

RAP = right atrial pressure.

PCWP = pulmonary capillary wedge pressure.

CI = cardiac index.

PVRi = indexed pulmonary vascular resistance calculated as (mPAP-PCWP)/CI.

SvO2 = mixed venous oxygen saturation.

lung transplantation), mostly based on a combination of PDE5i and ERA [11]. For our patient, we chose the goal-oriented treatment strategy of Group 1 with an aggressive sequential combination. In the absence of any data in the literature regarding upfront combination therapy in NF1-PAH, we did not choose this strategy, although it has been shown to be promising in Group 1 PAH [22]. Interestingly, tyrosine kinase inhibitors that downregulate the MAPK pathway may have a beneficial therapeutic effect in NF1-PAH [11,23]. Indeed, germline mutation in the NF1 gene leads to a loss of GTPase activity of neurofibromin (the protein that results in uncontrolled MAPK pathway activation), which in turns leads to dysregulation of cell proliferation and differentiation [24]. These mechanisms may be involved in the genesis of NF1-PAH [25].

In conclusion, NF1-PAH is rare disease, and this diagnosis must be considered in the presence of suggestive symptoms. Comparing results from multimodal testing including HRCT, PFTs and CPET is key to the diagnostic approach. The current therapeutic strategy is almost identical to that of Group 1 and should be aggressive given the low survival. Improved understanding of the underlying molecular and genetic mechanisms could help to develop novel therapies.

References

- [1] S. Pinson, A. Créange, S. Barbarot, J.F. Stalder, Y. Chaix, D. Rodriguez, et al., Recommendations for the treatment of neurofibromatosis type 1, *J. Fr. Ophthalmol.* 25 (4) (avr 2002) 423–433.
- [2] R.M. Reynolds, G.G.P. Browning, I. Nawroz, I.W. Campbell, Von Recklinghausen's neurofibromatosis: neurofibromatosis type 1, *Lancet Lond Engl.* 361 (9368) (3 mai 2003) 1552–1554.
- [3] R.E. Ferner, Neurofibromatosis 1 and neurofibromatosis 2: a twenty first century perspective, *Lancet Neurol.* 6 (4) (avr 2007) 340–351.
- [4] J.H. Ryu, J.G. Parambil, P.S. McGrann, G.L. Aughenbaugh, Lack of evidence for an association between neurofibromatosis and pulmonary fibrosis, *Chest* 128 (4) (oct 2005) 2381–2386.
- [5] A. Oikonomou, K. Vadikolias, T. Birbilis, D. Bouros, P. Prassopoulos, HRCT findings in the lungs of non-smokers with neurofibromatosis, *Eur. J. Radiol.* 80 (3) (déc 2011) e520–523.
- [6] A.C. Zamora, H.R. Collard, P.J. Wolters, W.R. Webb, T.E. King, Neurofibromatosis-associated lung disease: a case series and literature review, *Eur. Respir. J.* 29 (1) (janv 2007) 210–214.
- [7] W.R. Webb, P.C. Goodman, Fibrosing alveolitis in patients with neurofibromatosis, *Radiology* 122 (2) (févr 1977) 289–293.
- [8] S.J. Hamilton, J.M. Friedman, Insights into the pathogenesis of neurofibromatosis 1 vasculopathy, *Clin. Genet.* 58 (5) (nov 2000) 341–344.
- [9] J.T. Lie, Vasculopathies of neurofibromatosis type 1 (von Recklinghausen disease), *Cardiovasc Pathol. Off. J. Soc. Cardiovasc Pathol.* 7 (2) (avr 1998) 97–108.
- [10] National Institutes of Health consensus Development conference statement: neurofibromatosis. Bethesda, Md., USA, July 13–15, 1987, *Neurofibromatosis* 1 (3) (1988) 172–178.
- [11] D. Montani, F. Coulet, B. Girerd, M. Eyries, E. Bergot, H. Mal, et al., Pulmonary hypertension in patients with neurofibromatosis type 1, *Med. Baltim.* 90 (3) (mai 2011) 201–211.
- [12] D.R. Stewart, J.D. Cogan, M.R. Kramer, W.T. Miller, L.E. Christiansen, M.W. Pauculo, et al., Is pulmonary arterial hypertension in neurofibromatosis type 1 secondary to a plexogenic arteriopathy? *Chest* 132 (3) (sept 2007) 798–808.
- [13] J.K. Porterfield, R.E. Pyeritz, T.A. Traill, Pulmonary hypertension and interstitial fibrosis in von Recklinghausen neurofibromatosis, *Am. J. Med. Genet.* 25 (3) (nov 1986) 531–535.
- [14] P.J. Engel, R.P. Baughman, S.G. Menon, D.J. Kereiakes, L. Taylor, M. Scott, Pulmonary hypertension in neurofibromatosis, *Am. J. Cardiol.* 99 (8) (15 avr 2007) 1177–1178.
- [15] K. Ennibi, I. El Kassimi, I. Asfalou, J. Chaari, A. Benyass, Pulmonary hypertension and von Recklinghausen's disease: association and therapeutic difficulties, *Pneumol. Buchar Rom.* 64 (3) (sept 2015) 55–57.
- [16] S. Simeoni, A. Puccetti, M. Chilosi, E. Tinazzi, D. Prati, R. Corrocher, et al., Type 1 neurofibromatosis complicated by pulmonary artery hypertension: a case report, *J. Med. Investig. JMI* 54 (3–4) (août 2007) 354–358.
- [17] Y. Aoki, M. Kodama, T. Mezaki, R. Ogawa, M. Sato, M. Okabe, et al., Von Recklinghausen disease complicated by pulmonary hypertension, *Chest* 119 (5) (mai 2001) 1606–1608.
- [18] F. Kamdar, T. Thenappan, E. Missov, Pulmonary arterial hypertension in von Recklinghausen's disease, *Am. J. Med.* 128 (10) (oct 2015) e39–40.
- [19] N. Samuels, N. Berkman, E. Milgater, J. Bar-Ziv, G. Amir, M.R. Kramer, Pulmonary hypertension secondary to neurofibromatosis: intimal fibrosis versus thromboembolism, *Thorax* 54 (9) (sept 1999) 858–859.
- [20] G. Simonneau, M.A. Gatzoulis, I. Adatia, D. Celermajer, C. Denton, A. Ghofrani, et al., Updated clinical classification of pulmonary hypertension, *J. Am. Coll. Cardiol.* 62 (25 Suppl) (24 déc 2013) D34–D41.
- [21] « 2015 ESC/ERS guidelines for the diagnosis and treatment of pulmonary hypertension. The joint task force for the diagnosis and treatment of pulmonary hypertension of the European Society of Cardiology (ESC) and the European Respiratory Society (ERS). » Nazzareno Galiè, Marc Humbert, Jean-Luc Vachiery, Simon Gibbs, Irene Lang, Adam Torbicki, Gérald Simonneau, Andrew Peacock, Anton Vonk Noordegraaf, Maurice Beghetti, Ardeschir Ghofrani, Miguel Angel Gomez Sanchez, Georg Hansmann, Walter Klepetko, Patrizio Lancellotti, Marco Matucci, Theresa McDonagh, Luc A. Pierard, Pedro T. Trindade, Maurizio Zompatori and Marius Hooper. *Eur Respir J* 2015; 46: 903–975, *Eur. Respir. J.* 46 (6) (déc 2015) 1855–1856.
- [22] N. Galiè, J.A. Barberà, A.E. Frost, H.-A. Ghofrani, M.M. Hoeper, V.V. McLaughlin, et al., Initial use of ambrisentan plus tadalafil in pulmonary arterial hypertension, *N. Engl. J. Med.* 373 (9) (27 août 2015) 834–844.
- [23] Y. Tamura, T. Ono, M. Sano, K. Fukuda, M. Kataoka, T. Satoh, Favorable effect of sorafenib in a patient with neurofibromatosis-associated pulmonary hypertension, *Am. J. Respir. Crit. Care Med.* 186 (3) (1 août 2012) 291–292.
- [24] H. Brems, E. Beert, T. de Ravel, E. Legius, Mechanisms in the pathogenesis of malignant tumours in neurofibromatosis type 1, *Lancet Oncol.* 10 (5) (mai 2009) 508–515.
- [25] L. Reviron-Rabec, B. Girerd, A. Seferian, K. Campbell, S. Brosseau, E. Bergot, et al., Pulmonary complications of type 1 neurofibromatosis, *Rev. Mal. Respir.* (33, 8 févr 2016).