



# Patient Transfer with Kocher Forceps on the Axillary Artery: A Rare Case of Ongoing Iatrogenic Vascular Injury

Charalampos Seretis<sup>1</sup>, Andreas Tsimpoukis<sup>1</sup>, Andreas Georgiakakis<sup>1</sup>, Panagiotis Kitrou<sup>2</sup>, Eleftheria Panteli<sup>3</sup>, and Spyros I. Papadoulas<sup>1</sup>

Departments of <sup>1</sup>Vascular Surgery, <sup>2</sup>Interventional Radiology, and <sup>3</sup>Anesthesiology, University Hospital of Patras, Patras, Greece

Iatrogenic trauma of the axillary artery by non-vascular surgeons can occur during various general surgical procedures such as resection of soft tissue tumors or axillary lymph node clearance. Prompt recognition, appropriate initial management, and rapid transfer to a tertiary vascular surgery service, if needed, are key steps to ensuring patient safety. Here we present a case of iatrogenic axillary artery injury during the resection of a recurrent soft tissue tumor in a local hospital. The desperate application of a Kocher clamp on the bleeding axillary artery by the operating general surgeons controlled the bleeding but led to further arterial damage. The patient was transferred to our tertiary hospital, where the arterial injury was repaired using a vein interposition graft. Apart from the encountered intraoperative technical challenges, this case highlights the need for broader training of non-vascular specialist surgeons on the core principles of basic vascular surgical techniques and oncovascular surgery.

Received February 7, 2022

Revised March 15, 2022

Accepted March 18, 2022

Published on March 31, 2022

Corresponding author: Spyros I. Papadoulas

Department of Vascular Surgery,  
University Hospital of Patras, Rio, Patras  
26504, Greece

Tel: 30-2610999406

Fax: 30-2610999360

E-mail: [spyros.papadoulas@gmail.com](mailto:spyros.papadoulas@gmail.com)

<https://orcid.org/0000-0001-8628-2173>

**Key Words:** Axillary artery, Emergencies, Vascular surgical procedures

Copyright © 2022 The Korean Society for Vascular Surgery

This is an Open Access article distributed under the terms of the Creative Commons Attribution Non-Commercial License (<http://creativecommons.org/licenses/by-nc/4.0>) which permits unrestricted non-commercial use, distribution, and reproduction in any medium, provided the original work is properly cited.

Cite this article; Vasc Specialist Int 2022. <https://doi.org/10.5758/vsi.220010>

## INTRODUCTION

Iatrogenic axillary artery injuries are not commonly encountered and usually occur during orthopedic operations of the shoulder and upper humerus or during interventional radiology procedures [1-4]. Apart from immediate intraoperative iatrogenic injuries, axillary artery occlusion is a rare complication of external beam radiotherapy, mainly in breast cancer patients [5,6]. We report a case of a patient who was transferred with a Kocher forceps on the injured axillary artery for hemorrhage control. To the best of our knowledge, there are no previous reports similar to this case of severe crushing injury secondary to placement of traumatic forceps directly on the axillary artery as a salvage hemostatic maneuver by non-vascular specialist surgeons.

This case report was approved by the Institutional Review Board of the University Hospital of Patras (IRB no. 29/11-07-2018). The patient provided informed consent for the presentation of this case.

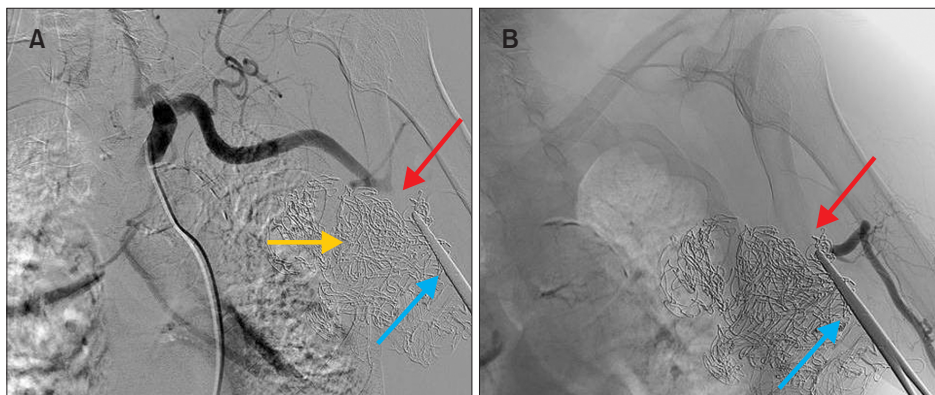
## CASE

An 83-year-old Caucasian male was transferred to our emergency department from a local general hospital where he underwent resection of a recurrent sizeable lipoma in the left axillary area under local anesthesia. During the index procedure, the operating general surgeons encountered brisk bleeding while dissecting the circumference of the lesion, attempted to gain control with the application of hemostatic sutures, and finally applied Kocher forceps directly

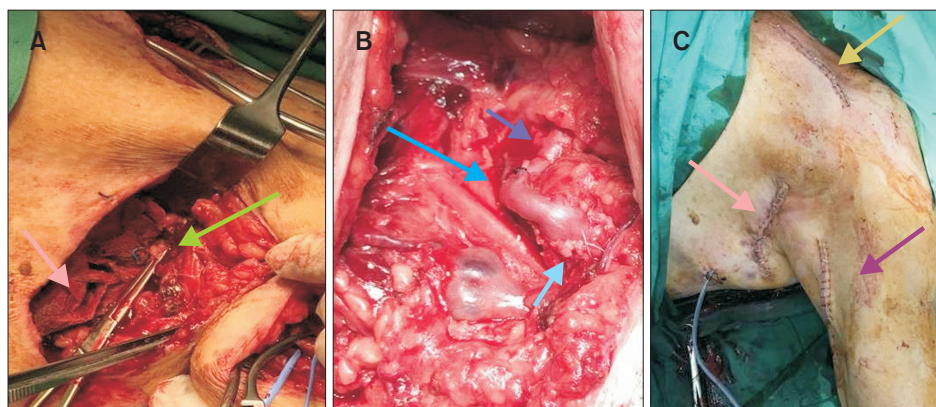
on the bleeding point on the axillary artery. Pressure dressings were further applied in the axillary cavity to aid hemostasis. The wound was closed with interrupted sutures, and the patient was transferred to our center with Kocher forceps in situ. The left arm appeared pale, pulseless, and without pain or features of impaired sensation and motility. Urgent angiography demonstrated abrupt disruption of the arterial blood flow in the axillary artery at the level of the external occlusion (Fig. 1). Hence, in the absence of interventional treatment options, the patient was urgently transferred to the operating theater for surgical exploration and injury repair. Of note, at the time the decision was made to perform operative exploration and arterial reconstruction, a total of 4 hours had elapsed from the point of occlusion of the axillary artery.

Wide preparations of the trunk, left arm, and thigh were performed to harvest the great saphenous vein (GSV) as an autologous graft. Vascular control was achieved proximally

and distally using two new separate incisions allowing access to the infraclavicular axillary artery and brachial artery, respectively. The initial wound was subsequently explored, 19 pressure swabs were removed, and the tip of the Kocher forceps was clamped to the axillary artery, causing a significant focal crushing injury. The axillary artery was dissected, clamped proximally and distally and the Kocher forceps was removed. A longitudinal arteriotomy revealed multiple intimal disruptions and focal transections. The approximately 3.5-cm injured segment of the axillary artery was resected, and a thromboembolectomy with a 3 Fr Fogarty catheter was performed but revealed no distal thrombus. Arterial continuity was restored using GSV interposition grafting (Fig. 2). An upper limb fasciotomy was deemed unnecessary; after the confirmation of palpable radial pulses, the patient was transferred to the intensive care unit for further postoperative management. His postoperative course was uncomplicated from a vascular perspective



**Fig. 1.** Preoperative digital subtraction angiography image demonstrated abrupt loss of contrast filling in the axillary artery due to the application of crushing Kocher forceps. (A) Antegrade angiography image taken via femoral access. (B) Retrograde angiography image taken via brachial access. Red arrow, filling defect; blue arrow, Kocher forceps; yellow arrow, pressure dressings.



**Fig. 2.** Operative photos: (A) The tip of the Kocher forceps was crushing the axillary artery (green arrow) and pressure dressings were applied in the axillary cavity to aid hemostasis (pink arrow). (B) Interposition venous graft (light blue arrow) with proximal (dark blue) and distal anastomoses (green-blue arrow). (C) Postoperative photo depicted the subclavian incision for proximal control (beige arrow), the brachial incision for distal control (purple arrow), and the initial axillary incision made at the local hospital (pink arrow).

despite a prolonged rehabilitation period due to the need for a percutaneous tracheostomy during hospitalization in the intensive care unit.

## DISCUSSION

The current case highlights the need for careful preoperative planning when extensive dissection is anticipated close to major vascular structures, including the liberal use of cross-sectional imaging such as computed tomography angiography or magnetic resonance angiography to enable the advance formation of a precise operative plan. Under this notion, patients at the possible risk of major vascular structure injury intraoperatively could ideally be directly referred to tertiary centers with on-site vascular and interventional radiology coverage so that if an inadvertent vascular injury occurs, immediate help would be available. In addition, we believe that there are further learning points for non-vascular specialists for the intraoperative management of iatrogenic axillary artery injuries. More specifically, the placement of a non-traumatic artery forceps instead of a traumatic one, such as the Kocher forceps used in this case, could have resulted in a less severe crushing injury and hence reduced the complexity of the final reconstructive procedure.

A more appropriate maneuver from the general surgeon in the local hospital would be to control the bleeding digitally both distally and proximally to the bleeding point. The use of suction would enable primary suturing of the partial artery transection with non-absorbable polypropylene or polybutylene monofilament sutures. Even if this urgent and possibly non-fine manipulation led to moderate arterial stenosis, it would not be a problem because the rich collateral circulation of the shoulder precludes severe arm ischemia. If the patient remained asymptomatic or had mild symptoms, no further intervention would be required. Percutaneous angioplasty is performed in selected cases.

All of the above-mentioned points indicate the imperative need to train non-vascular surgeons in the fundamental and core procedures of vascular surgery, particularly if they operate in non-tertiary hospitals without on-site vascular surgery coverage. Globally, the lack of basic training in vascular surgery emergencies and key vascular procedures has been a well-recognized problem for non-vascular surgery trainees [7]. From a root-cause analysis perspective, we believe that the magnitude of axillary artery injury is a cumulative effect of suboptimal preoperative planning and intraoperative decisions and can be avoided by appropriately focused training in the fundamentals of vascular surgery.

Regarding the operative strategy during definitive management of this type of injury, a stepwise approach is

mandatory that adheres to the principles of proximal and distal vascular control prior to the attempt of any risky dissection of the previously dissected area. The concept of oncovascular surgery has recently become widely used and emphasized during the resection of benign or malignant tumors with anticipated involvement/critical proximity of the tumor to major vascular structures [8-10]. The use of an oncovascular multidisciplinary team approach is important. Vascular surgeons play a crucial role in achieving better outcomes; thus, they must take initiative from preoperative planning and surgery to postoperative treatment. Undoubtedly, this implies the need for dedicated and accredited senior oncovascular fellowships in specialized high-volume centers [8-10]. To the best of our knowledge, despite the recognition of this training gap on an international scale, no relevant accredited pathway has yet been established. However, until the structured development of relevant subspecialization, educating non-vascular surgeons on the basic vascular surgical techniques and principles of oncovascular surgery is of paramount importance and should be incorporated in the training curricula of national and international non-vascular societies.

Finally, apart from the above-mentioned plea for moving the concept of oncovascular surgery forward, we strongly recommend pre-planned appropriate patient positioning and preparation for vein graft harvesting as we advocate against the use of synthetic grafts in a potentially contaminated surgical field [11,12]. The latter would apply in all settings of emergency/trauma cases as well as in other potentially contaminated fields in which major vascular reconstructions are required, such as in the context of multi-visceral resections for abdominopelvic tumors.

## FUNDING

None

## CONFLICTS OF INTEREST

The authors have nothing to disclose.

## ORCID

Charalampos Seretis

<https://orcid.org/0000-0001-6887-3308>

Andreas Tsimpoukis

<https://orcid.org/0000-0001-9437-7412>

Andreas Georgiakakis

<https://orcid.org/0000-0002-4389-330X>

Panagiotis Kitrou

<https://orcid.org/0000-0001-7631-2068>

Eleftheria Panteli

<https://orcid.org/0000-0002-6267-1032>

Spyros I. Papadoulas

<https://orcid.org/0000-0001-8628-2173>

## AUTHOR CONTRIBUTIONS

Concept and design: SIP, CS. Analysis and interpretation: PK, EP. Data collection: AG, AT. Writing the article: CS, SIP. Critical revision of the article: PK. Final approval of the article: all authors. Statistical analysis: none. Obtained funding: none. Overall responsibility: SIP.

## REFERENCES

- 1) O'Neill DR, King JJ, Farmer KW. Reverse total shoulder arthroplasty after iatrogenic axillary artery injury: a case report. *J Shoulder Elbow Surg* 2021;30:e121-e128.
- 2) Reid D, Chue WL. Endovascular management of an axillary arterial injury post shoulder dislocation. *Emerg Med Australas* 2009;21:515-517.
- 3) Veraldi GF, De Manzoni G, Tasselli S, Minicozzi A, Ruzzenente A, Pacca R, et al. Iatrogenic axillary artery injury from humeral neck fracture repair. A rare and unusual event in which and aggressive strategy was mandatory to save a child limb. *Chir Ital* 2006;58:247-251.
- 4) Riemer BL, D'Ambrosia R. The risk of injury to the axillary nerve, artery, and vein from proximal locking screws of humeral intramedullary nails. *Orthopedics* 1992;15:697-699.
- 5) Farrugia M, Gowda KM, Cheatle TR, Ashok TP. Radiotherapy-related axillary artery occlusive disease: percutaneous transluminal angioplasty and stenting. Two case reports and review of the literature. *Cardiovasc Intervent Radiol* 2006;29:1144-1147.
- 6) Bucci F, Robert F, Fiengo L, Plagnol P. Radiotherapy-related axillary arteriopathy. *Interact Cardiovasc Thorac Surg* 2012;15:176-177.
- 7) Panagiotopoulou IG, Pilgrim S, Sengupta N, Iype S, Fareed K, Cattle K, et al. What vascular skills do general surgery trainees need to learn? *Ann R Coll Surg Engl (Suppl)* 2014;96:308-311.
- 8) Sallam K, Khairy H. Oncovascular surgery and the making of the oncovascular surgeon. *Vasc Specialist Int* 2019;35:189-192.
- 9) Han A, Ahn S, Min SK. Oncovascular surgery: essential roles of vascular surgeons in cancer surgery. *Vasc Specialist Int* 2019;35:60-69.
- 10) Han SM. Oncovascular surgery: there would be no such thing without vascular surgeons. *Vasc Specialist Int* 2019;35:53-54.
- 11) Baker AC, Clouse WD. Upper extremity and junctional zone injuries. In: Rasmussen TE, Tai NRM, editors. *Rich's vascular trauma*. 3rd ed. Philadelphia: Elsevier; 2016. p. 149-167.
- 12) Kobayashi L, Coimbra R, Goes AMO Jr, Reva V, Santorelli J, Moore EE, et al. American Association for the Surgery of Trauma-World Society of Emergency Surgery guidelines on diagnosis and management of peripheral vascular injuries. *J Trauma Acute Care Surg* 2020;89:1183-1196.