

Magnetic Resonance Imaging-guided High-intensity Focused Ultrasound Ablation for Endometriosis of the Abdominal Wall

Minh Duc Nguyen*

Department of Radiology, Pham Ngoc Thach University of Medicine, Ho Chi Minh City, Vietnam

A 38-year-old patient with three children suffered from right-sided palpable nodules along with cyclic pain and swelling nodule in the low abdominal region during menstruation for 9 months. The Visual Analogue Scale (VAS) of the patient was 8 at clinical examination. In addition, she had a history of three times adopted cesarean section delivery. The patient was diagnosed with endometriosis of the rectus abdominis muscle via ultrasound-guided biopsy 1 month ago and indicated an open surgery to eradicate lesion completely. Nevertheless, the patient desired to experience a noninvasive therapy; she was admitted to our interventional radiology center for magnetic resonance imaging-guided high-intensity focused ultrasound (MRI-guided HIFU). MRI findings showed that she had a 180-mm old transversal scar [Figure 1a]. There was no evidence of uterine adenomyosis. Endometriosis lesion is located in the right rectus abdominis muscle with a diameter of 12 mm. The lesion was high intensity on T2-weighted image [Figure 1b]. Before the treatment, the patient was adopted bowel preparation and fasted for 12 h. Diazepam (5 mg) was utilized 30 min prior to treatment. Intravenous drip infusions of paracetamol (1000 mg) and fentanyl citrate (100 µg) in 500 ml normal saline were managed before initiating the ablation. During the ablation procedure, the patient was positioned in the prone. In addition, due to prior long abdominal scar, we exploited polyethylene foam scar patch to cover the scar to avoid sonicating through the scar [Figure 1c]. Furthermore, we utilized a 4-cm thick gel pad so as to increase the distance from the transducer to the lesion to reduce the patient's heating sensation. Vital signs including blood pressure, heart rate, respiration rate,

and oxygen saturation were all consecutively assessed during the treatment. We used only three of 4-mm diameter treatment cells with a very low power of 60 W to sonicate centeredly and cautiously the lesion to avoid damage of adjacent tissues. Between each sonication, we prolonged the cooling time up to 5 min so that the temperature of the skin can recover to the baseline temperature, therefore decreasing the risk of fat and skin burn. The total duration treatment was about 20 min. At immediate posttreatment, T1-weighted image with contrast enhancement manifested that the lesion was fully ablated [Figure 1d]. There was no evidence of the surrounding fat burn or skin burn. The patient was discharged at the same day. At 1-month, 3-month, and 6-month follow-ups, the VAS of the patient was reduced to 6, 2, and 1, respectively. In addition, on T2-weighted image at 6-month follow-up, the volume and high signal intensity of lesion were lessened significantly in comparison with the baseline features [Figure 2]. There were no severe complications during the follow-up period.

Endometriosis of the abdominal wall accounts for 0.1% of endometriosis patients, which is generally diagnosed postoperatively.^[1] Until now, conventional and standard therapy to treat this disease is surgery.^[2] Recently, the wish of patients who do not want to undergo a surgery or have a new scar urges the innovation and utilization of some other minimally invasive therapies such as HIFU under the guidance of MRI or ultrasound. HIFU treatment is successfully applied for the treatment of various

Article History:

Received 27 May 2019
Received in revised form 20 September 2019
Accepted 3 October 2019
Available online 23 January 2020

Access this article online

Quick Response Code:



Website:
www.e-gmit.com

DOI:
10.4103/GMIT.GMIT_47_19

Address for correspondence:

Dr. Minh Duc Nguyen,
Department of Radiology, Pham Ngoc Thach University of Medicine, 02
Duong Quang Trung, Ward 12, District 10, Ho Chi Minh City, Vietnam.
E-mail: bsnguyenminhduc@pnt.edu.vn

This is an open access journal, and articles are distributed under the terms of the Creative Commons Attribution-NonCommercial-ShareAlike 4.0 License, which allows others to remix, tweak, and build upon the work non-commercially, as long as appropriate credit is given and the new creations are licensed under the identical terms.

For reprints contact: reprints@medknow.com

How to cite this article: Nguyen MD. Magnetic resonance imaging-guided high-intensity focused ultrasound ablation for endometriosis of the abdominal wall. *Gynecol Minim Invasive Ther* 2020;9:45-6.

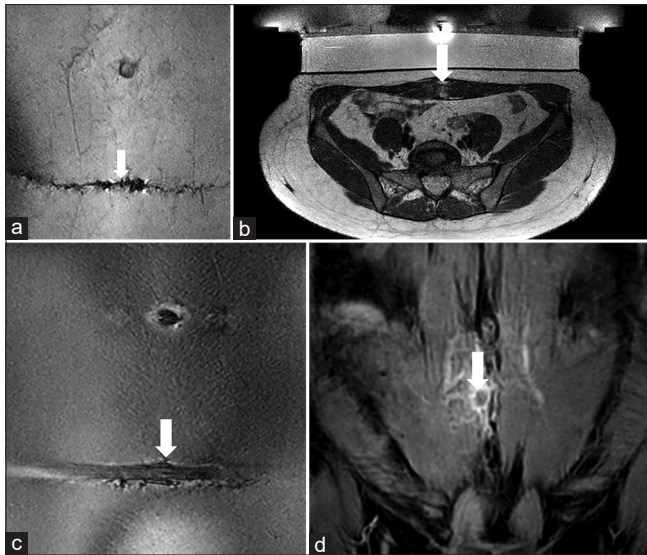


Figure 1: (a) Coronal T2-weighted fast-field echo image shows a long transversal cesarean scar (white arrow). (b) Axial T2-weighted image shows a hyperintense endometriosis lesion inside the right rectus abdominis muscle (white arrow). (c) Coronal T2-weighted fast-field echo image shows a transversal cesarean scar covered with scar path (white arrow). (d) Coronal T1-weighted with contrast enhancement image shows the fully ablated lesion after MRI-guided HIFU treatment (white arrow)

gynecological diseases such as uterine leiomyoma and uterine adenomyosis. The sonication beam lifts the tissue's temperature efficaciously up to 65°C or more which induces coagulation necrosis of lesion.^[3] In this study, our findings showed that the endometriosis of the rectus abdominis muscle is ablated flourishingly without adverse effects. The patient's VAS was improved significantly during the follow-up period. Our results are fully concordant with the previous studies.^[4-7] In terms of therapeutic outcome, there is no significant difference between the HIFU and surgical treatment for this disease.^[2] There are some advantages of HIFU treatment for this disease including quick recovery, no blood loss, no exposure to anesthesia, and no formation of a new scar. Nonetheless, there are some disadvantages of this therapy such as high installed investment, high maintaining cost, and large consuming space.^[8] Overall, the clinician should take into consideration that HIFU in some circumstances can be utilized as an alternatively noninvasive treatment for endometriosis of the abdominal wall.

Ethical approval

Pham Ngoc Thach University of Medicine Institutional Review Board has approved this project, IRB No. 6_CDHA obtained on 22th May in 2015.

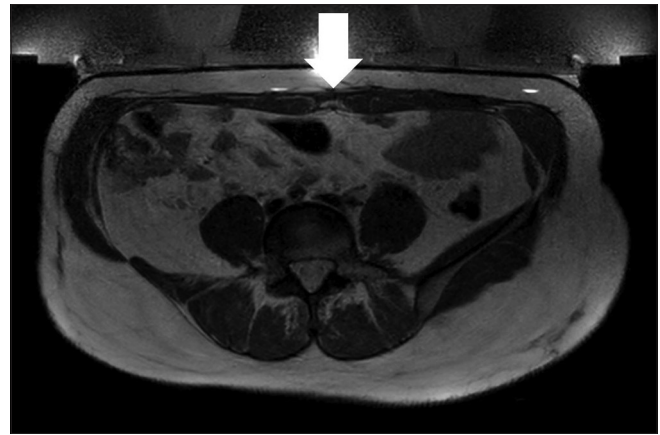


Figure 2: Axial T2-weighted image shows an absence of hyperintense endometriosis lesion inside the right rectus abdominis muscle (white arrow) along with a reduction of lesion size compared to axial T2-weighted image features prior to the treatment

Declaration of patient consent

The authors certify that they have obtained all appropriate patient consent forms. In the form, the patient has given her consent for her images and other clinical information to be reported in the journal. The patient understands that her name and initials will not be published and due efforts will be made to conceal their identity, but anonymity cannot be guaranteed.

Financial support and sponsorship

Nil.

Conflicts of interest

There are no conflicts of interest.

REFERENCES

1. Sedhain N, Dangal G, Karki A, Pradhan HK, Shrestha R, Bhattachan K, *et al.* Cesarean scar endometriosis. *J Nepal Health Res Counc* 2018;15:292-4.
2. Zhu X, Chen L, Deng X, Xiao S, Ye M, Xue M. A comparison between high-intensity focused ultrasound and surgical treatment for the management of abdominal wall endometriosis. *BJOG* 2017;124 Suppl 3:53-8.
3. Duc NM, Huy HQ. Influences of screening magnetic resonance imaging parameters on high-intensity focused ultrasound outcome for adenomyosis. *Rep Med Imaging* 2018;11:9-14.
4. Duc NM, Huy HQ, Keserci B. Adverse events of focused ultrasound surgery for uterine fibroids and adenomyosis. *Rep Med Imaging* 2018;11:15-26.
5. Nguyen MD. Single-phase focused ultrasound surgery for 15-leiomyoma and huge leiomyoma patients. *Gynecol Minim Invasive Ther* 2018;7:178-80.
6. Luo S, Zhang C, Huang JP, Huang GH, He J. Ultrasound-guided high-intensity focused ultrasound treatment for abdominal wall endometriosis: A retrospective study. *BJOG* 2017;124 Suppl 3:59-63.
7. Wang Y, Wang W, Wang L, Wang J, Tang J. Ultrasound-guided high-intensity focused ultrasound treatment for abdominal wall endometriosis: Preliminary results. *Eur J Radiol* 2011;79:56-9.
8. Kim YS. Clinical application of high-intensity focused ultrasound ablation for uterine fibroids. *Biomed Eng Lett* 2017;7:99-105.