



Since January 2020 Elsevier has created a COVID-19 resource centre with free information in English and Mandarin on the novel coronavirus COVID-19. The COVID-19 resource centre is hosted on Elsevier Connect, the company's public news and information website.

Elsevier hereby grants permission to make all its COVID-19-related research that is available on the COVID-19 resource centre - including this research content - immediately available in PubMed Central and other publicly funded repositories, such as the WHO COVID database with rights for unrestricted research re-use and analyses in any form or by any means with acknowledgement of the original source. These permissions are granted for free by Elsevier for as long as the COVID-19 resource centre remains active.



Contents lists available at ScienceDirect

Diabetes & Metabolic Syndrome: Clinical Research & Reviews

journal homepage: www.elsevier.com/locate/dsx

Review and Meta-analysis

Global reports of myocarditis following COVID-19 vaccination: A systematic review and meta-analysis



Sirwan Khalid Ahmed ^{a, c, *}, Mona Gamal Mohamed ^b, Rawand Abdulrahman Essa ^a,
Eman Abdelaziz Ahmed Rashad ^b, Peshraw Khdir Ibrahim ^c, Awat Alla Khdir ^a,
Zhiar Hussien Wsu ^a

^a Department of Emergency, Rania Pediatric & Maternity Teaching Hospital, Rania, Sulaimani, Kurdistan-region, Iraq

^b Department of Adult Nursing, RAK Medical and Health Sciences University, Ras Al Khaimah, United Arab Emirates

^c Department of Adult Nursing, University of Raparin, Rania, Sulaimani, Kurdistan-region, Iraq

ARTICLE INFO

Article history:

Received 29 March 2022

Received in revised form

30 April 2022

Accepted 17 May 2022

Keywords:

COVID-19

Myocarditis

COVID-19 vaccines

mRNA vaccine

Cardiovascular complications

ABSTRACT

Background and aims: Recent media reports of myocarditis after receiving COVID-19 vaccines, particularly the messenger RNA (mRNA) vaccines, are causing public concern. This review summarizes information from published case series and case reports, emphasizing patient and disease characteristics, investigation, and clinical outcomes, to provide a comprehensive picture of the condition.

Methods: A systematic literature search of PubMed and Google scholar was conducted from inception to April 27, 2022. Individuals who develop myocarditis after receiving the COVID-19 vaccine, regardless of the type of vaccine and dose, were included in the study.

Results: Sixty-two studies, including 218 cases, participated in the current systematic review. The median age was 29.2 years; 92.2% were male and 7.8% were female. 72.4% of patients received the Pfizer-BioNTech (BNT162b2) vaccine, 23.8% of patients received the Moderna COVID-19 Vaccine (mRNA-1273), and the rest of the 3.5% received other types of COVID-19 vaccine. Furthermore, most myocarditis cases (82.1%) occurred after the second vaccine dose, after a median time interval of 3.5 days. The most frequently reported symptoms were chest pain, myalgia/body aches and fever. Troponin levels were consistently elevated in 98.6% of patients. The admission ECG was abnormal in 88.5% of cases, and the left LVEF was lower than 50% in 21.5% of cases. Most patients (92.6%) resolved symptoms and recovered, and only three patients died.

Conclusion: These findings may help public health policy to consider myocarditis in the context of the benefits of COVID-19 vaccination.

© 2022 Diabetes India. Published by Elsevier Ltd. All rights reserved.

1. Introduction

International efforts to drive vaccinations are critical to restoring health and economic and social recovery as the SARS-CoV-2 coronavirus (COVID-19)-caused pandemic continues [1]. The COVID-19 vaccines developed by Pfizer-BioNTech (BNT162b2) and Moderna (mRNA-1273) were granted emergency approval by the Food and Drug Administration (FDA) of the United States in December 2020. Reports of myocarditis after the COVID-19 vaccination, notably after the messenger RNA (mRNA) vaccines, have

recently received widespread media attention, causing widespread concern among the general public [1]. Myocarditis is diagnosed in about ten to twenty people per 100,000 in the general population each year, and it is more common in men and younger age groups [2]. Myocarditis following mRNA COVID-19 vaccination was first reported in Israel in April 2021, and then several case reports and case series were reported around the world.

Specifically, this report examines the current literature on myocarditis following COVID-19 vaccination, summarizing available information from previously published case reports and case series, with a strong attention on reporting patient and disease characteristics, as well as investigation and clinical outcome, in order to provide a comprehensive picture of the condition.

* Corresponding author. Department of Emergency, Rania Pediatric & Maternity Teaching Hospital, Rania, Sulaimani, 46012, Kurdistan region-Iraq, Iraq.

E-mail address: sirwan.ahmed1989@gmail.com (S.K. Ahmed).

2. Methods

2.1. Review objectives

The main objective is to clarify the potential occurrence of myocarditis associated with COVID-19 vaccination and elaborate on the demographic and clinical characteristics of COVID-19 vaccinated individuals who develop myocarditis and how many cases have been reported in the literature.

2.2. Protocol and registration

The review is written in accordance with the Preferred Reporting Items for Systematic Reviews and Meta-Analyses (PRISMA) 2020 guidelines for the systematic review of available literature [3]. The protocol of the review was registered in the International Prospective Register of Systematic Reviews (PROSPERO) with ID CRD42022308997. The AMSTAR-2 checklist was also used to evaluate this study, and it was found to be of high quality [4]. This review article does not require ethics approval.

2.3. Search strategy

A comprehensive search of major electronic databases (PubMed and Google Scholar) was conducted on April 27 10, 2022, to locate all publications. The AND operator was used to connect two of the most important concepts in the search terminology ("COVID-19" AND "Myocarditis"). ("Myocarditis" and "COVID-19" OR "SARS-CoV-2" OR "Coronavirus Disease 2019" OR "severe acute respiratory syndrome coronavirus 2" OR "coronavirus infection" OR "2019-nCoV" AND "vaccine, vaccination, OR vaccine" were used in the search. To make sure the search was completed, we checked the references of all relevant papers.

2.4. Eligibility criteria

All case series and case reports on post-COVID-19 vaccine myocarditis in humans were included. Individuals who develop myocarditis after receiving the COVID-19 vaccine, regardless of the type of vaccine and dose. The references of the relevant articles will also be reviewed for additional articles that meet the inclusion criteria. Narrative and systematic reviews, original and unavailable data papers were excluded from this review. Moreover, articles other than English were excluded in this review.

2.5. Data extraction and selection process

PRISMA 2020 was used to guide every step of the data extraction process from the original source. Two independent authors (SKA and RAE) used the Rayyan website to screen abstracts and full-text articles based on inclusion and exclusion criteria [5]. The discrepancies between the two independent authors were resolved by discussion. Microsoft Excel spreadsheets collected the necessary information from the extracted data. Author names, year of publication, age, gender, type of COVID-19 vaccine, dose, days to symptoms onset, symptoms, troponin level, LVEF 50% or LVEF >50%, ECG, length of hospital stay/days, treatment, and outcomes were extracted from each study.

2.6. Critical appraisal

To assess the quality of all included studies, we used the Joanna Briggs Institute's critical appraisal tool for case series and case reports [6]. Two different authors (SKA and RAE) evaluated each article, each of whom worked independently. Paper evaluation

disputes were resolved through discussion. Articles with an average score of 50% or higher were included in the data extraction process. The AMSTAR 2 criteria were used to evaluate the results of our systematic review [4]. The AMSTAR 2 tool assigned a "moderate" rating to the overall quality of our systematic review.

2.7. Data synthesis and analysis

All the articles included in the current systematic review were analyzed, and the data were extracted and pooled. This included (authors' names, year of publication; gender; type of COVID-19 vaccine, dose, days to symptoms onset, troponin level, LVEF below or above 50%, ECG, length of hospital stay/days; treatment and outcomes). We gathered this data from the results of eligibility studies. COVID-19 vaccine recipients who developed myocarditis were included in the study.

3. Results

3.1. Selection of studies

When we searched the major databases (PubMed and Google Scholar) on April 27, 2022, we discovered 2979 articles relevant to our search criteria. A citation manager tool (Mendeley) was then used to organize the references, and 397 articles were automatically removed because they contained duplicate content. Next, the titles, abstracts, and full texts of 2585 articles were checked for accuracy, and 2494 articles were rejected because they did not meet the criteria for inclusion. Besides that, 91 articles were submitted for retrieval, but twenty-seven were rejected because they did not meet our inclusion requirements. The current systematic review was limited to 62 articles in total (Fig. 1). The details of case reports and case series are shown in (Table 1).

3.2. Characteristics of the included studies

Overall, sixty-two studies, including 218 cases each, from the United States, Italy, Israel, Germany, Poland, France, Korea, Brazil, Japan, Mexico, Spain, New Zealand, Portugal, Germany, Iraq Turkey and Iran participated in this systematic review. The median age was 29.2 years; 92.2% were male and 7.8% were female. 72.4% of patients received the Pfizer-BioNTech (BNT162b2) vaccine, 23.8% of patients received the Moderna COVID-19 Vaccine (mRNA-1273), and the rest of the 3.5% received other types of vaccines (Johnson & Johnson, AstraZeneca, Sinovac, Sputnik V vaccine).

The vast majority of cases are from the United States. All patients were diagnosed with myocarditis or myopericarditis following COVID-19 vaccination, regardless of the type of vaccine and dose.

Furthermore, most myocarditis cases (82.1%, n = 179) occurred after the second vaccine dose, after a median time interval of 3.5 days. The most frequently reported symptoms were chest pain (99.1% n = 216), fever (31.6% n = 69), myalgia/body aches (36.6% n = 80), and also variable reports of viral prodromes such as chills, headaches, and malaise. Troponin levels were consistently elevated in 98.6% (n = 215) of the cases where they were reported, consistent with myocardial injury. The admission electrocardiogram (ECG) was abnormal in 88.5% (n = 193) of cases, and the left ventricular ejection fraction (LVEF) was lower than 50% in 21.5% (n = 47) of cases. The median length of hospital stay was 5.8 days in 182 patients but unknown in 36 patients. The vast majority of patients (92.6%) (n = 202) resolved symptoms and recovered, and only three patients died (Table 2).

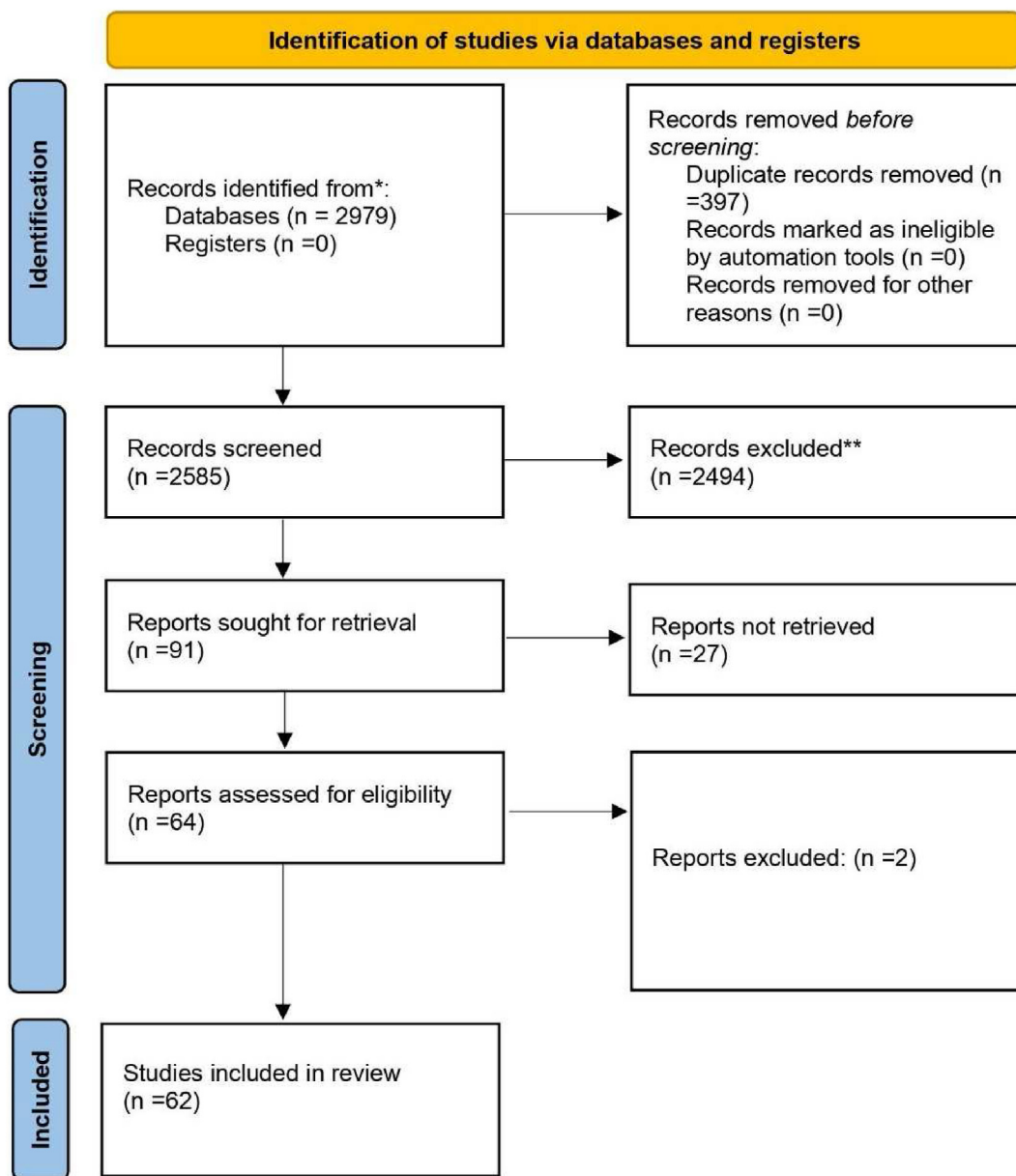


Fig. 1. PRISMA flow-diagram.

4. Discussion

The current systematic review summarized evidence from the original case reports and case series that explored the development of myocarditis after the COVID-19 vaccination. Throughout the selected studies, most of the participants were male, from the USA, and their mean age 29.2 was years old. The vaccine-induced myocarditis mechanism is unknown but may be related to the active pathogenic component of the vaccine and specific human proteins, which could lead to immune cross-reactivity resulting in autoimmune disease, which is one cause of myocarditis [7–10]. The occurrence of myocarditis in men may be related to sex hormone variations, as testosterone hormone suppresses anti-inflammatory immune cells while promoting more aggressive T helper cells [7,11].

These findings were matched with Oster et al. (2022) [12], who found the incidence rate of myocarditis among vaccinated male people was similar to that seen in typical cases of myocarditis and

there was a strong male predominance for both conditions [13]. Fatima et al. (2022) [7] found most patients who developed myocarditis were males. Moreover, Patone et al. (2022) [14] mentioned that the incidence of myocarditis was among England males younger than 40 years old. Similarly, a systematic review study found that the Incidence of myocarditis following mRNA vaccines is low but probably highest in males aged 12–29 years old [15].

Another important finding in the current systematic review is that most participants received Pfizer-BioNTech (BNT 162b2) followed by the Moderna COVID-19 vaccine (mRNA-1273), and most of the cases who complained of myocarditis received two doses of the vaccine. This indicates that mRNA vaccines are associated with a higher risk of developing myocarditis than viral vector vaccines, including Janssen, Oxford, and Sinovac. Bozkurt et al. (2021) [2], have assumed that autoantibody generation could attack cardiac myocytes in response to the mRNA vaccine, increasing the risk.

Table 1

Characteristics and outcomes of patients with myocarditis related to COVID-19 vaccine.

Author/Year of publication	Country	Age	Gender	Type of COVID-19 vaccine	Dose	Days to symptom onset	Symptoms	Troponin level	LVEF <50% or LVEF >50%	Electrocardiogram (ECG)	Treatment	Length of hospital stay (days)	Outcome
Abu Mouch et al., 2021 [24]	Israel	6 cases mean age 22 years	All of them were male	BNT162b2	2nd in 5 cases and 1st in one case	Mean 4.5 days	Chest pain/discomfort	Elevated in all cases	LVEF >50% in all cases	Abnormal in all cases	NSAIDs and colchicine	Mean 5.6 days	Recovered
Marshall et al., 2021 [25]	USA	7 cases mean age 16.7 years	All of them were male	BNT162b2	2nd	Mean 2.57 days	Chest pain	Elevated in all cases	LVEF >50% in 6 cases and LVEF <50% in one case	Abnormal in all cases	NSAIDs, IVIg, IV methylprednisolone, PO prednisone, famotidine, aspirin	Mean 11.57 days	Recovered
D'Angelo et al., 2021 [26]	Italy	30 years	Male	BNT162b2	1st	21 days	dyspnea, constrictive retrosternal pain, nausea, and profuse sweating	Elevated	LVEF >50%	Abnormal	Bisoprolol, aspirin, and prednisolone	7 days	Recovered
Nassar et al., 2021 [27]	USA	70 years	Female	. Ad26.COV2-S	1st	2 days	The patient arrived at the emergency department in severe respiratory distress	Elevated	LVEF >50%	Abnormal	vasopressors and antibiotic therapy	8 days	Died
Kim et al., 2021 [28]	USA	4 cases mean age 38.25 years	3 males and 1 female	mRNA-1273 in 2 cases And BNT162b2 in 2 cases	2nd	Mean 2.75 days	Chest pain	Elevated in all cases	LVEF >50% in 3 cases and LVEF <50% in one case	Abnormal in all cases	Corticosteroids NSAIDs and colchicine	Mean 2.5 days	Recovered
Montgomery et al., 2021 [10]	USA	23 cases mean age 25 years	All of them were male	BNT162b2 in 7 cases and mRNA-1273 in 16 cases	2nd in 20 cases and 1st in 3 cases	Mean 2 days	Chest pain	Elevated in all cases	LVEF <50% in 4 cases and LVEF ≥50% in 19 cases	Abnormal in 19 cases and normal in 4 cases	All patients received brief supportive care	Mean 7 days	16 cases were fully recovered and 7 cases under follow-up
Verma et al., 2021 [29]	USA	2 cases (45, 42) years Mean age 43.5 years	1 male and 1 female	BNT162b2- in 1 case and mRNA-1273 in 1 case	1st in one case and 2nd in another case	Mean 12 days	Chest pain, dyspnea and dizziness,	Elevated in all cases	LVEF >50% in all cases	Abnormal in all cases	intravenous diuretics, methylprednisolone, lisinopril, spironolactone, and metoprolol succinate).	7 days	female case recovered and male case died
Rosner et al., 2021 [30]	USA	7 cases Mean age 27.42 years	All of them were male	BNT162b2 in 5 cases, one case mRNA-1273 and one case Ad26.COV2-S	2nd in 6 cases and 1st in one case	Mean 3.85 days	Chest pain	Elevated in all cases	LVEF >50% in 6 cases and LVEF <50% in one case	Abnormal in 6 cases and normal in one case	β-blocker and anti-inflammatory medication	Mean 2.85 days	Recovered
Dionne et al., 2021 [31]	USA	15 cases mean age 15 years	14 cases male and one case female	BNT162b2 in all cases	2nd in all cases	Mean 3 days	Chest pain, fever, myalgia, headache	Elevated in all cases	Mean LVEF <50% in all cases	Abnormal in all cases	β-blocker therapy.	Mean 2 days	Recovered
García et al., 2021 [32]	Mexico	39 years	Male	BNT162b2	2nd	¼ day	Chest pain	Elevated	LVEF >50%	Abnormal	anti-inflammatory medication	6 days	Recovered
Dickey et al., 2021 [33]	USA	6 cases mean age 27 years	All of them were male	BNT162b2 in 5 cases and one case mRNA-1273	2nd	Mean 3.33 days	chest pain, chills, myalgia, malaise, headache and fever	Elevated in all cases	LVEF >50% in 3 cases and LVEF <50% in 3 cases	Abnormal in 5 cases and normal in one case	Unknown	Unknown	Recovered
Tano et al., 2021 [34]	USA	8 cases mean age	All of them were male	BNT162b2 in all cases	2nd in 7 cases and	Mean 2.37 days	Chest pain, fatigue, abdominal pain, fever, shortness of breath	Elevated in all cases	LVEF >50% in all cases	Abnormal in 6 cases and normal in 2 cases	NSAIDs	Mean 2.36 days	Recovered

Larson et al., 2021 [35]	USA and Italy	16.61 years 8 cases mean age 31.62 years	All of them were male	BNT162b2 in 5 cases and 3 cases mRNA-1273	1st in one case 2nd in 7 cases and 1st in one case	Mean 2.75 days	Chest pain, myalgia, fever, chills, shortness of breath and cough	Elevated in all cases	LVEF >50% in 6 cases and LVEF <50% in 2 cases	Abnormal in 7 cases and normal in 1 case	NSAIDs, colchicine and prednisone	Unknown	Recovered
Deb et al., 2021 [36]	USA	67 years	Male	mRNA-1273	2nd	¼ day	Nausea, orthopnea, fatigue	Elevated	LVEF >50%	Normal	intravenous furosemide, bronchodilators	2 days	Recovered
Abbate et al., 2021 [37]	USA	2 cases mean age 30.5 years	One male and one female	BNT162b2 in all cases	2nd in one case and 1st in second case	Mean 5.5 days	Fever, cough, chest pain, nausea and vomiting	Unknown	LVEF <50% in all cases	Abnormal in all cases	Prednisone	73 days for one case	One case died and one recovered
Muthukumar et al., 2021 [38]	USA	52 years	Male	mRNA-1273	2nd	1 day	Chest pain, fevers, shaking chills, myalgias, and headache	Elevated	LVEF <50%	Abnormal	low-dose lisinopril and carvedilol	4 days	Recovered
Isaak et al., 2021 [39]	Germany	15 years	Male	BNT162b2	2nd	1 day	fever, myalgia	Elevated	LVEF <50%	Abnormal	Unknown	7 days	Recovered
Cereda et al., 2021 [40]	Italy	12 years	Male	BNT162b2	2nd	1 day	Chest pain	Elevated	LVEF >50%	Abnormal	Bisoprolol and ramipril	7 days	Recovered
Watkins et al., 2021 [41]	USA	20 years	Male	BNT162b2	2nd	2 days	Chest pain and shortness of breath	Elevated	LVEF >50%	Abnormal	Colchicine, metoprolol, ibuprofen	Unknown	Recovered
Chamling et al., 2021 [42]	Germany	3 cases mean age 37.66 years	2 males and 1 female	BNT162b2 in 2 cases, and ChAdOx1 nCoV-19 in 1 case	1st in 2 cases and 2nd in 1 case	Mean 7 days	Chest pain	Elevated in 2 case and not elevated in 1 case	LVEF >50% in all cases	Abnormal in 2 cases and normal on 1 case	Unknown	Unknown	Recovered
Mansour et al., 2021 [43]	USA	2 cases mean age 23 years	1 male and 1 female	mRNA-1273 in all cases	2nd in all cases	1 day	Chest pain, fever,	Elevated in all cases	LVEF >50% in all cases	Abnormal in all cases	metoprolol	Mean 2 days	Recovered
Levin et al., 2021 [44]	Israel	7 cases mean age 20.42 years	All of them were male	BNT162b2 in all cases	2nd in all cases	Mean 7 days	Chest pain, fatigue, fever and headache	Elevated in all cases	LVEF >50% in 5 cases LVEF <50% in 2 cases	Abnormal in all cases	Colchicine, Ibuprofen, Bisoprolol, and Ramipril	Mean 2.5 days	Recovered
Schauer et al., 2021 [45]	USA	13 cases mean age 15.07 years	12 male and 1 female	BNT162b2 in all cases	2nd in all cases	Mean 2.76 days	chest pain, shortness of breath, fever and myalgia	Elevated in all cases	LVEF >50% in 11 cases LVEF <50% in 2 cases	Abnormal in 9 cases and normal in 4 cases	NSAIDs	Mean 2 days	Recovered
Shumkova et al., 2021 [46]	Poland	23 years	Male	BNT162b2	2nd	1 day	chest pain, shortness of breath and fever	Elevated	LVEF >50%	Abnormal	Aspirin and methylprednisolone	6 days	Recovered
Minocha et al., 2021 [47]	USA	17 years	Male	BNT162b2	2nd	2 days	chest pain	Elevated	LVEF >50%	Abnormal	NSAIDs	6 days	Recovered
Hasnie et al., 2021 [48]	USA	22 years	Male	mRNA-1273	1st	3 days	Chest pain	Elevated	LVEF >50%	Abnormal	Aspirin and colchicine	2 days	Recovered
Starekova et al., 2021 [49]	USA	5 cases mean age 25.2 years	4 males and 1 female	BNT162b2 in 3 cases and mRNA-1273 in 2 cases	2nd in all cases	Mean 2,6 days	Chest pain, fatigue, nausea, fever, chills and myalgia	Elevated in all cases	LVEF >50% in 4 cases LVEF <50% in 1 case	Abnormal in 4 cases and normal in 1 case	Unknown	Unknown	Recovered
Koizumi et al., 2021 [50]	Japan	2 cases mean age 24.5 years	All of them were male	mRNA-1273 in all cases	2nd in all cases	Mean 2.5 days	Chest pain	Elevated in all cases	LVEF >50% in all cases	Abnormal in all cases	NSAIDs	Mean 4 days	Recovered
McLean et al., 2021 [51]	USA		Male	BNT162b2	2nd	1 day	Chest pain	Elevated	LVEF >50%	Abnormal	NSAIDs	7 days	Recovered

(continued on next page)

Table 1 (continued)

Author/Year of publication	Country	Age	Gender	Type of COVID-19 vaccine	Dose	Days to symptom onset	Symptoms	Troponin level	LVEF <50% or LVEF >50%	Electrocardiogram (ECG)	Treatment	Length of hospital stay (days)	Outcome
Riedel et al., 2021 [52]	Brazil	16 years 47 years	Male	Sinovac COVID-19 vaccine in activated (China)	2nd	Unknown	Chest pain Cough and myalgia	Elevated	LVEF <50%	Abnormal	Unknown	Unknown	Recovered
In-Cheol et al., 2021 [53]	Korea	24 years	Male	BNT162b2	2nd	1 day	Chest pain	Elevated	LVEF >50%	Abnormal	Unknown	5 days	Recovered
Nguyen et al., 2021 [54]	Germany	20 years	Male	mRNA-1273	1st	1 day	Chest pain, fatigue and myalgia	Elevated	LVEF >50%	Abnormal	Unknown	Unknown	Recovered
Azdaki et al., 2021 [55]	Iran	70 years	Male	ChAdOx1 nCoV-19.	1st	3 days	Syncope	Elevated	LVEF >50%	Abnormal	magnesium sulfate	7 days	Recovered
Sokolska et al., 2021 [56]	Poland	21 years	Male	BNT162b2	1st	3 days	Chest pain	Elevated	LVEF >50%	Abnormal	Unknown	Unknown	Recovered
Patel et al., 2021 [57]	USA	5 cases mean age 23.2 years	All of them were male	BNT162b2 in 4 cases and mRNA-1273 in 1 case	2nd in 4 cases and 1st in 1 case	Mean 2.2 days	Chest pain, dyspnea, nausea, headache and chills	Elevated in all cases	LVEF >50% in all cases	Abnormal in all cases	Colchicine, Ibuprofen and aspirin	Mean 1.8 days	Recovered
Kim et al., 2021 [58]	Korea	29 years	Male	BNT162b2	2nd	1 day	Chest pain	Elevated	LVEF >50%	Normal	corticosteroids and NSAIDs.	7 days	Recovered
Ehrlich et al., 2021 [59]	Germany	40 years	Male	BNT162b2	1st	6 days	chest pain and shortness of breath, and fever	Elevated	LVEF <50%	Abnormal	Aspirin, heparin, beta-blocker and a mineralocorticoid antagonist	2 days	Recovered
Schmitt et al., 2021 [60]	France	19 years	Male	BNT162b2	2nd	3 days	Chest pain and dyspnea	Elevated	LVEF >50%	Abnormal	Unknown	1 day	Recovered
Kadwalwala et al., 2021 [61]	USA	38 years	Male	mRNA-1273	1st	2 days	Chest pain, fatigue and fever	Elevated	LVEF <50%	Abnormal	Methylprednisolone, lisinopril, and spironolactone	6 days	Recovered
Azir et al., 2021 [62]	USA	17 years	Male	BNT162b2	2nd	1 day	Chest pain	Elevated	LVEF >50%	Abnormal	aspirin and sublingual nitroglycerin	1 day	Recovered
Gabriel Amir et al., 2022 [63]	Israel	15 cases mean age 17.03 years	All of them were male	BNT162b2 in all cases	2nd in 14 cases and 1st in 1 case	Median 4.7 days	Chest pain and fever	Elevated in all cases	LVEF >50% in 12 cases LVEF <50% in 3 case	Abnormal in 14 cases and normal in 1 case	NSAIDs, colchicine, aspirin	Mean 5 days	Recovered
Ahmed SK 2022 [64]	Iraq	7 cases mean age 24.5 years	All of them were male	BNT162b2 in 5 cases and mRNA-1273 in 2 cases	2nd in all cases	Median 2.14 days	Chest pain, fever, fatigue, SOB	Elevated in all cases	LVEF >50% in 6 cases LVEF <50% in 1 case	Abnormal in all cases	colchicine and NSAIDs	Mean 2.4 days	Recovered
Mateusz Puchalski et al., 2022 [21]	Poland	5 cases mean age 16.6 years	All of them were male	BNT162b2 in all cases	2nd in 2 cases and 1st in 3 cases	Median 6.4 days	Chest pain, fever, shoulder pain	Elevated in all cases	LVEF >50% in all cases	Abnormal in all cases	ACEI	Mean 12.3 days	Recovered
Carolyn M. Rosner et al., 2022 [65]	USA	7 cases mean age 29.14 years	All of them were male	BNT162b2 in 4 cases and mRNA-1273 in 2 cases and J&J in 1 case	2nd in all cases	Median 3 days	Chest pain, SOB	Elevated in all cases	LVEF >50% in all cases	Abnormal in 6 cases and normal in 1 case	NA	NA	Recovered
Agata Łażniak-Pfajfer et al., 2022 [66]	Poland	3 cases mean age 17 years	All of them were male	BNT162b2 in all cases	2nd in 1 case and 1st in 2 cases	NA	Chest pain	Elevated in all cases	LVEF >50% in all cases	Abnormal in 1 case and normal in 2 cases	NA	NA	Recovered
	Japan						Chest pain				Colchicine, NAIADS		Recovered

Yoshiki Murakami et al., 2022 [67]		2 cases mean age 32.5	All of them were male	BNT162b2 in all cases	2nd in 1 case and 1st in 1 case	Median 6.5 days		Elevated in all cases	LVEF >50% in all cases	Abnormal in 1 case and normal in 1 case		Mean 5.5 days	
Farah Naghashzadeh et al., 2022 [68]	Iran	1 case 29years	Female	rAd26 and rAd5 (Sputnik V vaccine)	2nd	2 days	Chet pain	Elevated	LVEF <50%	Abnormal	methylprednisolone, prednisolone, and mycophenolate mofetil	7 days	Recovered
Chan-Hee Lee et al., 2022 [69]	South Korea	1 case 22 years	Male	mRNA-1273	2nd	5 days	Chest pain	Elevated	LVEF >50%	Abnormal	NAIADs	5 days	Recovered
Xavier Fosch et al., 2022 [70]	Spain	24 years	Male	BNT162b2	3rd	2 days	Chest pain	Elevated	LVEF >50%	Abnormal	NAIADs, colchicine	NA	Recovered
Daniel A. Gomes et al., 2022 [71]	Portugal	32 years	Male	mRNA-1273	2nd	2 days	Chest pain	Elevated	NA	Abnormal	NA	NA	Recovered
Eduardo Terán Brage et al., 2022 [72]	Spain	62 years	Female	mRNA-1273	3rd	1 day	Fever	Elevated	LVEF >50%	Abnormal	NSAIDs and colchicine	3 days	Recovered
Arman Sharbatdaran et al., 2022 [73]	USA	25 years	Male	mRNA-1273	2nd	3 days	shortness of breath, headache, fever, and sweating	Elevated	NA	Abnormal	Colchicine, aspirin	5 days	Recovered
Julia Moosmann et al., 2022 [74]	New Zealand	2 cases mean age 13 years	Male	BNT162b2 in all cases	2nd in all cases	Median 2.5 days	Chest pain	Elevated in all cases	LVEF >50%	Abnormal in all cases	NA	Median 7.5 days	Recovered
Carlotta Sciacaluga et al., 2022 [75]	Italy	2 cases men age 20.5 years	All of them were male	mRNA-1273	2nd in all cases	Median 3 days	Chest pain	Elevated in all cases	LVEF >50% in all cases	Abnormal in all cases	beta-blockers, antagonists, NSAIDs	Median 9 days	Recovered
Arianne Clare C. Agdamag et al., 2022 [76]	USA	80 years	Female	BNT162b2	1st	12 days	nausea, emesis, and diarrhoea.	Elevated	LVEF <50%	Abnormal	Methylprednisolone, metoprolol succinate, spironolactone	14 days	Recovered
Samuel Nunn et al., 2022 [77]	Germany	4 cases mean age 29.5 years	3 cases were male and 1 case were female	BNT162b2 in 3 cases and mRNA-1273 in 1 case	2nd in 3 cases and 1st in 1 case	Median 7.5 days	Chest pain,	Elevated in all cases	LVEF >50% in all cases	Abnormal in all cases	NA	Median 3 days	Recovered
Kanak Parmar et al., 2022 [78]	USA	4 cases mean age 29 years	3 cases were male and 1 case were female	mRNA-1273 in all cases	2nd in 3 cases and 1st in 1 case	Median 4 days	Chest pain	Elevated in all cases	LVEF >50% in all cases	Abnormal in 3 cases and normal in 1 case	Methylprednisolone	Median 7.5 days	Recovered
Mohammad Dlewati et al., 2022 [79]	USA	48 years	Male	mRNA-1273	2nd	2 days	Chest pain	Elevated	LVEF <50%	Abnormal	Metoprolol succinate, ramipril, atorvastatin	2 days	Recovered
Nobuko Kojima et al., 2022 [80]	Japan	17 years	Male	BNT162b2	2nd	2 days	Chest pain	Elevated	LVEF >50%	Abnormal	Aspirin, colchicine	23 days	Recovered
Katie A. Sharff et al., 2022 [81]	USA	6 cases mean age 28.8 years	4 cases were male and 2 cases were female	BNT162b2 in 5 cases and J&J in 1 case	3rd in 5 cases and 2nd in 1 case	Median 5.6 days	Chest pain	Elevated in 5 cases and normal in 1 case	LVEF >50% in 5 cases and LVEF <50% in 1 case	Abnormal in all cases	NA	Median 1.5 days	NA
Suresh Babu Chellapandian et al., 2022 [82]	Turkey	22 years	Male	mRNA-1273	2nd	2 days	Chest pain	Elevated	NA	Normal	colchicine	2 days	Recovered
Arthur Shiyovich et al., 2022 [19]	Israel	4 cases mean 31 years	3 cases were male and 1 case were female	BNT162b2 in all cases	3rd in all cases	Median 5.7 days	Chest pain	Elevated in all cases	LVEF >50% in all cases	Abnormal in 3 cases and normal in 1 case	NA	NA	Recovered

Table 2

Summary of pooled data from included research papers have been reported in the literature (n = 218).

Age	Median age - 29.23 years
Gender (n) %	Male - 201 (92.2%) Female - 17 (7.8%)
Type of COVID-19 vaccine (n) %	Pfizer-BioNTech (BNT162b2) - 158 (72.4%) Moderna COVID-19 Vaccine (mRNA-1273) - 52 (23.8%) Janssen (Johnson & Johnson) (Ad26.COV2. S) - 4 (1.8%) Oxford, AstraZeneca COVID-19 vaccine ChAdOx1 nCoV-19 - 2 (0.9%) Sinovac COVID-19 vaccine inactivated - 1 (0.4%) rAd26 and rAd5 (Sputnik V vaccine) - 1 (0.4%)
Dose (n) %	First dose - 28 (12.8%) Second dose - 179 (82.1%) Third dose - 11 (5.1%)
Days to symptom onset	Median 3.57 days
Symptoms (n) %	Chest pain - 216 (99.1%) Fever - 69 (31.6%) Myalgia/body aches - 80 (36.6%) Shortness of breath - 19 (8.7%)
Troponin level (n) %	Elevated - 215 (98.6%) Not elevated - 2 (0.9%) Unknown - 1 (0.4%)
LVEF (n) %	LVEF >50% - 169 (77.5%) LVEF <50% - 47 (21.5%) Unknown - 2 (0.9%)
Electrocardiogram (ECG) (n) %	Abnormal - 193 (88.5%) Normal - 25 (11.5%)
Length of hospital stay (days)	Median 5.8 days in 182 patients Unknown in 36 patients
Outcome (n) %	Recovered - 202 (92.6%) Under follow-up - 7 (3.2%) Unknown - 7 (2.7%) Died - 3 (1.4%)

Oster et al. (2022) [12] concluded that the risk of myocarditis after the mRNA vaccine was increased after the second dose in adolescents and young males. This finding is matched with Patone (2022) [14], who mentioned the risk of myocarditis increased within a week of receiving the first dose of both adenovirus and mRNA vaccines and after the second dose of mRNA vaccine. On the other hand, Simone et al. (2021) [16] concluded no relationship between COVID-19 mRNA vaccination and post vaccination myocarditis.

The findings extend these observations, including the median onset of symptoms after vaccine administration was 3.5 days. The most common symptoms are chest pain, followed by myalgia/body aches and fever. These findings matched with Pillay et al. (2021) [15], who reported in a systematic review that most myocarditis cases had a short symptoms onset of 2–4 days after a second dose, and the majority presented with chest pain. These findings matched with Oster et al. (2022) [12], who mentioned myocarditis was diagnosed within days of vaccination.

The diagnosis is often established by heart biopsy in patients with severe myocarditis. In patients with mild myocarditis, the diagnosis is based on compatible clinical findings and confirmed by elevated levels of blood markers or an electrocardiogram (ECG) indicative of cardiac injury, with new abnormalities on echocardiography or cardiac MRI [17].

Cardiac-specific investigations revealed that troponin levels were elevated in almost all cases, consistent with myocardial injury, which is associated with autoimmune processes matched with vaccine protein and the case immune system.

In the same lines as Lee et al. (2022) [1], a systematic review to investigate myocarditis following COVID-19 Vaccination in October 2020–October 2021, mentions that all reported cases have an elevated troponin level in keeping with myocardial injury.

In our study, less than one third of cases had left ventricle ejection fraction (LVEF) was less than 50%. Compared to patients

with COVID-19 illness, patients with vaccine associated myocarditis had a higher LVEF%.

This finding is consistent with Fronza et al. (2022) [18], who investigated myocardial injury patterns at MRI in COVID-19 Vaccine and discovered that more than half of the cases had more than 50% LVEF. Also, Shiyovich et al. (2022) [19], who analyzed myocarditis following the third (Booster) dose of COVID-19 vaccination, found that the mean left ventricular ejection fraction was $61 \pm 7\%$ (range 53–71%). Regional wall motion abnormalities were present in one of the patients only. Global T1 values were increased in one (25%) of the patients, while focal values were increased in 3 (75%) of the patients, Global T2 values were raised in one (25%) of the patients, while focal values were increased in all of the patients (100%). Global ECV was increased in 3 (75%) of the patients, while focal ECV was increased in all the patients (100%). LGE was present in all the patients.

In our systematic review and meta-analysis study, 88.5% of patients had abnormal changes in the electrocardiogram (ECG) result, regardless of the vaccine type.

Vidula et al. (2021) [20] support our findings by reporting two patients with clinically suspected myocarditis who presented with acute substernal chest pain and/or dyspnea after receiving the second dose of the vaccine and were found to have diffuse ST elevations on electrocardiogram (ECG), elevated cardiac biomarkers and inflammatory markers, and mildly reduced left ventricular (LV) function on echocardiography.

Also, Puchalski et al. [21] reported the findings of a case series regarding COVID-19-Vaccination-Induced Myocarditis in Teenagers. Electrocardiogram (ECG) patterns varied, but characteristic features of acute myocardial injury, including ST segment elevation or depression, and repolarization time abnormalities, were present in all cases.

Management of myocarditis remains mainly supportive and is based on restoring hemodynamic stability and the administration

of guideline-directed heart failure and arrhythmia treatment. According to our findings, all cases were treated with NSAIDs, beta-blockers, calcium channel blockers, and diuretics. Patients with preserved ventricular function and non-severe features were often treated with colchicine or non-steroidal anti-inflammatory drugs. The median length of hospital stay was 5.28 days in 182 patients, and the vast majority of patients resolved symptoms and recovered, and only 3 patients died.

This finding broadly supports the work of other studies in this area. Woo et al. [22] reported that many patients who received anti-inflammatory agents such as NSAIDs, colchicine, steroids, and intravenous immunoglobulin recovered without further medical treatment, with a hospital stay lasting 3–6 days.

In accordance with the present results, previous studies have demonstrated that almost all of the cases experienced a prompt recovery with no residual cardiac dysfunction. The median length of stay for all myocarditis cases was around 2–3 days, with a range of 2–10 days [23].

5. Conclusion

In conclusion, these findings may help public health policy consider myocarditis in the context of the benefits of COVID-19 vaccination and assess the cardiac condition before the choice of vaccine, which is offered to male adults. In addition, it must be carefully weighed against the very substantial benefit of vaccination. Moreover, further research is required to assess the long-term consequences and other risk factors following immunization, specifically the mRNA vaccines.

Funding

This research did not receive any specific grant from funding agencies in the public, commercial, or not-for-profit sectors.

Author agreement statement

We declare that this manuscript is original, has not been published before, and is not currently being considered for publication elsewhere. We confirm that the manuscript has been read and approved by all named authors and that there are no other persons who satisfied the criteria for authorship but are not listed. We confirm that all have agreed with the order of authors listed in our manuscript. We understand that the Corresponding Author is the sole contact for the Editorial process. He is responsible for communicating with the other authors about progress, submissions of revisions, and final approval of proofs.

Data availability statement

All relevant data are within the manuscript and its supporting information files.

Authors' contributions

Conception and design SKA acquisition of data SKA, RAE, MGM, EAA analysis and interpretation of data SKA, MGM, RAE, EEA, drafting of the manuscript SKA, RAE, MGM, EAA critical revision of the manuscript for important intellectual content statistical analysis SKA, MGM, RAE, EEA, PKI, AAK, ZHW administrative SKA, technical SKA, PKI, AAK, ZHW, supervision SKA, and all authors approving the final draft.

Provenance and peer review

Not commissioned, externally peer-reviewed.

Declaration of competing interest

There is no conflict to be declared.

Acknowledgments

Not applicable.

Appendix A. Supplementary data

Supplementary data to this article can be found online at <https://doi.org/10.1016/j.dsx.2022.102513>.

References

- [1] Lee ASY, Iswaree DD, Balakrishnan O, Khoo CY, Ng CT, Loh JKK, et al. Myocarditis following COVID-19 vaccination: a systematic review (october 2020–october 2021). *Heart Lung Circ* 2022:S1443–9506. <https://doi.org/10.1016/j.hlc.2022.02.002>.
- [2] Bozkurt B, Kamat I, Hotez PJ. Myocarditis with COVID-19 mRNA vaccines. *Circulation* 2021;144:471–84.
- [3] Page MJ, McKenzie JE, Bossuyt PM, Boutron I, Hoffmann TC, Mulrow CD, et al. The PRISMA 2020 statement: an updated guideline for reporting systematic reviews. *Int J Surg* 2021;88:105906. <https://doi.org/10.1016/j.ijsu.2021.105906>.
- [4] Shea BJ, Reeves BC, Wells G, Thuku M, Hamel C, Moran J, et al. Amstar 2: a critical appraisal tool for systematic reviews that include randomised or non-randomised studies of healthcare interventions, or both. *BMJ* 2017;358.
- [5] Uzzani M, Hammady H, Fedorowicz Z, Elmagarmid A. Rayyan—a web and mobile app for systematic reviews. *Syst Rev* 2016;5:1–10.
- [6] Moola S, Munn Z, Tufanaru C, Aromataris E, Sears K, Sfetcu R, et al. Chapter 7: systematic reviews of etiology and risk, vol. 5. *Joanna Briggs Inst Rev Manual Joanna Briggs Inst*; 2017. <https://synthesismanual.jbi.global/>.
- [7] Fatima M, Cheema HA, Khan MHA, Shahid H, Ali MS, Hassan U, et al. Development of myocarditis and pericarditis after COVID-19 vaccination in adult population: a systematic review. *Ann Med Surg* 2022:103486.
- [8] Pollack A, Kontorovich AR, Fuster V, Dec GW. Viral myocarditis—diagnosis, treatment options, and current controversies. *Nat Rev Cardiol* 2015;12:670–80.
- [9] Su JR. Myopericarditis following COVID-19 vaccination: updates from the vaccine adverse event reporting system. *VAERS*; 2021.
- [10] Montgomery J, Ryan M, Engler R, Hoffman D, McClenathan B, Collins L, et al. Myocarditis following immunization with mRNA COVID-19 vaccines in members of the US military. *JAMA Cardiol* 2021;6:1202–6.
- [11] Fairweather D, Cooper Jr LT, Blauwet LA. Sex and gender differences in myocarditis and dilated cardiomyopathy. *Curr Probl Cardiol* 2013;38:7–46.
- [12] Oster ME, Shay DK, Su JR, Gee J, Creech CB, Broder KR, et al. Myocarditis cases reported after mRNA-based COVID-19 vaccination in the US from december 2020 to august 2021. *JAMA* 2022;327:331–40.
- [13] Kytö V, Sipilä J, Rautava P. The effects of gender and age on occurrence of clinically suspected myocarditis in adulthood. *Heart* 2013;99:1681–4.
- [14] Patone M, Mei XW, Handunnetthi L, Dixon S, Zaccardi F, Shankar-Hari M, et al. Risks of myocarditis, pericarditis, and cardiac arrhythmias associated with COVID-19 vaccination or SARS-CoV-2 infection. *Nat Med* 2021;1–13.
- [15] Pillay J, Bialy L, Gaudet L, Wingert A, Mackie A, Paterson DI, et al. Myocarditis and pericarditis following COVID-19 vaccination: rapid systematic review of incidence, risk factors, and clinical course. *medRxiv* 2021.
- [16] Simone A, Herald J, Chen A, Gulati N, Shen AY-J, Lewin B, et al. Acute myocarditis following COVID-19 mRNA vaccination in adults aged 18 years or older. *JAMA Intern Med* 2021;181:1668–70.
- [17] Heymans S, Cooper LT. Myocarditis after COVID-19 mRNA vaccination: clinical observations and potential mechanisms. *Nat Rev Cardiol* 2021:1–3.
- [18] Fronza M, Thavendiranathan P, Chan V, Karur GR, Udell JA, Wald RM, et al. Myocardial injury pattern at MRI in COVID-19 vaccine-associated myocarditis. *Radiology* 2022:212559.
- [19] Shiyovich A, Witberg G, Aviv Y, Kornowski R, Hamdan A. A case series of myocarditis following third (booster) dose of COVID-19 vaccination: magnetic resonance imaging study. *Front Cardiovasc Med* 2022:9.
- [20] Vidula MK, Ambrose M, Glassberg H, Chokshi N, Chen T, Ferrari VA, et al. Myocarditis and other cardiovascular complications of the mRNA-based COVID-19 vaccines. *Cureus* 2021:13.
- [21] Puchalski M, Kamińska H, Bartoszek M, Brzewski M, Werner B. COVID-19-Vaccination-Induced myocarditis in teenagers: case series with further follow-up. *Int J Environ Res Publ Health* 2022;19:3456.
- [22] Woo W, Kim AY, Yon DK, Lee SW, Hwang J, Jacob L, et al. Clinical

- characteristics and prognostic factors of myocarditis associated with the mRNA COVID-19 vaccine. *J Med Virol* 2021.
- [23] Almas T, Rehman S, Mansour E, Khedro T, Alansari A, Malik J, et al. Epidemiology, clinical ramifications, and cellular pathogenesis of COVID-19 mRNA-vaccination-induced adverse cardiovascular outcomes: a state-of-the-heart review. *Biomed Pharmacother* 2022;149:112843.
- [24] Mouch SA, Roguin A, Hellou E, Ishai A, Shoshan U, Mahamid L, et al. Myocarditis following COVID-19 mRNA vaccination. *Vaccine* 2021;39:3790–3.
- [25] Marshall M, Ferguson ID, Lewis P, Jaggi P, Gagliardo C, Collins JS, et al. Symptomatic acute myocarditis in 7 adolescents after Pfizer-BioNTech COVID-19 vaccination. *Pediatrics* 2021:148.
- [26] D'Angelo T, Cattafi A, Carej ML, Booz C, Ascenti G, Cicero G, et al. Myocarditis after SARS-CoV-2 vaccination: a vaccine-induced reaction? *Can J Cardiol* 2021;37:1665–7.
- [27] Nassar M, Nso N, Gonzalez C, Lakhdar S, Alshamam M, Elshafey M, et al. COVID-19 vaccine-induced myocarditis: case report with literature review. *Diabetes Metabol Syndr* 2021;15:102205.
- [28] Kim HW, Jenista ER, Wendell DC, Azevedo CF, Campbell MJ, Darty SN, et al. Patients with acute myocarditis following mRNA COVID-19 vaccination. *JAMA Cardiol* 2021;6:1196–201.
- [29] Verma AK, Lavine KJ, Lin C-Y. Myocarditis after covid-19 mRNA vaccination. *N Engl J Med* 2021;385:1332–4.
- [30] Rosner CM, Genovese L, Tehrani BN, Atkins M, Bakhshi H, Chaudhri S, et al. Myocarditis temporally associated with COVID-19 vaccination. *Circulation* 2021;144:502–5.
- [31] Dionne A, Sperotto F, Chamberlain S, Baker AL, Powell AJ, Prakash A, et al. Association of myocarditis with BNT162b2 messenger RNA COVID-19 vaccine in a case series of children. *JAMA Cardiol* 2021;6:1446–50.
- [32] García B, Ortega P, Ja BF, León C, Burgos R, Dorta C. Acute myocarditis after administration of the BNT162b2 vaccine against COVID-19. *Rev Esp Cardiol* 2021;74:812–4.
- [33] Dickey JB, Albert E, Badr M, Laraja KM, Sena LM, Gerson DS, et al. A series of patients with myocarditis following SARS-CoV-2 vaccination with mRNA-1279 and BNT162b2. *Cardiovasc Imaging* 2021;14:1862–3.
- [34] Tano E, San Martin S, Girgis S, Martinez-Fernandez Y, Sanchez Vegas C. Perimyocarditis in adolescents after Pfizer-BioNTech COVID-19 vaccine. *J Pediatric Infect Dis Soc* 2021;10:962–6.
- [35] Larson KF, Ammirati E, Adler ED, Cooper Jr LT, Hong KN, Saponara G, et al. Myocarditis after BNT162b2 and mRNA-1273 vaccination. *Circulation* 2021;144:506–8.
- [36] Deb A, Abdelmalek J, Iwuji K, Nugent K. Acute myocardial injury following COVID-19 vaccination: a case report and review of current evidence from vaccine adverse events reporting system database. *J Prim Care Community Health* 2021;12:2150132711029230.
- [37] Abbate A, Gavin J, Madanchi N, Kim C, Shah PR, Klein K, et al. Fulminant myocarditis and systemic hyperinflammation temporally associated with BNT162b2 mRNA COVID-19 vaccination in two patients. *Int J Cardiol* 2021;340:119–21.
- [38] Muthukumar A, Narasimhan M, Li Q-Z, Mahimainathan L, Hitto I, Fuda F, et al. In-depth evaluation of a case of presumed myocarditis after the second dose of COVID-19 mRNA vaccine. *Circulation* 2021;144:487–98.
- [39] Isaak A, Feisst A, Luetkens JA. Myocarditis following COVID-19 vaccination. *Radiology* 2021;301:E378–9.
- [40] Cereda A, Conca C, Barbieri L, Ferrante G, Tumminello G, Lucreziotti S, et al. Acute myocarditis after the second dose of SARS-CoV-2 vaccine: serendipity or atypical causal relationship? *Anatol J Cardiol* 2021;25:522.
- [41] Watkins K, Griffin G, Septaric K, Simon EL. Myocarditis after BNT162b2 vaccination in a healthy male. *Am J Emerg Med* 2021;50:815–e1.
- [42] Chamling B, Vehof V, Drakos S, Weil M, Stalling P, Vahlhaus C, et al. Occurrence of acute infarct-like myocarditis following COVID-19 vaccination: just an accidental co-incidence or rather vaccination-associated autoimmune myocarditis? *Clin Res Cardiol* 2021;110:1850–4.
- [43] Mansour J, Short RG, Bhalla S, Woodard PK, Verma A, Robinson X, et al. Acute myocarditis after a second dose of the mRNA COVID-19 vaccine: a report of two cases. *Clin Imag* 2021;78:247–9.
- [44] Levin D, Shimon G, Fadlon-Derai M, Gershovitz L, Shovali A, Sebbag A, et al. Myocarditis following COVID-19 vaccination—a case series. *Vaccine* 2021;39:6195–200.
- [45] Schauer J, Buddha S, Colyer J, Sagiv E, Law Y, Chikkabyrappa SM, et al. Myopericarditis after the Pfizer messenger ribonucleic acid coronavirus disease vaccine in adolescents. *J Pediatr* 2021;238:317–20.
- [46] Shumkova M, Vassilev D, Karamfiloff K, Ivanova R, Stoyanova K, Yaneva-Sirakova T, et al. Acute myocarditis associated with the Pfizer/BioNTech vaccine. *Kardiol Pol* 2021;79:1282–3.
- [47] Minocha PK, Better D, Singh RK, Hoque T. Recurrence of acute myocarditis temporally associated with receipt of the mRNA coronavirus disease 2019 (COVID-19) vaccine in a male adolescent. *J Pediatr* 2021;238:321–3.
- [48] Hasnie AA, Hasnie UA, Patel N, Aziz MU, Xie M, Lloyd SG, et al. Perimyocarditis following first dose of the mRNA-1273 SARS-CoV-2 (Moderna) vaccine in a healthy young male: a case report. *BMC Cardiovasc Disord* 2021;21:1–6.
- [49] Starekova J, Bluemke DA, Bradham WS, Grist TM, Schiebler ML, Reeder SB. Myocarditis associated with mRNA COVID-19 vaccination. *Radiology* 2021;301:E409–11.
- [50] Koizumi T, Awaya T, Yoshioka K, Kitano S, Hayama H, Amemiya K, et al. Myocarditis after COVID-19 mRNA vaccines. *QJM An Int J Med* 2021;114:741–3.
- [51] McLean K, Johnson TJ. Myopericarditis in a previously healthy adolescent male following COVID-19 vaccination: a case report. *Acad Emerg Med* 2021;28:918–21.
- [52] Riedel PG, Sakai VF, Toniasso S de CC, Brum MCB, Fernandes FS, Pereira RM, et al. Heart failure secondary to myocarditis after SARS-CoV-2 reinfection: a case report. *Int J Infect Dis* 2021;113:175–7.
- [53] In-Cheol K, Hyungseop K, Jeong LH, Yoon KJ, Jin-Young K. Cardiac imaging of acute myocarditis following COVID-19 mRNA vaccination. *J Kor Med Sci* 2021;36:1–6.
- [54] Nguyen TD, Mall G, Westphal JG, Weingärtner O, Möbius-Winkler S, Schulze PC. Acute myocarditis after COVID-19 vaccination with mRNA-1273 in a patient with former SARS-CoV-2 infection. *ESC Hear Fail*; 2021.
- [55] Azdaki N, Farzad M. Long QT interval and syncope after a single dose of COVID-19 vaccination: a case report. *Pan Afr Med J* 2021:40.
- [56] Sokolska JM, Kurcz J, Kosmala W. Every rose has its thorns—acute myocarditis following COVID-19 vaccination. *Kardiol Pol* 2021;79:1153–4.
- [57] Patel YR, Louis DW, Atalay M, Agarwal S, Shah NR. Cardiovascular magnetic resonance findings in young adult patients with acute myocarditis following mRNA COVID-19 vaccination: a case series. *J Cardiovasc Magn Reson* 2021;23:1–8.
- [58] Kim D, Choi JH, Jang JY, So O, Cho E, Choi H, et al. A case report for myopericarditis after BNT162b2 COVID-19 mRNA vaccination in a Korean young male. *J Kor Med Sci* 2021:36.
- [59] Ehrlich P, Klingel K, Ohlmann-Knafo S, Hüttinger S, Sood N, Pickuth D, et al. Biopsy-proven lymphocytic myocarditis following first mRNA COVID-19 vaccination in a 40-year-old male: case report. *Clin Res Cardiol* 2021;110:1855–9.
- [60] Schmitt P, Demoulin R, Poyet R, Capilla E, Rohel G, Pons F, et al. Acute Myocarditis after COVID-19 vaccination: a case report. *Rev Med Interne* 2021;42:797–800.
- [61] Kadwalwala M, Chadha B, Ortoleva J, Joyce M. Multimodality imaging and histopathology in a young man presenting with fulminant lymphocytic myocarditis and cardiogenic shock after mRNA-1273 vaccination. *BMJ Case Reports CP* 2021;14:e246059.
- [62] Azir M, Inman B, Webb J, Tannenbaum L. STEMI mimic: focal myocarditis in an adolescent patient After mRNA COVID-19 vaccine. *J Emerg Med* 2021;61:e129–32.
- [63] Amir G, Rotstein A, Razon Y, Beyersdorf GB, Barak, Corren Y, Godfrey ME, et al. CMR imaging 6 months after myocarditis associated with the BNT162b2 mRNA COVID-19 vaccine. *Pediatr Cardiol* 2022:1–8.
- [64] Ahmed SK. Myocarditis after BNT162b2 and mRNA-1273 COVID-19 vaccination: a report of 7 cases. *Ann Med Surg* 2022:103657.
- [65] Rosner CM, Atkins M, Saeed IM, de Lemos JA, Khera A, Maghsoudi A, et al. Patients with myocarditis associated with COVID-19 vaccination. *J Am Coll Cardiol* 2022;79:1317–9.
- [66] Łażniak-Pfajfer A, Surmacz R, Rajewska-Tabor J, Pyda M, Lesiak M, Bobkowski W. Myocarditis associated with COVID-19 vaccination in three teenage males. *Pol Arch Intern Med* 2021.
- [67] Murakami Y, Shinohara M, Oka Y, Wada R, Noike R, Ohara H, et al. Myocarditis following a COVID-19 messenger RNA vaccination: a Japanese case series. *Intern Med* 2022:8721–31.
- [68] Naghashzadeh F, Shafaghi S, Dorudinia A, Naji SA, Marjani M, Amin A, et al. Myocarditis following rAd26 and rAd5 vector-based COVID-19 vaccine: case report. *ESC Hear Fail* 2022;9:1483–6.
- [69] Lee C-H, Kong E-J. FDG PET/MRI of acute myocarditis after mRNA COVID-19 vaccination. *Clin Nucl Med* 2022;47:e421–2.
- [70] Fosch X, Serra J, Torres PL, Preda L, González R, Mojer F. In: Acute myocarditis after a third dose of the BNT162b2 COVID-19 vaccine. *Rev Española Cardiol (English);* 2022.
- [71] Gomes DA, Santos RR, Freitas P, Paiva MS, Ferreira J, Trabulo M. Acute myocarditis following mRNA COVID-19 vaccine. *Arq Bras Cardiol* 2022;118:787–8.
- [72] Brage Et, Ruiz JR, Martín JG, Rodríguez JDO, Tocino RV, Rodríguez-Diego S, et al. Fulminant myocarditis IN a patient with a lung adenocarcinoma after the third dose OF modern COVID-19 vaccine. A case report and literature review. *Curr Probl Cancer Case Reports* 2022;6:100153.
- [73] Sharbatdaran A, Chahal Y, Moleai M, Bhavsar D. A rare case of COVID-19 vaccine-induced myopericarditis in a young adult. *Radiol Case Reports* 2022;17:1916–20.
- [74] Moosmann J, Gentles T, Occlshaw C, Mitchelson B. COVID vaccine-associated myocarditis in adolescent siblings: does it run in the family? *Vaccines* 2022;10:611.
- [75] Sciacaluga C, D'Ascenzi F, Cameli M, Gallotta M, Menci D, Antonelli G, et al. Case report: two case reports of acute myopericarditis after mRNA COVID-19 vaccine. *Front Cardiovasc Med* 2022;9:827237.
- [76] Agdamag ACC, Gonzalez D, Carlson K, Koney S, McDonald WC, Martin CM, et al. Fulminant myocarditis following coronavirus disease 2019 vaccination: a case report. *Eur Hear Journal-Case Reports* 2022;6:ytac007.
- [77] Nunn S, Kersten J, Tadic M, Wolf A, Gonska B, Hüll E, et al. Case report: myocarditis after COVID-19 vaccination—case series and literature review. *Front Med* 2022;9:836620.
- [78] Parmar K, Mekraksakit P, Del Rio-Pertuz G, Sethi P, Motes A, Hughes M, et al. Myocarditis following COVID-19 mRNA vaccination. In: *Baylor univ med cent*

- proc, vol. 35. Taylor & Francis; 2022. p. 209–13.
- [79] Dlewati M, Park K, Rawat S, Conte J, Bhadha K. COVID-19 mRNA vaccine-associated myocarditis presenting as STEMI in a 48-year-old male. *Case Reports Cardiol* 2022;2022.
- [80] Kojima N, Tada H, Okada H, Yoshida S, Sakata K, Usui S, et al. Case report: myocarditis associated with COVID-19 mRNA vaccination following myocarditis associated with *Campylobacter jejuni*. *Front Cardiovasc Med* 2022;9:837759.
- [81] Sharff KA, Dancoes DM, Longueil JL, Lewis PF, Johnson ES. Myopericarditis after COVID-19 booster dose vaccination. *Am J Cardiol* 2022.
- [82] Chellapandian SB, Turkmen S, Salim I, Chinnakaruppan S, Mohammad J. Myocarditis following COVID-19 mRNA (mRNA-1273) vaccination. *Clin Case Reports* 2022;10:e05741.