

A Cross-Sectional Study of Nailfold Capillary Changes in Psoriasis

Abstract

Background: Microcirculation in the skin of psoriasis patients significantly differs from unaffected individuals. Vascular changes precede skin lesions and occur even in nonlesional skin. **Aims:** The primary aim of this work was to study the nailfold capillary changes in psoriasis patients, and to compare it with that of controls. The secondary aim of this work was to compare the nailfold capillary changes in psoriasis patients with and without nail changes. **Methods:** A comparative cross-sectional study of 40 psoriasis patients and 40 age and sex-matched controls analyzed the capillaries of the proximal nailfold of all fingers using a dermoscope. The mean capillary loop density/mm, tortuous capillaries, capillary hemorrhages, and avascular areas were assessed. **Results:** The mean nailfold capillary loop density in psoriasis (6.98 ± 0.54 per mm) was significantly less than that in controls (8.01 ± 0.61 per mm) ($P < 0.001$). Avascular areas in the nailfold of psoriasis patients (55%) were significantly more than the same in controls (22.5%) ($P = 0.003$). Of 40 psoriasis patients, 26 had nail psoriasis. Of this, 19 (73%) had avascular areas ($P = 0.002$). No significant association of nailfold capillary density or avascular areas with disease duration or severity was noted. An increase in tortuous capillaries and nailfold hemorrhages noted in psoriasis was not significant. **Limitations:** Small sample size, not having participants with psoriatic arthropathy, and lack of information on capillary diameter and capillary changes in hyponychium were the limitations. **Conclusion:** The reduced mean capillary loop density, and higher frequency of avascular areas noted in cases compared to controls, points to a pathogenic role for microvascular damage in psoriasis. Whether the lack of association of these changes with disease duration and severity suggests the possibility of these being early disease markers for psoriasis, needs further analysis in larger prospective studies.

Keywords: Capillary density, dermoscopy, microscopic angioscopy, nailfold capillaroscopy, psoriasis

Introduction

Vascular changes constitute a significant factor in the pathogenesis of psoriasis. Although most studies suggest a primary role for the immune system in psoriasis pathogenesis, it has been argued that vascular change precedes the immune response.^[1]

Nailfold capillaroscopy is widely used in evaluation of collagen vascular diseases. But there exists limited data on nailfold capillaroscopy in psoriasis, and the available studies give conflicting information.

Methods

We performed a comparative cross-sectional study on the first 40 patients with a clinical diagnosis of psoriasis, and 40 age- and gender-matched controls who

attended the dermatology department from January 1, 2015. Controls were selected from individuals who have never been diagnosed with psoriasis.

We excluded patients with other coexisting conditions causing nailfold capillary and microvascular abnormalities, such as connective tissue disorders, diabetes mellitus, hypertension or any other microvascular disorders, pregnant patients, fingers that sustained trauma including manicure within the past 2 weeks, and those below 18 and above 65 years.^[2-4] Institutional ethics committee approved the study.

The sample size calculated based on the standard deviation (SD) of the mean score for capillary density (0.8) in a similar study was 40 each in cases and controls.^[5]

This is an open access journal, and articles are distributed under the terms of the Creative Commons Attribution-NonCommercial-ShareAlike 4.0 License, which allows others to remix, tweak, and build upon the work non-commercially, as long as appropriate credit is given and the new creations are licensed under the identical terms.

For reprints contact: WKHLRPMedknow_reprints@wolterskluwer.com

How to cite this article: Santhosh P, Riyaz N, Bagde P, Binitha MP, Sasidharanpillai S. A cross-sectional study of nailfold capillary changes in psoriasis. Indian Dermatol Online J 2021;12:873-8.

Received: 28-Sep-2020. **Revised:** 04-Mar-2021.
Accepted: 23-Apr-2021. **Published:** 22-Nov-2021.

Parvathy Santhosh,
Najeeba Riyaz¹,
Pranaya Bagde²,
Manikoth P.
Binitha³,
Sarita
Sasidharanpillai³

Department of Dermatology,
Malabar Medical College
Hospital and Research Centre,
Kozhikode, Kerala, ¹Department
of Dermatology, KMCT
Medical College, Kozhikode,
Kerala, ²Hair O Craft Hair
Transplantation Centre,
Kochi, Kerala, ³Department of
Dermatology and Venereology,
Government Medical College,
Kozhikode, Kerala, India

Address for correspondence:

Dr. Parvathy Santhosh,
Department of Dermatology,
Malabar Medical College
Hospital and Research Centre,
Kozhikode, Kerala, India.
E-mail: drparvathysanthosh@
gmail.com

Access this article online

Website: www.idoj.in

DOI: 10.4103/idoj.IDOJ_793_20

Quick Response Code:



Methodology

After obtaining informed written consent from individual study participants, we collected data (with a preset proforma) on age, gender, onset, and duration of illness, treatment taken, and other coexistent diseases. We conducted a detailed clinical and dermatological examination including nail changes. Based on Psoriasis Area and Severity Index (PASI) score, patients were classified into mild (PASI <10), moderate (PASI 10-20), and severe (PASI >20) disease.

The subjects were asked to avoid smoking and caffeine for 6 hours before the examination. They were made to sit comfortably at an ambient room temperature for 15 min, and then subjected to a detailed nailfold capillaroscopy, performed with the hands placed on a flat surface. Nailfold capillary abnormalities were studied using a dermoscope (Ultracam TLS by DermaIndia) under polarized light, after application of linkage fluid, and photographed. All fingers of both hands were studied. The parameters assessed included mean capillary loop density per millimeter, presence of tortuous capillaries, capillary hemorrhages, and avascular areas in the posterior nailfold. Mean capillary loop density was calculated as the number of capillaries in 1 mm length using the calibration software of the dermoscope after examining all fingers. An inter-capillary distance of more than 0.5 mm was taken as an avascular area.^[3] Tortuous capillaries and capillary hemorrhages were evaluated based on visual assessment. The data collected were entered in a preset proforma. Images were subsequently coded and stored.

Data analysis

The data were tabulated using Microsoft Excel and analyzed by using the Statistical Packages for the Social Sciences (SPSS) software program, version 18.0. Quantitative variables were expressed as mean \pm SD. Qualitative variables were expressed as frequency or percentages. Statistical tests employed included Chi-square test, independent samples *t* test, and ANOVA (analysis of variance). A value of $P < 0.05$ was considered statistically significant.

Results

Among patients, there were 23 men and 17 women. The mean age of the patients was 44.3 ± 10.97 years. Majority belonged to the 46–60 years' age group (17, 42.5%). The most common type of psoriasis was chronic plaque psoriasis (23, 57.5%), followed by erythrodermic (nine, 22.5%), pustular (six, 15%), and guttate psoriasis (two, 5%). Approximately 65% (26/40) of psoriasis patients had associated nail changes. Majority (19, 47.5%) of patients had mild disease based on PASI score.

Capillary loop density

The mean capillary loop density of cases was 6.98 ± 0.49 per mm, whereas that of controls was 8.01 ± 0.61 per mm,

which was statistically significant ($P < 0.001$) [Table 1]. Though statistically not significant, the mean capillary loop density in men with psoriasis (6.92 ± 0.52 per mm) was less than that of women (7.06 ± 0.43 per mm). No significant association was found between mean capillary loop density and age or disease severity. The mean capillary loop density was lowest in erythrodermic psoriasis. No significant difference was noted in the mean capillary loop density between different clinical types of psoriasis [Tables 1 and 2].

Avascular areas

Avascular areas were present in the nailfold of 55% (22/40) of the patients and 22.5% (9/40) of controls [Figures 1–5]. This was statistically significant ($P = 0.003$) [Table 1]. A statistically significant female predilection for avascular areas was observed in the cases ($P < 0.001$), which was not reflected in the controls. We noted avascular areas in the nailfold in 73.1% (19/26) of patients with nail psoriasis, and in 21.4% (3/14) of those without nail psoriasis. A significant association was noted between the presence of avascular areas and the presence of nail changes ($P = 0.002$). Presence of avascular areas did not show any significant association with age, clinical type of psoriasis, disease duration, or severity [Tables 1 and 3].

Tortuous capillaries

Tortuous capillaries were present in 25% (10/40) of cases and 17.5% (7/40) of controls, which was not significant [Table 1 and Figures 6 and 7]. Among cases, tortuous capillaries were present in the nailfold of 5.9% (1/17) women and 39.1% (9/23) of men. This was statistically significant ($P = 0.02$). Among controls, tortuous

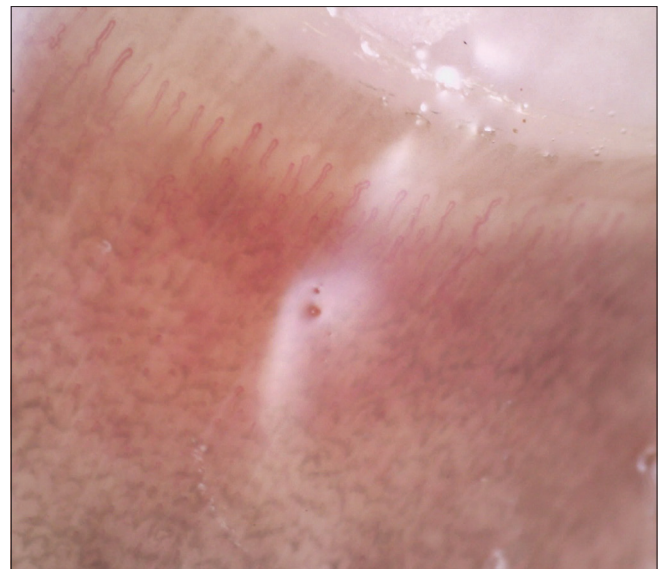


Figure 1: Capillaries of posterior nailfold, viewed at a lower magnification, giving a global view of capillary distribution and morphology. Shows regularly arranged capillaries with a hair pin shape. (Nailfold capillaroscopy using Ultracam TLS dermoscope, polarized light, with linkage fluid, contact dermoscopy, 75 \times magnification)

Table 1: Nailfold capillaroscopy findings in cases and controls

Study participants	Mean capillary loop density per mm	Avascular areas (n, %)	Tortuous capillaries (n, %)	Capillary hemorrhages (n, %)
Cases (n=40)	6.986±0.546	22 (55%)	10 (25%)	6 (15%)
Controls (n=40)	8.017±0.627	9 (22.5%)	7 (17.5%)	2 (5%)
P value	<0.001	0.003	0.412	0.316

Table 2: Mean capillary loop density in posterior nailfold in patients with psoriasis

Study participants (N=40)	Mean capillary loop density per millimetres
Parameter assessed	Number of patients (% of total)
Age group in years (P=0.80)	
<30	6 (15%)
31-45	14 (35%)
46-60	17 (42.5%)
>60	3 (7.5%)
Gender (P=0.335)	
Male	23 (58%)
Female	17 (42%)
Duration of disease (P=0.50)	
<10 years	18 (45%)
10-20 years	19 (47.5%)
>20 years	3 (7.5%)
Clinical type of psoriasis (P=0.787)	
Chronic plaque	23 (57.5%)
Erythrodermic	9 (22.5%)
Guttate	2 (5%)
Pustular	6 (15%)
Psoriasis area severity index (P=0.102)	
<10 (mild)	19 (47.5%)
10-20 (moderate)	12 (30%)
>20 (severe)	9 (22.5%)
Nail changes due to psoriasis (P=0.084)	
Present	26 (65%)
Absent	14 (35%)

capillaries were noted in 17.6% (3/17) of women and 17.4% (4/23) of men. The difference was not significant. No significant association was noted between tortuous capillaries and type, duration, or severity of psoriasis or presence of nail changes.

Capillary hemorrhages

Capillary hemorrhages were present in 15% (6/40) of patients and 5% (2/40) of controls. This was not significant [Table 1]. Although a higher number of men (5/23, 21.7%) had nailfold capillary hemorrhages compared to women (1/16, 5.9%), this was not significant. This male predilection was not reflected in the control



Figure 2: Capillaries of posterior nailfold, viewed at a higher magnification (Nailfold capillaroscopy using Ultracam TLS dermoscope, polarized light, with linkage fluid, contact dermoscopy, 150× magnification)

group. There was no significant association between capillary hemorrhages and disease duration, severity, clinical type, or presence of nail psoriasis.

Discussion

We observed a statistically significant decrease in mean nailfold capillary loop density in psoriasis patients compared to controls, which was consistent with previous studies.^[5-7] However, Iorizzo *et al.*^[8] have observed an increase in capillary loop density in hyponychium in patients with nail bed psoriasis, akin to findings in psoriatic skin lesions.^[9]

No association was recorded between mean capillary loop density and age of the patients this study, which could be attributed to the exclusion of those aged below 18 and above 65 years. We excluded patients with extremes of age, as previous authors have observed age to be a confounding factor in nailfold capillary changes.^[4,10] The lower mean capillary loop density observed in male patients compared to female patients was reflected in the control population as well in our study, which indicates that gender difference in mean capillary loop density in psoriasis may not be associated with the disease process.

Though statistically not significant, mean capillary loop density was lower in patients with more severe disease. Previous studies give conflicting results on this aspect.^[5,8]

Our finding of lower mean capillary loop density (statistically not significant) in patients with nail changes of psoriasis compared to those without nail involvement mirrored the observation of others.^[5,11]

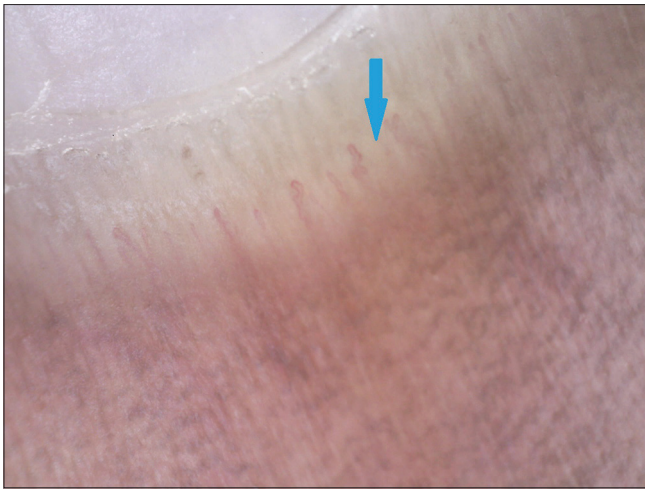


Figure 3: Reduced capillary density, with presence of avascular areas in posterior nailfold (Nailfold capillaroscopy using Ultracam TLS dermoscope, polarized light with linkage fluid, contact dermoscopy, 75× magnification) (Blue arrow indicates avascular area)

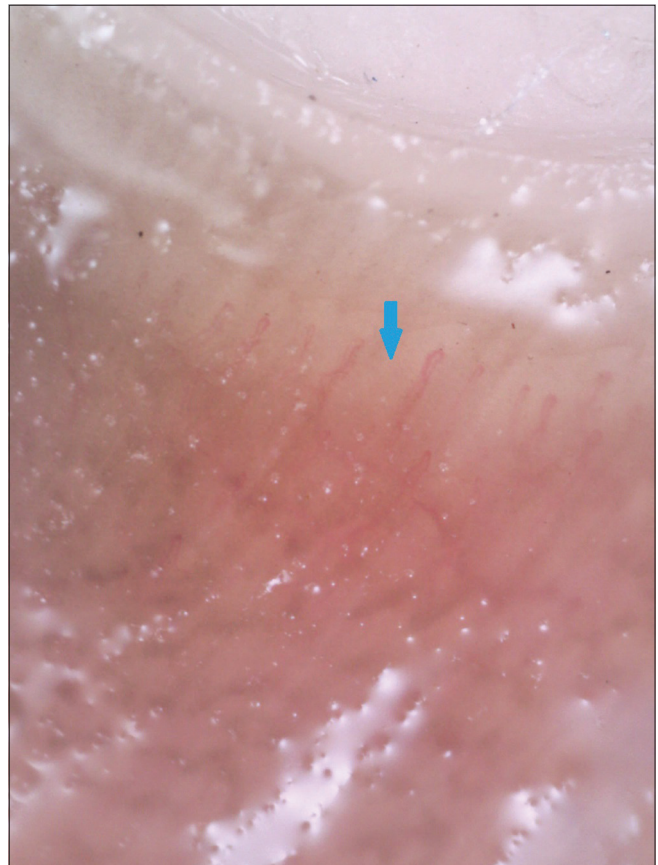

Figure 4: Avascular areas in posterior nailfold viewed at higher magnification (Nailfold capillaroscopy using Ultracam TLS dermoscope, polarized light, with linkage fluid, contact dermoscopy, 150x magnification) (Blue arrow indicates avascular area)

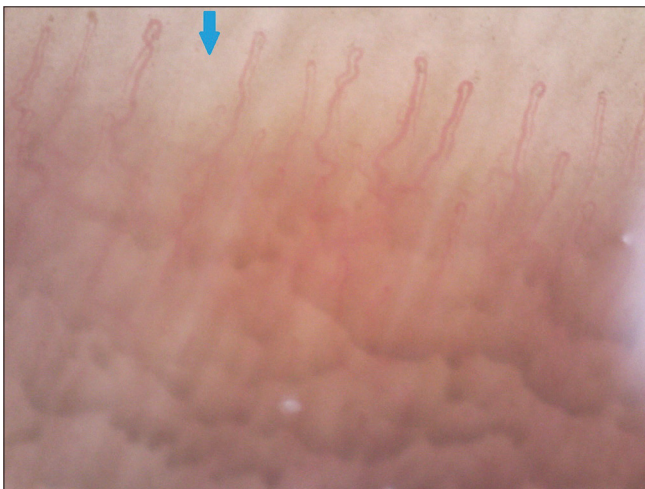

Figure 5: Avascular areas in posterior nailfold viewed at higher magnification (Nailfold capillaroscopy using Ultracam TLS dermoscope, polarized light, with linkage fluid, contact dermoscopy, 150× magnification) (Blue arrow indicates avascular area)

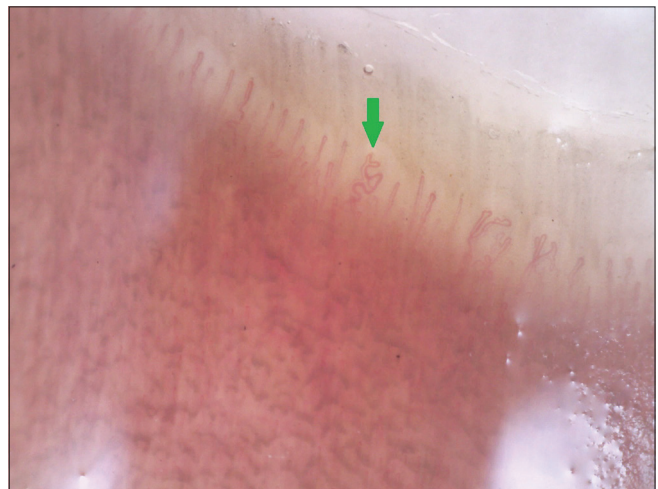


Figure 6: Tortuous capillary loop in posterior nailfold viewed at lower magnification (Nailfold capillaroscopy using Ultracam TLS dermoscope, polarized light, with linkage fluid, contact dermoscopy, 75× magnification) (Green arrow indicates tortuous capillary loop)

The significant association between avascular areas and psoriasis (more frequent in nail psoriasis) documented by us, was as reported earlier.^[5] This is attributed to the presence of trophic disturbances in the periungual region of patients.^[11] Levels of angiogenic factors like transforming growth factor beta (TGF- β), platelet-derived growth factor (PDGF), and vascular endothelial growth factor (VEGF) have been found to be raised in psoriasis, which can significantly alter the morphology and physiology of the microcirculation, and may have a role in nailfold capillary changes.^[5,12,13] Zaric *et al.*^[7] have observed sluggishness of blood flow in the nailfold capillaries of psoriasis patients. The lack of association between the presence of avascular areas and the disease duration, and the statistically significant association observed between avascular areas and nail psoriasis in this study were concordant with literature.^[5]

The lack of significant association between presence of tortuous nailfold capillaries and psoriasis noted by us was comparable to one previous study, but was discordant to the observation of certain others.^[6,8,11,14] Our finding of 25% of patients with psoriasis showing tortuous

Table 3: Avascular areas in posterior nailfold in patients with psoriasis

Study participants (N=40)		Avascular areas present (number)
Parameter assessed	Number of patients (% of total)	
Age group in years $P=0.44$		
<30	6 (15%)	3
31-45	14 (35%)	7
46-60	17 (42.5%)	9
>60	3 (7.5%)	3
Gender $P < 0.001$		
Male	23 (58%)	11
Female	17 (42%)	11
Duration of disease $P=0.476$		
<10 years	18 (45%)	8
10-20 years	19 (47.5%)	12
>20 years	3 (7.5%)	2
Clinical type of psoriasis $P=0.296$		
Chronic plaque	23 (57.5%)	10
Erythrodermic	9 (22.5%)	1
Guttate	2 (5%)	5
Pustular	6 (15%)	6
Psoriasis area severity index $P=0.070$		
<10 (mild)	19 (47.5%)	7
10-20 (moderate)	12 (30%)	8
>20 (severe)	9 (22.5%)	7
Nail changes due to psoriasis $P=0.002$		
Present	26 (65%)	19
Absent	14 (35%)	3

capillaries, fell between the reported frequencies in two previous studies (17.3% and 54.3%).^[5,15] We did not come across any previous study reporting a male predilection for presence of tortuous capillaries in psoriasis as documented by us. Grassi *et al.*^[16] stated that tortuosity has limited diagnostic value but may indicate angiogenesis in some diseases.

Though we noted a higher percentage of cases manifesting capillary hemorrhages than controls, this was not significant. Previous authors had conflicting findings.^[7,11]

Whether the lack of association between nailfold capillary changes and disease duration and severity observed by us is a reflection of the mentioned changes being markers of early disease, needs to be analyzed in prospective studies with large sample sizes.

Limitations

Small sample size, inability to study the nailfold capillary changes in patients with psoriatic arthropathy (since none of the study participants manifested psoriatic arthropathy) and lack of information on capillary diameter and capillary changes in the hyponychium were the limitations.

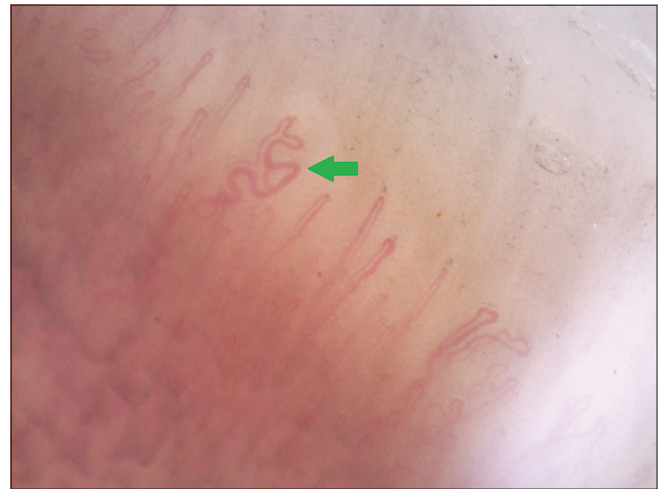

Figure 7: Tortuous capillary loop in posterior nailfold viewed at higher magnification (Nailfold capillaroscopy using Ultracam TLS dermoscope, polarized light, with linkage fluid, contact dermoscopy, 150x magnification) (Green arrow indicates tortuous capillary loop)

Conclusion

Mean nailfold capillary loop density in psoriasis patients is reduced, irrespective of age, gender, duration, or severity of disease. Nailfold capillaries of psoriasis patients showed avascular areas, which was more frequent in those with nail psoriasis. Prospective studies with large sample sizes may give more information on whether nailfold capillary changes can be considered as early disease markers of psoriasis.

Declaration of patient consent

The authors certify that they have obtained all appropriate patient consent forms. In the form, the patients have given their consent for their images and other clinical information to be reported in the journal. The patients understand that name and initials will not be published and due efforts will be made to conceal identity, but anonymity cannot be guaranteed.

Financial support and sponsorship

Nil.

Conflicts of interest

There are no conflicts of interest.

References

1. Goodfield M, Hull SM, Holland D, Roberts G, Wood E, Reid S, *et al.* Investigations of the “active” edge of plaque psoriasis: Vascular proliferation precedes changes in epidermal keratin. *Br J Dermatol* 1994;131:808-13.
2. Chojnowski MM, Felis-Giemza A, Olesińska M. Capillaroscopy – A role in modern rheumatology. *Paper Reumatologia* 2016;54:67-72.
3. Etehad Tavakol M, Fatemi A, Karbalaie A, Emrani Z, Erlandsson BE. Nailfold capillaroscopy in rheumatic diseases: Which parameters should be evaluated? *Biomed Res Int* 2015;2015:974530.

4. Dolezalova P, Young SP, Bacon PA, Southwood TR. Nailfold capillary microscopy in healthy children and in childhood rheumatic diseases: A prospective single blind observational study. *Ann Rheum Dis* 2003;62:444-9.
5. Ribeiro CF, Siqueira EBD, Holler AP, Fabricio L, Skare TL. Periungual capillaroscopy in psoriasis. *An Bras Dermatol* 2012;87:550-3.
6. Salli L, Raymondi F, Pappalardo A. Periungual capillaroscopy in psoriatic arthritis. *Clin Ter* 1998;150:409-12.
7. Zaric D, Clemmensen OJ, Worm AM, Stahl D. Capillary microscopy of the nailfold in patients with psoriasis and psoriatic arthritis. *Dermatologica* 1982;164:10-4.
8. Iorizzo M, Dahdah M, Vincenzi C, Tosti A. Videodermoscopy of the hyponychium in nail bed psoriasis. *J Am Acad Dermatol* 2008;58:714-5.
9. De Angelis R, Bugatti L, Del Medico P, Nicolini M, Filosa G. Videocapillaroscopic findings in the microcirculation of the psoriatic plaque. *Dermatology* 2002;204:236-9.
10. Terreiri MTRA, Andrade LEC, Puccinelli ML, Hilário MOE, Goldenberg J. Nailfold capillaroscopy: Normal findings in children and adolescents. *Semin Arthritis Rheum* 1999;29:36-42.
11. Bhushan M, Moore T, Herrick AL, Griffiths CE. Nailfold video capillaroscopy in psoriasis. *Br J Dermatol* 2000;142:1171-6.
12. Veale DJ, Ritchlin C, Fitzgerald O. Immunopathology of psoriasis and psoriatic arthritis. *Ann Rheum Dis* 2005;64(Suppl 2):ii26-9.
13. Bressan AL, Gripp A, Oliveira EF, Silva RS. Síndrome de extravasamento capilar sistêmico. *An Bras Dermatol* 2011;86:593-5.
14. Bartosińska J, Chodorowska G. Original proposal of capillaroscopic images' classification in psoriasis vulgaris and psoriatic arthritis. *Post Dermatol Alergol* 2009;26:17-24.
15. Sivasankari M, Arora S, Vasdev V, Mary EM. Nailfold capillaroscopy in psoriasis. *Med J Armed Forces India* 2021;77:75-81.
16. Grassi W. Basic findings in capillaroscopy. In: Grassi W, Del Medico P, editors. *Atlas of Capillaroscopy*. 1st ed. Italy: EDRA; 2004. p. 10-25.