



Case Report

Spinal epidural arteriovenous fistula with improved sphincter impairment detected by intraoperative neurophysiological monitoring

Shogo Shima¹, Yasuko Tanaka², Shinsuke Sato¹, Yasunari Niimi¹

¹Department of Neurosurgery and Neuroendovascular Therapy, St. Luke's International Hospital, ²Department of Clinical Laboratory and Intraoperative Neurophysiology, St. Luke's International Hospital, Tokyo, Japan.

E-mail: *Shogo Shima - shisho@luke.ac.jp; Yasuko Tanaka - yasukoma@luke.ac.jp; Shinsuke Sato - satosh@luke.ac.jp; Yasunari Niimi - yasunm@luke.ac.jp

*Corresponding author:

Shogo Shima,
Department of Neurosurgery
and Neuroendovascular
Therapy, St. Luke's International
Hospital, Tokyo, Japan.

shisho@luke.ac.jp

Received : 01 July 2022

Accepted : 06 August 2022

Published : 26 August 2022

DOI

10.25259/SNI_592_2022

Quick Response Code:



ABSTRACT

Background: A spinal epidural arteriovenous fistula (SEAVF) is a rare type of arteriovenous shunt that occurs mainly in the thoracic or lumbar spine. Patients with SEAVF develop motor/sensory disturbances of the lower extremities and sphincter dysfunction. Among these symptoms, sphincter impairments show less improvement than others, and its relevance to neurophysiological monitoring has not been documented.

Case Description: A 77-year-old woman presented with progressive motor weakness and numbness in the lower extremities and urinary and fecal incontinence. Spinal magnetic resonance imaging showed spinal cord edema in Th5-Th11 and enlarged perimedullary veins. We performed spinal angiography and endovascular treatment under intraoperative neurophysiological monitoring (IOM), including sensory evoked potential (SEP), motor evoked potential (MEP), and bulbocavernosus reflex (BCR) monitoring. Diagnostic angiography revealed a SEAVF with perimedullary venous drainage fed by the left L2 segmental artery. The shunt was completely embolized using N-butyl-2-cyanoacrylate. Although SEP and MEP of the lower legs were recordable during treatment, anal MEP and BCR were not observed. The sphincter symptoms improved 1.5 years after the treatment. Follow-up angiography revealed no shunt recurrence and improved venous congestion. Anal MEP and BCR were detected during angiography, indicating neurophysiological improvement in sphincter function. The prolonged latency of the monitoring suggested a pudendal nerve injury.

Conclusion: This case report first described improvement of the IOM correlated with the functional recovery of sphincters after embolization of a SEAVF. Follow-up neurophysiological monitoring is important to assess the functional recovery of the sphincter.

Keywords: Endovascular treatment, Intraoperative neurophysiological monitoring, Sphincter impairment, Spinal epidural arteriovenous fistula

INTRODUCTION

Spinal epidural arteriovenous fistulas (SEAVFs) are relatively rare spinal vascular malformations that frequently occur in men aged >60 years and are known to be associated with prior trauma or surgical history.^{[7][8]} They are typically seen in the thoracic or lumbar spine, and the shunt points are mainly located in the ventral epidural space.^[8] SEAVFs primarily drain into the epidural venous plexus, which can cause cord compression or congestive myelopathy if intradural reflux

to perimedullary veins exists.^[10] Microsurgical resection or endovascular embolization is chosen based on the clinical condition and vascular anatomy of the lesion, and neurophysiological monitoring under general anesthesia is recommended for functional safety and treatment decision-making in both procedures.^[13] Intraoperative neurophysiological monitoring (IOM), which includes measurement of somatosensory evoked potentials (SEPs) and motor evoked potentials (MEPs) and bulbocavernosus reflex (BCR) monitoring, is useful for the assessment of functional integrity during endovascular treatment for spinal cord lesions.^[11,14] The importance and methodology of IOM are well-defined; however, the relevance of IOM results to sphincter impairments has not been documented. We report a case of lumbar SEAVF treated with endovascular therapy that showed improvement in sphincter impairment, which was correlated with improvements in anal MEPs and BCR.

CASE PRESENTATION

A 72-year-old woman with progressive symptoms of gait disturbance, constipation, and urinary incontinence for 1 year was referred to our hospital. She showed no medical or trauma history and was wheelchair-dependent due to lower-leg weakness. Physical examination revealed motor weakness, bilateral numbness of the lower extremities, and anal sphincter impairment. Her Aminoff-Logue scale gait, micturition, and bowel scores were 5, 2, and 2, respectively. Computed tomography revealed no significant brain abnormalities. Spinal magnetic resonance imaging (MRI) revealed diffuse spinal cord edema in Th5-Th11 and multiple flow voids on the back of the region, indicating venous congestion and perimedullary venous ectasia [Figure 1a]. The conus medullaris ended at the L1 vertebral level. We suspected spinal vascular malformations and performed spinal angiography followed by endovascular treatment under IOM.

Neurophysiological monitoring

A neurophysiological monitoring unit (Neuromaster MEE-1208; NIHON KOHDEN Corp. Tokyo, Japan) was used for IOM. All electrodes were inserted into the scalp according to the International 10-20 system for electroencephalography. SEPs were elicited by stimulation of the anterior tibial nerve at the ankle (intensity: 20–40 mA, duration: 0.2 ms, and repetition rate: 5.7 Hz) and recorded through needle electrodes inserted into the scalp at CZ'-FZ. MEPs were elicited by transcranial electrical stimulation using corkscrew-like electrodes placed on the scalp at C3-C4. Monophasic stimulation of five square-wave pulses (intensity, 550V; single pulse duration, 0.5 ms; interstimulus interval, 2 ms; and repetition rate, 2 Hz) was applied. MEPs of the lower extremities were recorded using needle

electrodes inserted into the abductor pollicis brevis, tibialis anterior, and abductor hallucis. Anal MEPs were recorded using electrodes inserted into the bilateral bulbospongiosus muscles. The stimulating electrode of the BCR was placed at the pubic symphysis, with the cathode on the dorsum of the clitoris and the anode on the labia majora. Short trains of five square-wave pulses (intensity, 40 mA; single pulse duration, 0.2 ms; interstimulus interval, 2 ms; and repetition rate, 2.7 Hz) were used to elicit BCR. Recordings of the evoked response of the BCR were performed using the same needle electrodes as the anal MEPs.

Endovascular treatment and IOM

All spinal angiography and treatments were performed under general anesthesia using propofol (4–10 mg/kg/h) and remifentanyl (0.25–0.5 µg/kg/min). Baseline monitoring was performed after induction of general anesthesia. All SEPs and MEPs were recorded, except the anal MEP and BCR at baseline. Diagnostic and treatment angiography was performed using a cobra-shaped 4-French catheter (Medikit, Tokyo, Japan) through the femoral artery access. The left Th8 segmental artery injection demonstrated delayed spinal venous drainage in the anterior spinal artery, while the left L2 segmental artery injection revealed a SEAVF with perimedullary venous drainage. The shunt was supplied from the left dorsal somatic branch through the retrocorporeal anastomosis and was located in the contralateral ventral epidural space with a venous pouch [Figures 1b and c]. Intradural venous reflux through the posterior spinal vein was observed from the lower edge of the venous pouch at the L2 vertebral level [Figure 1b]. No other feeders were detected in other segmental arteries. Endovascular embolization of the shunt was then performed. After placing the guiding catheter on the left L2 segmental artery, a 1.5-Fr flow-directed catheter (Marathon; Medtronic, Minneapolis, MN, USA) was advanced over a microwire (CHIKAI X 010; ASHI INTECC, Aichi, Japan) into the dorsal somatic branch. After confirming the absence of posterior spinal artery opacification, *N*-butyl-2-cyanoacrylate (NBCA) (Histoacryl; B. Braun, Melsungen, Germany) diluted with iodized oil (Lipiodol; Guerbet, Aulnay-sous-Bois, France) at 17% was injected from the microcatheter. The NBCA infiltrated the upper part of the venous pouch through the shunt point and control angiography revealed complete shunt obliteration [Figures 1d and e]. Anal MEP/BCR monitoring revealed no potential during the procedure and no changes in other MEPs and SEPs were observed after treatment [Figures 2a and b].

Clinical course

The post treatment clinical course was stable without complications and anticoagulant medication was initiated to prevent venous thrombosis. The patient was transferred to a

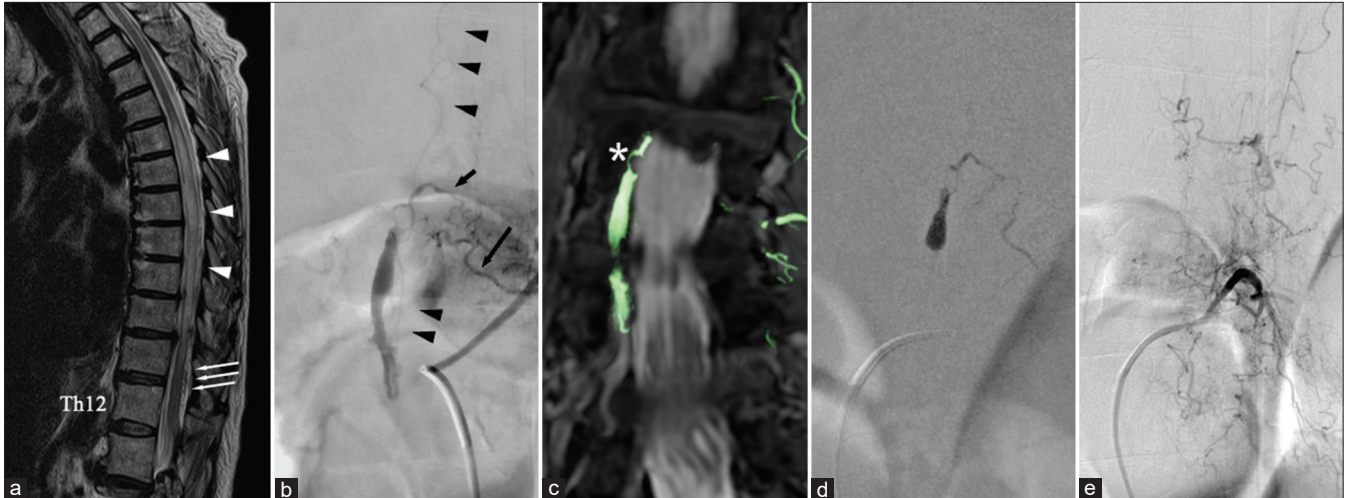


Figure 1: (a) Sagittal view of T2-weighted magnetic resonance imaging (MRI) of the spinal cord shows a diffuse high signal intensity from Th5 to Th11 (arrowheads) and multiple flow voids in the subarachnoid space (arrows). (b) Preoperative spinal angiography from the left L2 segmental artery reveals a spinal epidural fistula supplied from the dorsal somatic branch (long arrow) through retrocorporeal anastomosis (short arrow). The shunt forms a venous pouch and cranially drains through the posterior spinal vein (arrowheads). (c) The fusion image of MRI and maximum intensity projection shows the shunt point located in the lateral epidural space (asterisk). (d) NBCA injected from the microcatheter infiltrates into the shunt points and upper part of the venous pouch. (e) Postoperative angiography shows complete obliteration of the shunts with remnant venous congestion.

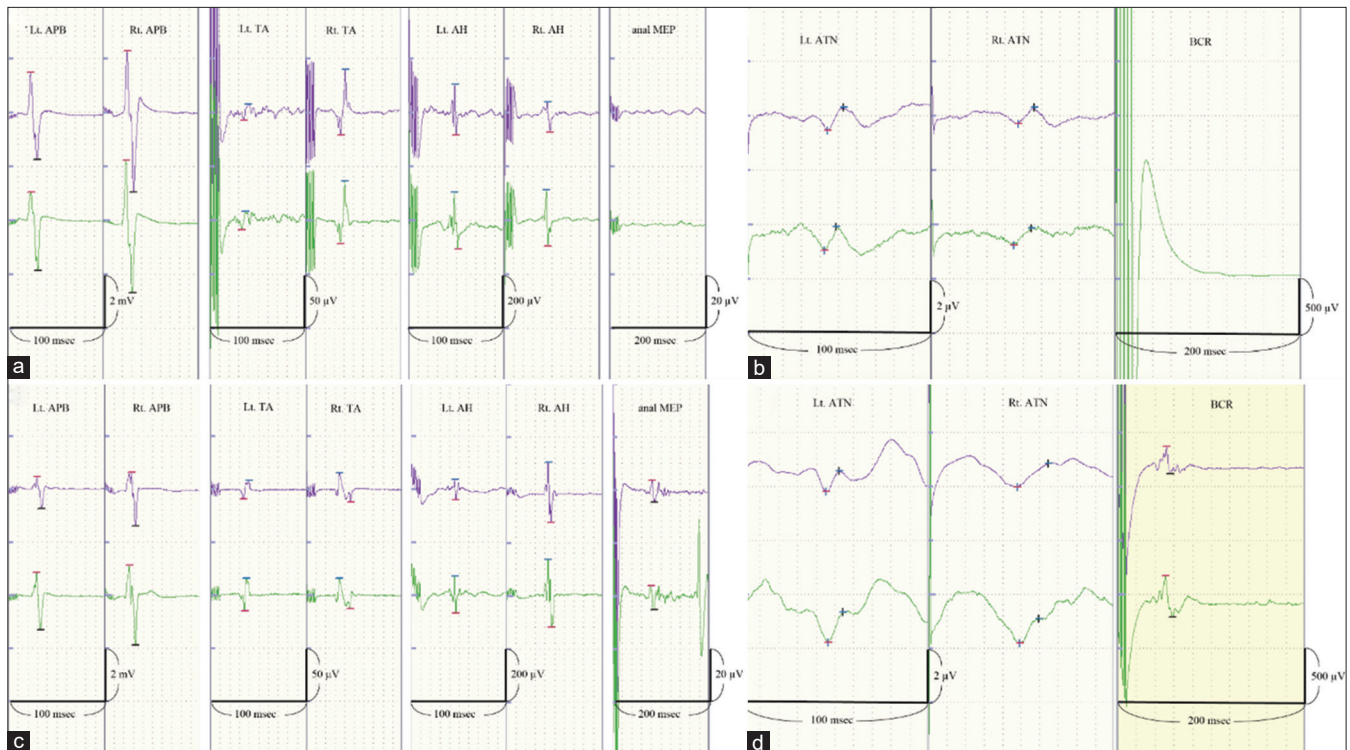


Figure 2: Potentials in the upper row show baseline records. Potentials in the lower row were recorded at the end of the procedures. (a) Motor evoked potentials (MEPs) from both lower extremities and the anal MEP were monitored at the first treatment. The amplitude and latency of the MEPs from the lower extremities were stable during the embolization of the shunt. The anal MEP was not recorded. (b) The bilateral anterior tibial nerve SEP at the first treatment shows no changes throughout the procedure. The BCR was not recordable throughout the procedure. (c) The anal MEP was observed at the 1.5-year follow-up angiography. The mean amplitude was 8.8 μ V, and the mean latency was approximately 80 ms. (d) The BCR was observed at the 1.5-year follow-up angiography. The mean amplitude was 294.9 μ V and the mean latency was approximately 50 ms. APB: Abductor pollicis brevis, TA: Tibialis anterior, AH: Abductor hallucis, MEP: Motor evoked potential, SEP: Somatosensory evoked potential, BCR: Bulbocavernosus reflex.

rehabilitation hospital with a modified Rankin scale score of 3. At the 3-month follow-up, the lower-extremity paraplegia had improved, but fecal and urinary disturbances remained unchanged. Spinal MRI showed the disappearance of flow voids and remnant thoracic cord edema. At 18 months after the treatment, she could walk with a walker, and constipation and urination improved. The Aminoff-Logue scale gait, micturition, and bowel scores were 4, 1, and 1. Anal MEP/BCR monitoring revealed potentials that were not observed during the follow-up angiography [Figures 2c and d; mean latencies and average amplitudes of anal MEP and BCR, approximately 60 ms and 50 ms and 9.5 μ V and 295 μ V, respectively]. The angiography showed persistent shunt occlusion and improved venous drainage of the spinal cord, while MRI confirmed a normal spinal cord without edema [Figures 3a and b].

DISCUSSION

IOM for spinal cord surgery was introduced in the 90s and has been applied to spinal endovascular treatment.^[3] Multimodality IOM is essential for preventing neurological complications during embolization of spinal cord vascular malformations.^[13,14] However, the correlation of improvement in IOM with sphincter function in patients with spinal vascular shunts has never been reported. This case report is the first to describe an IOM improvement associated with functional recovery in sphincter function after embolization of a SEAVF.

SEAVF is a rare spinal arteriovenous shunt, which has been lately defined and distinguished from spinal

dural arteriovenous fistula (SDAVF) through the recent neuroimaging and angiographic advances.^[1] This vascular lesion predominantly develops at the lumbar level as opposed to SDAVF, which more commonly occurs at the thoracic level.^[8] The shunt is located in the epidural space and usually forms a venous pouch with epidural or sometimes intradural venous drainage.^[1] On the basis of these anatomical and angiographic characteristics, the main clinical manifestations are spinal cord compression or congestive myelopathy, causing paraparesis, sensory disturbances, and sphincter dysfunction.^[8,15] This patient presented with flaccid weakness of the lower extremities, bladder atonia, and severe constipation, which is the so-called conus medullaris syndrome. The symptoms were derived from the angioarchitecture of the lesion. In the present case, the SEAVF had a venous pouch that extended longitudinally over the L2 and L3 vertebrae. The conus medullaris was at the L1 level and not compressed by the venous pouch. The drainage vein from the venous pouch flowed up at the L2 vertebral level. Bowel and micturition deficits are thought to occur because of congestive myelopathy rather than cord compression.

The symptoms of spinal vascular shunts, especially sensory and bowel disturbances, tend to be refractory to treatment.^[2] Our patient showed improvement in the lower-extremity motor weakness immediately after the treatment, while the bowel and urinary disturbances were unchanged. However, these sphincter impairments gradually recovered in concordance with improvements in spinal cord congestion on MRI and spinal angiography. Follow-up neurophysiological monitoring also showed improvement. In addition to MEPs and SEPs of the lower extremities, we monitored anal MEPs and BCR, which were not recorded just after the disappearance of the shunt by embolization, but were detected at the 1.5-year follow-up and associated with improved symptoms and image findings. The normal latency of MEPs from the external anal sphincter elicited by transcranial stimulation is approximately 19–21 ms,^[5] while the mean latency of this patient's anal MEPs was 80 ms. We also successfully recorded the BCR, which reflects the afferent and efferent reflex arcs of the spinal cord mediated by the pudendal nerve that originates from the neural cord segments S2, S3, and S4. These measurements are components of the conus medullaris that correspond to vertebral level L1 in the patient. Prolonged BCR latency is associated with a pudendal nerve injury in females, and a longer clinical course of nerve injury may extend this latency.^[12] The BCR latency in this patient (50 ms) was longer than the normative value, suggesting pudendal nerve injury^[4] and potentially reflecting the interval from onset to treatment. It is reported that myelopathy could damage spinal motor neurons with faster conduction velocity and affect the synapses between the corticospinal tract and spinal motor neurons.^[6] Venous congestion in the spinal cord may damage the efferent nerve fibers of the pudendal nerve.

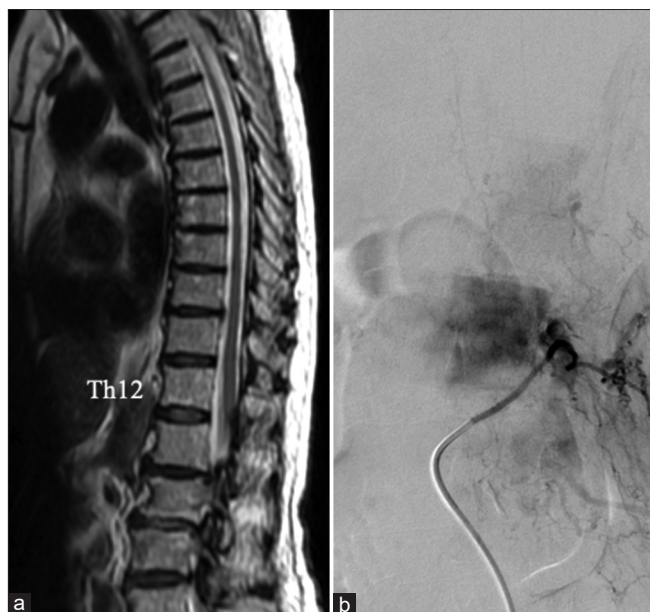


Figure 3: (a) The follow-up magnetic resonance imaging shows the disappearance of the spinal cord congestion. (b) The follow-up spinal angiography demonstrates no recurrence of the shunts and improved venous flow of the spinal cord.

IOM for spinal arteriovenous shunts can help prevent neurological complications and predict treatment outcomes.^[9,13] Furthermore, we propose its follow-up use to monitor the neurophysiological recovery of sphincters. Comparative evaluations of intraoperative and post treatment neurophysiological monitoring may reveal imperceptible changes in sphincter impairment. In the present case, the appearance of anal MEP and BCR with extended latencies correlated well with the partial clinical recovery of sphincters and implied residual damage to the pudendal nerve. Although more data are required to quantify the degree of nerve injury, we demonstrated that IOM could be an indicator for the functional recovery of pudendal nerve or sphincters.

CONCLUSION

We report a rare case of SEAVF treated with the endovascular approach in which improved sphincter impairment was detected by MEP/BCR monitoring. This case highlights the utility of follow-up neurophysiological monitoring to assess the functional recovery of the sphincter.

Declaration of patient consent

The authors certify that they have obtained all appropriate patient consent.

Financial support and sponsorship

Nil.

Conflicts of interest

There are no conflicts of interest.

REFERENCES

- Byun JS, Tsang AC, Hilditch CA, Nicholson P, Fang YB, Krings T, *et al.* Presentation and outcomes of patients with thoracic and lumbosacral spinal epidural arteriovenous fistulas: A systematic review and meta-analysis. *J Neurointerv Surg* 2019;11:95-8.
- Cenzato M, Debernardi A, Stefini R, D'Aliberti G, Piparo M, Talamonti G, *et al.* Spinal dural arteriovenous fistulas: Outcome and prognostic factors. *Neurosurg Focus* 2012;32:E11.
- Deletis V, Sala F. Intraoperative neurophysiological monitoring of the spinal cord during spinal cord and spine surgery: A review focus on the corticospinal tracts. *Clin Neurophysiol* 2008;119:248-64.
- Granata G, Padua L, Rossi F, De Franco P, Coraci D, Rossi V. Electrophysiological study of the bulbocavernosus reflex: Normative data. *Funct Neurol* 2013;28:293-5.
- Inoue S, Kawaguchi M, Takashi S, Kakimoto M, Sakamoto T, Kitaguchi K, *et al.* Intraoperative monitoring of myogenic motor-evoked potentials from the external anal sphincter muscle to transcranial electrical stimulation. *Spine (Phila Pa 1976)* 2002;27:E454-9.
- Kaneko K, Taguchi T, Morita H, Yonemura H, Fujimoto H, Kawai S. Mechanism of prolonged central motor conduction time in compressive cervical myelopathy. *Clin Neurophysiol* 2001;112:1035-40.
- Khalidi A, Hacein-Bey L, Origitano TC. Spinal epidural arteriovenous fistula with late onset perimedullary venous hypertension after lumbar surgery: Case report and discussion of the pathophysiology. *Spine (Phila Pa 1976)* 2009;34:E775-9.
- Kiyosue H, Matsumaru Y, Niimi Y, Takai K, Ishiguro T, Hiramatsu M, *et al.* Angiographic and clinical characteristics of thoracolumbar spinal epidural and dural arteriovenous fistulas. *Stroke* 2017;48:3215-22.
- Kothbauer K, Pryor JC, Berenstein A, Setton A, Deletis V. Motor evoked potentials predicting early recovery from paraparesis after embolisation of a spinal dural arteriovenous fistula. *Interv Neuroradiol* 1998;4:81-4.
- Mull M, Othman A, Dafotakis M, Hans FJ, Schubert GA, Jablawi F. Spinal epidural arteriovenous fistula with perimedullary venous reflux: Clinical and neuroradiologic features of an underestimated vascular disorder. *AJNR Am J Neuroradiol* 2018;39:2095-102.
- Niimi Y, Sala F, Deletis V, Berenstein A. Provocative testing for embolization of spinal cord AVMs. *Interv Neuroradiol* 2000;6 Suppl 1:191-4.
- Niu X, Wang X, Huang H, Ni P, Lin Y, Shao B. Bulbocavernosus reflex test for diagnosis of pudendal nerve injury in female patients with diabetic neurogenic bladder. *Aging Dis* 2016;7:715-20.
- Sala F, Beltramello A, Gerosa M. Neuroprotective role of neurophysiological monitoring during endovascular procedures in the brain and spinal cord. *Neurophysiol Clin* 2007;37:415-21.
- Sala F, Niimi Y, Berenstein A, Deletis V. Role of multimodality intraoperative neurophysiological monitoring during embolisation of a spinal cord arteriovenous malformation. A paradigmatic case. *Interv Neuroradiol* 2000;6:223-34.
- Silva N Jr, Januel AC, Tall P, Cognard C. Spinal epidural arteriovenous fistulas associated with progressive myelopathy. Report of four cases. *J Neurosurg Spine* 2007;6:552-8.

How to cite this article: Shima S, Tanaka Y, Sato S, Niimi Y. Spinal epidural arteriovenous fistula with improved sphincter impairment detected by intraoperative neurophysiological monitoring. *Surg Neurol Int* 2022;13:384.