

Open repair of type III endoleak with preservation of the endograft for a ruptured abdominal aortic aneurysm after endovascular aneurysm repair

Kirthi Bellamkonda, MSc, and Cassius Iyad Ochoa Chara, MD, MS, *New Haven, Conn*

ABSTRACT

Abdominal aortic aneurysm rupture after endovascular aneurysm repair (EVAR) is rare, but remains a significant limitation of endovascular technology. Preservation of the endograft during open conversion of a post-EVAR rupture has been shown to be associated with improved perioperative outcomes. An interposition Dacron graft with felt pledgets is a novel bail-out option for the open reconstruction of a type III endoleak with total endograft preservation. This technique is useful in high-risk patients presenting with ruptured abdominal aortic aneurysm after EVAR and no clear source of endoleak. (*J Vasc Surg Cases and Innovative Techniques* 2021;7:117-9.)

Keywords: Open conversion; EVAR; AAA rupture; Endoleak; Graft preservation

Abdominal aortic aneurysm (AAA) rupture after endovascular aneurysm repair (EVAR) is rare, but remains a significant limitation of endovascular technology. Most cases of late open conversion (OC) after EVAR involve partial or complete explantation of the endograft and require suprarenal or supraceliac aortic clamping.¹ Preservation of the endograft during OC has been shown to be associated with improved perioperative outcomes.² This case presents a novel bail-out open technique for the repair of ruptured AAA related to type III endoleak discovered intraoperatively with preservation of the endograft in an elderly patient.

The patient consented to the publication of these case details.

CASE REPORT

An 87-year-old man with a history of prior EVAR presented with an AAA rupture. He was hemodynamically stable on presentation. A computed tomography scan showed a large intraperitoneal hematoma anterior to a 9.6 cm AAA suggestive of contained rupture with no evidence of endoleak (Fig 1). He was highly functional, living independently, and had a history of hyperlipidemia and diabetes.

The patient had undergone EVAR for ruptured AAA 6 years prior at an outside hospital with a modular Gore Excluder device

(W. L. Gore & Associates, Flagstaff, Ariz). He subsequently developed a type Ia endoleak after a short period of time, and 9 Heli-FX staples (Medtronic, Santa Rosa, Calif) were placed circumferentially around the proximal graft neck. Postoperative angiography showed no endoleak, and subsequent follow-up showed continued sac shrinkage.

The patient was taken to the operating room. After angiography failed to demonstrate an endoleak, abdominal exploration was performed. The supraceliac aorta was dissected for proximal control. After evacuation of the hematoma, the AAA sac was opened and bleeding was encountered immediately between the iliac limb and the main body of the endograft, consistent with a type III endoleak. The supraceliac aorta was clamped. However, the patient's hemodynamic status became labile and tolerance of aortic cross-clamping was clearly poor. It was felt that he would not tolerate graft explantation. Next, the detached limb of the main body endograft and the iliac limb were clamped with a Fogarty Hydragrip clamp and the supraceliac control was released. There was no evidence of any type I or II endoleak and no bleeding was seen in the open aneurysm sac. A 14-mm interposition Dacron graft was anastomosed to the main body proximally and the iliac limb distally using 3-0 Prolene and strips of felt pledgets. The sac was imbricated over the repair.

The patient had an uneventful postoperative course. He was extubated on postoperative day 2 and discharged on postoperative day 15. At the 2-year follow-up, he remains asymptomatic with stable aneurysm size and no evidence of endoleak (Fig 2).

DISCUSSION

This case report presents a bail-out option for open repair of type III endoleak discovered intraoperatively during aneurysm sac exploration in an elderly patient who was a poor candidate for endograft explantation. Although most reinterventions after EVAR are endovascular, approximately 4% are late OCs. These pose a high morbidity (38%-55%) and high mortality (8.1%-18.0%).²⁻⁴ In particular, type III endoleaks seem to comprise 9% of the total cases undergoing OC, and can cause sudden

From the Division of Vascular Surgery and Endovascular Therapy, Yale School of Medicine.

Author conflict of interest: none.

Correspondence: Kirthi Bellamkonda, MSc, Division of Vascular Surgery and Endovascular Therapy, Yale School of Medicine, 333 Cedar St, New Haven, CT 06510 (e-mail: kirthi.bellamkonda@yale.edu).

The editors and reviewers of this article have no relevant financial relationships to disclose per the Journal policy that requires reviewers to decline review of any manuscript for which they may have a conflict of interest.

2468-4287

© 2021 The Authors. Published by Elsevier Inc. on behalf of Society for Vascular Surgery. This is an open access article under the CC BY-NC-ND license (<http://creativecommons.org/licenses/by-nc-nd/4.0/>).

<https://doi.org/10.1016/j.jvscit.2020.12.004>

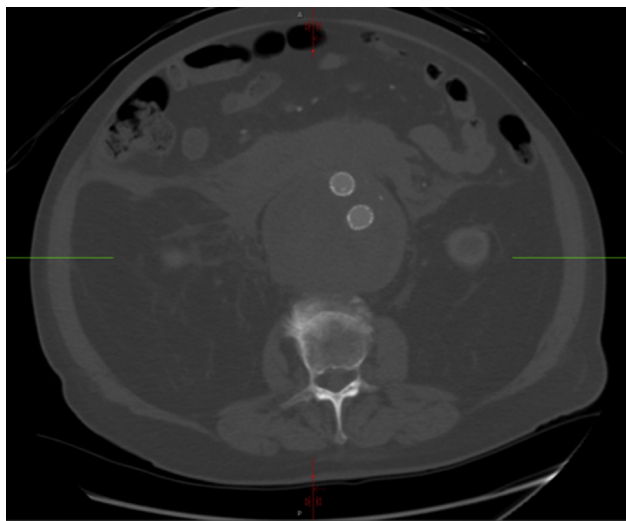


Fig 1. Preoperative computed tomography scan demonstrating a large hematoma.

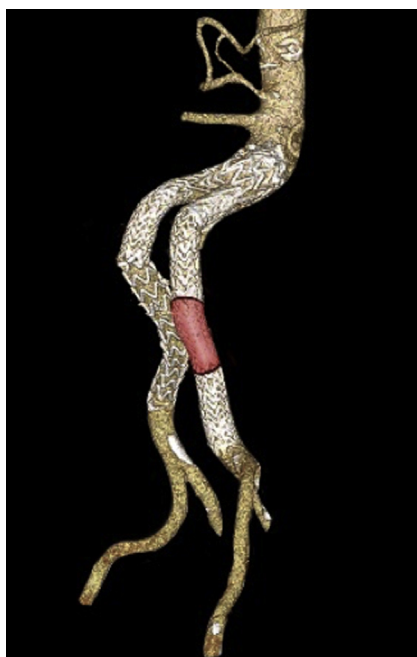


Fig 2. Postoperative computed tomography scan reconstruction demonstrating endograft with a Dacron interposition graft.

deterioration with rapid sac expansion.¹ In a study by Antoniou et al, type III endoleaks were the second leading cause of after EVAR rupture.^{5,6} Of type III endoleaks, modular disconnections are the more common type and are predisposed by short overlap between stent graft components (<10 mm), large AAA diameter, and high angulation at graft junctions causing separation along the greater curvature.⁷ Several endovascular and open options have been described for salvage with partial or complete explantation of the endograft.⁷⁻⁹

Endovascular treatment of type III endoleaks entails relining the endografts to provide enough coverage and seal between the main body and iliac limb. Graft relining is the preferred modality for a type III endoleak identified on preoperative imaging, because it does not require a laparotomy and may be performed quickly and without cross-clamping of the aorta. In this case, endovascular treatment was not performed given the uncertain source of endoleak and the complex vascular history of this patient including prior type I endoleak and use of endoanchors. Neither a preoperative computed tomography scan nor intraoperative angiography identified any endoleak. It is possible that the surrounding hematoma sealed the area of leak and, because the patient was relatively hypotensive, there was no additional extravasation of contrast. There was no lack of overlap that could be appreciated between the stent grafts.

Given the patient's presentation, the surgical team was prepared for explantation. However, the patient would not have tolerated that procedure. In retrospect, the patient did not require total explantation and inspection after clamping the disconnected limbs and releasing the supra-celiac cross clamp did not show evidence of flow in the aneurysm sac. In a study of late OC by Kouvelos et al,¹ the endograft was only totally preserved in 4.8% of cases, all of which were either type II endoleaks treated by vessel ligation with no disturbance of the main body, or type I endoleaks treated by neck bandings. In the 36 type III endoleaks described in the study, no endograft preservation was described. Cho et al¹⁰ describe several cases of partial explantation with proximal cuff preservation. However, explanting poses significant risk.^{2,11} Removal of the proximal perirenal endograft with barbs, hooks, and suprarenal stents can be challenging. In this case, the endostaples used caused severe periaortic inflammation and could have made explantation of the proximal portion unsafe.¹¹ Lyden et al¹² cautioned that distal limb removal could also be risky and requires abundant traction.

A Dacron-endograft anastomosis was described by Lipsitz; when possible, a native artery was incorporated into the suture line and the sac tightly imbricated over the whole complex to prevent any kinking of components.¹¹ Because this case involved an interposition graft, it was not possible to incorporate native artery, so pledgets were instead used to reinforce the suture line.

CONCLUSIONS

This case demonstrates a novel bail-out open treatment option with complete endograft preservation for a type III endoleak encountered during open abdominal exploration. An interposition Dacron graft with felt pledgets is a durable option for open reconstruction of a type III endoleak. This technique is useful in high-risk patients presenting with ruptured AAA after EVAR and no clear source of endoleak.

REFERENCES

1. Kouvelos G, Koutsoumpelis A, Lazaris A, Matsagkas M. Late open conversion after endovascular abdominal aortic aneurysm repair. *J Vasc Surg* 2015;61:1350-6.
2. Chaar CIO, Eid R, Park T, Rhee RY, Abu-Hamad G, Tzeng E, et al. Delayed open conversions after endovascular abdominal aortic aneurysm repair. *J Vasc Surg* 2012;55:1562-9.e1.
3. Mohapatra A, Robinson D, Malak O, Madigan MC, Avgerinos ED, Chaer RA, et al. Increasing use of open conversion for late complications after endovascular aortic aneurysm repair. *J Vasc Surg* 2019;69:1766-75.
4. Turney EJ, Steenberge SP, Lyden SP, Eagleton MJ, Srivastava SD, Sarac TP, et al. Late graft explants in endovascular aneurysm repair. *J Vasc Surg* 2014;59:886-93.
5. Harris PL, Vallabhaneni SR, Desgranges P, Becquemin J-P, van Marrewijk C, Laheij RJ, et al. Incidence and risk factors of late rupture, conversion, and death after endovascular repair of infrarenal aortic aneurysms: the EUROSTAR experience. *J Vasc Surg* 2000;32:739-49.
6. Antoniou GA, Georgiadis GS, Antoniou SA, Neequaye S, Brennan JA, Torella F, et al. Late rupture of abdominal aortic aneurysm after previous endovascular repair: a systematic review and meta-analysis. *J Endovasc Ther* 2015;22:734-44.
7. Skibba AA, Evans JR, Greenfield DT, Yoon HR, Katras T, Ouriel K, et al. Management of late main-body aortic endograft component uncoupling and type IIIa endoleak encountered with the Endologix Powerlink and AFX platforms. *J Vasc Surg* 2015;62:868-75.
8. Eng ML, Brewer MB, Rowe VL, Weaver FA. Treatment options for late type III endoleaks after endovascular aneurysm repair. *Ann Vasc Surg* 2015;29:594.e5-9.
9. Klonaris C, Lioudaki S, Katsargyris A, Psathas E, Kouvelos G, Doulaptsis M, et al. Late open conversion after failed endovascular aortic aneurysm repair. *J Vasc Surg* 2014;59:291-7.
10. Cho M, Choi C, Cho S, Kim S-Y, Min S-i, Ahn S, et al. Late type 3b endoleak mimicking type 2 endoleak after endovascular aortic aneurysm repair. *Vasc Specialist Int* 2017;33:81.
11. Lipsitz EC, Ohki T, Veith FJ, Suggs WD, Wain RA, Rhee SJ, et al. Delayed open conversion following endovascular aortoiliac aneurysm repair: partial (or complete) endograft preservation as a useful adjunct. *J Vasc Surg* 2003;38:1191-7.
12. Lyden SP, McNamara JM, Sternbach Y, Illig KA, Waldman DL, Green RM. Technical considerations for late removal of aortic endografts. *J Vasc Surg* 2002;36:674-8.

Submitted Sep 21, 2020; accepted Dec 10, 2020.