

TGF- β 1 expression in chromophobe renal cell carcinoma and renal oncocytoma

A. Demirović,¹ S. Cesarec,¹ Z. Marušić,¹ D. Tomas,^{1,2} M. Milošević,³ T. Hudolin,⁴ B. Krušlin^{1,2}

¹Department of Pathology, Sestre Milosrdnice University Hospital Centre, Zagreb

²School of Medicine, University of Zagreb

³Andrija Štampar School of Public Health, Zagreb

⁴Department of Urology, Clinical Hospital Centre Zagreb, Croatia

Abstract

Distinguishing renal oncocytoma (RO) from the eosinophilic variant of chromophobe renal cell carcinoma (ChRCC) under the light microscope is a common diagnostic problem. Our recent research has shown significant difference between the presence of tumor fibrous capsule in ChRCCs and ROs. Transforming growth factor beta 1 (TGF- β 1) is a potent cytokine involved in regulating a number of cellular processes. Two main purposes of this research were to investigate whether the TGF- β 1 staining could be related to the presence of tumor fibrous capsule and if it could be used in the differential diagnosis between ChRCC and RO. We investigated 34 cases: 16 ChRCCs (8 eosinophilic and 8 classic) and 18 ROs. All available slides of each tumor, routinely stained with hematoxylin and eosin (H&E) were first analyzed to note the presence of tumor fibrous capsule. One paraffin embedded tissue block matching the representative H&E slide was selected for the immunohistochemical analysis. TGF- β 1 expression was analyzed semiquantitatively in the tumor tissue, the tumor fibrous capsule, if present and the peritumoral renal parenchyma. Intensity of TGF- β 1 expression was weaker in ChRCCs than the one observed in ROs ($P < 0.05$). The type of reaction in ChRCCs was predominantly membranous unlike in ROs, which exhibited a predominantly cytoplasmic reaction ($P < 0.05$). Moreover, none of the ROs showed membranous type of reaction for TGF- β 1. In the group of ChRCCs, tumors with capsule had statistically significant higher quantity of TGF- β 1 expression in tumor tissue and in peritumoral renal parenchyma compared to the tumors without capsule ($P < 0.05$). Our results showed different types of TGF- β 1 expression in ChRCCs and ROs: ChRCCs had predominantly

membranous type of reaction, and ROs predominantly cytoplasmic. Furthermore, ChRCCs with capsule had statistically significant higher quantity of TGF- β 1 expression in tumor tissue and in peritumoral renal parenchyma compared to the tumors without capsule. Based on these findings we can speculate that it could be possible that TGF- β 1 plays a role in the formation of fibrous capsule in ChRCCs.

Introduction

The distinction of various renal neoplasms with eosinophilic features can be very challenging. Among these, the most important diagnostic problem is distinguishing renal oncocytoma (RO) from the eosinophilic variant of chromophobe renal cell carcinoma (ChRCC). RO is a benign tumor, whereas ChRCC is a low-grade malignant tumor that has a metastatic potential. Moreover, ChRCC may undergo sarcomatoid transformation, which is associated with more aggressive behavior.¹ Numerous studies have focused on the differentiation of these tumors but there is still no specific and unequivocal immunohistochemical or morphologic marker for distinguishing ChRCC and RO.^{2-11,12}

Transforming growth factor beta 1 (TGF- β 1) is a potent, pleiotropic cytokine involved in regulating a number of cellular processes including proliferation, differentiation, apoptosis, development, tissue repair, cell motility, extracellular matrix formation, inflammation, immunosuppression, and tumorigenesis.¹³ Positive staining for TGF- β 1 was observed in tubular epithelial cells in the tissue surrounding the tumor capsule of the renal cell carcinoma suggesting its role in capsular formation, but the exact mechanism of capsular formation is not clearly defined.¹⁴ Our recent research has shown significant difference between the presence of tumor fibrous capsule between ChRCCs and ROs. ChRCCs were more often surrounded with fibrous capsule that separates tumor tissue from adjacent renal parenchyma.¹⁵

Two main purposes of this research were to investigate whether the TGF- β 1 staining could be related to the presence of tumor fibrous capsule and if the TGF- β 1 staining could be used in the differential diagnosis between ChRCC and RO.

Materials and Methods

Materials

The study was carried out in compliance with the Helsinki declaration and approved by

Correspondence: Dr. Alma Demirović, Department of Pathology, Sestre Milosrdnice University Hospital Centre, Vinogradska 29, Zagreb, Croatia.
Tel. +385.1.3787465 - Fax: +385.1.3787244.
E-mail: alma.demirovic@kbcs.m.hr

Key words: capsule, chromophobe renal cell carcinoma, renal oncocytoma, TGF- β 1.

Contributions: AD, histopathological evaluation, manuscript writing and revision; SC, literature search, photomicrographs acquisition, material preparation; ZM, histopathological evaluation, patient clinical information supply; DT, histopathological evaluation, manuscript drafting; MM, statistical analysis; TH, patient clinical information supply, material preparation; BK, general concept outlining, manuscript drafting and revision. All authors have read and approved the final manuscript.

Conflict of interests: the authors declare no conflict of interests.

Received for publication: 21 August 2013.

Accepted for publication: 5 December 2013.

This work is licensed under a Creative Commons Attribution NonCommercial 3.0 License (CC BY-NC 3.0).

©Copyright A. Demirović et al., 2014
Licensee PAGEPress, Italy
European Journal of Histochemistry 2014; 58:2265
doi:10.4081/ejh.2014.2265

the institutional ethics committee (no. 30-1/07). Pathology reports of histologically confirmed ROs and ChRCCs diagnosed at three Departments of Pathology (Sestre Milosrdnice University Hospital Centre, Zagreb, University Hospital Dubrava, Zagreb and General Hospital Varaždin) from the period 2002-2011 were reviewed. The diagnosis for all cases was established according to the criteria proposed by the WHO Classification of Tumors of the Urinary System and Male Genital Organs from 2004.¹⁵

There were 34 cases in total: 16 (8 eosinophilic and 8 classic) ChRCCs (M:F=7/9; age:42-76 years, mean 60.3) and 18 ROs (M:F=6/12; age:46-80 years, mean 66.7). Tumor size in the group of ChRCCs ranged from 2-16 cm (mean 6.7), and in the group of ROs from 0.9-6 cm (mean 3.1).

Methods

All available slides of each tumor, routinely stained with hematoxylin and eosin (H&E) were first analyzed to note the presence of tumor fibrous capsule. One paraffin embedded tissue block matching the representative H&E slide was selected for the immunohistochemical analysis. Deparaffinization and immuno-

histochemical staining were performed after the microwave streptavidin immunoperoxidase protocol on a DAKO Tech-Mate™ TM Horizon automated immunostainer (Dako, Copenhagen, Denmark). We used primary monoclonal antibody to TGF-β1 (ab74525, dilution 1/25; Abcam, Cambridge, UK). Human placenta tissue served as positive control, and replacement of the primary antibody with iso-

type-matched immunoglobuline was used as a negative control. TGF-β1 expression was analyzed semiquantitatively in the tumor tissue, the tumor fibrous capsule, if present and the peritumoral renal parenchyma. In tumor tissue reaction was grouped by intensity, quantity and type of staining as follows: intensity – absent, weak, medium, strong; quantity – no positive tumor cells (0), <10% of cells (+), 10-

50% of cells (++) , >50% of cells (+++); type – membranous, mixed, cytoplasmic. In the tumor fibrous capsule and the peritumoral renal parenchyma reaction was grouped by intensity and quantity as follows: intensity – absent, weak, medium, strong; quantity – no positive cells (0), <10% of cells (+), 10-50% of cells (++) , >50% of cells (+++).

All samples were examined independently

Table 1. Pathohistologic data and results of immunohistochemical staining for TGF-β1 in chromophobe renal cell carcinoma.

N.	Type	Tumor size (cm)	Capsule	Tumor tissue			Capsule		Parenchyma	
				Intensity	Quantity	Type	Intensity	Quantity	Intensity	Quantity
1	C	6.5	Present	Weak	+++	Mix	Weak	+	Medium	+++
2	E	12	Present	Weak	++	M	Weak	+	Medium	+++
3	E	3	Present	Weak	+++	M	Weak	+	Medium	+++
4	C	4.5	Present	Weak	+++	M	Weak	++	Medium	+++
5	E	5.5	Present	Weak	+++	M	Weak	++	Medium	+++
6	C	7.2	Present	Medium	+++	M	Weak	++	Strong	+++
7	C	4.7	Present	Weak	+++	M	Medium	++	Medium	+++
8	E	5.5	Present	Medium	+++	Cy	Weak	+	Medium	+++
9	E	10.5	Present	Medium	+++	Mix	Medium	++	Weak	+++
10	C	6	Present	Medium	+++	M	Weak	++	Weak	+++
11	E	2	Present	Weak	+++	M	Weak	+	Weak	+++
12	E	10	Present	Weak	+++	Mix	Weak	+	Medium	+++
13	E	5.5	Present	Medium	+++	M	Medium	++	Medium	+++
14	E	3.5	Absent	Weak	++	M	/	/	Strong	+++
15	C	16	Absent	Weak	+	M	/	/	Weak	++
16	C	4.5	Absent	Weak	+++	Mix	/	/	Weak	+++

C, classic; E, eosinophilic; Mix, mixed; M, membranous; Cy, cytoplasmic; +, <10% of positive cells; ++, 10-50% of positive cells; +++, >50% of positive cells.

Table 2. Pathohistologic data and results of immunohistochemical staining for TGF-β1 in renal oncocytoma.

N.	Tumor size (cm)	Capsule	Tumor tissue			Capsule		Parenchyma	
			Intensity	Quantity	Type	Intensity	Quantity	Intensity	Quantity
1	1.5	Present	Medium	+++	Cy	Medium	+++	Medium	+++
2	3	Present	Weak	+++	Cy	Medium	+++	Medium	+++
3	1.7	Present	Medium	+++	Cy	Medium	++	Medium	+++
4	6	Present	Medium	+++	Mix	Medium	++	Medium	+++
5	4	Present	Weak	+++	Mix	Weak	++	Weak	+++
6	2.5	Present	Strong	+++	Cy	Medium	++	Medium	++
7	3	Present	Strong	+++	Mix	Medium	+	Strong	+++
8	2.5	Present	Medium	+++	Cy	Weak	+	Weak	+++
9	2.5	Absent	Medium	+++	Mix	/	/	Medium	+++
10	2.2	Absent	Weak	++	Cy	/	/	Medium	++
11	0.9	Absent	Medium	+++	Cy	/	/	Medium	+++
12	4	Absent	Medium	+++	Cy	/	/	Medium	+++
13	5.5	Absent	Medium	+++	Cy	/	/	Weak	+++
14	2.5	Absent	Strong	+++	Mix	/	/	Strong	+++
15	3.5	Absent	Strong	+++	Cy	/	/	Strong	+++
16	2.5	Absent	Weak	+++	Cy	/	/	Weak	+++
17	3.5	Absent	Weak	+++	Cy	/	/	Weak	+++
18	4	Absent	Weak	+++	Cy	/	/	Weak	+++

Mix, mixed; Cy, cytoplasmic; +, <10% of positive cells; ++, 10-50% of positive cells; +++, >50% of positive cells.

by three observers (AD, ZM and DT) and any difference was resolved by a joint review.

Statistical analysis

Statistical analysis was done using Pearson χ^2 -test, Spearman's correlation test, Fisher's exact test and Mann-Whitney test. A P value <0.05 was considered to be statistically significant.

Results

Tumor fibrous capsule was present in 13/16 cases (81.3%) of ChRCCs and in 8/18 cases (44.4%) of ROs. Statistical analysis showed significant difference between the presence of fibrous capsule in these two observed tumor groups ($P<0.05$). In cases of ChRCCs the capsule was found to encompass the whole tumor circumference on the examined slides. In cases of ROs with capsule it was formed only partially and incompletely encircled the tumor tissue. Relevant pathohistologic data and results of immunohistochemical staining are summarized in Tables 1 and 2. Tumor tissue of all cases of ChRCCs and ROs showed positive immunohistochemical reaction for TGF- β 1. Intensity of TGF- β 1 expression was weaker in ChRCCs than the one observed in ROs ($P<0.05$). The type of reaction in ChRCCs was predominantly membranous unlike in ROs, which exhibited a predominantly cytoplasmic reaction ($P<0.05$) (Figures 1 and 2). Moreover, none of the ROs showed membranous type of reaction for TGF- β 1. The intensity and quanti-

ty of TGF- β 1 expression in tumor capsule and peritumoral renal parenchyma, regardless of the capsule presence, did not show any differences between ChRCCs and ROs ($P>0.05$).

In the group of ChRCCs, tumors with capsule had statistically significant higher quantity of TGF- β 1 expression in tumor tissue and in peritumoral renal parenchyma compared to the tumors without capsule ($P<0.05$). In the group of ROs the intensity and quantity of TGF- β 1 expression in tumor tissue and peritumoral renal parenchyma, regardless of the capsule presence, did not show any differences ($P>0.05$).

Discussion

ChRCC and RO are both rare renal neoplasms: ChRCC accounts for 5% and RO represents 3% to 9% of all primary renal tumors.¹⁶ In most cases, classic ChRCC can be easily differentiated from RO based on H&E microscopic slides. The distinction between the eosinophilic variant of ChRCC and RO is challenging in the majority of cases. Considering their different biological behavior, ChRCC and RO must be diagnosed properly. On the H&E stained slides RO has uniform, round nuclei and discrete nucleoli. ChRCC more often has hyperchromatic, irregular wrinkled nuclei, prominent nucleoli and perinuclear halos.^{9,10}

There have been numerous studies that explored the possible use of various immunohistochemical markers in differentiation of RO from ChRCC. Zheng *et al.*² investigated the

expression of LMP2 with promising results: they reported that nuclear positivity for LMP2 favors the diagnosis of eosinophilic ChRCC but the number of cases seems insufficient to make final conclusions.² Fernandez-Acenero *et al.*³ also explored a wide immunohistochemical panel for the differential diagnosis of renal tumors with oncocytic features, including cytokeratins 7 and 20, CD117, CD10, p53, progesterone and racemase and found no specific, single marker for the accurate diagnosis of these tumors.³ Other explored immunohistochemical markers include kidney-specific cadherin, cytokeratin 7, KIT and PAX 2, claudin-7 and 8, MAGE-A3/4, NY-ESO-1, caveolin1, CD63 and cytokeratin 14.^{4,8,11,12} TGF- β 1 is a cytokine involved in regulating a number of cellular processes including proliferation, differentiation, apoptosis, development, tissue repair, cell motility, extracellular matrix formation, inflammation, immunosuppression, and tumorigenesis.¹³ TGF- β 1 induces differentiation of fibroblasts to myofibroblasts in a number of physiologic and pathologic processes.¹⁷⁻¹⁹ Shimasaki *et al.*¹⁴ observed positive staining for TGF- β 1 in tubular epithelial cells in the tissue surrounding the tumor capsule of the renal cell carcinoma suggesting its role in capsular formation. Tubular epithelial cells positive for TGF- β 1 were restricted to the surrounding area of the tumor, whereas epithelial cells in tubules away from the capsule had no positive reaction for TGF- β 1.¹⁴ However, their research consisted of nineteen renal tumors, 17 conventional renal cell carcinomas, and only 2 ChRCCs, and this number of cases seems absolutely insufficient. We have previously

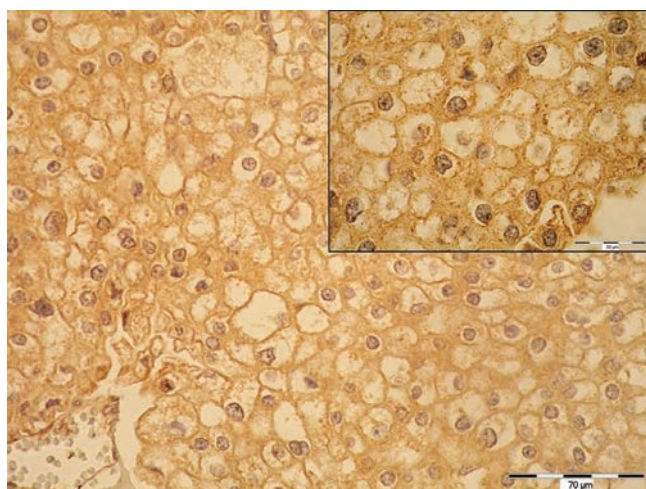


Figure 1. Membranous type of reaction for TGF- β 1 in chromophobe renal cell carcinoma. Scale bar: 70 μ m; scale bar in inset: 30 μ m.

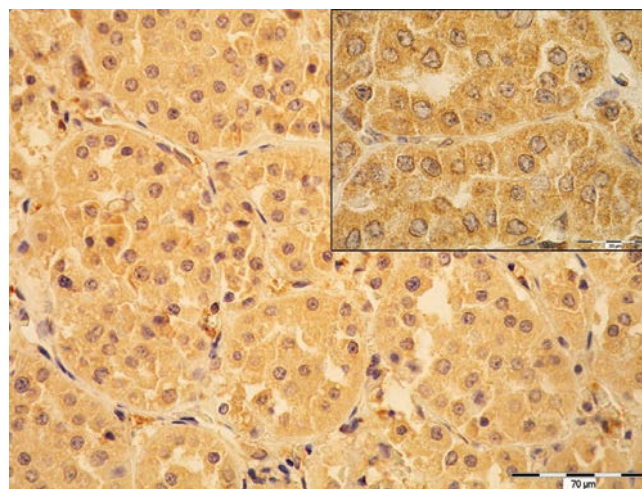


Figure 2. Cytoplasmic type of reaction for TGF- β 1 in renal oncocytoma. Scale bar: 70 μ m; scale bar in inset=30 μ m.

shown that ChRCCs were more often surrounded with fibrous capsule than ROs.¹⁵ In the present study we investigated the TGF- β 1 expression in ChRCCs and ROs, in tumor fibrous capsule, if it was present and in peritumoral renal parenchyma. Two main purposes of this research were to investigate whether the TGF- β 1 staining could be related to the presence of tumor fibrous capsule and if the TGF- β 1 staining could be used in the differential diagnosis between ChRCC and RO. Our results showed different types of TGF- β 1 expression in ChRCCs and ROs: ChRCCs had predominantly membranous type of reaction, and ROs predominantly cytoplasmic. Moreover, none of the ROs showed membranous type of reaction for TGF- β 1. In addition, the intensity of TGF- β 1 expression was significantly weaker in ChRCCs compared to ROs.

These findings could be useful in forthcoming investigations of immunohistochemical markers that could be used for the differential diagnosis of ChRCC and RO. However, larger number of cases should be analyzed to confirm the potential value of TGF- β 1 staining in differential diagnosis between ChRCC and RO. The results of the present study confirmed that ChRCCs are more often surrounded by fibrous capsule than ROs. Furthermore, ChRCCs with capsule had statistically significant higher quantity of TGF- β 1 expression in tumor tissue and in peritumoral renal parenchyma compared to the tumors without capsule. Based on these findings we can speculate that it could be possible that TGF- β 1 plays a role in the formation of tumor fibrous capsule in ChRCCs. Similar findings are also reported by Shimasaki *et al.*¹⁴ However, the exact process of capsule formation in the above mentioned tumors remains an enigma. Another interesting finding that appeared in this study was that the intensity of TGF- β 1 expression was weaker in ChRCCs than in ROs, independently of the capsular presence. It is known that TGF- β has a dual role in tumors. It can act as a tumor suppressor or become an oncogenic factor.²⁰ In normal epithelium TGF- β inhibits cell proliferation and induces apoptosis, but during tumorigenesis it gains pro-oncogenic function.²¹ It could be only speculated that, concerning its stronger intensity in ROs these tumors remain inhibited by the tumor suppressor activity of TGF- β , therefore behaving as benign tumors whereas levels of TGF- β in ChRCCs are insufficient, leaving a small possibility for malignant behavior of these tumors. However, the connection between the biological function of TGF- β 1 and its immunohistochemical expression in these groups of tumors has to be analyzed more thoroughly, in a prospective study and preferably on a larger number of cases. We believe that ChRCCs and ROs are an excellent model for the investiga-

tion of the capsule formation considering their similar microscopic appearance but different biological behavior as well as a fact that ChRCCs are indeed more often encompassed by fibrous capsule than ROs.

Future investigations should be focused on the detection of mechanisms that lead to tumor capsule formation in ChRCCs and ROs. Hopefully, this could reveal potential discriminating markers between ChRCC and RO.

References

- Lopez-Beltran A, Scarpelli M, Montironi R, Kirkali Z. 2004 WHO Classification of the renal tumors of the adults. *Eur Urol* 2006;49:798-805.
- Zheng G, Chaux A, Sharma R, Netto G, Caturegli P. LMP2, a novel immunohistochemical marker to distinguish renal oncocytoma from the eosinophilic variant of chromophobe renal cell carcinoma. *Exp Mol Pathol* 2012;94:23-32.
- Fernandez-Acenero MJ, Cazorla A, Manzarbeitia F. Immunohistochemistry for the differential diagnosis of renal tumors with oncocytic features. *Urol Oncol* 2011; 29:545-9.
- Demirović A, Džombeta T, Tomas D, Spajić B, Pavić I, Hudolin T, et al. Immunohistochemical expression of tumor antigens MAGE-A3/4 and NY-ESO-1 in renal oncocytoma and chromophobe renal cell carcinoma. *Pathol Res Pract* 2010;206:695-9.
- Mete O, Kilicaslan I, Gulluoglu MG, Uysal V. Can renal oncocytoma be differentiated from its renal mimics? The utility of anti-mitochondrial, caveolin 1, CD63 and cytokeratin 14 antibodies in the differential diagnosis. *Virchows Arch* 2005;447:938-46.
- Liu L, Qian J, Singh H, Meiers I, Zhou X, Bostwick DG. Immunohistochemical analysis of chromophobe renal cell carcinoma, renal oncocytoma, and clear cell carcinoma: an optimal and practical panel for differential diagnosis. *Arch Pathol Lab Med* 2007;131:1290-7.
- Osunkoya AO, Cohen C, Lawson D, Picken MM, Amin MB, Young AN. Claudin -7 and claudin-8: immunohistochemical markers for the differential diagnosis of chromophobe renal cell carcinoma and renal oncocytoma. *Hum Pathol* 2009;40:206-10.
- Mazal PR, Exner M, Haitel A, Krieger S, Thomson RB, Aronson PS, et al. Expression of kidney-specific cadherin distinguishes chromophobe renal cell carcinoma from renal oncocytoma. *Hum Pathol* 2005;36:22-8.
- Okon K, Sinczak-Kuta A. Nuclear morphometry as a tool of limited capacity for distinguishing renal oncocytoma from chromophobe carcinoma. *Pol J Pathol* 2008;59:9-13.
- Brimo F, Epstein JI. Selected common diagnostic problems in urologic pathology: perspectives from a large consult service in genitourinary pathology. *Arch Pathol Lab Med* 2012;136:360-71.
- Memeo L, Jhang J, Assaad AM, McKiernan JM, Murty VV, Hibshoosh H, et al. Immunohistochemical analysis for cytokeratin 7, KIT, and PAX2: value in the differential diagnosis of chromophobe cell carcinoma. *Am J Clin Pathol* 2007;127:225-9.
- Cui C, Lal P, Master S, Ma Y, Baradet T. Expression of parafibromin in major renal cell tumors. *Eur J Histochem* 2012;56:e39.
- Glick AB. TGF β 1, back to the future: revisiting its role as a transforming growth factor. *Cancer Biol Ther* 2004;3:276-83.
- Shimasaki N, Kuroda N, Guo L, Jin Y, Miyazaki E, Hayashi Y, et al. The participation of myofibroblasts in the capsular formation of human conventional and chromophobe renal cell carcinomas. *Histol Histopathol* 2005;20:67-73.
- Demirović A, Cesarec S, Spajić B, Tomas D, Bulimbašić S, Milošević M, et al. Can renal oncocytoma be distinguished from chromophobe renal cell carcinoma by the presence of fibrous capsule? *Virchows Arch* 2010;456:85-9.
- Eble JN, Sauter G, Epstein JI, Sesterhenn IA. World Health Organization Classification of Tumours. Pathology and Genetics of Tumours of the Urinary System and Male Genital Organs. 2004, IARC Press, Lyon.
- Kumar V, Abbas AK, Fausto N in Robbins and Cotran pathologic basis of disease, 7th ed. Philadelphia: Elsevier Saunders;2005, p.110-17.
- Seong GJ, Hong S, Jung SA, Lee JJ, Lim E, Kim SJ, et al. TGF- β -induced interleukin-6 participates in transdifferentiation of human Tenon's fibroblasts to myofibroblasts. *Mol Vis* 2009;15:2123-28.
- Sandbo N, Lau A, Kach J, Ngam C, Yau D, Dulin NO. Delayed stress fiber formation mediates pulmonary myofibroblast differentiation in response to TGF- β . *Am J Physiol Lung Cell Mol Physiol* 2011;301: L656-66.
- Derynck R, Akhurst RJ, Balmain A. TGF- β signaling in tumor suppression and cancer progression. *Nat Genet* 2001;29:117-129.
- Levy L, Hill CS. Alterations in components of the TGF-beta superfamily signaling pathways in human cancer. *Cytokine Growth Factor Rev* 2006;17:41-58.