

Case Report

Idiopathic Adult Ileoileal and Ileocolic Intussusception *in situs Inversus Totalis*: A Rare Coincidence

Nazish Butt, Syed H. Shah, Abdul R. Alvi¹, Tanveer-ul-Haq², Saba Hassan³

Departments of Medicine,
Section of Gastroenterology,
¹Surgery, ²Radiology, ³Pathology,
Aga Khan University Hospital,
Stadium Road Karachi, Pakistan

Address for correspondence:

Dr. Syed H. Shah,
Kamruddin Mohamed Jassani
Professor of Medicine,
Head Section of
Gastroenterology,
The Aga Khan University,
Karachi, Pakistan.
E-mail: hasnain.alishah@aku.edu

ABSTRACT

Situs inversus totalis is a rare autosomal recessive congenital anomaly that is characterized by mirror image anatomy of the abdominal and thoracic organs. We report a case of a 28-year-old male with situs inversus totalis, who developed an idiopathic ileoileal and ileocolic intussusception, which was diagnosed on computed tomography scan. Patient underwent successfully ileal resection and side-to-side functional anastomosis of ileum 12 cms from ileocecal junction. Postoperative course was uneventful. To the best of our knowledge, this is the first case of idiopathic adult intussusception with situs inversus totalis in the literature.

Key Words: Colonoscopy, computed tomography, idiopathic adult intussusception, situs inversus totalis

Received: 23.11.2010, Accepted: 26.02.2011

How to cite this article: Butt N, Shah SH, Alvi AR, T, Hassan S. Idiopathic adult ileoileal and ileocolic intussusception in situs inversus totalis: A rare coincidence. Saudi J Gastroenterol 2012;18:68-70.

The term situs inversus is a short form of the Latin phrase “situs inversus viscerum,” meaning “inverted position of the internal organs.”^[1] Situs inversus is generally an autosomal recessive, although it can be X-linked genetic disorder with an incidence of 1 in 10,000.^[2] Patients with situs anomalies have a variety of gastrointestinal abnormalities. Gastric volvulus, malrotation anomalies, duodenal atresia or stenosis, gastroschisis, hiatal hernia, appendicitis, polysplenia, biliary atresia, and short pancreas have been reported in the literature.^[3] The association of idiopathic adult intussusception with situs inversus totalis is not reported in the literature. Adult intussusception is rare representing 5% of all cases of intussusception and accounts for only 1-5% of intestinal obstruction in adults.^[4]

We report a case of idiopathic ileoileal and ileocolic intussusception associated situs inversus totalis.

CASE REPORT

A 28-year-old male patient presented to the emergency department with a 3 day history of lower abdominal pain

and bloody diarrhea. He was already a diagnosed case of situs inversus totalis on the basis of chest X-ray and ultrasound abdomen, co-incidentally. His past medical history was significant for similar episodes of abdominal pain and bloody diarrhea for last 2 years. On clinical examination, he was alert, afebrile, and mildly pale. Abdominal examination revealed mild left iliac fossa tenderness. There was no palpable lump, guarding or rigidity. Bowel sounds were audible on auscultation. On per rectal examination, stools were absent. Rest of the examination was unremarkable. Initial laboratory tests revealed serum hemoglobin of 7.5 g/dl, hematocrit 25.6%, serum iron of 8 mcg/dl, total iron binding capacity of 379 mcg/dl, and ferritin of 5.66 ng/ml. The platelet count, prothrombin time, and liver function tests were normal. Plain abdominal radiograph revealed minimal air in large intestine; findings representative of subacute distal small bowel obstruction. Ultrasound of abdomen revealed minimal streak of free fluid in Morrison's pouch. His pain subsided after receiving intravenous analgesics, antibiotics, and fluids. During hospitalization, the patient had two episodes of hematochezia and severe abdominal pain. Plain abdominal radiograph during the episode of abdominal pain was normal. On the third day of admission, colonoscopy was performed with cecal intubation time of 5 min. It revealed 1-2 cm ileal ulcer. Computed tomography (CT) scan of the abdomen showed situs inversus totalis (the apex of the heart, stomach, and spleen resting on the right side and the liver on the left side of the abdomen) and ileocolic intussusception giving the appearance of bowel within bowel associated with minimal free fluid in pelvis [Figures 1 and 2]. No

Access this article online	
	Quick Response Code:
	Website: www.saudijgastro.com
	DOI: 10.4103/1319-3767.91732

evidence of proximal bowel obstruction was noted. Patient underwent an exploratory laparotomy and operative findings were ileoileal and ileocolic intussusception, through cecum up to transverse colon. There was no evidence of bowel ischemia. Retrograde reduction and segmental resection of ileum 12 cm from ileocecal junction was done which contained a polypoidal mass. Anatomical side-to-side but functionally end to end anastomosis was performed with mechanical GIA-75 single use stapler with absorbable staples. Appendicectomy was performed as well. The gross specimen showed inflammatory pseudo polyps [Figure 3]. Histopathology showed a small intestinal tissue exhibiting numerous inflammatory pseudopolyps projecting above the mucosal surface composed almost entirely of inflamed granulation tissue with surface ulceration. Crypts are dilated and hyperplastic [Figure 4]. The postoperative period was uneventful. After 3 months of follow up patient is fine and has no bowel symptoms till date.

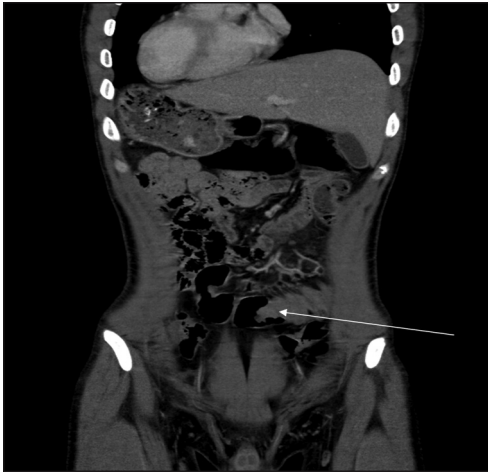

Figure 1: Contrast-enhanced CT scan of the abdomen demonstrated situs inversus totalis with apex of the heart, stomach and spleen resting on the right side and the liver on the left side of the abdomen and ileocolic intussusception which creates characteristic bowel-within-bowel appearance, seen in left iliac fossa (white arrow)

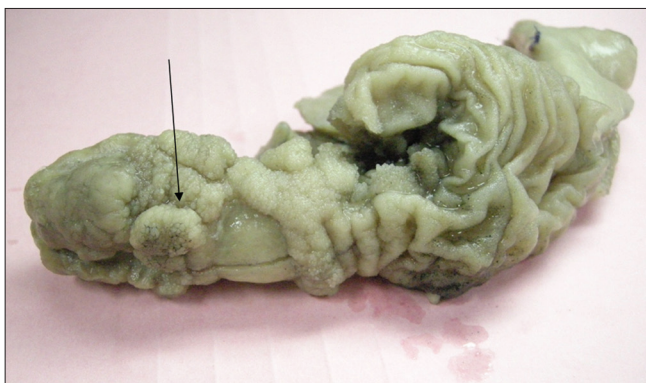

Figure 3: The resected ileum specimen shows inflammatory pseudo polyps (black arrow)

DISCUSSION

Patients with situs inversus totalis are usually asymptomatic, healthy and have a normal life expectancy.^[5] Situs inversus is associated with Kartagener syndrome, congenital heart diseases and gastrointestinal anomalies.^[3,6] The control of normal human somatic asymmetry is not yet known. Environmental factors, including exposure to retinoic acid and maternal diabetes, have been implicated in laterality defects among offspring of affected parents.^[7] Situs inversus and intestinal intussusception has been reported in a dog in the literature.^[8] Although there are several case reports in the literature explaining idiopathic adult intussusception and situs anomalies independently, to the best of our knowledge, the association of idiopathic adult intussusception with situs inversus totalis has not been previously reported in the literature.

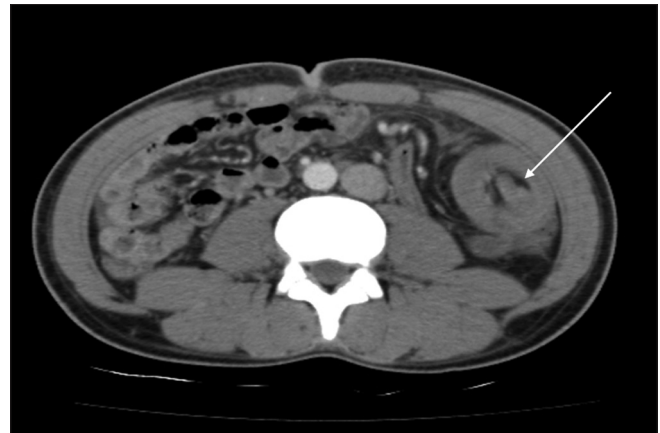


Figure 2: Contrast-enhanced CT scan of the abdomen demonstrated the classic findings of a target like an ileocolic intussusception, with no evidence of proximal bowel obstruction *in situs inversus totalis* (white arrow)

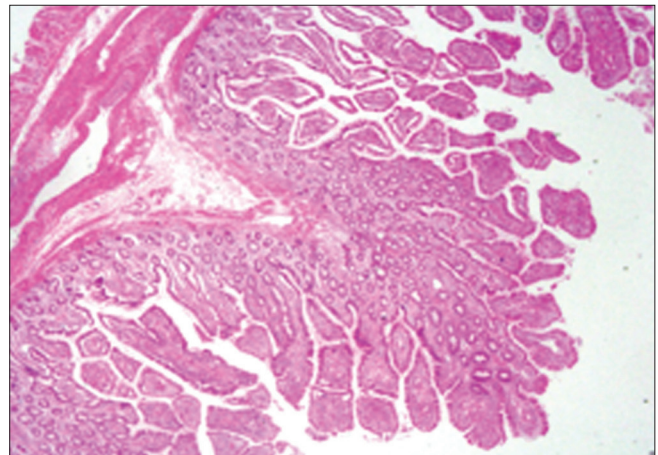


Figure 4: Histopathology showing inflammatory pseudopolyps projecting above the mucosal surface composed of inflamed granulation tissue with surface ulceration and dilated and hyperplastic crypts

In adults, intussusception is rare, and the diagnosis is not typically at the top of the differential list. The patient typically presents with nonspecific abdominal pain, cramping and with an acute or chronic obstruction.^[9] Most adult intussusceptions are enteric and benign in origin. Unlike the more common idiopathic intussusception found in children, intussusception in adults remains a surgical disease. Idiopathic adult intussusception is more likely to occur in the small intestine than in the colon.^[10,11]

In this case, the histopathology report was suggestive of inflammatory pseudo polyps projecting above the mucosal surface. The inflammatory pseudo polyps were formed as a result of intermittent intussusception.

The association of intestinal intussusception with situs inversus totalis remains unknown. Yui Mano *et al.* reported some unusual arrangement of intestinal loops along the jejunum, ileum and at the terminal ileum (8 cm oral from the ileocecal valve) in male cadaver with situs inversus totalis.^[12] It can be hypothesized that decreased rigidity in the wall of the cecum or some variation in the anatomy of the ileocecal valve in the situs inversus totalis patients make it more prone to prolapse.

Plain abdominal films and ultrasonography are typically the initial investigations for the evaluation of abdominal symptoms.^[13] However, these were not found to be useful in this case. Abdominal CT scan is currently considered as the most sensitive radiological method to confirm intussusception. Most cases of intussusception found on CT are not suspected clinically. The characteristic features of CT scan include an inhomogeneous “target” or “sausage”-shaped soft-tissue mass with a layering effect.^[14] Colonoscopy is considered invaluable in evaluating cases of intussusception presenting with subacute or chronic large bowel obstruction. However, we can localize the disease and be able to demonstrate the underlying pathology.^[13,15] Colonoscopy is considered challenging and difficult in *situs inversus totalis* due to complete left-right reversal of the internal organs. Dong Hyun Choi *et al.* reported prolonged cecal intubation time in SIT.^[16] We found colonoscopy very feasible in context to situs inversus totalis in this patient. The surgical options are not different in *situs inversus totalis* patients. Many procedures such as cholecystectomy, appendectomy, sigmoidectomy, gastrectomy, Roux-en-Y bypass, gastric banding, Nissen fundoplication, and hemicolectomy have been performed.^[17]

In conclusion, we reported an adult case of situs inversus totalis with an idiopathic ileoileal and ileocolic intussusception

not previously described. The mirror-image anatomy does not pose an unusual technical challenge in colonoscopy and surgery, although care should be taken when making a diagnosis in patients with situs inversus totalis because of the unusual location of the major organs. Abdominal CT is considered as the most sensitive imaging modality in the diagnosis of intussusception.

REFERENCES

- Hagler DJ, O'Leary PW: Cardiac malpositions and abnormalities of atrial and visceral situs In: Allen HD, Dariscoli DJ, Shaddy RE, Feltes TF (eds). *Heart Disease in Infants, Children, Adolescents*. 7th ed. Vol. 2. Williams and Wilkins; 2007:1149-71.
- Scusi EL, Wray CJ. Pancreatic adenocarcinoma in a patient with situs inversus: A case report of this rare coincidence. *World J Surg Oncol* 2009;7:98.
- Lee SE, Kim HY, Jung SE, Lee SC, Park KW, Kim WK. Situs anomalies and gastrointestinal abnormalities. *J Pediatr Surg* 2006;41:1237-42.
- Marinis A, Yiallourou A, Samanides L, Dafnios N, Anastasopoulos G, Vassiliou I, *et al.* Intussusception of the bowel in adults: A review. *World J Gastroenterol* 2009;15:407-11.
- Douard R, Feldman A, Bary F, Loric S, Delmas V. Anomalies of lateralization in man: A case of total situs inversus. *Surg Radiol Anat* 2000;22:293-7.
- Holzman D, Ott PM, Felix H. Diagnostic approach to primary ciliary dyskinesia: A review. *Eur J Pediatr* 2000;159:95-8.
- Lin AE, Ticho BS, Houde K, Westgate MN, Holmes LB. Heterotaxy: Associated conditions and hospital-based prevalence in newborns. *Genet Med* 2000;2:157-72.
- Hough JD, Carlson B, Weitkamp RA, McLean RT. Situs inversus and intussusception in a dog. *J Am Anim Hosp Assoc* 1979;15:335-37.
- Wang LT, Wu CC, Yu JC, Hsiao CW, Hsu CC, Jao SW. Clinical entity and treatment strategies for adult intussusceptions: 20 years' experience. *Dis Colon Rectum* 2007;50:1941-9.
- Zubaidi A, Al-Saif F, Silverman R. Adult intussusception: A retrospective review. *Dis Colon Rectum* 2006;49:1546-51.
- Barussaud M, Regenet N, Briennon X, de Kerviler B, Pessaix P, Kohnen-Sharhi N, *et al.* Clinical spectrum and surgical approach of adult intussusception. *Int J Colorectal Dis* 2006;21:834-9.
- Mano Y, Adachi N, Murakami G, Yokoyama T, Dodo Y. Human situs inversus of the thoracoabdominal structures. *Anat Sci Int* 2006;81:7-20.
- Begos DG, Sandor A, Modlin IM. The diagnosis and management of adult intussusception. *Am J Surg* 1997;173:88-94.
- Goh BK, Quah HM, Chow PK, Tan KY, Tay KH, Eu KW, *et al.* Predictive factors of malignancy in adults with intussusception. *World J Surg* 2006;30:1300-4.
- Chang FY, Cheng JT, Lai KH. Colonoscopic diagnosis of ileocolic intussusception in an adult- A case report. *S Afr Med J* 1990;77:313-4.
- Choi DH, Park JW, Kim BN, Han KS, Hong CW, Sohn DK, *et al.* Colonoscopy in *situs inversus totalis* patients. *Am J Gastroenterol* 2008;103:1311-2.
- Akbulut S, Caliskan A, Ekin A, Yağmur Y. Left-sided acute appendicitis with situs inversus totalis: Review of 63 published cases and report of two cases. *J Gastrointest Surg* 2010;14:1422-8.

Source of Support: Nil, **Conflict of Interest:** None declared.