

Research on a rat model of genotype IV swine hepatitis E virus

Zhijie Jian¹  | Youyou Li² | Zhiwen Xu³ | Jun Zhao¹  | Fengqin Li^{1,4} |
Huidan Deng¹ | Xiangang Sun¹ | Ling Zhu³ 

¹ College of Veterinary Medicine, Sichuan Agricultural University, Chengdu, P. R. China

² Sichuan Water Conservancy College, College of Veterinary Medicine, Chengdu, P. R. China

³ Key Laboratory of Animal Diseases and Human Health of Sichuan Province, College of Veterinary Medicine, Sichuan Agricultural University, Chengdu, P. R. China

⁴ College of Animal Science, Xichang University, Xichang, Sichuan, P. R. China

Correspondence

Ling Zhu, Key Laboratory of Animal Diseases and Human Health of Sichuan Province, College of Veterinary Medicine, Sichuan Agricultural University, Chengdu 611130, P. R. China. Email: abtczl72@126.com

Zhijie Jian and Youyou Li both are the co-first author.

Funding information

Research and Integration Demonstration of Key Technologies for Improving Quality and Efficiency of Sichuan Pig Industry Chain, Grant/Award Number: 2020YFN0147; Program Sichuan Veterinary Medicine and Drug Innovation Group of China Agricultural Research System; Sichuan Science and Technology Plan Program, Grant/Award Number: 2017NZ0038; Sichuan Science and Technology Support Program, Grant/Award Number: 2016NY0052

Abstract

Background: Hepatitis E virus (HEV) is an important zoonotic pathogen, Genotypes 3 and 4 are the main zoonotic genotype. Due to the lack of mature and effective culture cell lines, researches on genotype IV swine HEV (SHEV-4) infection and pathogenic mechanism have been carried out in pigs, gerbils and non-human primate models.

Objectives: The aim of this study was to establish a rat infection model by intra-peritoneal infection with SHEV-4, which provided a new research idea and scientific basis for further revealing the mechanism of HEV infection and preventing HEV infection.

Methods: SHEV-4 virus was administered intra-peritoneally to 6- to 8-week-old mice to observe the serological changes and virus release.

Results: According to the results of the rat serum HEV IgG, ALT and AST levels, swine HEV, minus-strand HEV RNA can infect Sprague–Dawley rats across species, and there are no obvious clinical symptoms after infection. HEV RNA was detected in most tissues and organs after infection, but the viral load was low. The liver had pathological changes of chronic hepatitis.

Conclusions: We found that the rat model of porcine HEV infection is a small animal model suitable for the study of HEV infection.

KEYWORDS

Cross-species infection, Intraperitoneal injection, Rat model, swine HEV-4, zoonosis

1 | INTRODUCTION

Hepatitis E genotype 3, 4, 7 are the zoonotic diseases (Dalton et al., 2014; Lee et al., 2015). The main route of transmission is faecal oral transmission via drinking contaminated water and eating contaminated food (Mushahwar, 2008; G. G. Schlauder et al., 1998; Tokita., 2003). Eating improperly cooked HEV-infected animal tissues or offal

may also lead to food-borne infections (Hiroyuki, et al., 2003; Khuroo., 2010). Additionally, the virus is spread through mother-to-child transmission (Boxall et al., 2006; Mitsui et al., 2004) and blood transmission (Colson et al., 2007; Jothikumar et al., 2006). HEV is also distributed in a variety of animals, can be transmitted between people and pigs and is an important pathogen that affects human health and the pig industry (Schlauder and Mushahwar, 2001). But what we need to know is that

This is an open access article under the terms of the [Creative Commons Attribution-NonCommercial-NoDerivs](https://creativecommons.org/licenses/by-nc-nd/4.0/) License, which permits use and distribution in any medium, provided the original work is properly cited, the use is non-commercial and no modifications or adaptations are made.

© 2022 The Authors. *Veterinary Medicine and Science* published by John Wiley & Sons Ltd.

genotypes 1 and 2 are primarily infected in humans and less frequently isolated from animals (He et al., 2002).

Hepatitis E virus (HEV) belongs to the Hepeviridae family Hepevirus, which is a single-stranded, positive, non-enveloped RNA virus. HEV has only one serotype and at least five genotypes (Miyashita et al., 2012). Genotype I is mainly distributed in Asia and Africa. Genotype II is distributed in Mexico and Africa. Genotypes I and II only infect humans, mainly young adults. Children and the elderly often show sub-clinical symptoms after infection, and the mortality rate of pregnant women after infection is as high as 20%. Genotype III is distributed throughout the world, genotype IV is mainly distributed in Asia (Cossaboom et al., 2012; Miyashita et al., 2012), and genotypes III and IV can infect humans and are spread by many animals. The first clinical case of acute symptomatic HEV genotype 4 infection was reported in a patient in Japan in 2020 (Kitaura et al., 2020). Studies have found that in addition to humans, the hosts of HEV genotypes III and IV include macaques, chimpanzees, rhesus monkeys, pigs, deer, dogs, cattle, sheep, chickens, rabbits, bats and zigzags (Cossaboom et al., 2012; Meng, 2013; Pavio, et al., 2010; Saad et al., 2007).

The study showed that the liver of pigs infected with HEV could not inactivate the virus after being exposed to 56°C for 1 hour or the milk containing HEV could not be pasteurized and the virus was still infectious (Emerson, et al., 2005; Huang et al., 2016). HEV-4 is mainly distributed in Asia and has 71.79 to 77.38% homology with other strains. The HEV-4 is divided into nine subtypes (a - i), separated from pigs, wild boars and humans. In addition, it is also isolated from sheep, cattle and goats in China (Nicand et al., 2005). Studies have shown that genotype IV swine HEV (SHEV-4) can be transmitted between humans and pigs, and human-to-animal transmission of HEV is becoming a major public health problem. The animal models used for the study of SHEV-4 cross-species infection are few in species and mainly adopt the non-natural route of infection-intravenous injection. Compared with the intravenous infection, the intra-peritoneal infection process can better simulate the blood flow to the liver during natural HEV infection. Sprague-Dawley (SD) Rats have been widely used in life sciences and biomedical research. Therefore, this experiment selected SD rats as the experimental object to study the distribution of genotype IV SHEV-4 in different tissues and the virus-shedding law of rat. This study provides new research ideas and scientific basis for further revealing the mechanism of HEV infection and preventing HEV infection.

2 | MATERIALS AND METHODS

2.1 | Viruses

SHEV-4-positive fecal disease material was provided by a pig farm in Sichuan, China. We tested the fecal suspension for other pathogens and all results were negative, ensuring that only SHEV-4 virus was present in the fecal suspension. Fecal samples were diluted in phosphate-buffered saline (10%, w/v), vortex shocked for 1 min, centrifuged at $12,000 \times g$ 4°C for 10 min, filtered through 0.22- μ m microfilters and add with penicillin and streptomycin. Viral genomic titers in

Implications

- Swine hepatitis E virus (SHEV-4) has emerged as an important human zoonotic HEV strain, while HEV-infected animals are usually excreted into the environment through feces to contaminate water supplies or food.
- This study used Sprague-Dawley (SD) rats as experimental animals, revealed that SHEV-4 could be infected by intra-peritoneal injection in SD rats.
- The study revealed the detoxification and tissue virus distribution of SHEV after cross-species infection, so as to provide new research ideas and scientific basis for further revealing the mechanism of HEV infection and preventing HEV infection.

the above positive feces samples were determined by quantitative real-time polymerase chain reaction (qRT-PCR) at 3.31×10^4 copies/ μ L, as previously described (YY L et al., 2017). The suspension was aliquoted in volumes of 1.5 mL and stored at -80°C.

2.2 | Animal groups and infection

Specific pathogen-free female SD rats (6- to 8-week old, 80-100 g body weight) were obtained from the Chengdu Dashuo Experimental Animal Co., Ltd. The rats were kept at 22°C under a 12 h light/dark cycle, and they were provided with food and water ad libitum. Prior to the study, feces and serum samples were collected separately to detect HEV RNA by qRT-PCR and to determine anti-HEV IgG and IgM by Enzyme-linked immunosorbent assay (ELISA), ensure that the SD rats used in this study are negative to anti-HEV antibodies and HEV RNA. The study was carried out in accordance with the UK Animals (Scientific Procedures) Act, 1986 and associated guidelines. The study was approved by the Sichuan Experimental Animal Management Committee (permit number SYXK [Chuan] 2019-187). Sixty-three rats were divided randomly into three groups: 21 rats in the experimental group (Group 1), 21 rats in the control group (Group 2) and 21 rats in the blank group (Group 3). Rats of Group 1 were treated with an intra-peritoneal injection of 500 μ L of genotype IV HEV-positive swine faeces suspension. Rats of Group 2 were given a 500- μ L sham injection of sterile normal saline, while the rats of Group 3 were given nothing.

2.3 | General observations and sample collection

Rats were observed daily for 7 weeks after infection, and their physical condition and survival were recorded. At 0, 7, 14, 21, 28, 35, 42 and 49 days post-inoculation (dpi), three rats in each group were humanely killed and subjected to histo-pathological analyses and internal organ cultures. The organ (including brain) and faeces samples were used for HEV RNA detection. Blood was used to detect HEV antibodies.

2.4 | Histopathology

The organs (heart, liver, spleen, lung and kidney) were fixed in 4% paraformaldehyde for 2–3 days, embedded in paraffin, serially sectioned and stained with haematoxylin and eosin.

2.5 | Virology and serology analyses

Total RNA was extracted from the heart, liver, spleen, lung, kidney, brain, faeces and blood samples using RNAiso Plus (Takara Bio Inc., Dalian, China) according to the manufacturer's protocol. From each tissue and organ sample of each group of animals, a 2-g sample was taken for RNA extraction, and the sample type was analysed three times for replication purposes. Reverse transcriptase polymerase chain reaction (RT-PCR) was performed according to the instructions provided by the kit manufacturer (PrimeScript 1st Strand cDNA Synthesis Kit, Takara Bio Inc.). Real-time PCR was performed according to the instructions provided by the kit manufacturer (SYBR Premix Ex TaqTM II Kit, Takara Bio Inc.) using the following open reading frame -2 primer sets: forward, 5'- ATTCGTCGGCTGGAGGT -3' and reverse, 5'- ACGGGACT-CACCAAGATCAATA -3'. The results were expressed in terms of cycle

threshold (Ct). Standard quantification curves were produced by plotting the Ct values against the logarithm of the input copy numbers of standard DNA. Standard DNA was obtained in another study (YY L et al., 2017). The results are expressed as genomic copy number per gram of samples (copies/g).

Two primers were used for minus-strand HEV RNA detection. The RT-nPCR primers were: HEV-F1 (5'-GCCAGTATCGTGTGTYC-3'), HEV-R1 (5'- TARTCARCGGTATCCTCCAAA -3'), HEV-F2 (5'-CTGG-YGTCGYTGAGGAAG-3') and HEV-R2 (5'-CAGTRAGYGAAAGCC-AAAGC-3'). The amplified RT-nPCR products were analysed using gel electrophoresis and visualised using gel Doc (Bio RAD), with a final amplification product of 638 bp.

ELISA was used for HEV IgG antibody (HEV IgG) detection (Wantai Biological Pharmaceutical Co., Ltd, Beijing, China). All serum samples were tested for anti-HEV.

2.6 | Serum transaminase level detection

ALT, AST and ALP levels in the serum samples were measured by a blood biochemical analyser (Tekang Science and Technology Co., Ltd., Jiangxi, China).

TABLE 1 HEV RNA quantification in samples from Group 1 rats

dpi	0	7	14	21	28	35	42	49	
Heart	1	-	-	-	4.64×10^2	-	7.56×10^2	-	
	2	-	-	-	3.46×10^2	-	4.12×10^2	-	
	3	-	-	-	4.60×10^2	-	6.43×10^2	-	
liver	1	-	3.95×10^3	-	-	-	-	-	
	2	-	3.64×10^3	-	-	-	-	-	
	3	-	3.86×10^3	-	-	-	-	-	
Spleen	1	-	3.91×10^3	-	3.26×10^2	2.58×10^3	-	-	
	2	-	3.62×10^3	-	5.12×10^2	3.98×10^3	-	-	
	3	-	3.78×10^3	-	4.30×10^2	3.44×10^3	-	-	
Lungs	1	-	-	-	1.08×10^3	-	6.64×10^2	-	
	2	-	-	-	2.22×10^3	-	4.13×10^2	-	
	3	-	-	-	1.19×10^3	-	3.43×10^2	-	
Kidney	1	-	3.61×10^3	2.29×10^4	-	-	1.95×10^3	-	
	2	-	3.74×10^3	3.45×10^4	-	-	1.88×10^3	-	
	3	-	3.83×10^3	3.43×10^4	-	-	2.34×10^3	-	
Brain	1	-	3.83×10^3	2.18×10^3	-	-	-	-	
	2	-	3.85×10^3	3.04×10^3	-	-	-	-	
	3	-	3.60×10^3	3.35×10^3	-	-	-	-	
Faeces	1	-	4.57×10^3	9.70×10^2	-	-	4.87×10^2	1.02×10^4	1.88×10^2
	2	-	4.26×10^3	5.10×10^2	-	-	3.55×10^2	1.18×10^4	2.01×10^2
	3	-	4.13×10^3	6.55×10^2	-	-	4.14×10^2	2.11×10^4	1.12×10^2

Real-time HEV RT-PCR results on individual faecal samples (HEV copies/g of sample) at each sampling time and from samples at necropsy; 1, 2 and 3 in the Table represent three rats that underwent the same test at different time intervals (three replicates). The data in Table 1 are the average values of three experiments. All results were analysed by SPSS and showed a Cv (coefficient variation) <1.0%. -, negative for HEV RNA quantification. Dpi, day post-infection.

2.7 | Data analysis

Statistical analyses were performed to determine the SHEV-4 infection proportions using Statistical Package for Social Sciences version 22.0 (SPSS, Inc., Chicago, IL, US) and GraphPad Prism 5.01. Bio-Rad CFX Manager 3.0 and LightCycler 96 SW 1.1 were used to analyse the real-time PCR results.

3 | RESULTS

3.1 | HEV RNA detection

HEV infection data for real-time RT-PCR on faecal samples and organs are presented in Table 1. In our trial, all Group 1 animals were infected by HEV. None of the Groups 2 and 3 rats excreted HEV from day 7 to 49. Inoculated animals started to shed HEV from 7 to 14 dpi and from 35 to 49 dpi. At the necropsy stage, all organs contained HEV RNA at different stages (Table 1).

TABLE 2 Minus-strand HEV RNA detection results in samples from Group 1 rats

Dpi		0	7	14	21	28	35	42	49
Heart	1	-	-	-	-	-	-	-	-
	2	-	-	-	-	-	-	-	-
	3	-	-	-	-	-	-	-	-
Liver	1	-	-	-	-	-	-	-	-
	2	-	-	-	-	-	-	-	-
	3	-	-	-	-	-	-	-	-
Spleen	1	-	-	-	-	-	-	-	-
	2	-	-	-	-	-	-	-	-
	3	-	-	-	-	-	-	-	-
Lung	1	-	-	-	-	-	-	-	-
	2	-	-	-	-	-	-	-	-
	3	-	-	-	-	-	-	-	-
Kidney	1	-	-	-	-	-	-	-	-
	2	-	-	-	-	-	-	-	-
	3	-	-	-	-	-	-	-	-
Brain	1	-	-	-	-	-	-	-	-
	2	-	-	-	-	-	-	-	-
	3	-	-	-	-	-	-	-	-
Faeces	1	N	N	N	N	N	N	N	N
	2	N	N	N	N	N	N	N	N
	3	N	N	N	N	N	N	N	N

Minus-strand HEV RNA RT-nPCR results on individual faecal samples at each sampling time and from samples at necropsy; 1, 2 and 3 in Table represent three rats that underwent the same test at different time intervals (three replicates).+, positive for minus-strand HEV RNA; -, negative for minus-strand HEV RNA; N, not detected; dpi, day post-infection.

3.2 | Minus-strand HEV RNA detection in Group 1

Minus-strand HEV RNA data for Group 1 by RT-nPCR on fecal samples and organs are presented in Table 2. In this trial, all Group 1 animals were infected with minus-stranded HEV RNA. At the necropsy stage, all organs contained minus-strand HEV RNA at different stages (Table 2). Therefore, we can confirm that the virus actively replicates in those tissues.

3.3 | Estimation of time to HEV seroconversion

Detection of anti-HEV antibodies was performed on all groups of three animals until 49 dpi. None of the Groups 2 and 3 animals showed

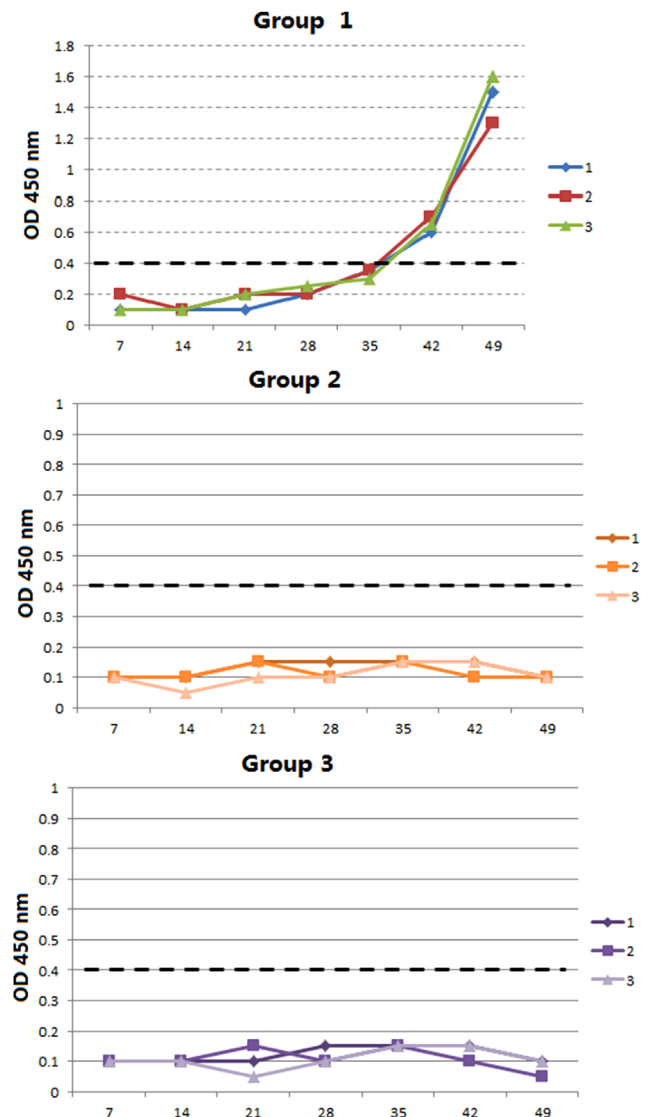


FIGURE 1 HEV serology results on individual sera samples from Groups 1, 2 and 3 rats. Optical density (450 nm) values from the ELISA test, HEV 0.4 v per animal, with three animals of each group at different stages after infection. For each group, the cut-off value is indicated by a dashed black line. The results are the average values of three experiments. All results were analysed by SPSS and showed a Cv (coefficient variation) < 1.0%

TABLE 3 Serum transaminase detection results from rats in Groups 1, 2 and 3

dpi	0	7	14	21	28	35	42	49
ALT (U/L)								
Group 1	33	33.5	33.8	67.5	82.3	60.3	63.9	55.8
Group 2	45.6	50.6	55.5	57.4	48.6	49.9	53.4	54.5
Group 3	38.5	34.3	42.6	44	43.5	40.6	41.8	45.4
AST (U/L)								
Group 1	90	85.5	91.4	125.3	111.3	132.1	65.6	60.2
Group 2	110	121	139.7	119.9	120	115	124	117
Group 3	115	132	122	134	140	136	123	130
ALP (U/L)								
Group 1	252	260	272.6	323.2	244.1	397.6	335.4	317.1
Group 2	222	280	318	224	275	311	256	251
Group 3	231	240	225	258	309	318	295	237

The reference range of alanine aminotransferase (ALT) is from 33.0 to 98.7 U/L; b: the reference range of aspartate aminotransferase (AST) is from 69.5 to 210.0 U/L; and c: the reference range of alkaline phosphatase (ALP) is from 40.0 to 190.0 U/L. The reference range is indicated by a dashed black line. The results are the average values of three experiments. All results were analysed by SPSS and showed a Cv (coefficient variation) <1.0%.

anti-HEV antibody responses. Serum samples from Group 1 had anti-HEV antibodies between 42 and 49 dpi (Figure 1).

3.4 | Changes in serum transaminases

The detection of serum transaminases was performed on all groups of animals until 49 dpi (Table 3). The ALT values of rats in Groups 1, 2, and 3 were all within the reference range from 0 to 49 dpi. The ALT values of Groups 2 and 3 showed no significant changes at different time points, while the ALT value of Group 1 increased significantly during 14 to 28 dpi and decreased significantly between 28 and 35 days. The AST values of rats in Groups 2 and 3 were all within the reference range between 0 and 49 dpi, while the AST values of rats in Group 1 increased significantly between 14 and 21 dpi and decreased significantly between 35 and 42 dpi. The AST values were below the reference range at 49 dpi. The ALP values for all rats in the three groups were not within the reference range (Figure 2).

3.5 | Histological lesions

The pathological changes in various tissues were determined by microscopy. The lesions observed in the heart, liver, spleen, lungs and kidney were different in the Group 1 rats at 0 and 49 dpi (Figures 3–7). No significant pathological changes were found in the heart, liver, spleen, lungs and kidney of rats in Group 2 (Figure 8) and Group 3 (Figure 9).

Lesions in the heart were not observed (Figure 3). A hepatic examination revealed features characteristic of hepatitis in a number of liver

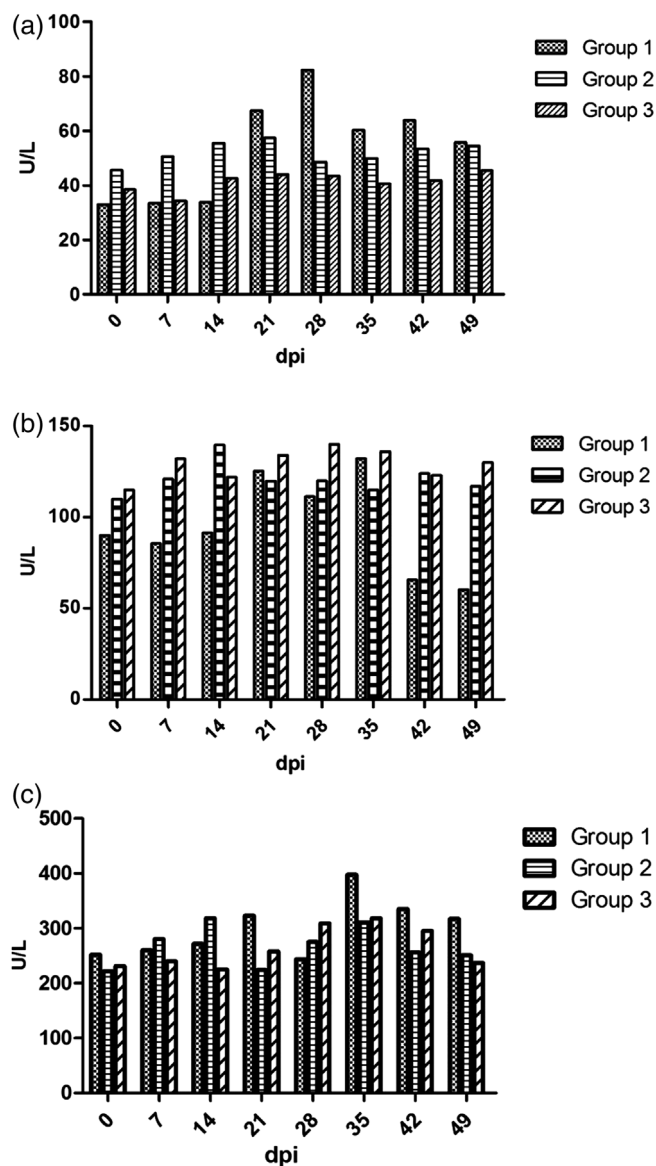


FIGURE 2 Changes in ALT, AST and ALP levels from Groups 1, 2 and 3 rats. The dotted histogram represents Group 1, the horizontal histogram represents Group 2, and the slashed histogram represents Group 3. (a) The reference range of alanine aminotransferase (ALT) is 33.0 to 98.7 U/L; (b) the reference range of aspartate aminotransferase (AST) is 69.5 to 210.0 U/L; and (c) the reference range of alkaline phosphatase (ALP) is 40.0 to 190.0 U/L

samples including congestion, vacuolization, swelling, deformation and necrosis (Figure 4). Hepatocytes showed punctate necrosis at 7 dpi (Figure 4B). A small number of neutrophils infiltrated the liver sinus at 14 dpi (Figure 4C). Some liver cells showed focal necrosis, with shrinkage or dissolution of the nuclei at 7 and 49 dpi (Figure 4B, H). The liver cells were observed to have vacuolated degeneration, swelling and deformation at 7, 14 and 49 dpi (Figure 4B, C, H).

Lymphocytes in the splenic nodules were slightly decreased in the white pulp area at 14 and 21 dpi (Figure 5C, D). Lymphocytes in the splenic nodules of the white marrow area were significantly reduced, while the macrophages were increased at 35 dpi (Figure 5F). A small

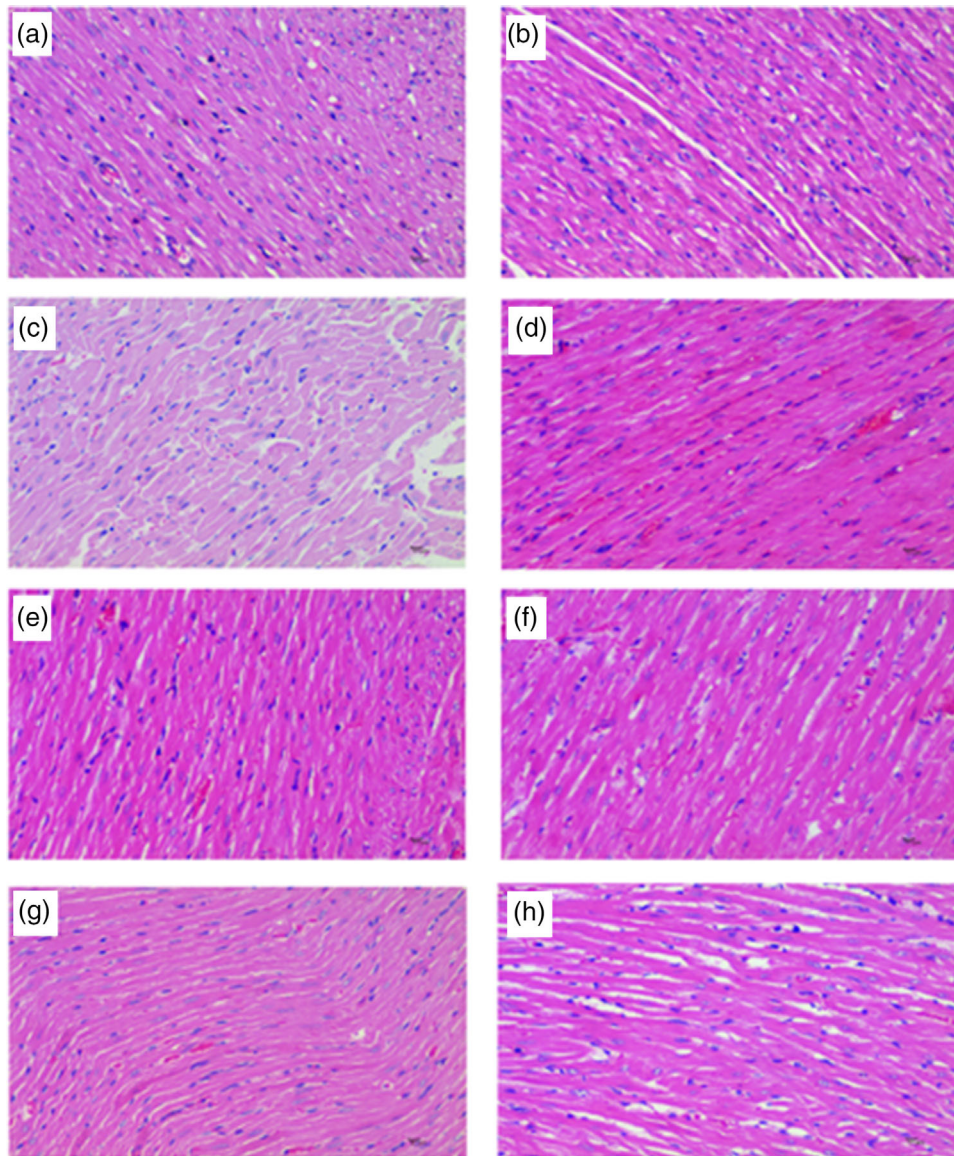


FIGURE 3 Heart histological lesions of rats from Group 1. a, b, c, d, e, f, g and h are heart lesions on 0, 7, 14, 21, 28, 35, 42 and 49 dpi, respectively. HE. 400 ×

number of neutrophils infiltrated the red pulp region from 35 to 49 dpi (Figure 5F–H).

The lung lesions were characterised by haemorrhage, inflammation and fibrosis in the middle stage of infection. The perivascular stroma was slightly oedematous, the connective tissue was loosely arranged, the stroma was widened and a small amount of fibrous tissue hyperplasia was seen at 14 dpi (Figure 6C). A small amount of fibrous tissue proliferated. A small number of inflammatory cells infiltrated the lungs at 21 dpi including neutrophils and monocytes (Figure 6D).

The main lesions of the kidney were degeneration and congestion. A small number of renal tubular epithelial cells showed slight degeneration at 28 dpi (Figure 7E). The glomeruli were slightly enlarged and the basement membrane of the capillaries was slightly thickened at 35 dpi (Figure 7F). In the interstitium, in addition to blood vessel dilation and

congestion, new capillaries and an increased number of adipocytes were observed at 42 dpi (Figure 7G).

4 | DISCUSSION

As HEV is easily degraded and inactivated and an effective cell culture system for HEV is not available, few in-depth studies have been performed for HEV. Laboratory rats and European rabbits have become the potential animal models for different HEV strains. The study has shown that only two of nine rabbits inoculated with HEV-4 became infected (Ma et al. 2010). There are studies that show that Wistar rats seemed resistant to intravenous inoculation of HEV-4 derived from wild boar (Schlosser et al., 2018). There have been no reported cases of SHEV-4 infection in SD rats by intra-peritoneal injection. After

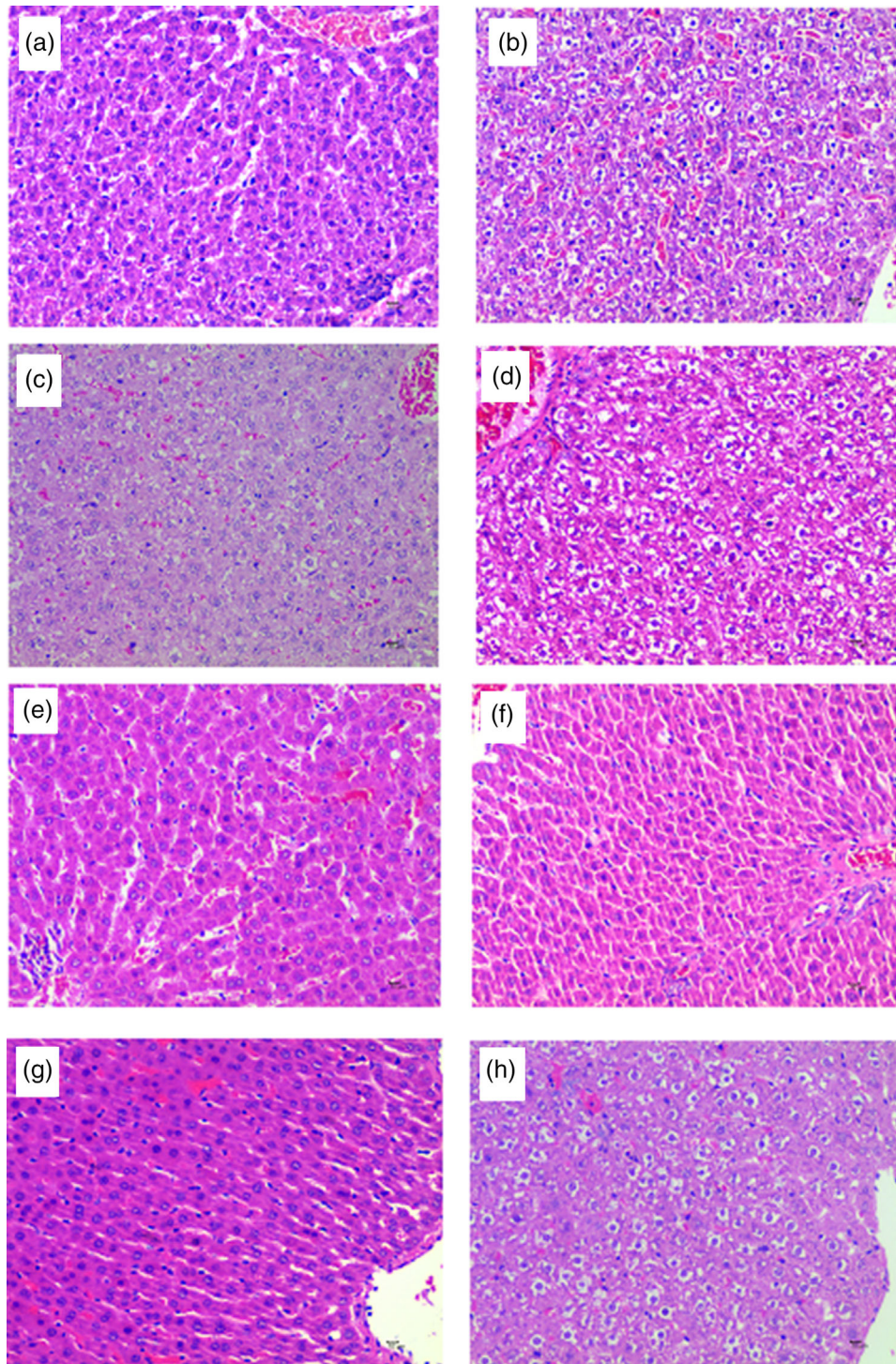


FIGURE 4 Liver histological lesions of rats from Group 1. Pathological changes were characterised by congestion, vacuolization and necrosis. a, b, c, d, e, f, g and h are liver lesions on 0, 7, 14, 21, 28, 35, 42 and 49 dpi, respectively. HE. 400 ×

the 20th century, SD rats were used in various fields of life science research, especially in oncology, pharmacology, toxicology, endocrinology and nutrition. Establishing persistent HEV infection in laboratory rats had been challenging. Studies have shown that intra-peritoneal injection can better mimic the direction of blood flow into the liver during the natural HEV infection route than the intravenous route (Mao et al., 2014). SD rats, which present wide sources and high reproduc-

tive rates, can be used as an animal model for HEV infection. Therefore, SD rats are widely available, have high growth rates and high reproduction rates and can be used as a potential animal model for HEV infection.

In this study, the SD rats inoculated with swine HEV faecal suspension by intra-peritoneal injection did not have clinical symptoms of hepatitis E or abnormal reactions. After the SD rats were vaccinated with

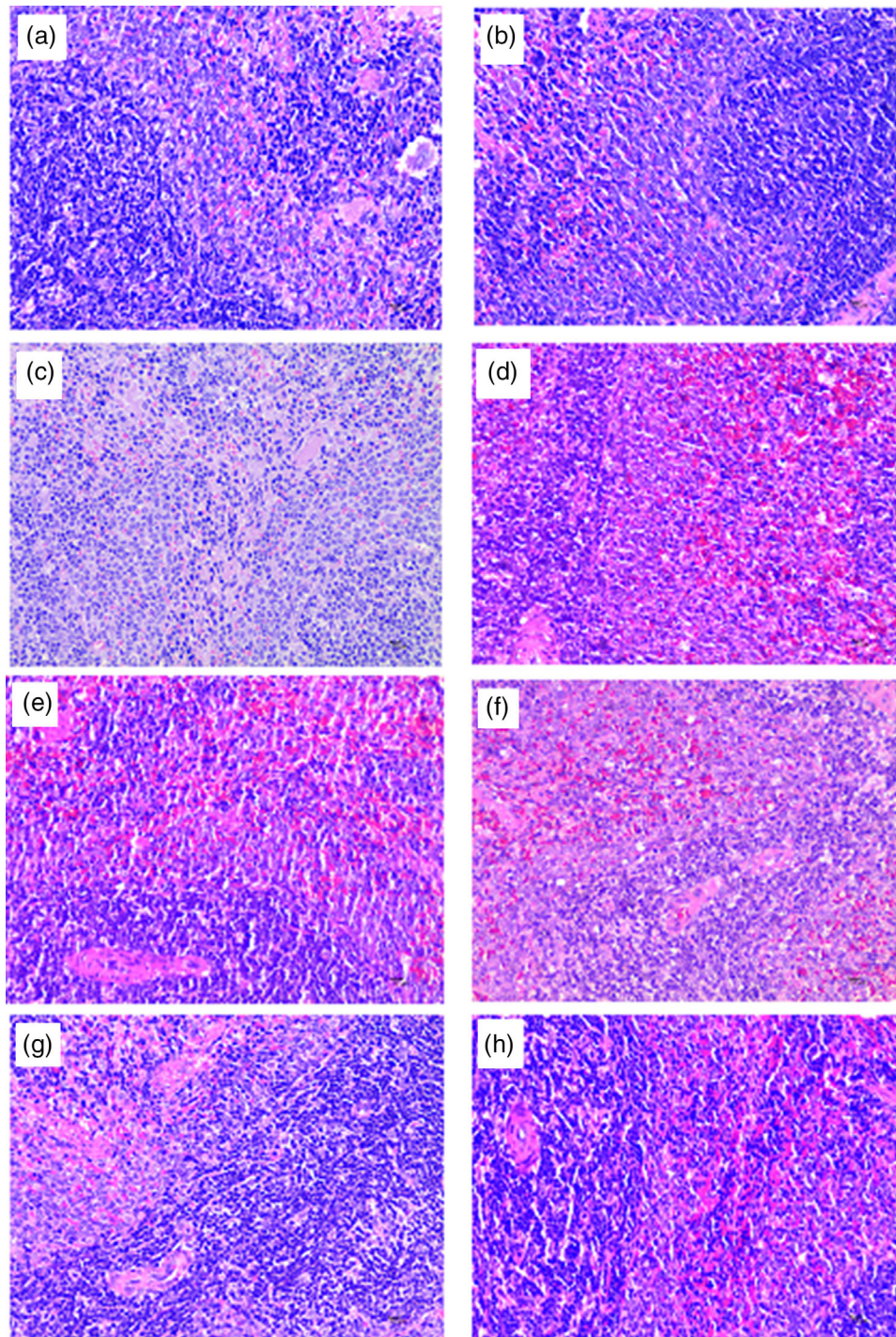


FIGURE 5 Splenic histological lesions of rats from Group 1. Pathological changes were characterised by inflammation. a, b, c, d, e, f, g and h are splenic lesions on 0, 7, 14, 21, 28, 35, 42 and 49 dpi, respectively. HE. 400 ×

a peritoneal suspension of swine HEV, HEV RNA was detected in the faeces from 7 to 14 dpi and 35 to 49 dpi. HEV RNA was detected in the liver at 7 dpi. The liver, heart, spleen, lung, kidney and brain harboured HEV RNA at different time points, indicating that all tissues and organs can be infected with HEV. Recently, several cases of HEV infection have been reported in the human nervous system, especially in the brain, with corresponding neurological symptoms; however, there have

been no reports of HEV infection of the nervous system in rats. Because HEV RNA was detected in the brain, the results of this experiment indicate that HEV may infect the rat's nervous system. The intermittent detection of HEV RNA in tissues and organs may occur for a number of reasons, such as the virus invading the body, individual organs having an immune response at different times, the activity of lymphocytes that can destroy pathogens and the easy degradation and instability of

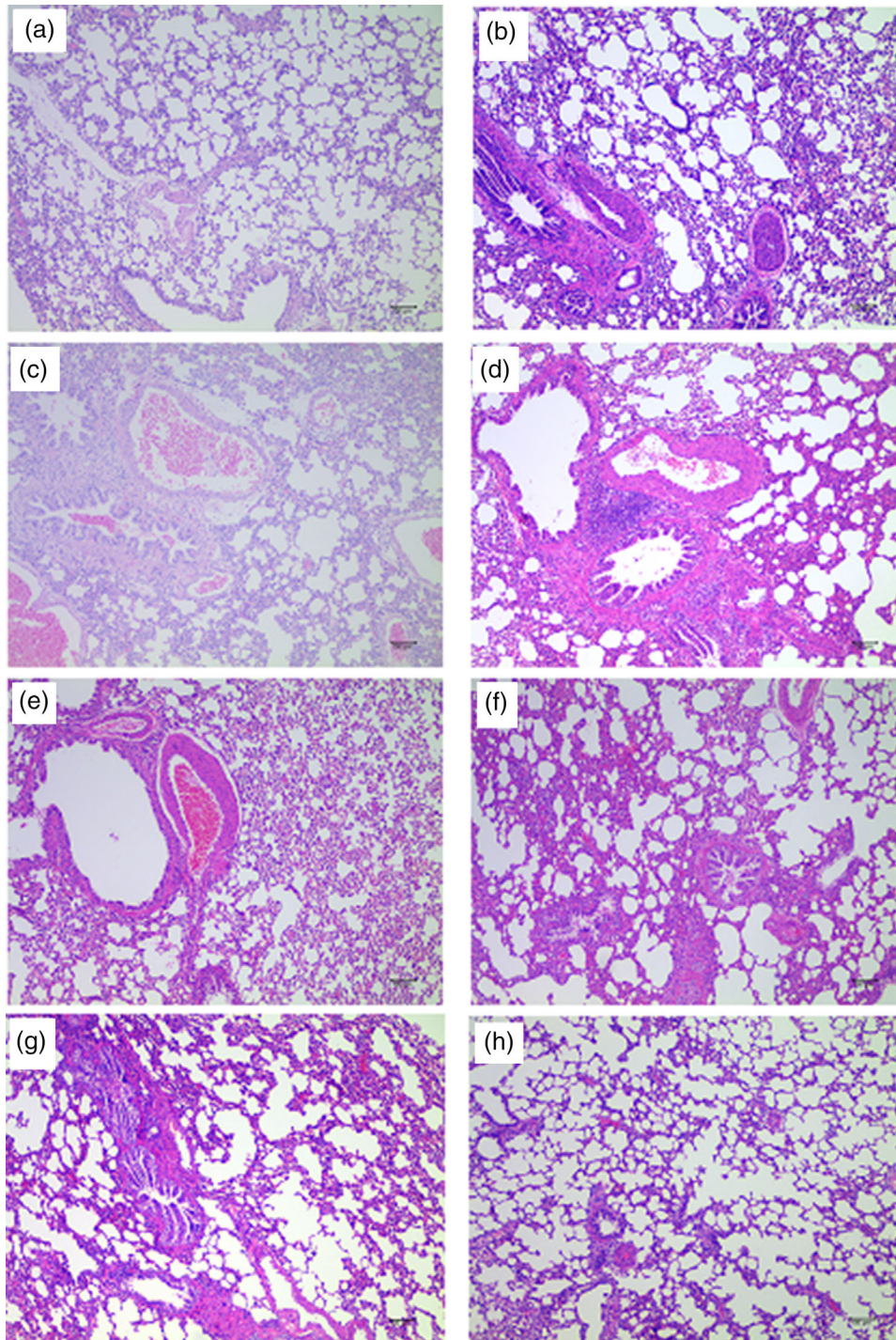


FIGURE 6 Lung histological lesions of rats from Group 1. Pathological changes were characterised by haemorrhage, inflammation and fibrosis. a, b, c, d, e, f, g and h are lung lesions on 0, 7, 14, 21, 28, 35, 42 and 49 dpi, respectively. HE. 100 ×

the HEV pathogen itself causing HEV RNA to be undetectable at some stages. In addition, the virus may infect organs and tissues at different time points and may show tissue tropism; thus, the number of virions in a given organ may differ or be completely absent depending on the stage, resulting in no detectable HEV RNA.

The antigen of swine HEV can be detected in serum about 14 days after contact with infected pigs, and can last for 14 days (Bouwknegt

et al., 2009). Antibody detection was performed in the three groups of rats. The results showed that HEV IgG was detected at 35 dpi in rats vaccinated with porcine HEV faecal suspension and consistently reached 49 dpi, indicating that the immune response began to occur in the rats at 35 dpi after inoculation with swine HEV faecal suspension. The results of HEV RNA detection also showed that from 42 to 49 dpi, tissues or organs of the rats did not harbour HEV RNA except for

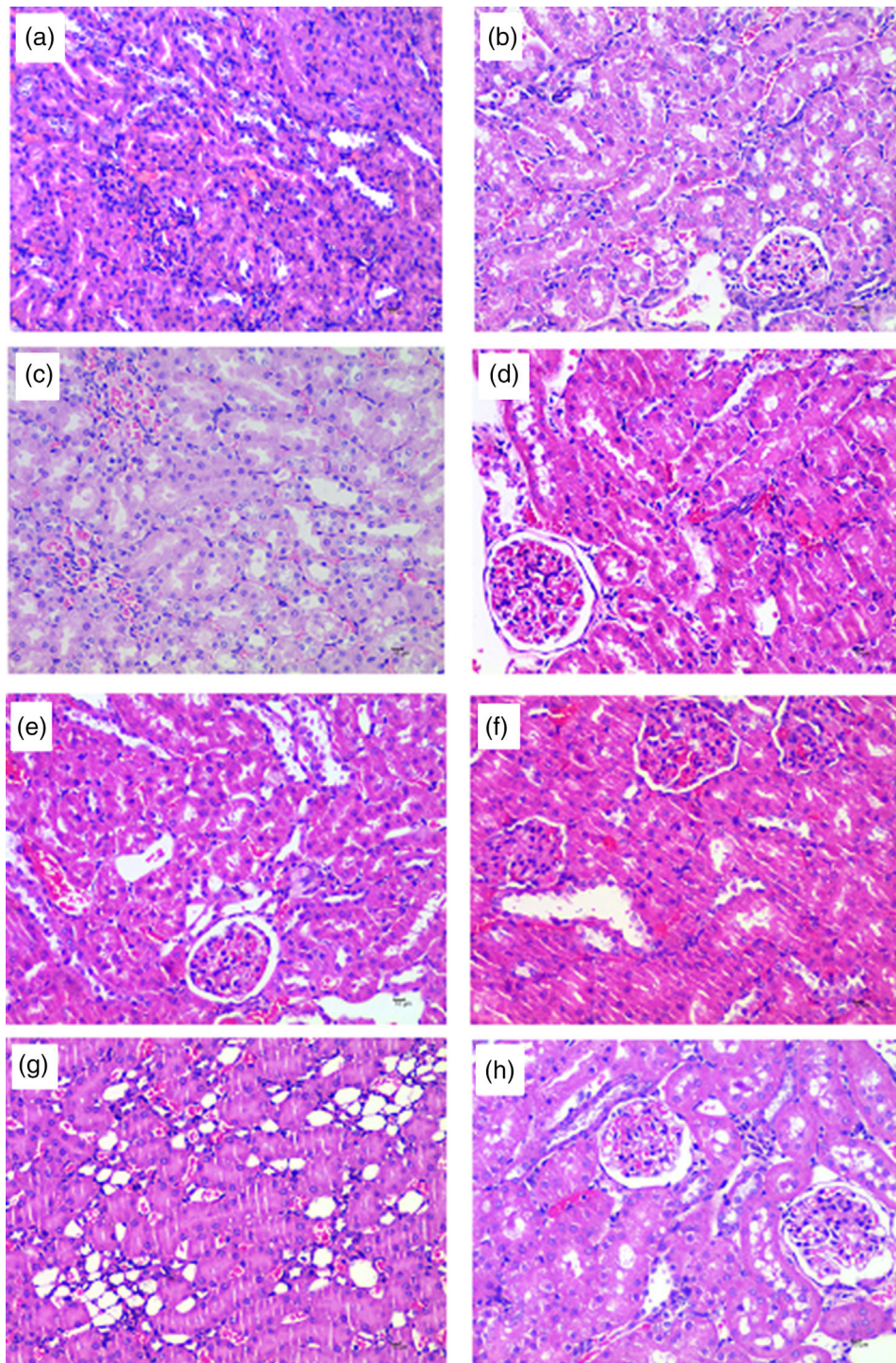


FIGURE 7 Kidney histological lesions of rats from Group 1. Pathological changes were characterised by degeneration and congestion. a, b, c, d, e, f, g and h are kidney lesions on 0, 7, 14, 21, 28, 35, 42 and 49 dpi, respectively. HE. 400 ×

faeces. This indicates that serum antibodies can be produced during exposure to antigens in animals, and investigations have also shown that human beings experiencing self-limited hepatitis E can produce higher antibody levels and effectively protect them from HEV outbreak areas (Lee et al., 2016).

The serum ALT and AST levels of SD rats inoculated with HEV in pigs showed an overall increasing and then decreasing trend. The serum

ALT and AST levels were highest at 28 and 35 dpi, and AST levels dropped below the reference range at 49 dpi, the results indicated that the liver function of rats infected with swine HEV could recover naturally. ALT and AST are important serum enzymes that can sensitively reflect liver cell damage and the degree of injury. Hepatocyte damage is the main reason for an elevation in ALT and AST. Serum ALT is sensitive to all kinds of acute viral hepatitis and drugs or alcohol-induced liver

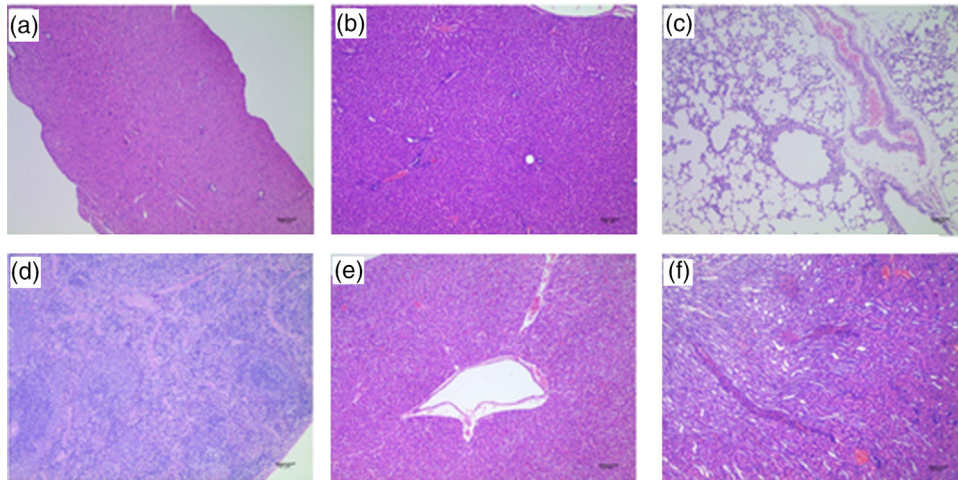


FIGURE 8 Partial histological lesions in organs of rats from Group 2. No significant pathological changes were found in the heart, liver, spleen, lung and kidney. a, b, c, d, e and f are heart, liver, lung, spleen, liver and kidney lesions at the research stage, respectively. HE. 100 ×

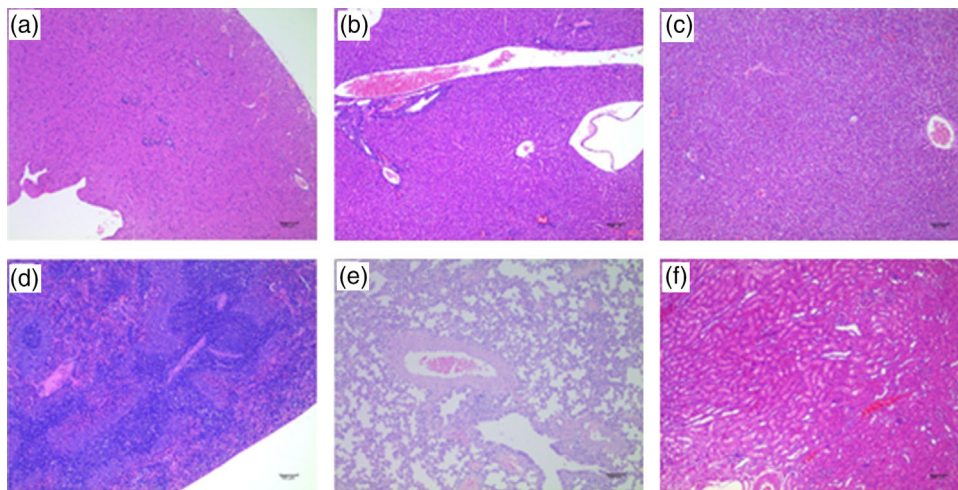


FIGURE 9 Partial histological lesions in organs of rats from Group 3. No significant pathological changes were found in the heart, liver, spleen, lung and kidney. a, b, c, d, e and f are heart, liver, liver, spleen, lungs and kidney lesions at the research stage, respectively. HE. 100 ×

cell injury. ALT rises sharply before clinical symptoms, such as jaundice and AST, increase. However, an elevation in AST is not as appropriate as an elevation in ALT (Wang, 2005). The changes in ALT and AST in this study showed that the hepatocytes of the rats that were inoculated with porcine HEV faecal suspension were damaged, probably due to the viral hepatitis, which is inconsistent with the changes in ALT and AST in the serum of SD rats that were infected with HEV genotype IV by (Gong et al., 2012). The main reason for the differences may be different inoculation doses or physical conditions of the rats. Slight histological changes were observed after viral infection, but ALT and AST levels in Groups 1, 2 and 3 rats were within the reference range. This may be due to the weak pathogenicity of the HEV virus, in which most animal infections are sub-clinical; in the SHEV rat infection model, organs other than the liver do not show significant lesions and the pathological changes in the liver are also mild, indicating the low pathogenicity of the SHEV rat model. The result is consistent with Li(JT

L, 2014). In this study, the levels of ALP in the rats of the three groups exceeded the reference range; therefore, this part of the experimental data was not worth analysing. ALP was generally higher than the reference range due to two potential factors: a physiological increase and a pathological increase. All the rats in this study were SPF rats and a pathological increase was, therefore, not considered, suggesting a potential physiological cause (Nicole et al., 2007). The rats weight was approximately 80 g at the start of this study and the rats gained weight quickly during the research stage. At this stage, the rats were in a physiological period of skeletal development, which may cause ALP to be higher than the reference level even at 0 dpi.

Under light microscopy, the lesions in each tissue were relatively slight and were relatively serious at 49 dpi. A small amount of hepatocyte degeneration could be seen in the liver of some animals in this experiment, which may have been caused by incomplete fasting and excessive hepatic glycogen in the liver before necropsy.

The vacuolar degeneration of hepatocytes and neutrophil infiltration in the liver sinusoids may be related to environmental factors such as hypoxia. Certain pathological changes, such as hepatocellular necrosis, are considered chronic hepatitis symptoms and may be related to HEV infection. There are many enzymes in the liver including RNase. In the early stage of infection, the virus number is greatly increased, but some of the RNA is degraded by RNase, and therefore, only a small amount of RNA can be detected in the liver in the initial stage. In the middle and late stages of infection, the enzyme will degrade a large amount of RNA, and at these time points, the liver has developed an immune response due to the viral infection along with other pathological changes. At this time, the liver has accumulated much pathological damage and the process is irreversible. Therefore, RNA is not detected in the middle and late stages of infection, but pathological changes are readily observed due to hepatitis. The splenic lymphocyte counts in certain animals in this study were reduced, and a small amount of neutrophilic infiltration in the red pulp may be caused by environmental factors, such as a stress response, which result in changes in the immune function of the animals and is not related to inoculation. Certain animals had slight bleeding in the lung tissue, which may have been caused by improper dissection. The lung interstitium was slightly widened and a small amount of inflammatory cell infiltrate was observed, which was not related to HEV challenge. In the kidney tissue of some animals, occasional cytoplasmic staining of tubular epithelial cells was observed and a small number of cells were detached, which may be due to artefacts caused by tissue fixation and the production process. New capillaries were produced in the kidney interstitium, likely due to differences in individual animals. In summary, after inoculation with a swine HEV faecal suspension in SD rats, only the liver showed pathological changes of chronic hepatitis, and other tissues did not show obvious lesions at different stages due to HEV challenge.

In conclusions, the positive rate of HEV RNA in faeces and tissues and organs indicated that SHEV-4 was successfully infected by intraperitoneal injection in rats. After infection, the excretion of virus with faeces in rats was delayed, and the production time of HEV antibody was longer, and the level of ALT and AST showed a trend of increasing at first and then decreasing. Furthermore, we detected HEV RNA in the brain of rats infected with SHEV-4 for the first time, suggesting that SHEV-4 may infect the nervous system of rats. This is of great significance for the study of the mechanism of HEV infection and the damage effect on the body.

ACKNOWLEDGEMENTS

We thank Prof. Zhu for her insightful comments on the design of the study. This study was supported by the Research and Integration Demonstration of Key Technologies for Improving Quality and Efficiency of Sichuan Pig Industry Chain Grant number 2020YFN0147, the Program Sichuan Veterinary Medicine and Drug Innovation Group of China Agricultural Research System (CARS-SVDIP), the Sichuan Science and Technology Plan Program (Grant number 2017NZ0038) and the Sichuan Science and Technology Support Program (Grant number 2016NY0052).

CONFLICT OF INTEREST

The authors declare no any non-financial or financial competing interests.

ETHICS STATEMENT

The animal protocols and all procedures of the experiment were performed in compliance with the laws and guidelines of Sichuan Agricultural University Animal Care and Use Committee.

AUTHOR CONTRIBUTIONS

Zhijie Jian designed the study and wrote the manuscript. Youyou Li and Jun Zhao coordinated the sample acquisition. Fengqin Li and Huidan Deng prepared and performed the experiments. Zhijie Jian, Zhiwen Xu and Youyou Li contributed to the acquisition of clinical data. Xiang-gang Sun and Ling Zhu analysed the clinical and experimental data. All authors reviewed and approved the manuscript.

DATA AVAILABILITY STATEMENT

All data generated or analysed during this study are included in this published article.

PEER REVIEW

The peer review history for this article is available at <https://publons.com/publon/10.1002/vms3.707>

ORCID

Zhijie Jian  <https://orcid.org/0000-0001-6178-496X>

Jun Zhao  <https://orcid.org/0000-0002-5804-6816>

Ling Zhu  <https://orcid.org/0000-0002-2682-3465>

REFERENCES

- Bouwknegt, M., Rutjes, S., Reusken, C., Stockhofe-Zurwieden, N., Frankena, K., De Jong, M., & Poel, W. (2009). The course of hepatitis E virus infection in pigs after contact-infection and intravenous inoculation. *BMC Veterinary Research*, 5, 7.
- Boxall, E., Herborn, A., Kochethu, G., Pratt, G., Adams, D., Ijaz, S., & Teo, C. G. (2006). Transfusion-transmitted hepatitis E in a 'nonhyperendemic' country. *Transfusion Medicine*, 16(2), 79–83.
- Colson, P., Coze, C., Gallian, P., Henry, M., De Micco, P., & Tamalet, C. (2007). Transfusion-associated hepatitis E, France. *Emerging Infectious Diseases*, 13, 648–649.
- Cossaboom, C. M., Cordoba, L., Sanford, B. J., Pineyro, P., Kenney, S. P., Dryman, B. A., & Meng, X. J. (2012). Cross-species infection of pigs with a novel rabbit, but not rat, strain of hepatitis E virus isolated in the United States. *Journal of General Virology*, 93(Pt 8), 1687–1695.
- Dalton, H. R., Kamar, N., & Izopet, J. (2014). Hepatitis E in developed countries: current status and future perspectives. *Future Microbiology*, 9, 1361–1372.
- Emerson, S., Arankalle, V., & Purcell, R. (2005). Thermal stability of hepatitis E virus. *Journal of Infectious Diseases*, 192, 930–933.
- Gong, G., Hua, G. X., Zhang, W., Huang, F., Suo Lang, S. Z., & Cui, L. (2012). Establishment of SD rats model infected with Hepatitis E Virus (in chinese). *Heilongjiang Animal Science and Veterinary Medicine*, 166–167.
- Hiroyuki, M., Katsuo, O., Kazuaki, T., & Shunji, M. (2003). Severe hepatitis E virus infection after ingestion of uncooked liver from a wild boar. *Journal of Infectious Diseases*, 188(6), 944.

- He, J., Innis, B.L., Shrestha, M.P., Clayton, E.T., & David, W.V. (2002). Evidence that rodents are a reservoir of hepatitis E virus for humans in Nepal. *Journal of Clinical Microbiology*, *40*, 4493–4498.
- Huang, F., Li, Y., Yu, W., Jing, S., Wang, J., Long, F., & Pan, Q. (2016). Excretion of infectious hepatitis E virus into milk in cows imposes high risks of zoonosis. *Hepatology*, *64*, 350–359.
- Jothikumar, N., Cromeans, T. L., Robertson, B. H., Meng, X. J., & Hill, V. R. (2006). A broadly reactive one-step real-time RT-PCR assay for rapid and sensitive detection of hepatitis E virus. *Journal of Virological Methods*, *131*, 65–71.
- Khuroo, M. S., Kamili, S., & Khuroo, M. S. (2010). Clinical course and duration of viremia in vertically transmitted hepatitis E virus (HEV) infection in babies born to HEV-infected mothers. *Journal of Viral Hepatitis*, *16*(7), 519–523.
- Kitaura, S., Wakabayashi, Y., Okazaki, A., Okada, Y., & Moriya, K. (2020). The first case report of acute symptomatic HEV genotype 4 infection in an HIV-positive patient in Japan. *Internal Medicine*, *59*(13), 4505–4520.
- Lee, G. Y., Poovorawan, K., Intharasongkroh, D., Sa-Nguanmoo, P., Vongpunsawad, S., Chirathaworn, C., & Poovorawan, Y. (2015). Hepatitis E virus infection: Epidemiology and treatment implications. *World Journal of Virology*, *4*, 343–355.
- Lee, G. H., Tan, B. H., Teo, E. C., Lim, S. G., Dan, Y. Y., Wee, A., Aw, P. P., Zhu, Y., Hibberd, M.L., & Tan, C. K. (2016). Chronic infection with camelid hepatitis E virus in a liver-transplant recipient who regularly consumes camel meat and milk. *Gastroenterology*, *150*(2), 355–357.
- Li, J. T. (2014). *Epidemiological investigation of hepatitis E in Kunming area and establishment of animal models for hepatitis E virus infection in chinese.*
- Li, Y. Y., Gong, S. Y., Li, X. J., Mao, X. Y., Deng, Y. C., & Zhu, L. (2017). Development and application of a SYBR Green II real-time RT-PCR for detection of swine hepatitis E virus in chinese. *Chinese Journal of Zoonoses*, *1002–1006*.
- Mao, J., Zhao, Y., She, R., Cao, B., Xiao, P., Qiaoxing, W., & Soomro, M. (2014). Detection and localization of rabbit hepatitis E virus and antigen in systemic tissues from experimentally intraperitoneally infected rabbits. *Plos One*, *9*, e88607.
- Meng, X. J. (2013). Zoonotic and foodborne transmission of hepatitis E virus. *Seminars in Liver Disease*, *33*, 041–049.
- Ma, H., Zheng, L., Liu, Y., Zhao, C., Harrison, T.J., Ma, Y., Sun, S., Zhang, J., & Wang, Y. (2010). Experimental infection of rabbits with rabbit and genotypes 1 and 4 hepatitis E viruses. *PLoS ONE*, *5*, e9160.
- Mitsui, T., Tsukamoto, Y., Yamazaki, C., Masuko, K., Tsuda, F., Takahashi, M., & Okamoto, H. (2004). Prevalence of hepatitis E virus infection among hemodialysis patients in Japan: Evidence for infection with a genotype 3 HEV by blood transfusion. *Journal of Medical Virology*, *74*, 563–572.
- Miyashita, K., Kang, J. H., Saga, A., Takahashi, K., Shimamura, T., Yasumoto, A., & Uchida, T. (2012). Three cases of acute or fulminant hepatitis E caused by ingestion of pork meat and entrails in Hokkaido, Japan: Zoonotic foodborne transmission of hepatitis E virus and public health concerns. *Hepatology Research*, *42*, 870–878.
- Mushahwar, I. K. (2008). Hepatitis E virus: Molecular virology, clinical features, diagnosis, transmission, epidemiology, and prevention. *Journal of Medical Virology*, *80*, 646–658.
- Nicand, E., Armstrong, G. L., Enouf, V., Guthmann, J. P., Guerin, J.-P., Caron, M., & Andraghetti, R. (2005). Genetic heterogeneity of hepatitis E virus in Darfur, Sudan, and neighboring Chad. *Journal of Medical Virology*, *77*, 519–521.
- Nicole, J., & Fernandez, B. A. (2007). Kidney. Alkaline phosphatase: beyond the liver. *Veterinary Clinical Pathology*, *36*(3), 223–233.
- Pavio, N., Meng, X. J., & Renou, C. (2010). Zoonotic hepatitis E: animal reservoirs and emerging risks. *Veterinary Research*, *41*, 46.
- Saad, M. D., Hussein, H. A., Bashandy, M. M., Kamel, H. H., Earhart, K. C., Fryauff, D. J., & Mohamed, A. H. (2007). Hepatitis E virus Infection in work horses in Egypt. *Infection Genetics & Evolution*, *7*, 368–373.
- Schlauder, G. G., Dawson, G. J., Erker, J. C., Kwo, P. Y., Knigge, M. F., Smalley, D. L., & Mushahwar, I. K. (1998). The sequence and phylogenetic analysis of a novel hepatitis E virus isolated from a patient with acute hepatitis reported in the United States. *Journal of General Virology*, *79*, 447–456.
- Schlauder, G. G., & Mushahwar, I. K. (2001). Genetic heterogeneity of hepatitis E virus. *Journal of Medical Virology*, *65*, 282–292.
- Schlosser, J., Daehner, L., Dremsek, P., Tauscher, K., Fast, C., Ziegler, U., & Eiden, M. (2018). Different outcomes of experimental hepatitis E virus infection in diverse mouse strains, wistar rats, and rabbits. *Viruses*, *11*, 1.
- Tokita, H. (2003). Molecular and serological characterization of sporadic acute hepatitis E in a Japanese patient infected with a genotype III hepatitis E virus in 1993. *Journal of General Virology*, *84*, 421.
- Wang, J. D. (2005). *Veterinary drug laboratory testing technology (in Chinese)*. China Agricultural Science and Technology Press.

How to cite this article: Jian, Z., Li, Y., Xu, Z., Zhao, J., Li, F., Deng, H., Sun, X., & Zhu, L. (2022). Research on a rat model of genotype IV swine hepatitis E virus. *Veterinary Medicine and Science*, *8*, 886–898. <https://doi.org/10.1002/vms3.707>