

A Case of Community-acquired Bacteremic Empyema Caused by *Kocuria kristinae*

Ka Young Kim, Jae Hyun Cho, Chang Min Yu, Kyung Jin Lee, Jae Min Lee, Seokyoung Koh, Mingu Kwon, and Dasol Jeong

Department of Internal Medicine, National Police Hospital, Seoul, Korea

Kocuria kristinae, part of the normal flora of the skin and oral mucosa, is seldom reported as a human pathogen; infection is mostly associated with immunocompromised patients in healthcare facilities. Here, we describe the first case of bacteremic empyema caused by *K. kristinae* acquired from the community. *K. kristinae* was isolated from pleural effusion and two sets of peripheral blood samples drawn from two different sites. The empyema resolved after the insertion of a chest tube and intravenous administration of piperacillin-tazobactam and levofloxacin.

Key Words: *Kocuria kristinae*; Infection; Bacteremia; Empyema; Community-acquired Infections

Introduction

Kocuria were classically classified into the genus *Micrococcus* earlier; following taxonomic revision, they are now a member of the *Micrococcaceae* family [1]. *Kocuria* species are commensals found on human skin, mucosa, and the oropharynx. *K. kristinae* is a facultative anaerobic, non-motile, catalase-positive, coagulase-negative, and gram-positive coccus. It is an uncommon human pathogen. Only a few cases infected with *K.*

kristinae have been reported worldwide, and most were health-care-associated infections in immunocompromised patients such as those with uncontrolled diabetes, leukemia, renal failure, and malignancies with or without central-venous-catheter insertion [2-11]. Here we present the first reported case of *K. kristinae*-associated empyema and bacteremia in a well-controlled diabetic adult, which we assumed to be from the community.

Received: December 3, 2016 **Accepted:** January 18, 2017 **Published online:** November 15, 2017

Corresponding Author

Jae Hyun Cho, MD

Department of Internal Medicine, National Police Hospital, 123 Songi-ro, Songpa-gu, Seoul 05715, Korea

Tel: +82-2-3400-1516, Fax: +82-2-3400-1111

E-mail: chojh.md@gmail.com

Chang Min Yu, MD

Department of Internal Medicine, National Police Hospital, 123 Songi-ro, Songpa-gu, Seoul 05715, Korea

Tel: +82-2-3400-1517, Fax: +82-2-3400-1111

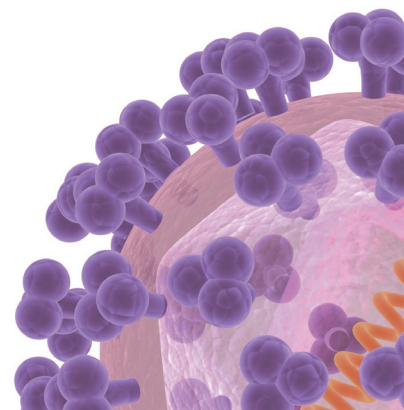
E-mail: yu0021@nph.go.kr

Jae Hyun Cho and Chang Min Yu corresponded equally to the work.

This is an Open Access article distributed under the terms of the Creative Commons Attribution Non-Commercial License (<http://creativecommons.org/licenses/by-nc/3.0>) which permits unrestricted non-commercial use, distribution, and reproduction in any medium, provided the original work is properly cited.

Copyrights © 2018 by The Korean Society of Infectious Diseases | Korean Society for Chemotherapy

www.icjournal.org



Case Report

In September 2014, a 57-year-old man visited the emergency department of National Police Hospital in Seoul, Korea. His chief complaint was dyspnea that had started two days prior. His associated symptoms were cough, sputum, left shoulder pain, diaphoresis, myalgia, fever, and a chilled sensation. He

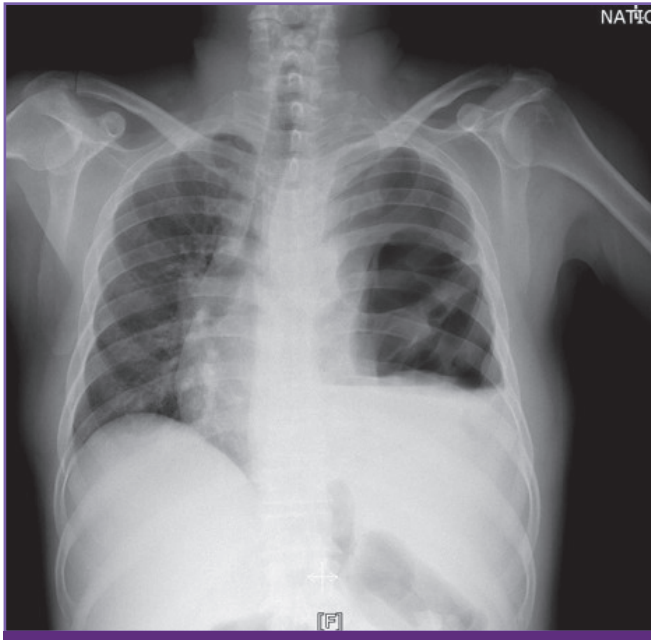


Figure 1. Chest radiograph on hospital day 1 showing left hydropneumothorax and pleural adhesion.

had well-controlled diabetes mellitus which had been diagnosed three years prior. Neither history of admission nor any intervention existed. He was a 30-pack year smoker and had been drinking an average of 100 mg of alcohol twice a week. He had no recent history of loss of consciousness or vomiting. Though he was not a heavy alcoholic, a chance of aspiration remained because he might not have remembered what happened when he was drunk. He usually worked with marble blocks as a mason, with considerable exposure to marble dust in his workplace. The patient insisted that he was always protected by an industrial mask. He reported no other medication, illicit drug, or herbal medicine use except for diabetes medication (linagliptin 2.5 mg and metformin 500 mg, once daily), which he had used ever since his diagnosis. He had no history of sexually transmitted diseases or recent sick contacts. He had traveled to a beach in Incheon one week prior and reported eating raw, unboned gizzards.

At the emergency department, the patient's initial blood pressure was 206/109 and his heart rate was 123 beats/minute. The blood pressure stabilized spontaneously within an hour, but the sinus tachycardia persisted. His body temperature was 38.2°C. A chest radiograph revealed left hydropneumothorax and pleural adhesion (Fig. 1). Low-dose chest computed tomography (CT) showed a large amount of left hydropneumothorax, multiloculated left pleural effusion, pleural adhesion, and passive atelectasis of the left lung (Fig. 2A). In enhanced images, pleural enhancement was observed (Fig. 2B). Labora-

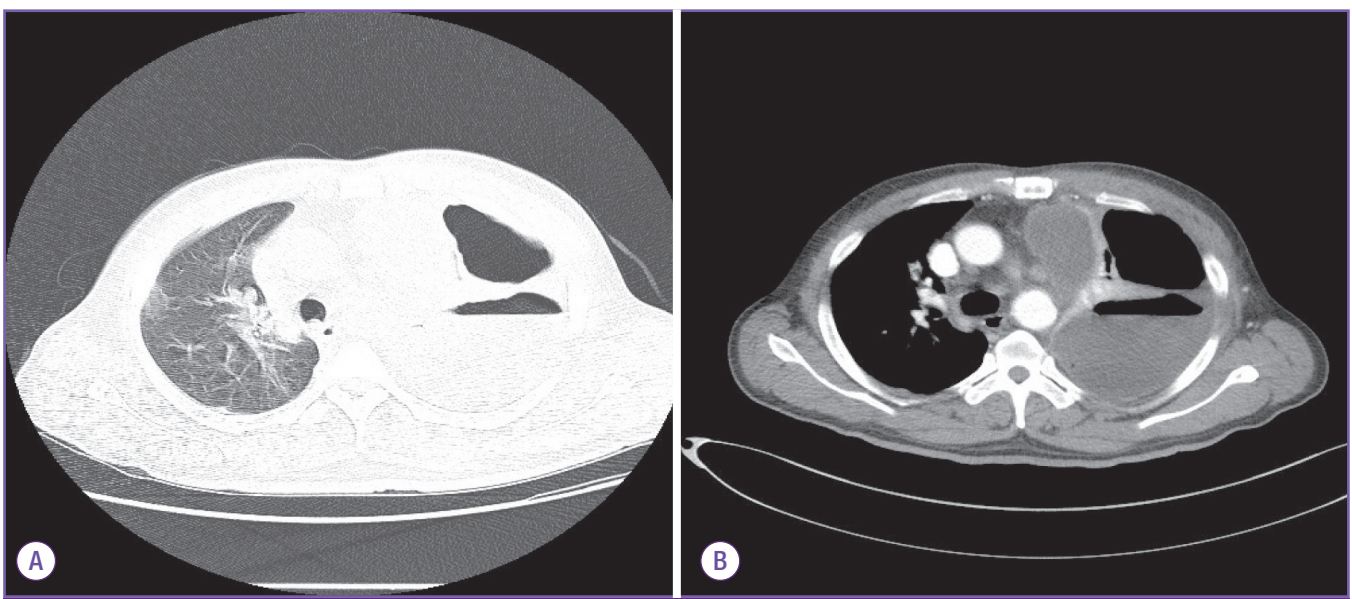


Figure 2. (A) Low-dose chest CT image on hospital day 1 showing a large amount of left hydropneumothorax, multiloculated left pleural effusion, pleural adhesion in left thorax, and passive atelectasis of the left lung. (B) Enhanced chest CT image on hospital day 1 showing a large amount of multiloculated left pleural effusion with pleural enhancement and left pneumothorax, with passive atelectasis with bronchial mucus plugging in the left lung.

tory tests revealed leukocytosis (white blood cell count: 24,300 cells/mm³) with 93 percent neutrophils. The erythrocyte sedimentation rate and C-reactive protein level were 121 mm/hr and 45.8 mg/dL, respectively. The arterial partial pressure of oxygen was 50.9 mmHg and three liters of oxygen were immediately applied by nasal prong. The hemoglobin A1c level was 6.9%. Aspartate aminotransferase, alanine aminotransferase, and total bilirubin levels were 21 IU/L, 26 IU/L, and 0.5 mg/dL, respectively. The prothrombin time was 1.18 INR and his albumin concentration was 3.0 g/dL, which was consistent with a septic condition. No other significant abnormality was seen in the chemical examinations. Two sets of blood cultures of samples drawn from two different peripheral sites were collected. A pleural fluid sample collected by thoracentesis was turbid, thick, and brownish-yellow in color. It also had a foul odor. The laboratory findings of the sample indicated exudative properties; the pleural fluid lactate dehydrogenase/serum lactate dehydrogenase was 1.08, glucose was 0 mg/dL, his white blood cell count was 2,976 cells/mm³ with uncountable segmented neutrophils, and the pH was 6.34. One set was cultured using the pleural fluid sample. On hospital day 1, intravenous ceftriaxone, levofloxacin, and clindamycin were administered under the suspicion of parapneumonic empyema due to aspiration pneumonia. A 24-French chest tube was inserted and the patient was admitted to the intensive care unit for close observation. On hospital day 2, to rule out esophageal injury-induced infection, an esophago-gastro-duodenoscopy (EGD) was performed because the patient had a history of eating unboned raw gizzard. The EGD showed no abnormalities, but the possibility of micro-rupture remained.

Three sets of culture were incubated for 24-48 hours and then inoculated to blood agar and MacConkey plates. The cultured microorganisms were gram-positive cocci, catalase-positive, and coagulase-negative. Colonies were collected from the

plates for identification using an automated system (MicroScan WalkAway 96 SI system, Siemens Healthcare Diagnostics Inc., West Sacramento, CA, USA, using conventional Pos panel). On hospital day 6, from all three culture sets, identical organism types were revealed, which were identified as *K. kristinae*. The biochemical results were negative for crystal violet, micrococcus screen, nitrate, novobiocin, indoxyl phosphatase, Voges-Proskauer, phosphatase, 40% bile esculin, L-Pyrrolidonyl-beta-naphthylamide, p-nitrophenyl-beta-D-galactopyranoside, urea, mannitol, arabinose, bacitracin, inulin, sodium chloride 6.5%, pyruvate, raffinose, ribose, and sorbitol sections of the panel. The optochin, arginine, lactose, trehalose, and mannose sections showed positive results. The overall probability of the identification was 95%.

According to the probability table of the MicroScan WalkAway 96 SI system, it was very rare for *K. kristinae* to show a negative reaction to the optochin and mannose parts of the panel, and uncommon to show a negative reaction to the trehalose part of the panel. A positive optochin reaction meant that the organism successfully grew in optochin, while positive results in the mannose and trehalose sections meant that the organism could ferment the corresponding carbohydrates and form acid metabolites. Conversely, it was very rare for *K. kristinae* to react positively to the crystal violet, novobiocin, nitrate, p-nitrophenyl-beta-D-glucuronide, phosphatase, and mannitol sections. This meant that the organism could not survive in low concentrations of crystal violet and novobiocin, could not reduce nitrate to nitrite, could not catalyze the hydrolyzation of p-nitrophenyl-beta-D-galactopyranoside, did not produce alkaline phosphatase, and could not ferment mannitol, respectively. Other sections of the panel may show variable results (MicroScan WalkAway 96 SI system, Siemens Healthcare Diagnostics Inc., USA).

On hospital day 8, the patient was referred to the general

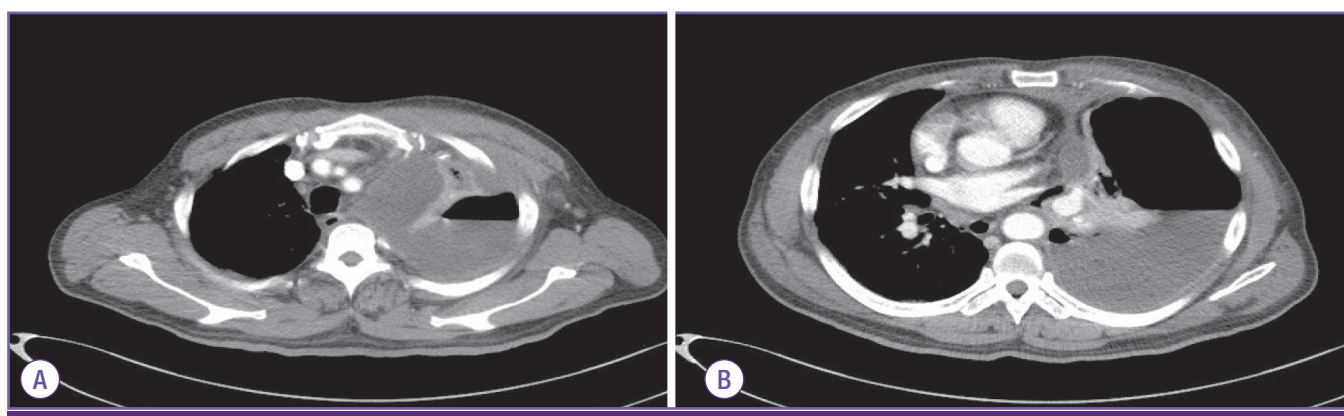


Figure 3. Enhanced chest CT image on hospital day 1 showing effusion near the mediastinum. Nearby esophagus (A) and pericardium (B).

ward, as his general condition and laboratory results had improved. On hospital day 11, his antibiotic treatment was escalated to intravenous piperacillin-tazobactam and levofloxacin due to a short episode of relapsed fever (up to 37.8°C). On hospital day 23, since the patient presented a fine general condition and improved chest radiographic findings without any respiratory symptoms or any other laboratory abnormalities, he was discharged with amoxicillin-clavulanic acid prescription for seven days. A follow-up blood culture sample drawn on hospital day 10 was negative and the chest radiographic findings had improved dramatically by the day of discharge.

Discussion

After the taxonomic dissection of *Kocuria* from the *Micrococcus* genus, a number of cases of infection have been reported in which these bacteria have been emphasized as emerging pathogens in immunocompromised hosts and hospital-associated infections.

This report described the first case of *K. kristinae*-induced bacteremic empyema in a healthy man without any history of hospitalization. The only medical history he had was diabetes, which was diagnosed only three years before the event, and was well-controlled, with a hemoglobin A1c level of 6.9% at the time of his admission.

The route of infection was not clear. The first possibility was aspiration pneumonia-induced empyema. Though the patient denied recent vomiting or losing consciousness, there still was a possibility of him lying or just not remembering the event after drinking. The second possibility that we considered was micro-perforation of the esophagus due to raw fish bones. Though we could not find visible esophageal mucosal defects in the EGD, there was a chance that we could not observe micro-injury of the esophagus. A micro-perforation of the esophagus might have acted as an inoculation route of bacteria into the intrathoracic area. The empyemic fluid from the nearby esophagus (Fig. 3) supported this second idea.

In this case, we started empirical antibiotic therapy to cover the common pathogens of aspiration pneumonia and empyema. Fortunately, the majority of *Kocuria* species are, so far, sensitive to most of the antibiotics used empirically in community-acquired pneumonia [12]. Therefore, regardless of the possibility of infection caused by *K. kristinae*, it seemed safer to start empirical antibiotics based on the epidemiology, infection site, and condition of the patient.

We reviewed the literature and identified a total of eight re-

ported cases and three case-series on *K. kristinae*-associated infections. Most of the cases were hospital-associated infection and involved immunocompromised patients with uncontrolled diabetes, underlying cancer, underlying end-stage renal disease, prematurity, etc. [2-10]. Few immunocompetent patients have been associated with this bacterial infection, but they had mostly undergone invasive procedures such as central venous catheter insertion or laparoscopic operation [11, 13]. The infected sites varied, but were mostly associated with sites of catheters insertion, such as peritonitis in patients on continuous-ambulatory-peritoneal-dialysis (CAPD), bacteremia and septic pulmonary emboli in a patient with a central-venous-catheter (CVC), endocarditis in a patient with a CVC, and urinary tract infection in patient with a urinary catheter [3-5, 8, 11]. In some cases, genetic methods were used to confirm the pathogen identity, but in others, only automated identification systems were used for final confirmation [3, 4, 8, 9]. Almost all cases survived, but one severe case of endocarditis in a patient with uncontrolled diabetes resulted in death [7].

It is not uncommon to misidentify coagulase-negative staphylococcus as *Kocuria* using standard biochemical analysis due to phenotypic variability. Therefore, genomic sequencing has been suggested for the precise identification of these rare microorganisms [14]. Data are scarce regarding the reliability of *Kocuria* species identification by automated systems, including the Vitek 2, Phoenix, or ATB systems [5, 14-16]. Recently reported cases used automation systems only for final confirmation of identification [3, 4, 8, 9].

The limitation in our case was that we could not totally exclude the possibility of misidentification. Since a genomic identification system was not available at our hospital, and the facilities were not sufficient to preserve the organism for further examination, we were unable to perform genomic tests. Although there are some studies on other automated identification systems for the identification of *Kocuria* species, no published study has reported on the MicroScan Walkaway 96 system used in our laboratory. Still, the preliminary identification provided by phenotypic tests should not be ignored [15]. Also, it was less likely to be just a simple misidentification since the same rare organism was isolated from three different specimens.

Since the organism is part of the normal flora, there was a minor possibility of contamination, but the fact that all three sets of specimens were collected by trained health-care providers using aseptic techniques with betadine preparation and sterile equipment makes this less likely.

We hope this case may broaden the clinical spectrum of re-

ported diseases caused by this unusual pathogen and add data on the virulence of this organism in humans.

Conflicts of Interest

No conflicts of interest.

ORCID

Jae Hyun Cho

<https://orcid.org/0000-0002-8276-0649>

References

1. Stackebrandt E, Koch C, Gvozdiak O, Schumann P. Taxonomic dissection of the genus *Micrococcus*: *Kocuria* gen. nov., *Nesterenkonia* gen. nov., *Kytococcus* gen. nov., *Dermacoccus* gen. nov., and *Micrococcus* Cohn 1872 gen. emend. *Int J Syst Bacteriol* 1995;45:682-92.
2. Basaglia G, Carretto E, Barbarini D, Moras L, Scalone S, Marone P, De Paoli P. Catheter-related bacteremia due to *Kocuria kristinae* in a patient with ovarian cancer. *J Clin Microbiol* 2002;40:311-3.
3. Carlini A, Mattei R, Lucarotti I, Bartelloni A, Rosati A. *Kocuria kristinae*: an unusual cause of acute peritoneal dialysis-related infection. *Perit Dial Int* 2011;31:105-7.
4. Cheung CY, Cheng NH, Chau KF, Li CS. An unusual organism for CAPD-related peritonitis: *Kocuria kristinae*. *Perit Dial Int* 2011;31:107-8.
5. Lai CC, Wang JY, Lin SH, Tan CK, Wang CY, Liao CH, Chou CH, Huang YT, Lin HI, Hsueh PR. Catheter-related bacteraemia and infective endocarditis caused by *Kocuria* species. *Clin Microbiol Infect* 2011;17:190-2.
6. Karadag Oncel E, Boyraz MS, Kara A. Black tongue associated with *Kocuria (Micrococcus) kristinae* bacteremia in a 4-month-old infant. *Eur J Pediatr* 2012;171:593.
7. Citro R, Prota C, Greco L, Mirra M, Masullo A, Silverio A, Bossone E, Piscione F. *Kocuria kristinae* endocarditis related to diabetic foot infection. *J Med Microbiol* 2013;62:932-4.
8. Tewari R, Dudeja M, Das AK, Nandy S. *Kocuria kristinae* in catheter associated urinary tract infection: a case report. *J Clin Diagn Res* 2013;7:1692-3.
9. Ahmed NH, Biswal I, Roy P, Grover RK. *Kocuria kristinae*, an unusual pathogen causing opportunistic infections in patients with malignancy. *Indian J Med Microbiol* 2014;32:456-8.
10. Chen HM, Chi H, Chiu NC, Huang FY. *Kocuria kristinae*: a true pathogen in pediatric patients. *J Microbiol Immunol Infect* 2015;48:80-4.
11. Dunn R, Bares S, David MZ. Central venous catheter-related bacteremia caused by *Kocuria kristinae*: case report and review of the literature. *Ann Clin Microbiol Antimicrob* 2011;10:31.
12. Szczerba I. [Occurrence and number of bacteria from the *Micrococcus*, *Kocuria*, *Nesterenkonia*, *Kytococcus* and *Dermacoccus* genera on skin and mucous membranes in humans]. *Med Dosw Mikrobiol* 2003;55:67-74.
13. Ma ES, Wong CL, Lai KT, Chan EC, Yam WC, Chan AC. *Kocuria kristinae* infection associated with acute cholecystitis. *BMC Infect Dis* 2005;5:60.
14. Ben-Ami R, Navon-Venezia S, Schwartz D, Schlezinger Y, Mekuzas Y, Carmeli Y. Erroneous reporting of coagulase-negative Staphylococci as *Kocuria* spp. by the Vitek 2 system. *J Clin Microbiol* 2005;43:1448-50.
15. Savini V, Catavittello C, Masciarelli G, Astolfi D, Balbinot A, Bianco A, Febbo F, D'Amario C, D'Antonio D. Drug sensitivity and clinical impact of members of the genus *Kocuria*. *J Med Microbiol* 2010;59:1395-402.
16. Boudewijns M, Vandeven J, Verhaegen J, Ben-Ami R, Carmeli Y. Vitek 2 automated identification system and *Kocuria kristinae*. *J Clin Microbiol* 2005;43:5832; author reply 5832.