

## TRANSLATIONAL RESEARCH

# Intrajugular balloon catheter reduces air embolism *in vitro* and *in vivo*

V. S. Eckle<sup>1,\*</sup>, B. Neumann<sup>2</sup>, T. O. Greiner<sup>2</sup>, H. P. Wendel<sup>2</sup> and C. Grasshoff<sup>1</sup><sup>1</sup>Department of Anaesthesiology and Intensive Care Medicine, University Hospital Tübingen, Germany, and<sup>2</sup>Department of Thoracic, Cardiac and Vascular Surgery, Clinical Research Laboratory, University Hospital Tübingen, Germany

\*Corresponding author. E-mail: veit-simon.eckle@uni-tuebingen.de

## Abstract

**Background:** Neurosurgical procedures requiring a sitting position may put the patient at risk of a potentially life-threatening air embolism. Transient manual jugular venous compression limits further air entry in this situation. This study presents an alternative technique aimed at reducing the risk of air embolism.

**Methods:** In an *in vitro* model, an intrajugular balloon catheter was inserted to demonstrate that this device prevents air embolism. In an *in vivo* study, this device was bilaterally placed into jugular vessels in pigs. Using an ultrasound technique, blood flow was monitored and jugular venous pressure was recorded before and during cuff inflation. Air was applied proximally to the inflated cuffs to test the hypothesis that this novel device blocks air passage.

**Results:** *In vitro*, the intrajugular balloon catheter reliably prevented further air entry ( $n=10$ ). Additionally, accumulated air could be aspirated from an orifice of the catheter ( $n=10$ ). *In vivo*, inflation of the catheter balloon completely obstructed venous blood flow ( $n=8$ ). Bilateral inflation of the cuff significantly increased the proximal jugular venous pressure from 9.8 (2.4) mm Hg to 14.5 (2.5) mm Hg ( $n=8$ ,  $P<0.05$ ). Under conditions mimicking an air embolism, air passage across the inflated cuffs was prevented and 78 (20%) ( $n=6$ ) of the air dose could be aspirated by the proximal orifice of the catheter.

**Conclusions:** These findings may serve as a starting point for the development of intrajugular balloon catheters designed to reduce the risk of air embolism in patients undergoing neurosurgery in a sitting position.

**Key words:** anesthesia; catheterization; embolism, air; jugular veins; models, animal; neurosurgical procedures; patient positioning; posture

### Editor's key points

- The sitting position is preferred for some neurosurgical procedures
- This position increases the risk of air embolism
- In this study the use of an intrajugular balloon catheter to reduce air embolism was studied
- *In vitro* and *in vivo* experiments (in pigs) were undertaken under conditions simulating embolism

- The catheter prevented air entry and increased jugular venous pressure and allowed air aspiration
- This may be a useful device in patients

Venous air embolism has been well documented as a serious complication during neurosurgical procedures undertaken in the sitting position.<sup>1</sup> In this posture, the incidence of air entry

Accepted: December 4, 2014

© The Author 2015. Published by Oxford University Press on behalf of the British Journal of Anaesthesia.

This is an Open Access article distributed under the terms of the Creative Commons Attribution Non-Commercial

License (<http://creativecommons.org/licenses/by-nc/4.0/>), which permits non-commercial re-use, distribution, and reproduction in any medium, provided the original work is properly cited. For commercial re-use, please contact [journals.permissions@oup.com](mailto:journals.permissions@oup.com)

into the vascular system varies between 7–76%, depending on the study and detection method.<sup>2–6</sup> Haemodynamically relevant venous air embolism, defined as a significant decrease in blood pressure, occurs in 1.9–3.3% of patients.<sup>7,8</sup> Thus standard surgical and anaesthetic procedures have been established to minimize the risk of life-threatening complications.<sup>9,10</sup> In case of detected air entry, manual jugular venous compression has been proved to limit further air entry by increasing the cerebral venous pressure.<sup>1,10,11</sup> Additionally, this pivotal manoeuvre also helps the surgeon to identify open vessels when air bubbles appear in venous lesions.<sup>10,11</sup> However, the efficacy of manual jugular vein compression may be limited to insufficient pressure and may even cause serious side effects such as a decrease in cerebral blood flow by direct carotid artery compression.<sup>1,12</sup> As an alternative method, we recently proposed an intrajugular balloon catheter to reduce the risk of air embolism.<sup>12</sup>

## Methods

### In vitro model of air embolism

An artificial vessel (made of translucent Tygon® tubing), corresponding to the jugular vein diameter in pigs was placed in a water-filled bottle. An additional tubing system continuously supplied air bubbles (95% oxygen/5% carbon dioxide) into the artificial vessel to mimic air embolism. Prototypes of an intrajugular balloon catheter were kindly provided by Alexander Krebs (Teleflex Medical, Kernertal, Germany) and Michal Syruček (Teleflex Medical, Hradec Kralove, Czech Republic). The intrajugular balloon catheter (7 Fr × 30 cm or 8.5 Fr × 30 cm) contained a proximal, medial and distal lumen and – most importantly – an inflatable balloon placed between the proximal and medial lumen (Fig. 1).<sup>12</sup> The intrajugular balloon catheter was inserted into the artificial vessel from the top. The balloon was inflated, with close attention paid to any air bubbles bypassing the cuff of the catheter. In a next step, aspiration of air of the medial lumen of the catheter from the location where air bubbles had entered the artificial vessel was attempted.

### In vivo model

All procedures were performed in accordance with institutional and federal guidelines, including the German Animal Welfare Act (TierSchG), and were approved by the Animal Care Committee (Eberhard-Karls-University, Tübingen, Germany) and the

Regierungspräsidium Tübingen, Germany (approval number A10/13). Close attention was paid to comply with relevant sections of the ARRIVE Guidelines.<sup>13</sup> The external jugular vein diameter was measured in the pigs using an ultrasound technique (Vivid I, GE Healthcare, München, Germany). Specific balloon catheters were manufactured for this study (see above). Under deep general anaesthesia, intrajugular balloon catheters were bilaterally placed in 8 pigs (German Landrace), weighing 48.9 (3.7) kg each. As premedication, 0.05 mg kg<sup>-1</sup> atropine (Köhler Pharma, Alsbach-Hähnlein, Germany), 4 mg kg<sup>-1</sup> azaperone (Lilly Elanco, Bad Homburg, Germany), 1 mg kg<sup>-1</sup> midazolam (Ratiopharm, Ulm, Germany) and 14 mg kg<sup>-1</sup> ketamine (Serumwerke Bernburg, Bernburg, Germany) were administered intramuscularly. After placing an intravenous line in the ear vein, general anaesthesia was intravenously induced by 2–5 mg kg<sup>-1</sup> propofol (Fresenius Kabi, Bad Homburg, Germany). After loss of consciousness, the trachea was intubated and the animal was continuously ventilated. The heart rate (ECG) and the end expiratory concentration of CO<sub>2</sub> were continuously monitored. For maintaining general anaesthesia 30–100 µg kg<sup>-1</sup> h<sup>-1</sup> fentanyl (Ratiopharm, Ulm, Germany) and 2 Vol-% isoflurane (CP Pharma, Burgdorf, Germany) were continuously administered. Cannulation of both external jugular veins was achieved by a commonly used surgical cut-down technique.<sup>14</sup> Under visual control, the catheter was inserted such that the inflated balloon was clearly located within the jugular vein. The vein puncture site was sealed with cyanoacrylate glue. Using a Doppler ultrasound technique (Vivid I, GE Healthcare, München, Germany), jugular blood flow was monitored and jugular venous pressure (JVP) was recorded before and during cuff inflation for up to 5 min. Air (10 ml) was injected proximally to the inflated cuffs to test the hypothesis that this novel device blocks air passage. For air injection a syringe (10 ml) was used and the air amount was slowly applied using the proximal luminae of the intrajugular catheters. After 30 s, aspiration of the remaining air was attempted via the proximal orifice of the catheter. After completion of the experiments a lethal dose of pentobarbital (100 mg kg<sup>-1</sup>, Merial GmbH, Hallbergmoos, Germany) was applied under general anaesthesia according to institutional procedure.

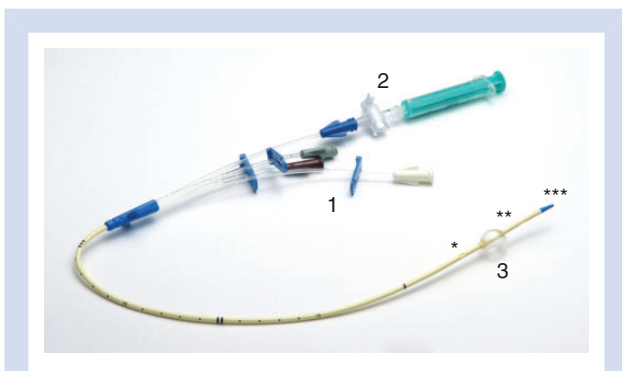
### Data analysis

Obstruction of blood flow monitored by ultrasound technique is reported descriptively. Data were tested for Gaussian distribution (D'Agostino & Pearson omnibus and Shapiro-Wilk normality test). For a parametric data set, ANOVA was performed followed by a Bonferroni's multiple comparison test and data are shown as mean (SD). The indicated P-values refer to the Bonferroni's multiple comparison test. A P-value of <0.05 was considered statistically significant and marked with an asterisk (\*).

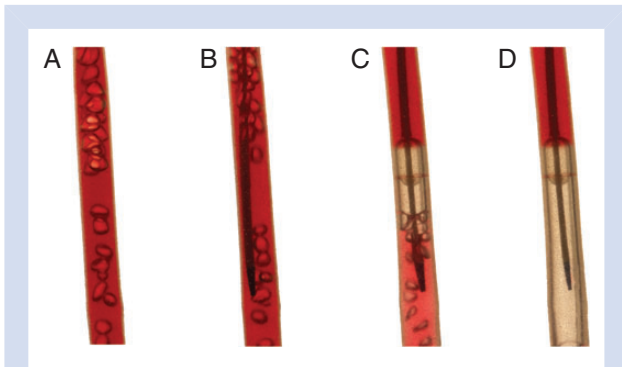
## Results

### In vitro experiments

Translucent Tygon® tubing with a similar inner diameter (1 cm) to the jugular vein of pigs [0.6 (0.1) cm, n=10] was placed into a water-filled bottle where air bubbles were continuously blown from the bottom into the artificial vessel to simulate air embolism (Fig. 2A). The intrajugular balloon catheter was inserted into the tubing from the opposite side (Fig. 2B). Under direct visual control, the balloon of the catheter was inflated to obstruct the inner diameter of the artificial vessel (Fig. 2C). In all experiments (n=10) no air bubbles bypassed the level of the catheter cuff. As anticipated, air



**Fig 1** The intrajugular balloon catheter is a 3-lumen central venous catheter, equipped with an additional lumen (2) for inflating a balloon cuff (3). The first orifice of the lumina is proximal (\*), while the second and third orifices are medial (\*\*) and distal (\*\*\*), respectively.



**Fig 2** (A) Artificial vessel containing water and air bubbles to simulate air embolism. (B) The intra jugular balloon catheter was inserted from the top of the artificial vessel. (C) The balloon of the intra jugular catheter was inflated. Note that the artificial vessel is completely obstructed. (D) Air accumulated under the inflated balloon. To improve clarity, the water in the artificial vessel was coloured with beetroot juice.

accumulated under the inflated balloon and could be entirely aspirated via the medial orifice of the catheter (Fig. 2D;  $n=10$ ). In summary, the efficacy of the intra jugular balloon catheter could be reliably demonstrated in this *in vitro* model of air embolism.

### In vivo experiments

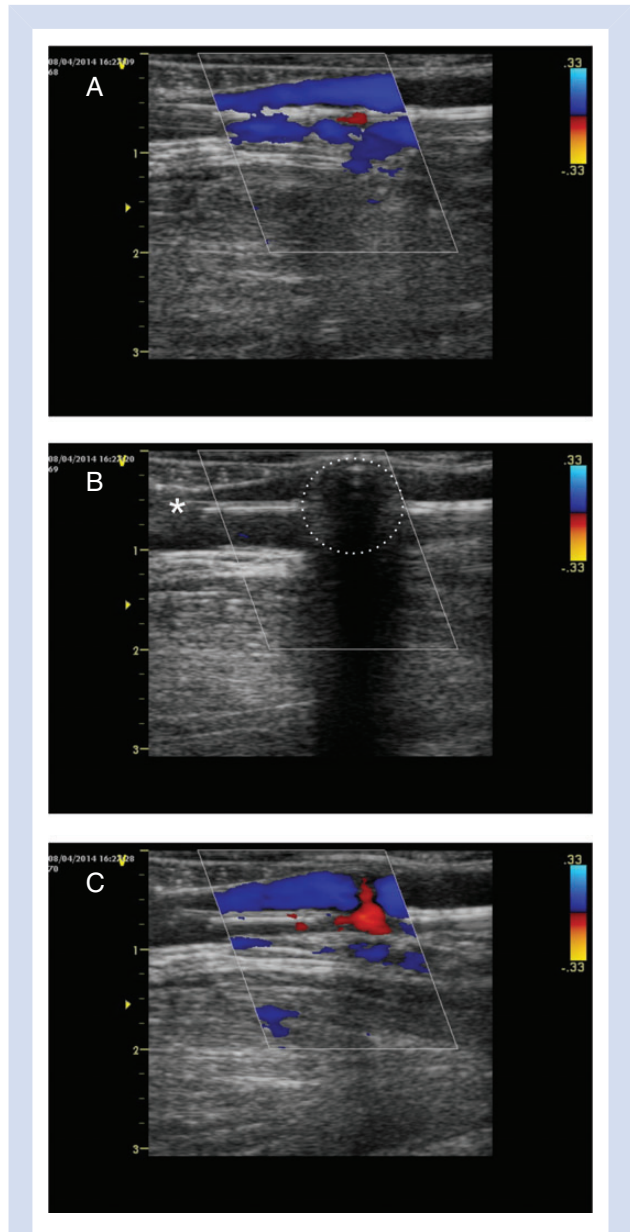
The location of bilaterally catheters placed into the jugular veins of 8 pigs during anaesthesia was identified by Doppler ultrasound and initially showed constant blood flow (Fig. 3A). After inflating the catheter cuff, blood flow was completely obstructed (Fig. 3B), and after deflation venous blood flow was restored (Fig. 3C). In one of the 16 purpose-built intra jugular balloon catheters we experienced difficulties deflating the cuff, as the inflated balloon prolapsed to the contralateral site of the orifice so that it was obstructed by the balloon's membrane. However, manual manipulation led to a re-opening of the orifice, allowing deflation.

In a next step, jugular venous pressure (JVP) was assessed via the proximal lumen of the catheter before and after bilateral cuff inflation for up to 5 min (Fig. 4). The initial JVP was 9.8 (2.4) mm Hg and increased after cuff inflation to 14.5 (2.5) mm Hg within 30 s ( $n=8$ ,  $P<0.05$ ). A similar effect was seen after 1, 3, and 5 min of balloon inflation. After cuff deflation the JVP decreased back to control values [9.3 (2.8) mm Hg,  $n=8$ ].

For testing the efficacy of the balloon catheter system to prevent air embolism *in vivo*, both cuffs were inflated and air (10 ml) was injected proximally to the balloons (Fig. 5). After 30 s, an attempt was made to re-trap the remaining air by aspirating through the proximal lumina of the catheters ( $n=6$ ). During this aspiration attempt 7.8 (2) ml of air could be captured, corresponding to 78 (20%) of the injected air volume.

### Discussion

Neurosurgical procedures of the cranial fossa posterior require the patient to be in a sitting position,<sup>15</sup> where air entry is facilitated by a negative venous pressure as a result of the surgical field being above the level of the heart.<sup>16</sup> When large quantities of air enter into the venous system, hypocapnia and hemodynamic instability may occur, suggesting venous air embolism.<sup>3 16</sup> As venous air embolism may cause lethal complications,<sup>15 17</sup> air detection methods such as precordial Doppler or transesophageal echocardiography are used during craniotomies in the

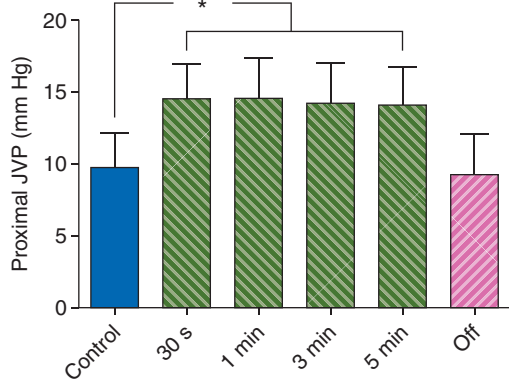


**Fig 3** (A) View of an intra jugular balloon catheter (whitish) within a jugular vein. Note the venous blood flow determined by Doppler (blue). (B) After inflation of the balloon (dotted line), blood flow was completely obstructed. The catheter tip is marked by an asterisk (white). A typical air shadow of the inflate cuff is clearly visible. (C) After deflation of the cuff, venous blood flow returned.

sitting position.<sup>17</sup> When air embolism occurs manual jugular compression has been shown to prevent further air entrainment.<sup>11 18 19</sup> Other studies have proposed the use of a transiently inflated tourniquet around the neck.<sup>20 21</sup> In recent work by Frydrychowski and co-workers, jugular vein compression was achieved using a sphygmomanometer.<sup>22</sup> The cuff was inflated to 40 mm Hg for 3 min in healthy volunteers while monitoring cerebral blood flow velocity and pial artery pulsation.<sup>22</sup> It could be shown that venous congestion led to a hyperkinetic cerebral circulation. Interestingly none of the volunteers ( $n=32$ ) experienced any adverse events. Another group investigated whether jugular venous compression alters cerebral blood flow or oxygen consumption in the head elevated

position in dogs.<sup>18</sup> Whilst the cerebral venous pressure was significantly elevated as expected, the cerebral blood flow or oxygen consumption remained unaffected during the application of neck vein compression for up to 30 min.<sup>18</sup>

In the present study, we provide first evidence that an intrajugular balloon catheter reduces air embolism *in vitro* and *in vivo*. An intrajugular balloon catheter combines the functionality of the jugular vein compression manoeuvre and a central venous

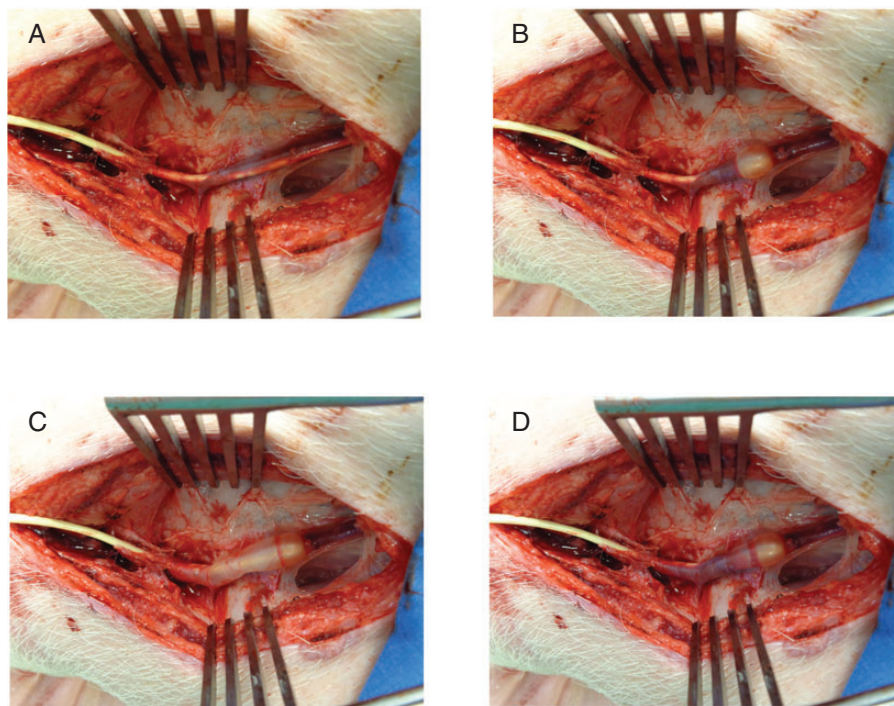


**Fig 4** Time course of the jugular venous pressure (JVP) before and after cuff inflation. Bilateral inflation of the cuffs (green bars) significantly increased the proximal JVP by 54 (12%) indicating obstruction ( $n=8$ , \* indicates a significant difference ( $P<0.05$ ) after a Bonferroni correction). Deflation of the balloon (off) returned JVP values to baseline (control).

line. In patients, this catheter may be used like a common central venous line for both liquid and drug administration either during surgical procedures or postoperatively. However, application in patients would require bilateral insertion of intrajugular balloon catheters. The incidence of accidental arterial puncture during central venous catheter placement is reported to be 2–5%.<sup>23 24</sup> The accidental arterial insertion of a large-bore catheter, which is associated with major complications, is around 0.06–0.5%.<sup>25 26</sup> To prevent major complications during central vein catheter placement ultrasound-guided placement should be used for central vein cannulation.<sup>27</sup> Therefore, the application in patients would require a cautious procedure using ultrasound guidance.<sup>28</sup>

We also demonstrated that 78 (20%) of the applied air could be aspirated by the proximal orifice of the catheter *in vivo* after mimicking air embolism. A shorter distance between the proximal orifice and the inflated cuff may have further increased the success in this experimental setting. Central venous catheters placed into the right heart are known to facilitate air aspiration in case of venous air embolism.<sup>29 30</sup> While a Bunegin-Albin catheter device may be helpful for air aspiration from the superior vena cava and the right atrium,<sup>30</sup> an intrajugular balloon catheter enables direct air aspiration from the jugular vein region and may even prevent additional air entering the heart. Further studies are needed to elucidate the utility of an intrajugular balloon catheter for air aspiration.

In our prototype testing, we experienced a balloon prolapse to the contralateral site of the connecting orifice so that instant deflation was not possible. Although balloon catheters are well established devices for use in vascular angioplasty or during anaesthesia as pulmonary artery catheters,<sup>31 32</sup> the next step of prototype development will address such complications.



**Fig 5** (A) View of the intrajugular balloon catheter inserted in a jugular vessel in a representative animal. (B) Inflation of the balloon was clearly visible. (C) To mimic air embolism, air was injected slowly after cuff inflation. (D) After 30 s, an attempt was made to aspirate the remaining air through the proximal orifice of the catheter.

In future studies, the use of intrajugular balloon catheters for assessing cerebral oxygenation should be determined, as blood samples from the jugular bulb may be obtained by the proximal lumen in order to monitor cerebral oxygenation during surgical procedures. For this purpose, an intrajugular balloon catheter may prove to be less invasive than the placement of a transjugular dural sinus catheter.<sup>33</sup>

## Authors' contributions

V.S.E., H.P.W. and C.G. conceived and performed the study, analysed the data and approved the final manuscript. B.N. and T.O. G. helped to perform the study and approved the final manuscript.

## Acknowledgements

The authors thank Professor Helen Galley for her helpful work as handling editor. Prototypes of the intrajugular balloon catheter were kindly provided by Alexander Krebs (Teleflex Medical, Kernen, Germany) and Michal Syruček (Teleflex Medical, Hradec Kralove, Czech Republic). The authors gratefully thank Hannes Schramm (University Hospital Tübingen, Germany) for his photographic assistance and Sandra Schmidt (München, Germany) for linguistic review.

## Declaration of interest

V.S.E. is the inventor of the intrajugular balloon catheter (international application No.: PCT/EP2012/063023). All other authors of this manuscript have no conflict of interest to declare.

## Funding

This study was funded by the Faculty of Medicine, Eberhard-Karls-University, Tübingen, Germany (AKF 306-0-0).

## References

- Mirski M, Lele A, Fitzsimmons L, Toung T. Diagnosis and treatment of vascular air embolism. *Anesthesiology* 2007; **106**: 164–77
- Black S, Ockert DB, Oliver WCJ, Cucchiara RF. Outcome following posterior fossa craniectomy in patients in the sitting or horizontal positions. *Anesthesiology* 1988; **69**: 49–56
- Lindroos A-C, Niiya T, Randell T, Romani R, Hernesniemi J, Niemi T. Sitting position for removal of pineal region lesions: the Helsinki experience. *World Neurosurg* 2010; **74**: 505–13
- Papadopoulos G, Kuhly P, Brock M, Rudolph KH, Link J, Eyrich K. Venous and paradoxical air embolism in the sitting position. A prospective study with transoesophageal echocardiography. *Acta Neurochir (Wien)* 1994; **126**: 140–3
- Leslie K, Hui R, Kaye AH. Venous air embolism and the sitting position: A case series. *J Clin Neurosci* 2006; **13**: 419–22
- Fathi A-R, Eshtehardi P, Meier B. Patent foramen ovale and neurosurgery in sitting position: a systematic review. *Br J Anaesth* 2009; **102**: 588–96
- Feigl GC, Decker K, Wurms M, et al. Neurosurgical procedures in the semisitting position: evaluation of the risk of paradoxical venous air embolism in patients with a patent foramen ovale. *World Neurosurg* 2014; **81**: 159–64
- Ganslandt O, Merkel A, Schmitt H, et al. The sitting position in neurosurgery: indications, complications and results. a single institution experience of 600 cases. *Acta Neurochir (Wien)* 2013; **155**: 1887–93
- Porter JM, Pidgeon C, Cunningham AJ. The sitting position in neurosurgery: a critical appraisal. *Brit J Anaesth* 1999; **82**: 117–28
- Jadik S, Wissing H, Friedrich K, Beck J, Seifert V, Raabe A. A standardized protocol for the prevention of clinically relevant venous air embolism during neurosurgical interventions in the semisitting position. *Neurosurgery* 2009; **64**: 533–9
- Losasso T, Muzzi D, Cucchiara R. Jugular venous compression helps to identify the source of venous air embolism during craniectomy in patients in the sitting position. *Anesthesiology* 1992; **76**: 156–7
- Eckle V-S, Grasshoff C. Intrajugular balloon catheter for prevention of air embolism. *J Neurosurg Anesthesiol* 2012; **24**: 81–2
- Kilkenny C, Browne W, Cuthill IC, Emerson M, Altman DG, NC3Rs Reporting Guidelines Working Group. Animal research: Reporting in vivo experiments: The ARRIVE guidelines. *Br J Pharmacol* 2010; **160**: 1577–9
- Bain SAF, Ting J, Simeonovic CJ, Wilson JD. Technique of venous catheterization for sequential blood sampling from the pig. *J Invest Surg* 1991; **4**: 103–7
- Gale T, Leslie K. Anaesthesia for neurosurgery in the sitting position. *J Clin Neurosci* 2004; **11**: 693–6
- Kumar R, Goyal V, Chauhan R. Venous air embolism during microelectrode recording in deep brain stimulation surgery in an awake supine patient. *Br J Neurosurg* 2009; **23**: 446–8
- Hamby W, Terry R. Air embolism in operations done in the sitting position; a report of five fatal cases and one of rescue by a simple maneuver. *Surgery* 1952; **31**: 212–5
- Toung TJK, Miyabe M, McShane AJ, Rogers MC, Traystman RJ. Effect of PEEP and jugular venous compression on canine cerebral bloodflow and oxygen consumption in the head elevated position. *Anesthesiology* 1988; **68**: 53–8
- Grady MS, Bedford RF, Park TS. Changes in superior sagittal sinus pressure in children with head elevation, jugular venous compression, and PEEP. *J Neurosurg* 1986; **65**: 199–202
- Pfitzner J, McLean AG. Controlled neck compression in neurosurgery. *Anaesthesia* 1985; **40**: 624–9
- Takahashi T, Yano K, Kimura T, Komatsu T, Shimada Y. Prevention of venous air embolism by jugular venous compression under superior sagittal sinus pressure monitoring in a brachycephalic patient during craniofacial reconstruction. *Paediatr Anaesth* 1997; **7**: 259–60
- Frydrychowski A, Winklewski P, Guminski W. Influence of acute jugular vein compression on the cerebral blood flow velocity, pial artery pulsation and width of subarachnoid space in humans. *PLoS One* 2012; **7**: e48245
- Eisen LA, Narasimhan M, Berger JS, Mayo PH, Rosen MJ, Schneider RF. Mechanical complications of central venous catheters. *J Intensive Care Med* 2006; **21**: 40–6
- Shah KB, Rao TLK, Laughlin S, El-Etr AA. A review of pulmonary artery catheterization in 6,245 patients. *Anesthesiology* 1984; **61**: 271–5
- Golden LR. Incidence and management of large-bore introducer sheath puncture of the carotid artery. *J Cardiothorac Vasc Anesth* 1995; **9**: 425–8
- Jobes DR, Schwartz AJ, Greenhow DE, Stephenson LW, Ellison N. Safer Jugular Vein Cannulation: Recognition of Arterial Puncture and Preferential Use of the External Jugular Route. *Anesthesiology* 1983; **59**: 353–5
- American Society of Anesthesiologists Task Force on Central Venous Access, Rupp S, Apfelbaum J, et al. Practice guidelines for central venous access: a report by the American Society of

- Anesthesiologists Task Force on central venous access. *Anesthesiology* 2012; **116**: 539–73
28. Feller-Kopman D. Ultrasound-guided internal jugular access: a proposed standardized approach and implications for training and practice. *Chest* 2007; **132**: 302–9
  29. Terry H, Daw E, Michenfelder J, Tuohy G, Miller R. Anesthesia for Neurosurgery. *Surg Clin North Am* 1965; **45**: 899–906
  30. Bunegin L, Albin M, Helsel P, Hoffmann A, Hung T. Positioning the right atrial catheter: a model for reappraisal. *Anesthesiology* 1981; **55**: 343–8
  31. Farooq M, Al-Ali F, Min J, Gorelick P. Reviving intracranial angioplasty and stenting ‘SAMMPRIS and beyond’. *Front Neurol* 0000; **5**: 101
  32. Gidwani UK, Mohanty B, Chatterjee K. The pulmonary artery catheter: a critical reappraisal. *Cardiol Clin* 2013; **31**: 545–65
  33. Hu H, Ge X, Cai H. Monitoring of intracranial pressure and cerebral hemodynamics by transjugular dural sinus catheterization. *J Clin Anesth* 2014; **26**: 147–8

Handling editor: H. F. Galley