

## Case Report

---

# Surgical Treatment of Optic Disc Pit Associated with Macular Detachment

Lukpan Orazbekov<sup>a</sup> Aigerim Bayanova<sup>a</sup> Daniyar Dauletbekov<sup>b</sup>

<sup>a</sup>First Ophthalmology Department, Kazakh Eye Research Institute, Almaty, Kazakhstan;

<sup>b</sup>Postgraduate Education Department, Kazakh Eye Research Institute, Almaty, Kazakhstan

## Keywords

Optic disc pit maculopathy · Serous macular detachment · Vitrectomy · Inner limiting membrane flap

## Abstract

We report a clinical case of a serous macular detachment associated with optic disc pit (ODP), which was successfully treated with vitrectomy and internal limiting membrane (ILM) flap technique. A twenty-four-year-old woman complained of visual loss with duration over 7 months. Upon ophthalmic examination using funduscopy and spectral domain optical coherence tomography (OCT), a serous macular detachment associated with optic disc pit was diagnosed. The patient was successfully treated by 25-gauge pars plana vitrectomy with ILM peeling and placing an autologous ILM flap to cover the optic disc including the ODP. This method of treatment resulted in complete retinal reattachment with best-corrected visual acuity improvement to 20/60 from initial 20/500, and OCT showed a complete retinal attachment. This clinical case suggests that 25-gauge vitrectomy with ILM peeling and an inverted ILM flap can be an effective treatment option for optic disc pit-associated serous macular detachment.

© 2022 The Author(s)  
Published by S. Karger AG, Basel

## Introduction

Optic disc pit (ODP) is a congenital anomaly of the optic nerve head. It is one of congenital cavitory optic disc anomalies, which include optic disc coloboma, morning glory, and ODP. It was first described in 1882 by T. Wiethe in a 62-year-old woman. ODPs occur in around 2 in 10,000 people, and there is no gender predisposition. The first manifestations appear between the ages of 20 and 40 [1].

---

Correspondence to:  
Daniyar Dauletbekov, [daniyar.dauletbekov@gmail.com](mailto:daniyar.dauletbekov@gmail.com)

The definite pathogenic mechanism of ODP is not completely understood, and no relations with systemic or eye diseases have been detected [2]. Approximately 25–75% of patients will develop serous detachment and/or retinoschisis of the central macula leading to ODP maculopathy (ODP-M) [1].

Currently, vitrectomy is most widely accepted treatment of ODP-M, leading to up 50–90% of successful foveal attachment [3, 4]. It is performed alone or in combination with laser treatment, gas tamponade, and internal limiting membrane (ILM) flap. The ILM flap technique involves standard vitrectomy along with the ILM peeling, and the peeled ILM is then inverted and positioned onto the ODP to seal it [5]. This case confirms that the ILM flap technique could be successfully used to treat macular detachment associated with ODP.

### Case Report

A 24-year-old woman presented with visual loss of at least 7-month duration in the left eye. Her past medical and family history was noncontributory.

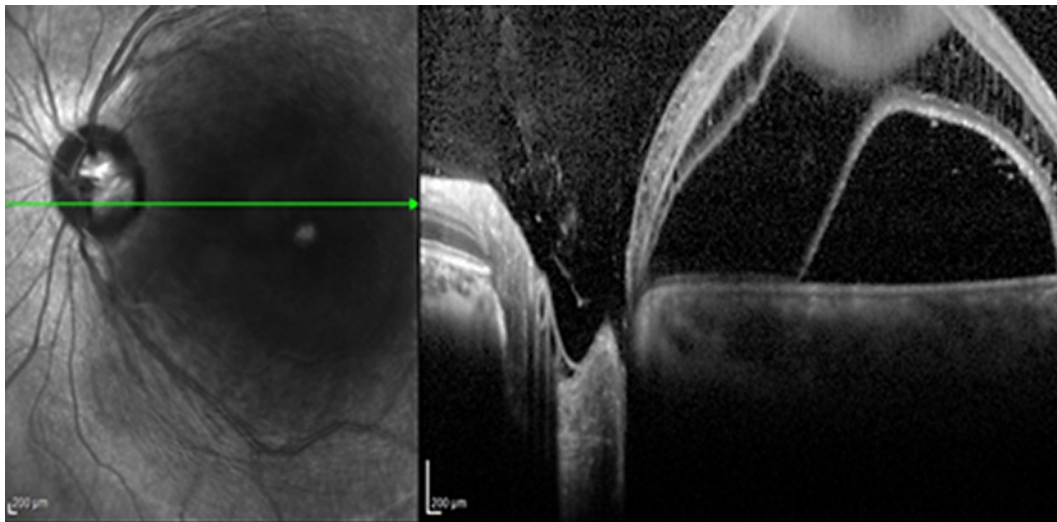
The best-corrected visual acuity (BCVA) improved to 20/25 in the right eye and 20/500 in the left eye using Snellen chart. Intraocular pressure was 16 mm of Hg in both eyes. The external ocular exam and anterior segment were normal bilaterally. An optic nerve pit in the left eye was noted with the presence of intraretinal fluid temporal to the disc, there was an associated local foveal detachment with extensive diffuse edema and retinoschisis, whereas the peripheral retina was normal. No pathology was found during ophthalmoscopy and optical coherence tomography (OCT) examination of retina in the right eye.

OCT imaging of the left eye showed detachment of the retinal pigment epithelium combined with splitting within the neurosensory layer of the retina and central macular thickness (CMT) increased to 610 microns. OCT of the optic disc showed ODP-associated serous macular detachment and presence of subretinal fluid (SRF) to the optic disc (shown in Fig. 1).

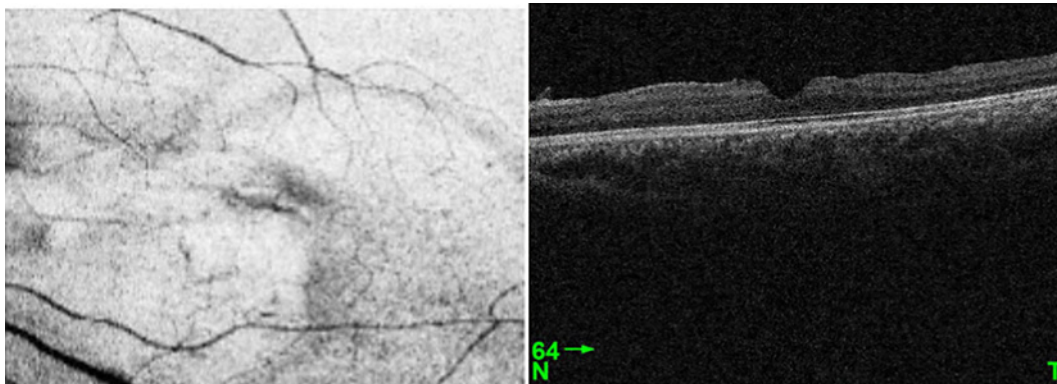
A 25-gauge vitrectomy was performed in the left eye, posterior hyaloid membrane removal, inner limiting membrane peeling stained with membrane blue dye (DORC), ODP tamponade with inverted inner limiting membrane flap, and 20% SF6 (Alcon ISPAN) gas tamponade. Postoperative instructions were to position facedown for 3 days. There were no complications during the surgery and the early postoperative period. The OCT of the macula showed a slight decrease of retinoschisis and the ILM flap in ODP at 7 days postoperative examination. A follow-up OCT examination in 1 month showed a decrease of retinoschisis, a flattening of edema of the neuroepithelium, a decrease of SRF. As the patient moved to another city, the next follow-up examination was possible only 18 months after the surgery. Best-corrected visual acuity of the left eye improved to 20/60 from initial 20/500. OCT showed a restored concave foveal contour, total edema resorption, complete retinal attachment, and flapped pit (shown in Fig. 2, 3), and the CMT was 258 microns. The patient was satisfied with the result and achieved visual acuity.

### Discussion

The origin of SRF in ODP-associated serous macular detachment and the exact mechanism of its appearance is still unknown. Histological investigations demonstrated no direct communication between the vitreous cavity and the subretinal space through the ODP defect [6]. Direct communication between the subarachnoid space and the subretinal space may serve as an origin of fluid. It has been observed that after vitrectomy and intravitreal gas tamponade, gas bubbles leak out of the optic nerve shell. This indicates continuity between



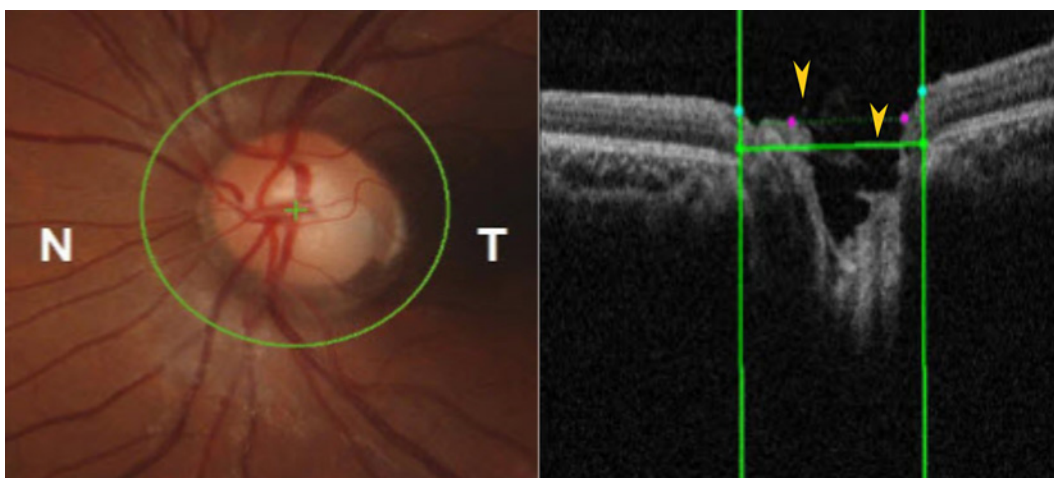
**Fig. 1.** Optic disc pit on OCT at initial visit. OCT scan of the optic nerve head of the left eye before surgery shows an optic disc pit with associated serous retinal detachment.



**Fig. 2.** Retinal reattachment and resolution of macular edema on OCT 18 months after surgery. OCT showed retinal reattachment and restored foveal contour.

the subarachnoid space of the optic nerve and the posterior vitreous. Studies based on OCT also have detected a communication between the subarachnoid and the subretinal spaces. On the contrary, potential sources of intraretinal fluid and SRF have been described as communication between the vitreous cavity and the subretinal space through the ODP defect. Some studies have shown the transit of gas or silicone oil from the vitreous to the subretinal space in patients with cavitory abnormalities of the optic disc, including ODP.

Currently, pars plana vitrectomy (PPV) is the treatment of choice for ODP-M. The rationale of the PPV use is based on the removal of the vitreous traction on the macula which contribute to the development of ODP-M [1, 7]. Additionally, the removal of the source of SRF leakage is considered a main aim in treatment of ODP-M [8–10]. In our case, PPV and ILM peeling allowed to remove vitreous traction, whereas the inverted ILM flap over the ODP allowed for prevention of fluid leakage to sub- and intraretinal space from vitreous cavity, and it is reported to be an effective method of ODP-M treatment [11]. We found this technique easy to implement given that the ILM peeling currently is a standard procedure during vitrectomy and there is no need for additional material to seal the pit.



**Fig. 3.** Nerve optic disc on OCT 18 months after surgery showed the absence of retinal detachment. Eighteen months after surgery, OCT revealed the tamponated optic nerve disc.

Travassos et al. transplanted autologous sclera which contributed to closure of the ODP in 3 eyes; in one case re-operation was needed [12]. Rizzo et al. [13] reported the retinal reattachment was observed in 5 out of 10 eyes after PPV, ILM peeling, endolaser photocoagulation on the temporal margin of the optic disc, and gas tamponade. This method is one of the most common techniques of surgical treatment of ODP. However, there was no significant difference in either fluid extent or OCT fluid distribution between the cases with and without use of endolaser to create a barrier between the pit and subretinal space; currently, the effectiveness of this procedure is in doubt [14, 15]. Additionally, cases with satisfactory results were reported without ILM peeling, so there is no evidence that ILM peeling is necessary for surgical and visual success [12]. Hara et al. [11] reported that SRF drainage might contribute to early reattachment, but Mohammed and Pai [5] described that the macula was completely reattached after 1 month without SRF drainage. In our case, we have not performed SRF drainage and the resolving of SRF took about 18 months.

In conclusion, the presented clinical case presents evidence that serous macular detachment in ODP-M can be successfully treated by vitrectomy and ODP tamponade with the ILM flap technique. Our case showed satisfactory results including no relapse in the long term and positive improvement in visual acuity and OCT data at 18 months post-surgery.

### Acknowledgment

The authors gratefully acknowledge the assistance of Dr. Neila Aldasheva for supporting the publication.

### Statement of Ethics

This case complies with the principles of the Declaration of Helsinki. The patient has given written informed consent for publication of the details of their medical case and any accompanying images. Ethical approval was not required for this study in accordance with local/national guidelines.

### Conflict of Interest Statement

The authors have no conflicts of interest to declare.

### Funding Sources

The authors declare no financial disclosures.

### Author Contributions

Aigerim Bayanova: coordinator of the patient's examinations, treatment procedures, and follow-ups. Lukpan Orazbekov and Daniyar Dauletbekov: provide analysis and interpretation of the data; and preparation, review, or approval of the manuscript.

### Data Availability Statement

All data generated or analyzed during this study are included in this article. Further inquiries can be directed to the corresponding author.

### References

- Georgalas I, Ladas I, Georgopoulos G, Petrou P. Optic disc pit: a review. *Graefes Arch Clin Exp Ophthalmol*. 2011; 249(8):1113–22.
- Kalogeropoulos D, Ch'ng SW, Lee R, Elaraoud I, Purohit M, Felicida V, et al. Optic disc pit maculopathy: a review. *Asia Pac J Ophthalmol*. 2019;8(3):247–55.
- Chatziralli I, Theodossiadis P, Theodossiadis GP. Optic disk pit maculopathy: current management strategies. *Clin Ophthalmol*. 2018;12:1417–22.
- Avci R, Kapran Z, Ozdek S, Teke MY, Oz O, Guven D, et al. Multicenter study of pars plana vitrectomy for optic disc pit maculopathy: MACPIT study. *Eye*. 2017 Sep 1;31(9):1266–73.
- Mohammed OA, Pai A. Inverted autologous internal limiting membrane for management of optic disc pit with macular detachment. *Middle East Afr J Ophthalmol*. 2013 Oct;20(4):357–9.
- Ferry AP. Macular detachment associated with congenital pit of the optic nerve head: pathologic findings in two cases simulating malignant melanoma of the choroid. *Arch Ophthalmol*. 1963;70(3):346–57.
- Talli PM, Fantaguzzi PM, Bendo E, Pazzaglia A. Vitrectomy without laser treatment for macular serous detachment associated with optic disc pit: long-term outcomes. *Eur J Ophthalmol*. 2016;26(2):182–7.
- D'Souza P, Babu U, Narendran V. Autologous free internal limiting membrane flap for optic nerve head pit with maculopathy. *Ophthalmic Surg Lasers Imaging Retina*. 2017 Apr 1;48(4):350–3.
- Caporossi T, Finocchio L, Barca F, Franco F, Tartaro R, Rizzo S. 27-gauge via pars plana vitrectomy with autologous ILM transplantation for optic pit disc maculopathy. *Ophthalmic Surg Lasers Imaging Retina*. 2018 Sep 1;49(9):712–4.
- Morris RE, Hashimi H, McFarland AJ, Kuhn F, Sapp M, Oltmanns M. Optic disc pit maculopathy: tamponade of maculoschisis. *Clin Ophthalmol*. 2019;13:1735–41.
- Hara R, Tsukahara Y, Simoyama T, Mori S. Refined internal limiting membrane inverted flap technique for intractable macular detachment with optic disc pit. *Case Rep Ophthalmol*. 2017;8(1):208–13.
- Travassos AS, Regadas I, Alfaiate M, Silva ED, Proença R, Travassos A. Optic pit: novel surgical management of complicated cases. *Retina*. 2013 Sep;33(8):1708–14.
- Rizzo S, Belting C, Genovesi-Ebert F, Di Bartolo E, Cresti F, Cinelli L, et al. Optic disc pit maculopathy: the value of small-gauge vitrectomy, peeling, laser treatment, and gas tamponade. *Eur J Ophthalmol*. 2012 Jul;22(4): 620–5.
- Lincoff H, Yannuzzi L, Singerman L, Kreissig I, Fisher Y. Improvement in visual function after displacement of the retinal elevations emanating from optic pits. *Arch Ophthalmol*. 1993;111(8):1071–9.
- Steel DHW, Williamson TH, Laidlaw DAH, Sharma P, Christopher M, Rees J, et al. Extent and location of intraretinal and subretinal fluid as prognostic factors for the outcome of patients with optic disk pit maculopathy. *Retina*. 2016;36(1):110–8.