

Case Report

A Rare Devastating Complication of Lasik: Bilateral Fungal Keratitis

H. Taylan Sekeroglu,¹ E. Erdem,¹ K. Yar,¹ M. Yağmur,¹ T. R. Ersoz,¹ and A. Uguz²

¹Department of Ophthalmology, Cukurova University, Yuregir, 01330 Adana, Turkey

²Department of Pathology, Cukurova University, 01330 Adana, Turkey

Correspondence should be addressed to H. Taylan Sekeroglu, h.taylan@yahoo.com

Received 19 August 2010; Revised 8 October 2010; Accepted 10 October 2010

Academic Editor: Edward Manche

Copyright © 2010 H. Taylan Sekeroglu et al. This is an open access article distributed under the Creative Commons Attribution License, which permits unrestricted use, distribution, and reproduction in any medium, provided the original work is properly cited.

Purpose. To report an unusual case of severe bilateral fungal keratitis following laser in situ keratomileusis (LASIK). **Method.** A 48-year-old man developed bilateral diffuse corneal infiltration two weeks after LASIK. The corneal scrapings revealed fungal filaments but cultures were negative. **Results.** The corneal ulceration was improved on the left eye whereas spontaneous perforation occurred and finally evisceration was needed on the right eye despite topical and systemic antifungal treatment. **Conclusions.** Fungal keratitis, especially with bilateral involvement, is a very rare and serious complication of LASIK surgery. Clinical suspicion is crucial because most of fungal keratitis are misdiagnosed as bacterial keratitis and can lead serious visual results, even eye loss.

1. Introduction

Laser in situ keratomileusis is a commonly used and mostly uneventful refractive surgery procedure. Because it is performed in partially aseptic conditions, infection after laser in situ keratomileusis is rare but it is still a sight-threatening, even a blinding complication. The incidence of postoperative infection after LASIK is 1 : 3000 to 1 : 5000 [1]. Postoperative intensive steroid use increases host susceptibility to microorganisms and can lead to opportunistic infections. Various infections of bacterial origin have been described. In this paper, we present a case of severe bilateral fungal keratitis after LASIK.

2. Case Report

A 48-year-old man with no significant ocular and medical history had bilateral simultaneous LASIK for -2.50 D myopia at a refractive surgery center. Two weeks after the operation, the patient complained of bilaterally reduction in vision, foreign body sensation, intense pain, and watering. He was diagnosed as having infectious keratitis by his ophthalmologist, who prescribed topical fortified cefazolin, fortified gentamicin every hour, and cyclopentolate 1%

three times daily. Upon detection of fungal filaments on the corneal scraping material, the treatment protocol was changed to topical amphotericin B 0,15%, natamycine 5%, and oral ketoconazole. The patient was subsequently referred to our clinic.

At the time of presentation, the visual acuities were hand motions bilaterally. He had bilateral intense eyelid edema and deep episcleral injection. Slit lamp examination revealed diffuse full-thickness corneal infiltration with overlying epithelial ulcer on both eyes. (Figures 1 and 2) His right eye had excessive central corneal thinning and 2,5 mm of hypopyon. Details of the anterior chamber, iris, and lens were not detectable in neither eye.

Fundus examinations could not be performed. B-scan ultrasonography showed no vitreoretinal pathology. Digitally measured intraocular pressures were estimated within normal limits bilaterally.

Corneal scrapings were taken from ulcer beds and edges of both eyes. The microscopic examination of smears with Periodic Acsid Schiff (PAS) stain revealed many fungal filaments (Figure 3). There was no growth on fungal and bacterial culture medias including blood agar, chocolate agar, and Sabouraud dextrose agar. Topical amphotericin B 0,15% and natamycine 5% every hour, cyclopentolate 1% three

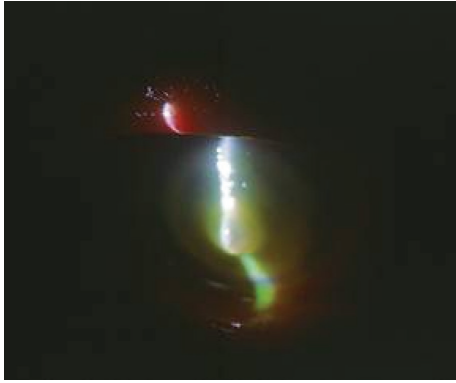


FIGURE 1: Clinical picture of the right eye at initial presentation. There is marked corneal infiltration, and central thinning.

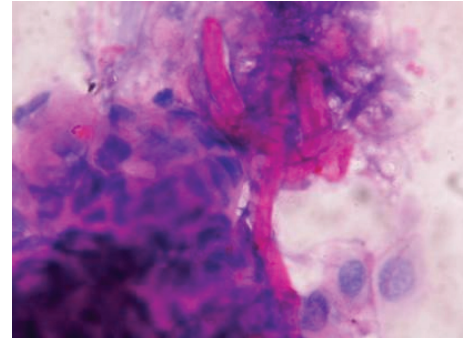


FIGURE 3: PAS positive fungal hyphae between corneal epithelial cells ($\times 1000$)

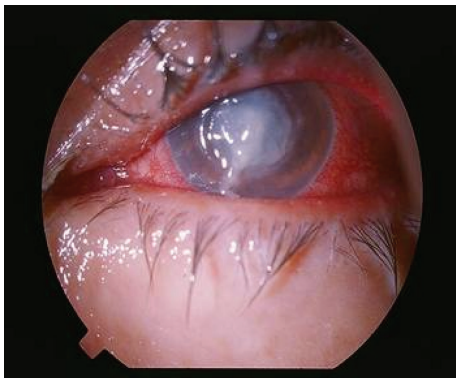


FIGURE 2: Conjunctival injection, diffuse central corneal infiltration and marked discharge in the left eye at initial presentation.

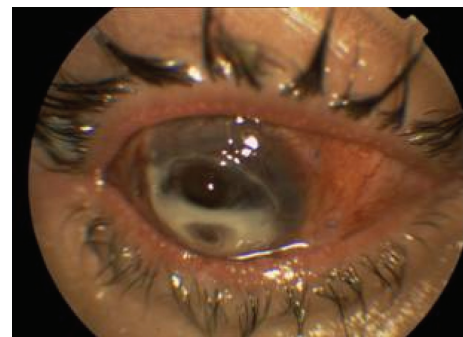


FIGURE 4: Clinical picture of the right eye after the first amniotic membrane transplantation. There is marked corneal thinning and vascularization.

times daily, and oral ketoconazole 2×200 mg twice daily were continued.

Despite antifungal treatment, the clinical appearance worsened. Excessive corneal thinning required repeated amniotic membrane transplantation (Figures 4 and 5). After the second transplantation, spontaneous perforation and iris prolapse occurred on the right eye, visual acuity dropped to no light perception. Eventually, evisceration was performed on that eye.

During followup, the visual acuity of the left eye improved to counting fingers and the active inflammation subsided (Figure 6.).

3. Discussion

LASIK is the most widely used refractive surgery procedure. Although bacterial and fungal keratitis, even endophthalmitis were reported as a complication [2, 3], infections are rare after this extraocular intervention. Moshirfar et al. found that the combined occurrence rate of infectious and noninfectious keratitis after LASIK was 2.66% [4]. Bilateral fungal infection is extremely rare after LASIK [5].

We report here a very severe case of bilateral fungal keratitis after LASIK resulted in evisceration in one eye and severe loss of vision in the other. The fungal pathogen could

not be specified by culture, but fungal hyphae were shown on microscopic examination.

Microbial contamination from eyelids, eyelashes, conjunctiva, microkeratome, operative drapes, gloves, and room air is possible during LASIK [6, 7]. Epithelial break after LASIK could allow microbial penetration [8], as well as long-term use of steroids could increase incidence of infection.

Khan et al. [9] found 5% microbial growth from cultured microkeratome blades used during uncomplicated LASIK procedures. All of the microorganisms were *Staphylococcus* species sensitive to fourth generation fluoroquinolones and vancomycin. None of the cases demonstrated signs of corneal infection. They concluded that antibiotic prophylaxis could have a role to eradicate subclinical bacterial stains.

Postoperative close follow-up after LASIK is essential because microbial keratitis can occur within days, weeks or even years after LASIK [10]. Vieira and Pereira described late-onset infectious keratitis after LASIK caused by *Pseudomonas* and *Fusarium* species [11].

The distinction between infection and postoperative inflammatory response must be made carefully for critical therapeutic intervention. Sterile infiltrates require topical corticosteroids, but misdiagnosis of the infection as an inflammation can exacerbate the existing clinical condition and worsen the prognosis.

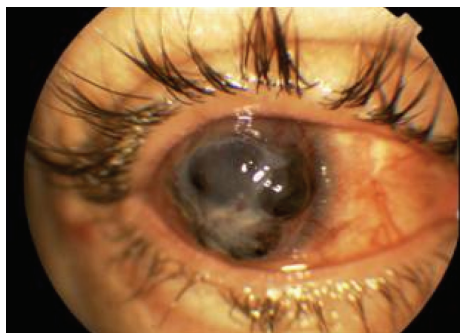


FIGURE 5: Severe iris prolapse and corneal melting of the right eye after second amniotic membrane transplantation.

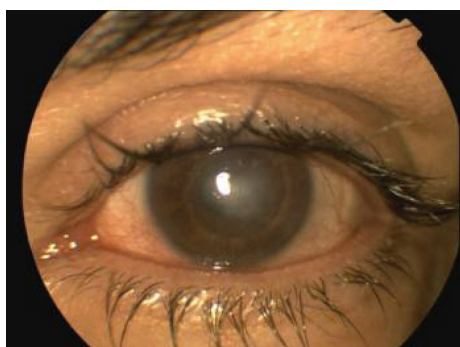


FIGURE 6: Clinical picture of the left eye 7 months after LASIK. There is minimal conjunctival injection and vascularized corneal leukoma.

Various fungal organisms including *Candida* [12], *Fusarium* [4], and *Alternaria* species [13] were isolated from post-LASIK corneas. *Aspergillus* species [14–16] are the most common cause of fungal keratitis. Most of fungal keratitis are misdiagnosed as bacterial keratitis. The treatment of fungal keratitis is crucial because of the lack of effective, strongly penetrating antifungal agents [17].

When post-LASIK infection is suspected, microbiological workup should be done immediately for proper treatment because fungal infections progress rapidly; however, culture confirmation and agent identification could not be always obtained [18]. Appropriate treatment is usually delayed because of negative and time-consuming cultures. In this condition, microscopic examination could be helpful in guiding the diagnosis and the decision of antifungal treatment, and also empirical treatment with broad spectrum fortified antibiotics is warranted. Corneal scrapings and conjunctival swabs must be taken. Deep corneal infiltration, Descemet's membrane penetration can occur in fungal corneal infections [19]. For resistant cases, flap lifting, irrigation with antibiotics, daily debridement, and repositioning should be done early. In case of progression and poor response to therapy, flap amputation is also indicated. The flap amputation could not be performed in the present case because of severe thinning and melting of the affected cornea at the time of presentation to our clinic. The progression was so fast that there was not enough time to change the

treatment protocol and to switch it to voriconazole. The patient had clinical stability after the amniotic membrane transplantation, the active infection subsided, and so the time of keratoplasty was postponed. The culture negativity was thought to be caused by the time delay and the treatment given between the first presentation and the referral. The fungal cultures were reconfirmed but were still negative.

Wide use of the LASIK procedure causes inevitable increase in complications, so the reports of post-LASIK infections increased in recent years [20]. Llovet et al., found that the incidence was 0,035% per procedure and detected the following risk factors: blepharitis, intraoperative epithelial defect, dry eye, and the health care environment [21]. Careful attention to patient selection, sterile technique, monitoring the intraoperative and postoperative environmental conditions, and hygiene are important. If bilateral simultaneous surgery is to be performed, change of the lid speculum and the microkeratome blade is mandatory to prevent contamination from the first eye. Clinical suspicion and looking up for preliminary infectious signs are essential in early intervention of antimicrobial therapy. Fungal infections are rare, and antifungal prophylaxis is not rationalized after the procedure. The reason of the fungal infection in the present case was thought to be the inappropriate sterilization of the operating room. However, in case of fungal contaminations, treatment is very difficult due to the difficulty in isolating the microorganism and the lack of very effective antifungal agents for the cornea.

Some of these cases could not be prevented from the poor prognosis leading to serious sequelae, poor final visual performance, even loss of the eye, as in our case. Patients should be aware of this rare but possible infections and especially possible bilateral complications after LASIK.

References

- [1] R. Solomon, E. D. Donnenfeld, D. T. Azar et al., "Infectious keratitis after laser in situ keratomileusis: results of an ASCRS survey," *Journal of Cataract and Refractive Surgery*, vol. 29, no. 10, pp. 2001–2006, 2003.
- [2] M. G. Mulhern, P. I. Condon, and M. O'Keefe, "Endophthalmitis after astigmatic myopic laser in situ keratomileusis," *Journal of Cataract and Refractive Surgery*, vol. 23, no. 6, pp. 948–950, 1997.
- [3] Q. Peng, M. P. Holzer, P. H. Kaufer, D. J. Apple, and K. D. Solomon, "Interface fungal infection after laser in situ keratomileusis presenting as diffuse lamellar keratitis: a clinicopathological report," *Journal of Cataract and Refractive Surgery*, vol. 28, no. 8, pp. 1400–1408, 2002.
- [4] M. Moshirfar, J. D. Welling, V. Feiz, H. Holz, and T. E. Clinch, "Infectious and noninfectious keratitis after laser in situ keratomileusis. Occurrence, management, and visual outcomes," *Journal of Cataract and Refractive Surgery*, vol. 33, no. 3, pp. 474–483, 2007.
- [5] M. S. Muallem, E. C. Alfonso, A. C. Romano et al., "Bilateral *Candida parapsilosis* interface keratitis after laser in situ keratomileusis," *Journal of Cataract and Refractive Surgery*, vol. 29, no. 10, pp. 2022–2025, 2003.
- [6] M. S. Sridhar, P. Garg, A. K. Bansal, and S. Sharma, "Fungal keratitis after laser in situ keratomileusis," *Journal of Cataract and Refractive Surgery*, vol. 26, no. 4, pp. 613–615, 2000.

- [7] H. Watanabe, S. Sato, N. Maeda, Y. Inoue, Y. Shimomura, and Y. Tano, "Bilateral corneal infection as a complications of laser in situ keratomileusis," *Archives of Ophthalmology*, vol. 115, no. 12, pp. 1593–1594, 1997.
- [8] K. O. Karp, P. S. Hersh, and R. J. Epstein, "Delayed keratitis after laser in situ keratomileusis," *Journal of Cataract and Refractive Surgery*, vol. 26, no. 6, pp. 925–928, 2000.
- [9] A. M. Khan, B. Larson, J. Noth, R. Rosen, and C. Bouchard, "Microbial cultures of the microkeratome blade immediately after flap construction in laser in situ keratomileusis," *Journal of Cataract and Refractive Surgery*, vol. 34, no. 5, pp. 842–845, 2008.
- [10] O. Semoun, T. Bourcier, B. Dupas et al., "Early bacterial keratitis after presbyopic LASIK," *Cornea*, vol. 27, no. 1, pp. 114–116, 2008.
- [11] A. C. Vieira, T. Pereira, and D. De Freitas, "Late-onset infections after LASIK," *Journal of Refractive Surgery*, vol. 24, no. 4, pp. 411–413, 2008.
- [12] W.-L. Chen, Y.-Y. Tsai, J.-M. Lin, and C.-C. Chiang, "Unilateral candida parapsilosis interface keratitis after laser in situ keratomileusis-case report and review of the literature," *Cornea*, vol. 28, no. 1, pp. 105–107, 2009.
- [13] T. Kocatürk, R. Pineda II, L. K. Green, and D. T. Azar, "Post-LASIK epithelial dendritic defect associated with *Alternaria*," *Cornea*, vol. 26, no. 9, pp. 1144–1146, 2007.
- [14] Y. Sun, A. Jain, and C. N. Ta, "Aspergillus fumigatus keratitis following laser in situ keratomileusis," *Journal of Cataract and Refractive Surgery*, vol. 33, no. 10, pp. 1806–1807, 2007.
- [15] I. C. Kuo, T. P. Margolis, V. Cevallos, and D. G. Hwang, "Aspergillus fumigatus keratitis after laser in situ keratomileusis," *Cornea*, vol. 20, no. 3, pp. 342–344, 2001.
- [16] C. S. Foster, "Fungal keratitis," *Infectious Disease Clinics of North America*, vol. 6, no. 4, pp. 851–857, 1992.
- [17] C. L. Karp, S. S. Tuli, S. H. Yoo et al., "Infectious keratitis after LASIK," *Ophthalmology*, vol. 110, no. 3, pp. 503–510, 2003.
- [18] D. S. C. Lam, A. T. S. Leung, J. T. Wu, D. S. P. Fan, A. C. K. Cheng, and Z. Wang, "Culture-negative ulcerative keratitis after laser in situ keratomileusis," *Journal of Cataract and Refractive Surgery*, vol. 25, no. 7, pp. 1004–1008, 1999.
- [19] G. Naumann, W. R. Green, and L. E. Zimmerman, "Mycotic keratitis. A histopathologic study of 73 cases," *American Journal of Ophthalmology*, vol. 64, no. 4, pp. 668–682, 1967.
- [20] M. A. Chang, S. Jain, and D. T. Azar, "Infections following laser in situ keratomileusis: an Integration of the published literature," *Survey of Ophthalmology*, vol. 49, no. 3, pp. 269–280, 2004.
- [21] F. Llovet, V. de Rojas, E. Interlandi et al., "Infectious Keratitis in 204 586 LASIK Procedures," *Ophthalmology*, vol. 117, no. 2, pp. 232–238, 2010.