

## Acute Hydrocephalus Caused by Cerebellar Abscess in HIV-Negative Castleman's Disease

### Abstract

Castleman's disease (CD) is a rare and indolent hematologic disorder characterized by solitary bulky adenopathy. Multiple nodal nonbulky localizations are described, while central nervous system involvement is rare. Immunodeficiency is associated with higher incidence of CD, and HIV serology should be performed at initial diagnosis. We report the case of a 64-year-old HIV-negative man affected by CD, presenting with acute hydrocephalus caused by a large cerebellar abscess.

**Keywords:** *Castleman's disease, cerebral abscess, HIV, hydrocephalus, stereotactic brain surgery*

### Introduction

Castleman's disease (CD) is a rare hematologic disorder involving lymphoid tissue proliferation that was first described by Castleman in 1956. This condition is also known as angiofollicular lymph node hyperplasia. In more than 70% of cases, CD presents as a solitary mediastinal or cervical mass with an indolent course.<sup>[1,2]</sup> The etiology of CD is unclear. Several origins have been proposed, such as immunocompromised states, chronic inflammation or infection, and autoimmune processes.<sup>[3,4]</sup> Correlations between CD and HIV and human herpesvirus (HHV)-8 infections have been found, probably because of immunosuppression. The involvement of the central nervous system is rare, and only a few cases of meningeal localization of CD have been reported.<sup>[5]</sup> Data are lacking about the incidence of cerebral abscesses, which are more usual in HIV patients. We present the case of a 64-year-old HIV-negative man with acute hydrocephalus caused by a large cerebellar abscess.

### Case Report

We present the clinical findings regarding a 64-year-old man, affected by arterial hypertension with heart and chronic renal failure.

Six months before coming to our attention, the patient suffered weakness

This is an open access journal, and articles are distributed under the terms of the Creative Commons Attribution-NonCommercial-ShareAlike 4.0 License, which allows others to remix, tweak, and build upon the work non-commercially, as long as appropriate credit is given and the new creations are licensed under the identical terms.

For reprints contact: reprints@medknow.com

and nausea with weight loss. A computed tomography (CT) of the thorax and abdomen showed diffuse lymph node involvement, without spleen enlargement. The lymph node biopsy revealed that he was affected by CD. Viral infections commonly related with CD (HIV and HHV-8) were excluded, except for a previous Epstein-Barr virus and herpes simplex virus infection. The patient was treated with chemotherapy, and his hematologic conditions improved.

A few days before the admission, he suffered from fever, headache, and gait imbalance. The patient was admitted to our Intensive Care Unit because of acute neurological deterioration with lethargy and unresponsiveness (Glasgow Coma Scale score 6). The head CT showed a hypodense lesion in the left cerebellar hemisphere with fourth ventricle and brainstem compression, upward cerebellar herniation, and triventricular hydrocephalus with trans-ependymal reabsorption of cerebrospinal fluid [Figure 1]. The lobulated lesion showed a marked enhancement, and the magnetic resonance imaging of the brain revealed the presence of a similar smaller lesion in the right parietal lobe [Figure 2]. The blood cell count showed 41,000 leukocytes/mm<sup>3</sup>. These findings were suggestive of abscess. We urgently positioned an external ventricular drainage in the right frontal horn, and the patient's neurological status improved after treatment of hydrocephalus. The following day, we performed a

**How to cite this article:** Rusconi A, Dario A, Agresta G, Balbi S. Acute hydrocephalus caused by cerebellar abscess in HIV-negative castleman's disease. *Asian J Neurosurg* 2019;14:1037-9.

**Angelo Rusconi,  
Alessandro Dario<sup>1</sup>,  
Gianluca Agresta,  
Sergio Balbi**

*Department of Biotechnology and Life Sciences, University of Insubria, <sup>1</sup>Neurosurgical Unit, Ospedale Di Circolo, Varese, Italy*

### Address for correspondence:

*Dr. Angelo Rusconi,  
Department of Biotechnology and Life Sciences, University of Insubria, Via JH Dunant 3, 21100 Varese, Italy.  
E-mail: angelo.rusconi@hotmail.com*

### Access this article online

**Website:** [www.asianjns.org](http://www.asianjns.org)

**DOI:** 10.4103/ajns.AJNS\_32\_17

### Quick Response Code:



minimally invasive aspiration, by means of a navigated stereotactic puncture of the lesion. The diagnosis of suppuration was confirmed. Since no specific microorganism was isolated, intravenous broad-spectrum antibiotic therapy was administered (cefotaxime 2 g every 6 h and metronidazole 500 mg every 8 h). The neurological symptoms gradually resolved, the ventricular drainage catheter was removed after 9 days, and the CT scan showed a reduction of the lesion with reexpansion of the fourth ventricle and resolution of hydrocephalus [Figure 3]. The patient was discharged and advised physical therapy, and the antibiotic therapy was discontinued after 10 weeks.

## Discussion

In most patients, brain abscess results from predisposing factors, such as underlying disease (e.g., infection with the human immunodeficiency virus), a history of treatment with immunosuppressive drugs, disruption of the natural protective barriers surrounding the brain (due to an operative procedure, trauma, and mastoiditis), or a systemic source of infection (e.g., endocarditis, congenital heart defects, and pulmonary arteriovenous fistulas).<sup>[6,7]</sup> The hematogenous spread of bacteria might also be related to cutaneous, paranasal, or dental foci of infection. Higher incidence rates have been observed in immunocompromised states and in HIV patients.<sup>[6]</sup>

CD is a condition associated with immunosuppression and frequently related with HIV infection, but no data are available about the central nervous system involvement. Only a few cases of leptomeningeal localization have been described.<sup>[5]</sup> Arima *et al.* reported a case of intraventricular chordoid meningioma associated with CD, probably due to interleukin-6 overproduction.<sup>[8]</sup>

In a literature review of 13 cases of meningeal CD, Matsumura *et al.*<sup>[9]</sup> reported that the mean age of presentation was 50 years and the most common location was the cerebral convexity. Only one case occurred in the posterior fossa.

Seizure was the most common clinical manifestation, followed by focal neurological sign and increased intracranial pressure. Clinical outcome was good in all cases after surgical removal of the lesion, and no recurrence was found. Since CD usually presents as a solitary lesion, prognosis is favorable after resection.

To our knowledge, no correlations between CD and brain abscess can be found in the literature. Our patient was affected from CD, but HIV and other viral infections were not present, and he was not immunocompromised. The patient harbored a large posterior cranial fossa abscess, and he developed acute triventricular hydrocephalus, due to fourth ventricle compression. His neurological deterioration was due to both ventricular enlargement and brainstem mass effect.

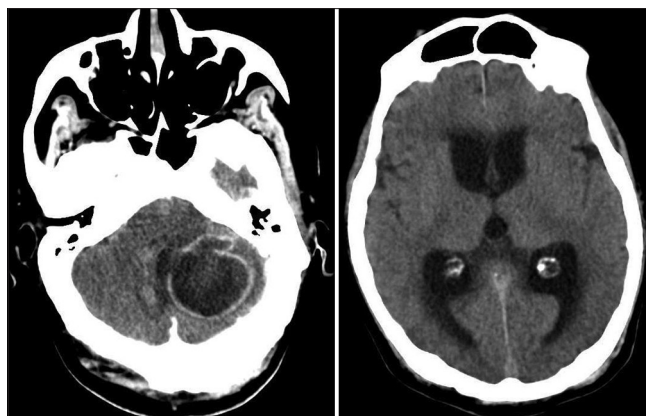


Figure 1: Contrast-enhanced head computed tomography showing large cerebellar mass with fourth ventricle and brainstem compression (left) and triventricular hydrocephalus (right)

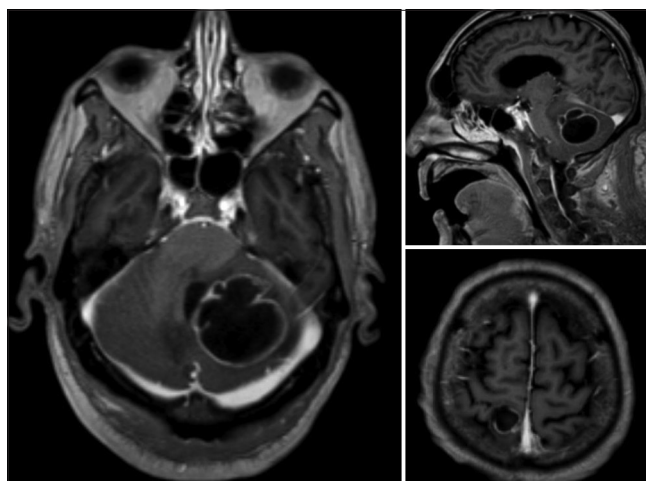


Figure 2: T1-weighted magnetic resonance imaging of the brain. Axial (left) and sagittal (top right) views showing enhancing cerebellar abscess; axial view showing a right parietal abscess (bottom right)

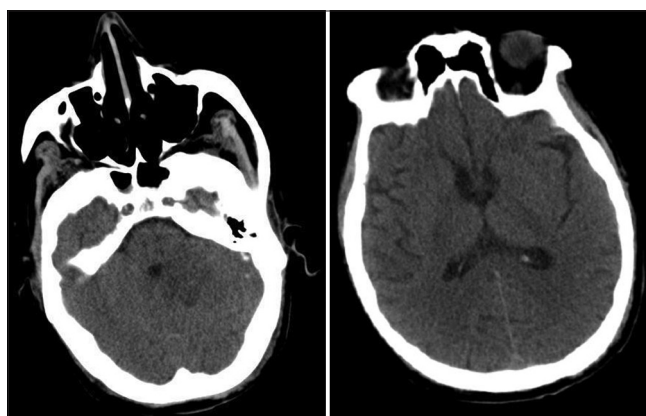


Figure 3: Postoperative head computed tomography revealing a reduction of the lesion with reexpansion of the fourth ventricle (left) and resolution of hydrocephalus (right)

Neurosurgical management of brain abscesses is directed to the relief of mass effect and to the identification of the causative pathogen, although cultures from cerebral abscesses are sterile in up to 25% of cases. With the use

of stereotactic neurosurgical techniques, brain abscesses are often amenable to stereotactic aspiration.<sup>[6,7]</sup> In our case, we choose to perform a ventricular catheterization first, to treat hydrocephalus, and to perform a stereotactic, frameless puncture of the abscess. The mass effect on cerebellar parenchyma and brainstem was reduced. Moreover, decompression of the fourth ventricle permitted the resolution of hydrocephalus, without the need for permanent shunting. Even though no specific pathogen was revealed by the cultures, broad-spectrum antibiotics were administered for 10 weeks, and the patient could return to his normal activity.

In conclusion, CD rarely involves the central nervous system and only a few cases of meningeal localization are reported. No cases of cerebral abscess are described, least of all in immunocompetent, HIV-negative patients. This is the first report of acute hydrocephalus in CD, due to a cerebellar abscess with fourth ventricle obliteration. We separately treated hydrocephalus and the abscess, with resolution of both conditions by means of minimally invasive procedures.

#### Ethical approval

All procedures performed in studies involving human participants were in accordance with the ethical standards of the Institutional and National Research Committee.

#### Informed consent

Informed consent was obtained from the patient included in the study.

#### Declaration of patient consent

The authors certify that they have obtained all appropriate patient consent forms. In the form, the patient has given his consent for his images and other clinical information to be reported in the journal. The patient understands that

name and initials will not be published and due efforts will be made to conceal identity, but anonymity cannot be guaranteed.

#### Financial support and sponsorship

Nil.

#### Conflicts of interest

There are no conflicts of interest.

#### References

1. Cronin DM, Warnke RA. Castleman disease: An update on classification and the spectrum of associated lesions. *Adv Anat Pathol* 2009;16:236-46.
2. Talat N, Belgaumkar AP, Schulte KM. Surgery in castleman's disease: A systematic review of 404 published cases. *Ann Surg* 2012;255:677-84.
3. Talat N, Schulte KM. Castleman's disease: Systematic analysis of 416 patients from the literature. *Oncologist* 2011;16:1316-24.
4. Zhu SH, Yu YH, Zhang Y, Sun JJ, Han DL, Li J, *et al.* Clinical features and outcome of patients with HIV-negative multicentric castleman's disease treated with combination chemotherapy: A report on 10 patients. *Med Oncol* 2013;30:492.
5. Coca S, Salas I, Martínez R, Saez MA, Vaquero J. Meningeal castleman's disease with multifocal involvement: A case report and review of literature. *J Neurooncol* 2008;88:37-41.
6. Brouwer MC, Tunkel AR, McKhann GM 2<sup>nd</sup>, van de Beek D. Brain abscess. *N Engl J Med* 2014;371:447-56.
7. Ko SJ, Park KJ, Park DH, Kang SH, Park JY, Chung YG, *et al.* Risk factors associated with poor outcomes in patients with brain abscesses. *J Korean Neurosurg Soc* 2014;56:34-41.
8. Arima T, Natsume A, Hatano H, Nakahara N, Fujita M, Ishii D, *et al.* Intraventricular chordoid meningioma presenting with Castleman disease due to overproduction of interleukin-6. *Case report. J Neurosurg* 2005;102:733-7.
9. Matsumura K, Nakasu S, Tanaka T, Nioka H, Matsuda M. Intracranial localized castleman's disease. *Case report. Neurol Med Chir (Tokyo)* 2005;45:59-65.