

[CASE REPORT]

Coronary Artery Spasm During Catheter Ablation Caused by the Intravenous Infusion of Isoproterenol

Yoshiyuki Okuya¹, Jae Yoon Park^{1,2}, Anuj Garg^{1,2} and Issam Moussa^{1,2}

Abstract:

Radiofrequency ablation is an established treatment for atrial fibrillation (AF). However, coronary artery spasm (CAS) is a rare but a potentially lethal complication associated with this procedure. A 54-year-old man with paroxysmal AF underwent pulmonary vein isolation. The procedure was completed and AF could not be induced after burst pacing and the administration of isoproterenol. Suddenly, ST-segment elevation developed in the anterior leads and frequent premature ventricular contractions followed by non-sustained ventricular fibrillation. The diagnosis of CAS was made by urgent coronary angiography. We identified isoproterenol as a potential cause of CAS. Physicians should be aware of this potentially lethal side effect.

Key words: coronary artery spasm, isoproterenol, catheter ablation, atrial fibrillation

(Intern Med 60: 1221-1224, 2021)

(DOI: 10.2169/internalmedicine.6130-20)

Introduction

Radiofrequency (RF) ablation has become a standard treatment modality for atrial fibrillation (AF), and it is generally considered to be a safe procedure. However, serious complications can occur. Case reports demonstrating coronary artery spasm (CAS) as a potential lethal complication of catheter ablation for AF have been published (1, 2). The occurrence of CAS during RF ablation is probably multifactorial, and its underlying mechanisms have not yet been fully determined. We herein report a patient who experienced severe CAS during RF ablation for AF due to the intravenous infusion of isoproterenol.

Case Report

A 54-year-old Caucasian man with history of hypertension, atrial flutter, nicotine dependence, and alcohol abuse was referred to our institution for RF ablation of paroxysmal AF. He previously underwent cavo-tricuspid isthmus ablation of atrial flutter and had isoproterenol infusion post ablation without any complications. The patient had been implanted with a loop recorder eighteen months prior to this

presentation. His height was 180 cm and body weight was 90.4 kg. He had no known allergies or family history of sudden death or cardiac disease. He had no prior resting or exercising angina, and a pharmacologic nuclear stress test demonstrated normal myocardial perfusion with normal wall motion prior to the procedure.

The ablation strategy employed pulmonary vein isolation under general anesthesia. There was no hemodynamic instability nor hypoxemia during the procedure. The sheath was removed from left atrium. AF could not be induced after burst pacing and the administration of isoproterenol at 5 µg/min. Therefore, the procedure was concluded.

Six minutes after stopping isoproterenol, the 12 lead surface electrocardiogram showed ST-segment elevation in the anterior and inferior leads and frequent premature ventricular contractions followed by non-sustained ventricular fibrillation (Fig. 1A). Urgent coronary angiography was performed which showed an occluded mid-left anterior descending artery and moderate-severe narrowing of left circumflex artery and right coronary artery (Fig. 1B). After the intracoronary administration of 200 µg nitroglycerin, the coronary narrowing and ST-segment elevation resolved (Fig. 2A, B). Diltiazem was added to the patient's medical regimen and he was discharged the following day without

¹Heart and Vascular Institute, Carle Foundation Hospital, USA and ²Carle Illinois College of Medicine, University of Illinois - Urbana Campaign, USA

Received: August 17, 2020; Accepted: September 23, 2020; Advance Publication by J-STAGE: November 9, 2020

Correspondence to Dr. Yoshiyuki Okuya, Yoshiyuki.Okuya@carle.com

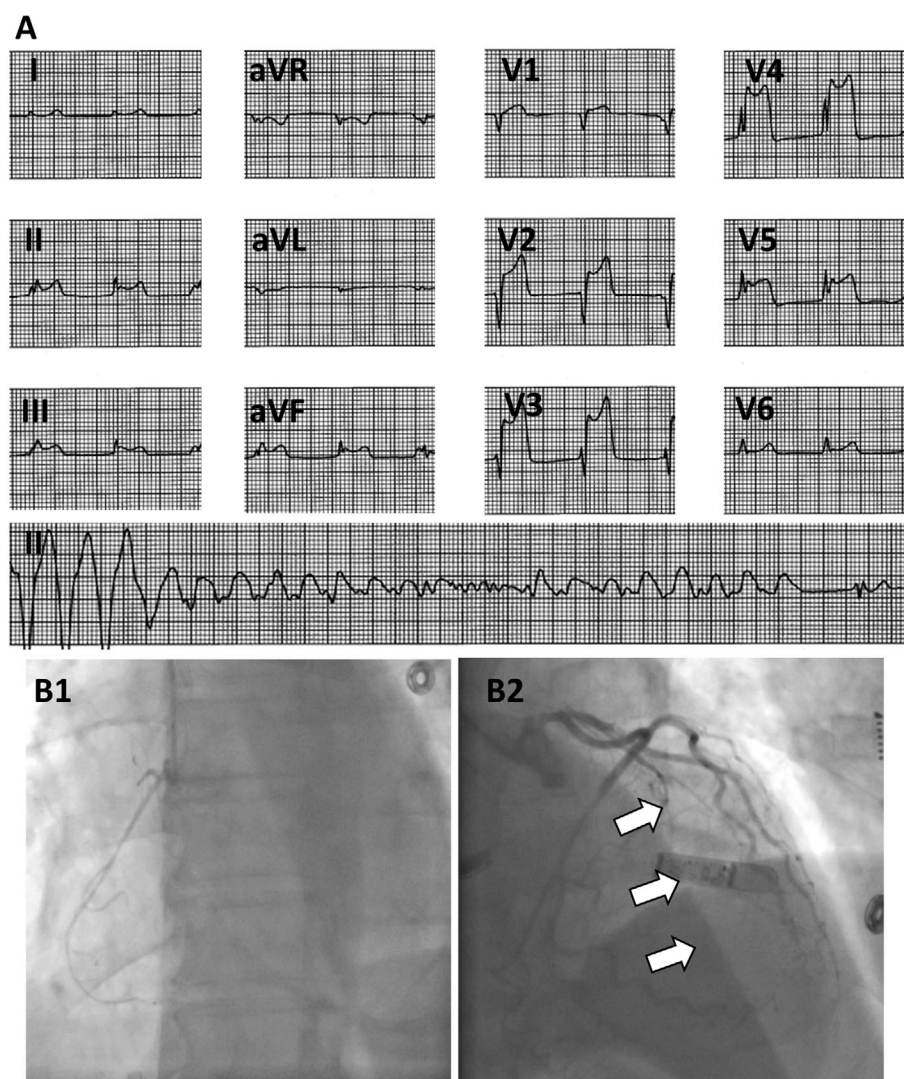


Figure 1. The 12-lead surface electrocardiogram showed ST-segment elevation in the anterior and inferior leads and frequent premature ventricular contractions followed by non-sustained ventricular fibrillation (A). Coronary angiography showed an occluded mid-left anterior descending artery (arrow) and moderate-severe narrowing of left circumflex artery and right coronary artery (B).

any complications. Smoking and alcohol intake were strictly prohibited.

Discussion

RF ablation is an established treatment for AF in terms of efficacy and safety. However, coronary artery related complications have been reported after RF ablation; these include direct thermal injury by RF energy (3), embolus (4) and CAS (1, 2, 5). To the best of our knowledge, this is the first case which showed severe CAS on angiography caused by isoproterenol during catheter ablation.

Patients with paroxysmal AF have high positive rates of drug-provoked CAS (6). Although the underlying mechanism responsible for CAS remains unclear, CAS during and after catheter ablation has been attributed to several different mechanisms such as direct thermal damage from RF energy to coronary artery (7), indirect effects via cryoenergy-

induced blood cooling (8), an imbalance in the autonomic nervous system activity caused by the affected ganglionated plexus through a thermal or cooling injury (1), and an imbalance in the autonomic discharge, such as stimulation of α -2 adrenergic receptors induced by dexmedetomidine (9). The CAS in the present case occurred after the ablation procedure. Moreover, neither cryoballoon nor dexmedetomidine was used. The present case was a rare case which showed CAS caused by isoproterenol infusion. The use of isoproterenol in the electrophysiology lab to study triggers of AF is well established (10). The mechanisms which isoproterenol induces AF may include an increase in intracellular calcium that facilitates abnormal automaticity or early after depolarizations and triggered activity. Accentuated antagonism leading to enhanced parasympathetic tone also may play a role in the inducibility of AF by isoproterenol (11). The relationship between the autonomic nervous system and CAS is complex. Although the parasympathetic activity is well

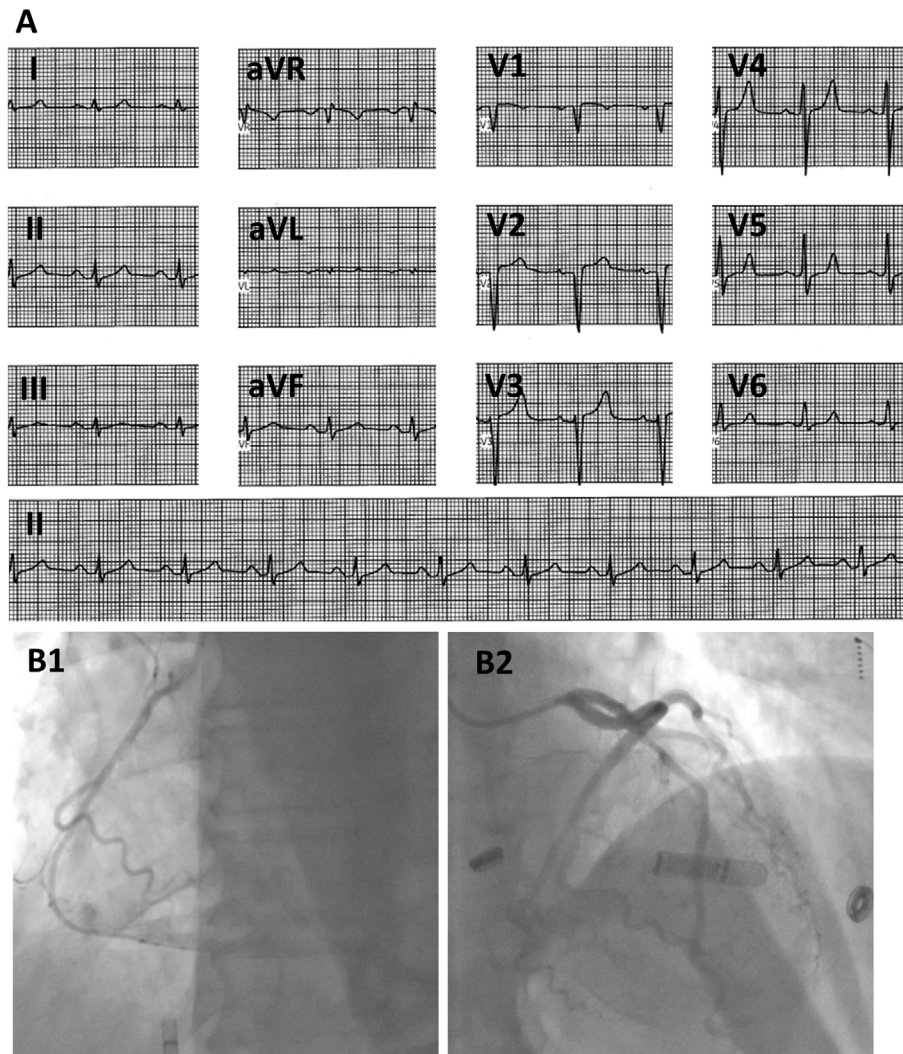


Figure 2. After the intracoronary administration of nitroglycerin, the 12-lead surface electrocardiogram showed an improvement of ST-segment elevation (A), and angiographic stenosis (B).

known to be a trigger of CAS, sympathetic stimuli may also play a role. CAS has been shown to occur more frequently during the rapid eye movement phase of sleep at night when there is a reduction in vagal activity and an increase in adrenergic activity (12), suggesting that CAS is not necessarily induced by parasympathetic activity. Moreover, several case reports have suggested that CAS can be induced by various sympathetic related stimuli (13, 14). Hung et al. showed that a head-up tilt test with isoproterenol can provoke CAS, which suggests that the induction of CAS is associated with a rapid elevation of sympathetic activity during augmented parasympathetic activity (15). The present case report describes the intravenous administration of isoproterenol, a non-selective β adrenoreceptor agonist, as a potential cause of CAS during catheter ablation for AF. Physicians should be aware of this potentially lethal side effect. A thorough preoperative history should be taken to determine whether a patient has a risk of CAS. The main risk factors for CAS are age, a smoking history, Japanese ethnicity, hypertension, and diabetes mellitus, and it can be precipitated by various factors such as mental exercise, cold ex-

posure, hyperventilation, or alcohol consumption (16). Although this patient was Caucasian and did not have alcohol flushing syndrome, the present case had history of nicotine dependence and alcohol abuse. Mizuno et al. reported that East Asian variants of the aldehyde dehydrogenase 2 genotype was associated with CAS in Japanese (17). The administration of a calcium channel blocker and smoking cessation before RF ablation may avoid CAS during these procedures. The 12-lead electrocardiogram should be continuously monitored throughout the procedure with special attention to ischemic changes. Moreover, coronary angiography and the administration of coronary vasodilator should be performed when ST changes are observed.

Conclusions

Isoproterenol administration during AF ablation may provoke severe CAS, possibly due to an autonomic nervous system imbalance. This is a rare complication of AF ablation and it should be considered when performing these procedures.

The authors state that they have no Conflict of Interest (COI).

References

- Hishikari K, Kuwahara T, Takahashi A, Isobe M. Severe coronary artery spasm during radiofrequency ablation for atrial fibrillation. *Int J Cardiol* **172**: e513-e515, 2014.
- Yajima K, Yamase Y, Oishi H, Ikehara N, Asai Y. Coronary artery spasm during cryoballoon ablation in a patient with atrial fibrillation. *Intern Med* **57**: 819-822, 2018.
- Wong KC, Lim C, Sadarmin PP, et al. High incidence of acute sub-clinical circumflex artery 'injury' following mitral isthmus ablation. *Eur Heart J* **32**: 1881-1890, 2011.
- Kuwahara T, Takahashi A, Takahashi Y, et al. Clinical characteristics of massive air embolism complicating left atrial ablation of atrial fibrillation: lessons from five cases. *Europace* **14**: 204-208, 2012.
- Tada H, Naito S, Oshima S, Taniguchi K. Vasospastic angina shortly after left atrial catheter ablation for atrial fibrillation. *Heart Rhythm* **2**: 867-870, 2005.
- Kawakami T, Ohno H, Tanaka N, Ishihara H, Kobayakawa H, Sakurai T. The relationship between paroxysmal atrial fibrillation and coronary artery spasm. *Pacing Clin Electrophysiol* **37**: 591-596, 2014.
- Takahashi Y, Jaïs P, Hocini M, et al. Acute occlusion of the left circumflex coronary artery during mitral isthmus linear ablation. *J Cardiovasc Electrophysiol* **16**: 1104-1107, 2005.
- Lehrmann H, Potocnik C, Comberg T, et al. Near-fatal coronary artery spasm during cryoballoon pulmonary vein isolation: an unreported complication. *Circ Arrhythm Electrophysiol* **7**: 1273-1274, 2014.
- Furui K, Morishima I, Kanzaki Y, Tsuboi H. Coronary vasospasm caused by intravenous infusion of dexmedetomidine: unrecognized pitfall of catheter ablation procedures of atrial fibrillation. *J Cardiol Cases* **20**: 221-224, 2019.
- Oral H, Crawford T, Frederick M, et al. Inducibility of paroxysmal atrial fibrillation by isoproterenol and its relation to the mode of onset of atrial fibrillation. *J Cardiovasc Electrophysiol* **19**: 466-470, 2008.
- Oral H, Ozaydin M, Tada H, et al. Mechanistic significance of intermittent pulmonary vein tachycardia in patients with atrial fibrillation. *J Cardiovasc Electrophysiol* **13**: 645-650, 2002.
- Otsuka K, Yanaga T, Watanabe H. Variant angina and REM sleep. *Am Heart J* **115**: 1343-1346, 1988.
- Lindsay PJ, Frank RC, Bittner EA, Berg S, Chang MG. ST elevations and ventricular tachycardia secondary to coronary vasospasm upon extubation. *Case Rep Anesthesiol* **2020**: 1527345, 2020.
- Sogut O, Kaya H, Gokdemir MT, Sezen Y. Acute myocardial infarction and coronary vasospasm associated with the ingestion of cayenne pepper pills in a 25-year-old male. *Int J Emerg Med* **5**: 5, 2012.
- Hung MJ, Wang CH, Cherng WJ. Provocation of coronary vasospastic angina using an isoproterenol head-up tilt test. *Angiology* **55**: 271-280, 2004.
- Matta A, Bouisset F, Lhermusier T, et al. Coronary artery spasm: new insights. *J Interv Cardiol* **2020**: 5894586, 2020.
- Mizuno Y, Harada E, Morita S, et al. East asian variant of aldehyde dehydrogenase 2 is associated with coronary spastic angina: possible roles of reactive aldehydes and implications of alcohol flushing syndrome. *Circulation* **131**: 1665-1673, 2015.

The Internal Medicine is an Open Access journal distributed under the Creative Commons Attribution-NonCommercial-NoDerivatives 4.0 International License. To view the details of this license, please visit (<https://creativecommons.org/licenses/by-nc-nd/4.0/>).