



Oncology

Prostate preserving resection of a rare giant peri-prostatic solitary fibrous tumor

Brent Gilbert^{a,**}, Andrew Csillag^c, Devang Desai^{a,b,c}, Scott McClintock^c^a The University of Queensland, Brisbane, QLD, Australia^b The Princess Alexandra Hospital, Brisbane, QLD, Australia^c Gold Coast University Hospital, Gold Coast, QLD, Australia

ARTICLE INFO

Keywords:

Prostate

Solitary fibrous tumor

ABSTRACT

Solitary fibrous tumors (SFTs) are rare mesenchymal neoplasms that have been infrequently documented in the prostate. In this case, a 78 year old man experiencing constipation and lower abdominal pain presented with a SFT arising from the prostatic fascia encompassing the dorsal vein complex and left neurovascular bundle. To our knowledge this is the first documented case of an SFT limited to the prostatic fascia and neurovascular tissues of the prostate. Using a prostate sparing approach we have been able to achieve favourable oncological and functional outcome.

Background

Solitary Fibrous tumors (SFTs) are rare mesenchymal tumors of fibroblastic origin that histologically, share a patternless, storiform distribution of spindle cells within a collagenous stroma.¹ SFTs can arise in various parts of the body but only recently been documented in the prostate.² The clinical course of SFTs is quite variable. Conventional SFTs have been labelled as an intermediate, rarely metastasizing, neoplasm with indolent clinical behavior. 20% of SFTs will be malignant, and despite surgical resection, local recurrence and metastasis can occur.³ A rare form of dedifferentiated SFT has also been described which can progress from conventional benign SFT to high grade sarcomas. As such SFTs should be surgically resected.

SFT arising from the prostate is rare and conventional and malignant SFT variants have been documented.³ Prostate SFTs are challenging presentations because tumor origin and the level of invasion is difficult to determine. The full extent of disease is only fully appreciated once resection is performed and histology analyzed. Here, we describe the first case where a SFT extends from prostatic fascia and involves the dorsal vein complex and neurovascular bundle but left glandular tissue intact.

Case study

A well 78 year old male presented with progressive constipation and

sporadic episodes of lower abdominal pain over two months. He denied having urinary tract symptoms, rectal bleeding or systemic features of illness. On examination he was mildly distended and tender in the lower abdomen. Per-rectal examination revealed a large and firm left hemi-prostate; the rectum was empty and rectal mucosa mobile. Apart from mild renal impairment, laboratory investigations, including PSA (2.0mg/mL) were within normal range.

Initial computer tomography (CT) imaging revealed a 53 × 35mm left sided peri-prostatic mass with heterogeneous enhancement and well defined margins (Fig. 1A). A follow up MRI showed a contrast-enhancing, solid, large mixed solid/cystic mass next to the left base of the bladder. The origin of the mass was indeterminate by these scans.

Cystoscopy showed a normal prostate urethra (PU) mucosa with moderate indentation on the left side extending into the base of the bladder. Endoscopic resection of the indentation was performed and histological analysis reported prominent hyperchromatic elongated nucleoli with positive PSA staining and was given a ISUP Grade-1 in <5% of tissue and the bladder tissue was suggestive of a papillary urothelial neoplasm of low malignant potential (PUNLMP). Given the size, structure and location of the lesion, the consensus was that the histological results were not representative of the medical imaging.

The patient was reviewed six weeks later and his symptoms had not resolved nor progressed. His PSA remained stable and repeat CT imaging showed that the mass had grown in size (63.2 × 46mm) and was impacting the local anatomy (Fig. 1B). The patient underwent an

* Corresponding author. University of Queensland, Brisbane, QLD, 4006, Australia.

E-mail address: brent.gilbert@health.qld.gov.au (B. Gilbert).

<https://doi.org/10.1016/j.eucr.2020.101167>

Received 11 February 2020; Received in revised form 5 March 2020; Accepted 11 March 2020

Available online 2 April 2020

2214-4420/© 2020 Published by Elsevier Inc. This is an open access article under the CC BY-NC-ND license (<http://creativecommons.org/licenses/by-nc-nd/4.0/>).

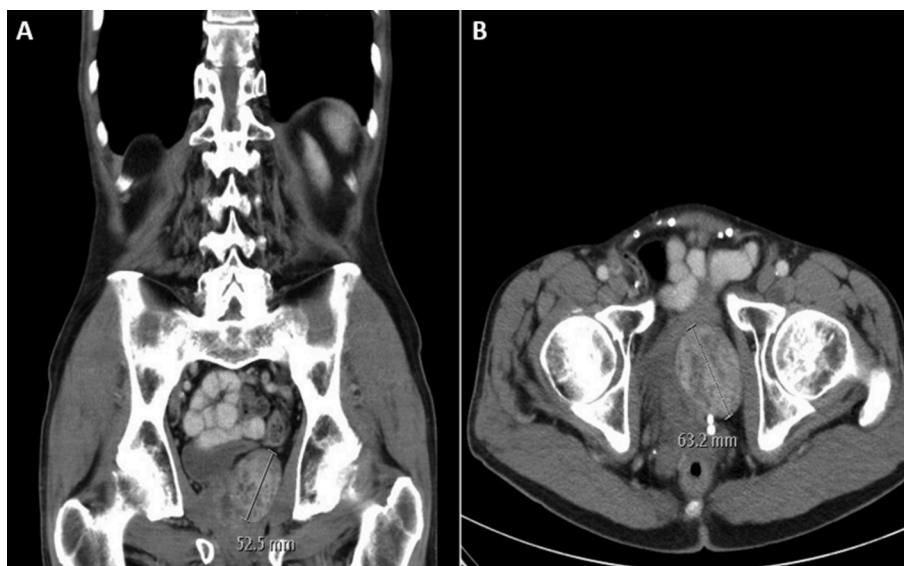


Fig. 1. CT Imaging of a Periprostatic SFT. A) Coronal CT image and B) Axial CT imaging shows a large left side periprostatic mass with heterogeneous enhancement and mass effect on surrounding structures.

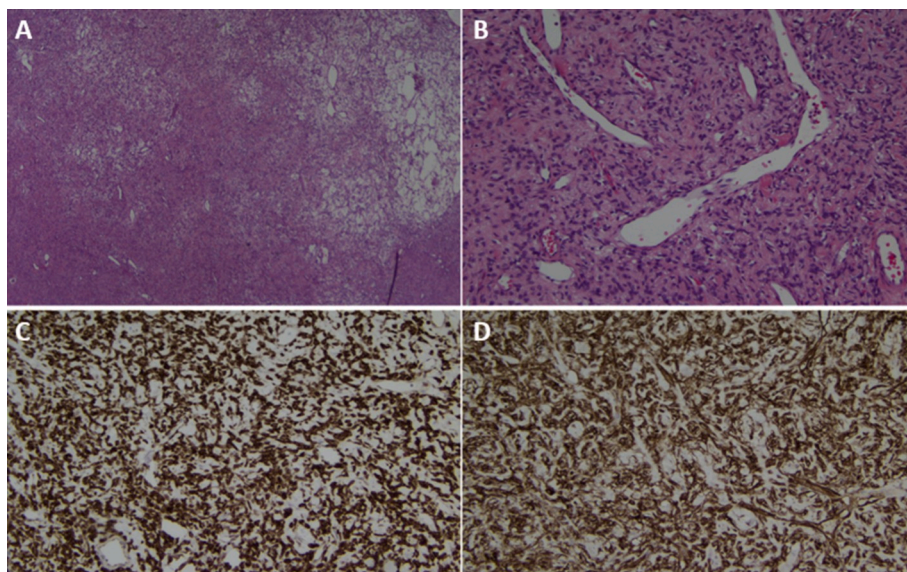


Fig. 2. Histology and Immunohistochemistry of a Periprostatic SFT. A) Low power (x20 magnification) H&E stain showing a patternless architecture of spindle cells with alternating hypercellular and hypocellular areas. B) Medium power (x100 magnification) H&E stain showing branching blood vessels, spindle-shaped tumor cells interspersed with collagenous stroma. C) BCL-2 immunohistochemical stain positive (x100 mag) D) CD34 immunohistochemical stain positive (x100 mag).

exploratory lower midline laparotomy which revealed an encapsulated tumor on the anterolateral prostate. It extended from the left neurovascular bundle and was surrounded by the dorsal venous complex. The firm tan mass was well circumscribed and smooth and was excised using a prostate sparing technique. Histological investigation revealed a nodular mass composed of spindle cells with intermixed hypocellular collagen networks and cellular areas. It had a distinct haemangiopericytoma vascular network. The mitotic rate was low (<1 mitosis/10 HPFs) and limited pleiomorphism was noted. The specimen stained positive for CD34, BCL2, STAT6 and vimentin and negative for AE1/AE3, CD117 and cytokeratin. In summary, the tumor appeared to be a non-malignant SFT (Fig. 2).

The operative procedure was uncomplicated and postoperative recovery period was uneventful. Four weeks post procedure the patient had reported his bowel habits improved and abdominal pain resolved. At 12 months, the patient remained asymptomatic and had no further recurrence.

Discussion

SFTs of the prostate are rare, with cases reported in patients 21–75 years old.⁴ The most common clinical findings include; urinary retention, frequency, dysuria, constipation, incontinence and abdominal pain. These tumors vary in size 2–14cm and weight 5g to >100g(4) and don't appear to impact PSA levels. Current imaging CT and MRI imaging modalities are non-specific and unable to differentiate SFT from other tumors of the prostate. As with the case described here, CT and MRI imaging was only used to confirm the tumor location and impact on surrounding structures.

Diagnosis of SFTs is only made through histological findings. Due to differences in clinical outcomes and management, prostate SFTs should be distinguished from other spindle cell neoplasms and malignant potential should be assessed.⁵ Macroscopically, benign SFT will have homogenous tan colour and may be capsulated. Malignant variants of SFT will show areas of hemorrhaging and necrosis and have infiltrative borders lacking a capsule. Microscopically, benign SFT are characterized

by a patternless distribution of spindle fibroblast cells within a collagenous stroma of branching haemangiopericytic vessels. The malignant potential of prostatic SFTs is difficult to predict but tumor size (>10 cm), mitotic activity (>4/10 HPFs), nuclear pleomorphism, hypercellularity, necrosis, infiltrative boundaries lacking a capsule and staining positive for Ki-67 have collectively been used to predict the malignant potential of SFTs with some success.⁵ Immunohistochemistry showing strong staining for CD34, CD99 and Bcl- 2 and the NAB-STAT6 fusion protein is indicative of SFT(1). Although not employed in this study, when diagnosis is questionable STAT6 staining should be used to help differentiate SFT from prostatic stromal lesions.

There are no available prognostic markers for SFT. Given the clinical course of SFTs it is essential to achieve clear surgical margins through complete resection. Compared to previously documented prostate SFTs this case is unique because it originated from the prostatic fascia. The neurovascular structures were involved but glandular tissue was spared. The location of the lesion enabled us completely resect the SFT and preserve the prostate and ensure sexual and urinary function remained intact.

From a diagnostic, therapeutic and prognostic view prostate SFT are

clinically challenging cases which have no guidelines dictating current best practice. Close surveillance may be suitable in select patients; however urologists should be mindful of the variable clinical course of SFTs. When possible surgical resection of the tumor and affected structures should be done with the aim of achieving clear surgical margins and preserving urinary and sexual function.

References

1. Thway K, Ng W, Noujaim J, Jones RL, Fisher C. The current status of solitary fibrous tumor: diagnostic features, variants, and genetics. *Int J Surg Pathol.* 2016;24(4): 281–292.
2. Wagner S, Greco F, Hamza A, Hoda RM, Holzhausen HJ, Fornara P. Retroperitoneal malignant solitary fibrous tumor of the small pelvis causing recurrent hypoglycemia by secretion of insulin-like growth factor 2. *Eur Urol.* 2009;55(3):739–742.
3. Ronchi A, La Mantia E, Gigantino V, et al. A rare case of malignant solitary fibrous tumor in prostate with review of the literature. *Diagn Pathol.* 2017;12(1):50.
4. Noguchi M, Hirabayashi Y, Kato S, Noda S. Solitary fibrous tumor arising from the prostatic capsule. *J Urol.* 2002;168(4 Pt 1):1490–1491.
5. Hansel DE, Herawi M, Montgomery E, Epstein JI. Spindle cell lesions of the adult prostate. *Mod Pathol.* 2007;20(1):148–158. an official journal of the United States and Canadian Academy of Pathology, Inc.