

Oncology

Direct Extension of Prostatic Adenocarcinoma Protruding Through the Urethral Meatus



Hasan Jhaveri^a, Kristen Combs^b, Faiyaaz Jhaveri^{b,c,*}

^a University of Virginia, Charlottesville, VA, USA

^b University of Central Florida College of Medicine, Orlando, FL, USA

^c Heart of Florida Regional Medical Center, Davenport, FL, USA

ARTICLE INFO

Article history:

Received 24 January 2017

Accepted 23 February 2017

Keywords:

Prostatic adenocarcinoma

Anterior urethra

Urethral meatus

ABSTRACT

Prostate cancer involving the anterior urethra is rare with few cases describing isolated recurrence to the anterior urethra. This case describes a patient with a history of metastatic prostate cancer who subsequently developed advanced prostate cancer involving the entire urethra with extension from the prostatic urethra to the urethral meatus. This will help future healthcare providers recognize this metastatic pattern as a possibility and explore this option when presented with a bleeding mass at the urethral meatus of unknown origin. It is important for clinicians to realize poorly differentiated prostate cancer may not produce PSA yet still behave aggressively.

© 2017 The Authors. Published by Elsevier Inc. This is an open access article under the CC BY-NC-ND license (<http://creativecommons.org/licenses/by-nc-nd/4.0/>).

Introduction

Overall, prostate cancer involving the anterior urethra is exceedingly rare. Isolated recurrence of metastatic prostate cancer to the anterior urethra has been reported in only ten cases.^{1–3} For these distinct, separate metastatic lesions, the mechanism of such metastases have been attributed to direct implantation by instrumentation, arterial tumor emboli, or possible venous or lymphatic dissemination in a retrograde manner.⁴ Direct extension of advanced prostate cancer has also been considered in these rare cases, although less likely, as those lesions were described as isolated from the primary tumor in the prostate. This case report describes the first case of direct extension of prostatic adenocarcinoma involving the entire urethra, extending from the prostatic urethra with protrusion through the urethral meatus.

Case report

We present the case of an 82-year-old man with history of metastatic prostate cancer who presented to the emergency room with a bleeding, fungating mass growing through the urethral meatus (Fig. 1). The patient is well known to our clinic initially

presenting over 2 years ago with a prostate-specific antigen (PSA) of 416.3 and prostate induration. The patient underwent a transurethral prostate biopsy for a Gleason score of 3 + 3 = 6 adenocarcinoma of the prostate followed by bilateral orchiectomies with a bone scan showing a superscan of diffuse bony metastasis. The patient was treated with palliative radiation therapy aimed at several areas of painful bony metastases. The patient's PSA dramatically dropped to 0.2 after bilateral orchiectomies and radiation therapy, and the patient clinically improved for several months. The patient then presented to the emergency room with back pain, urinary retention, and constipation requiring the use of Decadron. He was found to have a pathologic fracture of T11 causing spinal cord compression which required emergent fracture stabilization and tumor debulking. The subsequent pathologic report revealed metastatic poorly differentiated malignant neoplasm staining negative for PSA and prostatic specific acid phosphatase (PSAP) (Fig. 2). The serum PSA remained low at 0.26. Medical oncology services administered chemotherapy, bisphosphonate Zometa, and Prednisone to the treatment regimen. The patient recovered well and was able to void after catheter removal. However, 17 months later the patient developed hematuria and urethral bleeding with difficulty urinating. He underwent cystoscopy due to his urinary retention which revealed a large urethral mass extending from the prostatic urethra with direct extension past the membranous urethra which was causing occlusion of the lumen. The patient underwent cystoscopic biopsy of the urethral mass and suprapubic cystostomy tube placement to divert his urine.

* Corresponding author. University of Central Florida College of Medicine, Orlando, FL 32816, USA.

E-mail address: fjhaveri@msn.com (F. Jhaveri).

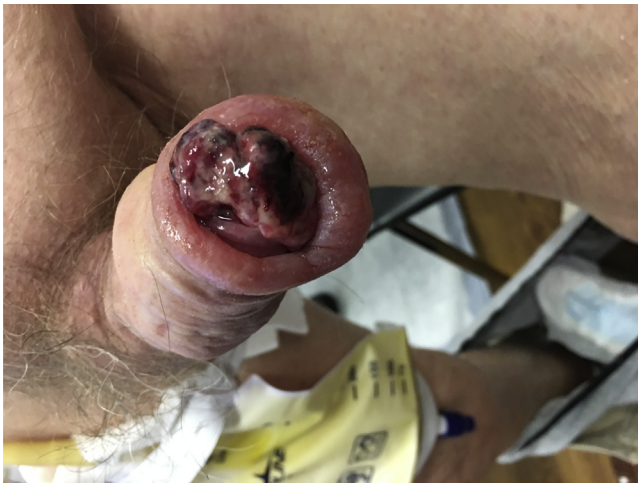

Figure 1. The image depicts the patient's indurated penis with a bleeding and fungating mass protruding through the urethral meatus.

Subsequent pathology report demonstrated poorly differentiated malignant neoplasm that stained negative for PSA and PSAP. Within 4 months, and despite a PSA of 0.14, the patient presented to the emergency room with a friable bleeding mass growing through the urethral meatus. Physical exam revealed severe induration of the penis and pubic region. Local wound care was applied with gauze dressings. Further treatment options were discussed with the patient and his family, but they have decided on comfort

measures and hospice care with no invasive treatments desired at this point.

Discussion

Taking into account the patient's clinical course, pathologic findings of the urethral mass and bony metastatic lesion, and markedly low serum PSA, it has been postulated that the original Gleason 6 adenocarcinoma has progressed to a higher grade tumor that is unable to produce PSA.

Although the urethral biopsy showed a poorly differentiated malignant neoplasm that stained negative for PSA, it is important to note, the occurrence of metastatic prostate cancer producing an undetectable or low serum PSA level is not rare⁵; therefore, this case is consistent with a prostate primary and not likely originating from a pelvic organ other than the prostate such as the urinary bladder, colon, or kidney. Primary urethral carcinoma is also unlikely due to the patient's severe metastatic prostate cancer clinical course and that the tumor is found on cystoscopy to extend directly from the prostate, at first through the membranous urethra and then to involve the entirety of the urethra, ultimately causing induration of the penis and pubic area. It is important to note the pathological findings of the metastatic bony lesion and urethral mass are identical and consistent with a poorly differentiated prostate adenocarcinoma. To our knowledge, no previous report had demonstrated prostatic adenocarcinoma spreading in this manner to growth through the urethral meatus.

Treatment options for this patient are focused on palliative care due to his poor prognosis from the advanced nature of his disease.

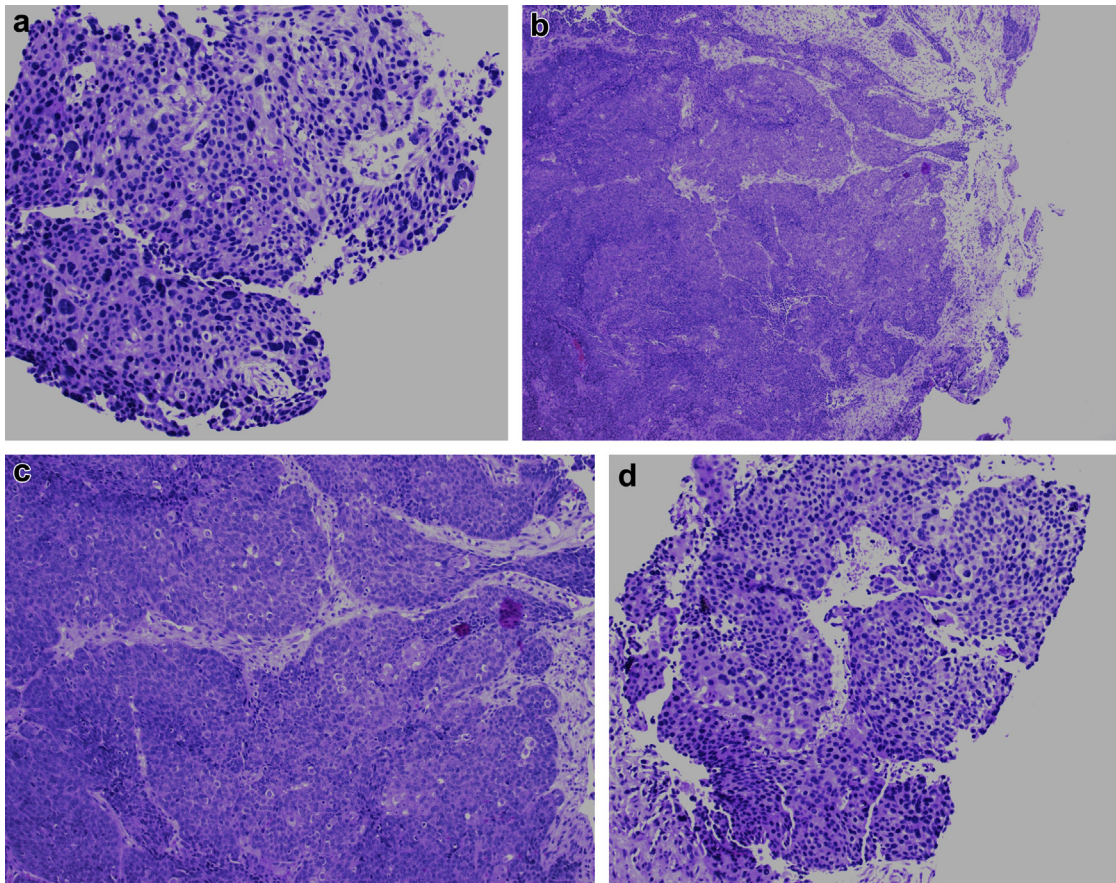


Figure 2. (a–d) These images depict the urethral biopsy photomicrograph showing poorly differentiated adenocarcinoma.

The patient's urine is already diverted with a suprapubic cystostomy tube. Surgical options for local control of his mass involving his entire penis, pubic area and growing through his urethral meatus could range from local debridement to partial and total penectomy. External radiation therapy could be considered and in one case intraurethral radioactive brachytherapy was used with palliative success.²

Due to the patient's advanced stage at the end of the his clinical course, partial or total penectomy was ruled out due to the out-weighing risks associated with the procedure and the patient's desire for no additional invasive treatments. Brachytherapy in this case is not likely indicated for tumor growing out of the urethral meatus. Palliative external radiation therapy remains an option, however, the patient's penile induration and edema may likely worsen with this approach.

Conclusion

The patient presented is the first known case of direct extension of prostatic adenocarcinoma involving the entire urethra, extending from the prostatic urethra with protrusion through the urethral meatus. Due to the patient's decision to forgo additional invasive

treatment options and the advanced nature of the disease, further treatment including surgical options and radiation are not indicated for this patient. Decision making on treatment options should be made on an individual patient basis for future patients presenting in a similar fashion.

Conflict of interest

There are no conflicts of interest.

References

1. Green JM, Tang WW, Jensen BW, Orihuela E. Isolated recurrence of ductal prostate cancer to anterior urethra. *Urology*. 2006;68(428):e13–e15.
2. de Porre P. Urethral metastases of a prostate cancer. A case report. *Strahlenther Onkol*. 1993 Apr;169(4):256–257.
3. Blanco Díez A, Ruibal Moldes M, Rodríguez-Rivera García J, et al. Metastasis of prostatic carcinoma to the urethra: report of a case. *Actas Urol Esp*. 2003 Oct;27(9):735–738.
4. Kobayashi T, Fukuzawa S, Oka H, et al. Isolated recurrence of prostatic adenocarcinoma to the anterior urethra after radical prostatectomy. *J Urol*. 2000;164(3):e780.
5. Lee DK, Park JH, Kim JH, et al. Progression of prostate cancer despite an extremely low serum level of prostate-specific antigen. *Korean J Urol*. 2010;51(5): 358–361.