

Larynx: implants and stents

Abstract

In the human larynx, implants are primarily used for the correction of glottis insufficiency. In a broader sense laryngeal stents may be considered as implants as well. Laryngeal implants can be differentiated into injectable and solid. The most important representatives of both groups are discussed in detail along with the respective technique of application. Laryngeal stents are primarily used perioperatively. Different types and their use are presented.

Keywords: glottic insufficiency, glottal gap, injection laryngoplasty, thyroplasty, laryngotracheal stenosis

Christian Sittel¹

1 Klinik für Hals-, Nasen-,
Ohrenkrankheiten, Plastische
Operationen, Klinikum
Stuttgart – Katharinen-
hospital, Stuttgart, Germany

1 Introduction

There is a great variety of devices to be put into the human larynx for medical reasons. It is a systematic difference whether only a limited use is intended, like in laryngeal stents. However, if the device is intended to remain in the larynx permanently the definition of a medical implant in the strict sense is fulfilled

2 Laryngeal implants

Surgical procedures aiming at closing a glottic insufficiency are by far the most important indications for laryngeal implants. Unilateral lower motor neuron type paralysis of the recurrent laryngeal nerve is the most common etiology for this condition. There are two main groups of products used for these procedures: Implants in the strict sense, which are made of solid material and are positioned into the paraglottic space via an open surgical approach by creating a window in the laryngeal framework. The idea is to bring the paralyzed vocal cord into a more median position. In contrast to that there are substances which are injected into the paralyzed cord in order to increase its volume and to reduce the glottal gap (injection laryngoplasty). Substances of high viscosity consisting of particles have been named “injectable implants” since they are serving the same purpose in the paraglottic space as solid implants for medialisation. The following gives an overview for both groups of implants.

2.1 Injectable implants

Probably the best known representative of this group is Teflon, which has been the most commonly used product for injection laryngoplasties between 1960 and 1980 [1]. Reports of Teflon particles having migrated to distant organs and repeated observations of severe foreign body granuloma have made Teflon paste obsolete for the use in humans [2], [3].

With textured particles consisting of polydimethylsiloxane (Vox Implants, until 2001 Bioplastique, producer: bioplasty bv, Geleen, Niederlande; distributor in Europe: Medtronic-Xomed, Düsseldorf) quite recently a material has become available which seems to offer characteristics comparable to Teflon while offering an excellent biocompatibility. With a mean size of about 200 μm these particles are not object to phagocytosis and migration, thus adding to their biological safety. There have been numerous reports showing a particle size of 65 μm as limit for lymphatic migration for polydimethylsiloxane particles [4]. Phagocytosis as key element of cell-mediated immune response like in foreign body reactions is not possible with particles of that size. For that reason and due to their non-organic basic structure hyperreagibility against polydimethylsiloxane particles have been observed neither in humans nor in animals [5], [6]. Therefore, anti-allergic testing prior to use is not necessary. Owing to this significant particle size the substance is of high viscosity, making the use of a high-pressure administration device mandatory. For the same reason the needle through which the substance is injected must be of sufficient gauge. In sharp contrast to resorbable materials polydimethylsiloxane particles need to be injected far lateral into the paraglottic space in order to avoid an irregular epithelial lining of the vocal cord surface. This localization is basically equal to external implants used in open thyroplasty. Therefore the term “injectable implants” has been coined for polydimethylsiloxane particles (Figure 1). It is not recommended to use this substance in the awake patient, since accurate positioning is of crucial importance. The material has been used in urology and facial plastic surgery for well over 15 years without remarkable substance-associated complications. In the human larynx several groups using polydimethylsiloxane particles have been able to show a permanent augmentation effect in the vocal fold leading to good functional results without formation of foreign body granuloma [7], [8], [9], [10], [11], [12]. Overcorrection is not necessary. In some cases relocation effects may occur, prior to definitive fixation of particles by sur-

rounding connective tissue. This may appear as migration and can be corrected by an additional injection. Polydimethylsiloxane particles have been approved to be used for injection laryngoplasty in the European Union since 2001.

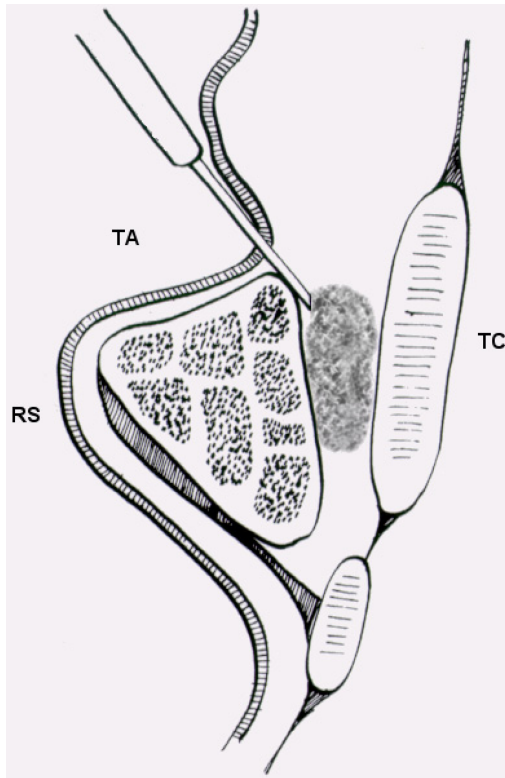


Figure 1: "Injectable Implant": augmentation in the paraglottic space

Recently a substance similar to polydimethylsiloxane particles has been approved by FDA in the USA, consisting of hydroxylapatite particles (Radiance FN, Bioform Inc., Franksville, Wisconsin/USA). The product is basically equal to a contrast enhancing substance having been developed for diagnostic radiology, technique of application is identical to that described for polydimethylsiloxane particles. Biochemically hydroxylapatite is identical to bone tissue, its excellent biocompatibility is well known from many medical applications in different fields. Main difference to polydimethylsiloxane particles is the potential resorption in human tissue at a rate which cannot be calculated. So far there are no data on functional effects or duration of the augmentation effect. While being officially approved in the US for use in the human larynx the product is not yet available on the European market.

2.2 Injectable, resorbable implants

In a broader sense substances may be considered as laryngeal implants if they are brought into the larynx without the primary intention of explantation at any point of time, even though they are subject to resorption in different time ranges depending on their respective biological characteristics.

Most popular representative of this group is bovine collagen, being in extensive use in aesthetic facial surgery. Experience with its use for injection laryngoplasty date back as far as 1986 [13], [14]. Preparations available are differing primarily in the concentration of bovine collagen in the solution that comes ready for injection (e.g. Zyderm1, Zyderm2, Collagen Aesthetics, Palo Alto, USA). There is a special preparation in which the collagen fibers are cross-linked, supposedly slowing the resorption process significantly [14]. The duration of the augmentation process according to different authors is ranging from 6–18 months. The existence of pre-formed antibodies against collagen in about 3% of patients makes allergy testing mandatory prior to use. A testing dosis is injected subcutaneously into the forearm and is being observed for 3 weeks. The site of augmentation should be the lamina propria of the vocal fold, because an intramuscular injection would lead to rapid resorption. Due to its low viscosity low-pressure injection through fine needles is possible, so application in the awake patient with surface anesthesia of the larynx is basically possible. So far there are no reports on substance-associated complications after injection laryngoplasty using collagen. According to the manufacturer a specially designed production process rules out any risk of prion transfer. However, collagen has still not yet been officially approved for injection laryngoplasty. This off-label use may cause reimbursement problems.

Hyaluronic acid has become an alternative to collagen due to its similar characteristics. This substance is present in connective tissue in humans and animals and is already being widely used in aesthetic surgery. Most products are of avine origin, but synthetically production is possible, too. Allergic reactions in persons with hypersensitivity against poultry proteins have been described, but allergic testing prior to use is not mandatory. Pure hyaluronic acid is resorbed rapidly and is usually embedded in hydrogels (Hylaform, Collagen Aesthetics Inc., Palo Alto, USA) to improve durability [15]. Only few data are available for vocal fold augmentation [16], [17], [18], the widespread use as filler in facial aesthetic surgery suggests a durability of 3–6 months. Therefore, hyaluronic acid seems suitable primarily for non-permanent injection laryngoplasty as in cases of recurrent laryngeal nerve palsy with electromyographically good prognosis, when temporary voice improvement is requested to bridge the time until recovery. For patients hesitating to decide for definitive thyroplasty or injection laryngoplasty it is often helpful to experience the possible result using a rapid resorbable, easy-to-use substance without any significant side-effects ("test-drive").

For more than 8 years processed collagen of human origin has been available to cover skin defects after burn trauma (Alloderm, LifeCell Corporation, Palo Alto, USA). This collagen is being collected from human cadavers having been tested extensively for potentially transmittable diseases. The manufacturer cooperates with selected tissue banks in North America only to maintain a high level of safety. So far no case of disease transmission or other

substance associated complications had to be observed. After collection the material is transported in an antibiotic solution, in the further cryofractioning process all human cells are completely removed with an avital matrix of dermal collagen and protein remaining. A preparation of these microparticles is marketed as filler for tissue defects under the brand name Cymetra. The substance comes as a powder and needs to be mixed with normal saline and lidocaine in order to get an injectable solution. Allergy testing is not necessary; however, patients with known allergies against antibiotics having been used in the preparation process must not be treated. Cymetra is FDA-approved as dermal filler, but not specifically for use in the human larynx. To date there is only one published report for injection laryngoplasty [19], showing faster resorption than bovine collagen. Comparatively fast resorption, significant higher costs and need to go through a mixing process prior to use will be shortcomings in Cymetra's competition against other substances.

By definition tissue from the same patient is not a medical implant. Since autologous fat is in direct competition with the substances discussed earlier it will be mentioned shortly. Autologous fat has been described as material for vocal fold augmentation in the early 90ies of the last century [20]. Harvesting is performed in the same session as augmentation, usually by aspiration or periumbilical incision. The correct harvesting technique is probably of major influence on the survival rate of adipocytes after transplantation [21]. The obvious advantages as excellent biocompatibility, simple harvesting and minimal costs made this technique popular worldwide soon. Until the end of the millennium autologous fat probably has been the most frequently used substance for injection laryngoplasty. Reports on extent of and time to resorption are varying. Using MRI long time vitality of the injected fat tissue could be shown as well as complete resorption [22], [23]. This lack of reproducibility and the advent of numerous alternative materials lead to a continuing decrease of autologous fat transplantation [24].

2.3 Solid implantats

Systematic development of surgical vocal fold medialisation as well as the term thyroplasty goes back to Isshiki [25]. He described the technique of forming a wedge by cutting a window into the laryngeal framework at the glottic level which was secured into the paraglottic space by a custom-made silastic implant. Due to irreproducible resorption of the impressed cartilage Sasaki's [26] modification became popular, which removed the cartilage within the window completely with the silastic implant doing the complete medialisation effect. Biological compatibility of completely polymerized medical grade silicone is excellent; extrusion rate seems not to be different to other medical implants [27]. Good compatibility in combination with low material costs and possibility of customization have made thyroplasty using silastic implants extremely popular for a long time in the US [28]. On the other hand the time-consuming non-standardized and

hardly reproducible preparation of the implant at the operation table has fueled the development of pre-formed devices. The VoCom system consists of excellent biocompatible hydroxylapatite and comes with 5 implant sizes and 4 baseplates offering a wide range of possible combinations [29]. Due to its tendency to osseointegrate hydroxylapatite is almost impossible to remove after implantation. The Montgomery system [30] is silicone based and comes with 5 different sizes for males and females, respectively. Dedicated tools are necessary for the implantation process, making the system quite expensive. In contrast to that the Titanium Vocal Fold Medialization Implant (TVFMI) can be inserted using standard equipment (Figure 2) and comes in 3 sizes differing in length only [31]. Ease of use and comparatively low cost has made the TVFMI popular all over Europe. Functional results seem to equal regardless of type of implant.

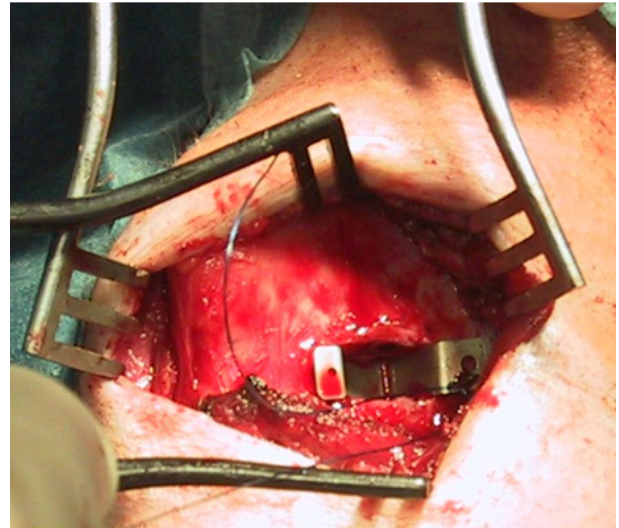


Figure 2: Titanium Vocal Fold Medialization Implant

3 Laryngeal stents

Indications for stents in the human larynx are postoperative stabilization after laryngofissure (as in laryngotracheal reconstruction for repair of laryngotracheal stenosis), stenting of a traumatized larynx to prevent formation of synechia and stenosis as well as preservation or reconstruction of a sharp-angled anterior commissure after oncological resection in this area. Long-term stenting for progressive dilatation of laryngotracheal stenosis is considered obsolete nowadays and will not be discussed. The Montgomery T-Tube has been introduced as early as 1965 [32] and has remained the laryngeal stent most widely used (Figure 3). It is a T-shaped uncuffed silicone tube with two long legs to be put into the trachea and the subglottic larynx while the short leg is positioned in the tracheostomy site (Figure 4). This tracheostomal leg is to be unplugged only for cleaning and in emergency. Prolonged breathing through this outer part of the T-tube inevitably leads to formation of crusts blocking the airway within relatively short time. For adults there are sizes

ranging from outer diameter of 4.5 to 16 mm with different length. There are paediatric variations (with the outer leg angled differently) coming with outer diameters ranging from 4.5 to 8 mm and a great variety of different lengths.




Figure 3: Montgomery T-Tube

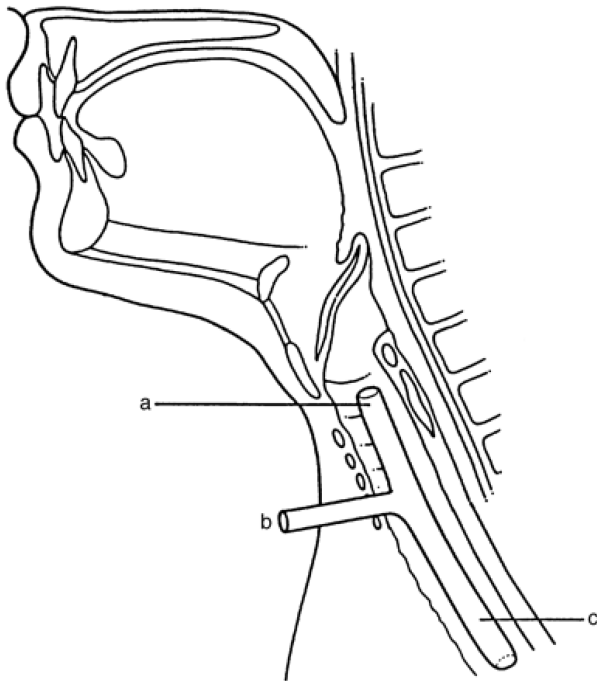


Figure 4: Montgomery T-Tube, schematic drawing of correct positioning

The Montgomery T-tube has replaced almost completely other types of laryngeal stents like those by Albouker or Berkovits [33], which will not be described here. Significant disadvantages of the Montgomery T-tube are the tendency to stimulate granulation tissue at the cranial and caudal end, laceration of the subglottic aspects of the vocal fold if positioned close to the glottic level and aspiration if positioned transglottic. There is also no standard connector to respirators [34]. Primarily in the narrow paediatric types crust formation may lead to dramatic situations rapidly. A modification by Schultz-Coulon named "double-cannula-technique" [35] helps effectively to avoid this: The external leg of the T-tube is being split in a sagittal plane allowing for the introduction of a

standard tracheal cannula without discomfort for the patient. The cranial end is no longer required as an airway and can be sutured to prevent aspiration.

After laryngotracheal reconstruction a Montgomery T-tube is typically left in place for about 3 weeks, but in case of multiple laryngofissure requiring long term stenting this can be much longer [36]. There is broad agreement among all relevant authors that long term use of a Montgomery T-tube should be a rare exception for cases in which reconstruction of the compromised airway is not feasible.

Although the Montgomery T-tube has been used successfully for decades the problems mentioned should not be underestimated. With the LT-mold a promising new device is on the way (but not yet commercially available) apparently avoiding some of the complications experienced with the T-tube in the paediatric population [37].

Laser resections in the anterior commissure may lead to formation of synechia, which also may occur after repeated removal of benign lesions (i.e. papilloma) or partial laryngectomy via open approach. Classically surgical treatment consists of open laryngofissure, synechia division and keel implantation for about 3 weeks [38]. Implantation and ex-plantation requiring an open approach and usually tracheostomy is time-consuming and uncomfortable for the patient. Transoral endoscopic synechia division (usually with the CO₂-laser) and stent application to avoid resynechia has become increasingly popular for these conditions after the introduction of the endoextralaryngeal needle driver [39]. These endoscopic stents can be made of silicone or PDS foils or silastic blocks and need to be custom made at the operating table.

The Montgomery larynx stent is formed after molds of the endolarynx and is made of radio-opaque silicone [38]. It comes in 4 different sizes and maybe used for postoperative or posttraumatic stenting and for fixation of mucosa transplants. This stent is secured with translaryngeal sutures, which can be problematic. The use of this stent nowadays is primarily in extended laryngeal trauma with significant mucosa laceration in order to provide simultaneously stabilization of the laryngeal framework as well as prophylaxis against synechia formation [40].

References

1. Arnold GE. Vocal rehabilitation of paralytic dysphonia. Arch Otolaryngol. 1962;76:358-68.
2. Ellis JC, McCaffrey TV, DeSanto LW, Reiman HV. Migration of Teflon after vocal cord injection. Otolaryngol Head Neck Surg. 1987;96(1):63-6.
3. Rubin HJ. Misadventures with injectable polytetrafluoroethylene (Teflon). Arch Otolaryngol. 1975;101(2):114-6.
4. Taylor SR, Gibbons DF. Effect of surface texture on the soft tissue response to polymer implants. J Biomed Mater Res. 1983;17(2):205-27. DOI: 10.1002/jbm.820170202
5. Beisang AA III, Ersek RA. Mammalian response to subdermal implantation of textured microimplants. Aesthetic Plast Surg. 1992;16:83-90. DOI: 10.1007/BF00455154

6. Allen O. Response to subdermal implantation of textured microimplants in humans. *Aesthetic Plast Surg.* 1992;16(3):227-30. DOI: 10.1007/BF00190068
7. Sittel C, Thumfart WF, Pototschnig C, Wittekindt C, Eckel HE. Textured polydimethylsiloxane elastomers in the human larynx: Safety and efficiency of use. *J Biomed Mater Res.* 2000;53(6):646-50. DOI: 10.1002/1097-4636(2000)53:6<646::AID-JBM5>3.0.CO;2-0
8. Sittel C. Polydimethylsiloxane particles are not experimental in the human larynx. *J Biomed Mater Res.* 2004;69B(2):251. DOI: 10.1002/jbm.b.30025
9. Alves CB, Loughran S, MacGregor FB, Dey JI, Bowie LJ. Bioplastique medialization therapy improves the quality of life in terminally ill patients with vocal cord palsy. *Clin Otolaryngol.* 2002;27(5):387-91. DOI: 10.1046/j.1365-2273.2002.00601.x
10. Turner F, Duflo S, Michel J, Giovanni A. Medialisation endoscopique de la corde vocale par injection de Vox-implant: notre experience. *Rev Laryngol Otol Rhinol (Bord).* 2006;127(5):339-43.
11. Hamilton DW, Sachidananda R, Carding PN, Wilson JA. Bioplastique injection laryngoplasty: voice performance outcome. *J Laryngol Otol.* 2007;121(5):472-5. DOI: 10.1017/S0022215106005275
12. Sittel C, Echternach M, Federspil PA, Plinkert PK. Polydimethylsiloxane particles for permanent injection laryngoplasty. *Ann Otol Rhinol Laryngol.* 2006;115(2):103-9.
13. Ford CN, Bless DM. A preliminary study of injectable collagen in human vocal fold augmentation. *Otolaryngol Head Neck Surg.* 1986;94(1):104-12.
14. Remacle M, Marbaix E, Hamoir M, Bertrand B, van den Eeckhaut J. Correction of glottic insufficiency by collagen injection. *Ann Otol Rhinol Laryngol.* 1990;99(6 Pt 1):438-44.
15. Segura T, Anderson BC, Chung PH, Webber RE, Shull KR, Shea LD. Crosslinked hyaluronic acid hydrogels: a strategy to functionalize and pattern. *Biomaterials.* 2005;26(4):359-71. DOI: 10.1016/j.biomaterials.2004.02.067
16. Chan RW, Titze IR. Hyaluronic acid (with fibronectin) as a bioimplant for the vocal fold mucosa. *Laryngoscope.* 1999;109(7):1142-9. DOI: 10.1097/00005537-199907000-00026
17. Hallen L, Johansson C, Laurent C. Cross-linked hyaluronan (Hylan B gel): a new injectable remedy for treatment of vocal fold insufficiency – an animal study. *Acta Otolaryngol.* 1999;119(1):107-11.
18. Hallen L, Dahlqvist A, Laurent C. Dextranomers in hyaluronan (DiHA): a promising substance in treating vocal cord insufficiency. *Laryngoscope.* 1998;108(3):393-7. DOI: 10.1097/00005537-199803000-00015
19. Karpenko AN, Dworkin JP, Meleca RJ, Stachler RJ. Cymetra injection for unilateral vocal fold paralysis. *Ann Otol Rhinol Laryngol.* 2003;112(11):927-34.
20. Brandenburg JH, Kirkham W, Koschke D. Vocal cord augmentation with autogenous fat. *Laryngoscope.* 1992;102(5):495-500. DOI: 10.1288/00005537-199205000-00005
21. Shaw GY, Szewczyk MA, Searle J, Woodroof J. Autologous fat injection into the vocal folds: technical considerations and long-term follow-up. *Laryngoscope.* 1997;107(2):177-86. DOI: 10.1097/00005537-199702000-00008
22. Bauer CA, Valentino J, Hoffman HT. Long-term result of vocal cord augmentation with autogenous fat. *Ann Otol Rhinol Laryngol.* 1995;104(11):871-4.
23. Brandenburg JH, Unger JM, Koschke D. Vocal cord injection with autogenous fat: a long-term magnetic resonance imaging evaluation. *Laryngoscope.* 1996;106(2):174-80. DOI: 10.1097/00005537-199602000-00013
24. McCulloch TM, Andrews BT, Hoffman HT, Graham SM, Karnell MP, Minnick C. Long-Term Follow-up of Fat Injection Laryngoplasty for Unilateral Vocal Cord Paralysis. *Laryngoscope.* 2002;112(7):1235-8. DOI: 10.1097/00005537-200207000-00017
25. Isshiki N, Morita H, Okamura H, Hiramoto M. Thyroplasty as a new phonosurgical technique. *Acta Otolaryngol.* 1974;78(5-6):451-7.
26. Sasaki CT, Driscoll BP, Gracco C, Eisen R. The fate of medialized cartilage in thyroplasty type I. *Arch Otolaryngol Head Neck Surg.* 1994;120(12):1398-9.
27. Halum SL, Postma GN, Koufman JA. Endoscopic management of extruding medialization laryngoplasty implants. *Laryngoscope.* 2005;115(6):1051-4. DOI: 10.1097/01.MLG.0000163342.10412.EB
28. Koufman JA, Isaacson G. Laryngoplastic phonosurgery. *Otolaryngol Clin North Am.* 1991;24(5):1151-77.
29. Cummings CW, Purcell LL, Flint PW. Hydroxylapatite laryngeal implants for medialization. Preliminary report. *Ann Otol Rhinol Laryngol.* 1993;102(11):843-51.
30. Montgomery WW, Montgomery SK. Montgomery thyroplasty implant system. *Ann Otol Rhinol Laryngol Suppl.* 1997;170:1-16.
31. Friedrich G. Titanium vocal fold medializing implant: introducing a novel implant system for external vocal fold medialization. *Ann Otol Rhinol Laryngol.* 1999;108(1):79-86.
32. Montgomery WW. T-Tube tracheal stent. *Arch Otolaryngol.* 1965;82:320-1.
33. Preciado D, Zalzal G. Laryngeal and tracheal stents in children. *Curr Opin Otolaryngol Head Neck Surg.* 2008;16(1):83-5. DOI: 10.1097/M00.0b013e3282f433f4
34. Guha A, Mostafa SM, Kendall JB. The Montgomery T-tube: anaesthetic problems and solutions. *Br J Anaesth.* 2001;87(5):787-90. DOI: 10.1093/bja/87.5.787
35. Schultz-Coulon HJ. Platzhaltertechnik nach laryngotrachealer Rekonstruktion [Long Term Stenting after Laryngotracheal Reconstruction]. *Laryngorhinootologie.* 2008;87(7):464-6. DOI: 10.1055/s-2008-1081062
36. Varvares MA, Montgomery WW. Repair of chronic subglottic stenosis with autogenous thyroid cartilage. *Ann Otol Rhinol Laryngol.* 2004;113(3 Pt 1):212-7.
37. Monnier P. Airway stenting with the LT-Mold: experience in 30 pediatric cases. *Int J Pediatr Otorhinolaryngol.* 2007;71(9):1351-9. DOI: 10.1016/j.ijporl.2007.05.027
38. Montgomery WW, Montgomery SK. Manual for use of Montgomery laryngeal, tracheal, and esophageal prostheses. *Ann Otol Rhinol Laryngol Suppl.* 1986;125:1-16.
39. Lichtenberger G, Toohill RJ. New keel fixing technique for endoscopic repair of anterior commissure webs. *Laryngoscope.* 1994;104(6):771-4. DOI: 10.1288/00005537-199406000-00023
40. Bell RB, Verschuereen DS, Dierks EJ. Management of laryngeal trauma. *Oral Maxillofac Surg Clin North Am.* 2008;20(3):415-30. DOI: 10.1016/j.coms.2008.03.004

Corresponding author:

Christian Sittel
Klinik für Hals-, Nasen-, Ohrenkrankheiten, Plastische
Operationen, Klinikum Stuttgart – Katharinenhospital,
Kriegsbergstr. 60, 70174 Stuttgart, Germany, Tel.:
+49(0)711 2783200
c.sittel@klinikum-stuttgart.de

Please cite as

Sittel C. Larynx: implants and stents. *GMS Curr Top Otorhinolaryngol
Head Neck Surg.* 2009;8:Doc04.
DOI: 10.3205/cto000056, URN: urn:nbn:de:0183-cto0000561

This article is freely available from

<http://www.egms.de/en/journals/cto/2011-8/cto000056.shtml>

Published: 2011-03-10

Copyright

©2011 Sittel. This is an Open Access article distributed under the terms
of the Creative Commons Attribution License
(<http://creativecommons.org/licenses/by-nc-nd/3.0/deed.en>). You
are free: to Share – to copy, distribute and transmit the work, provided
the original author and source are credited.