

# Arthroscopic lysis and lavage for internal derangement of the temporomandibular joint

Access this article online

Website:  
www.amsjournal.com

DOI:  
10.4103/2231-0746.175754

Quick Response Code:



Waseem A. Abboud, Navot Givol, Ran Yahalom

Department of Oral and Maxillofacial Surgery, Sheba Medical Center, Tel-Hashomer, Affiliated to Sackler School of Medicine, Tel-Aviv University, Israel

Address for correspondence:

Dr. Waseem A. Abboud, P. O. Box: 111, Shfar-Am 20200, Israel.  
E-mail: waseem.abboud@gmail.com

## ABSTRACT

**Introduction:** Arthroscopy of the temporomandibular joint (TMJ) is a valuable diagnostic and therapeutic tool for various intra-articular disorders, especially internal derangement (ID) of the TMJ. **Objectives:** To evaluate the efficacy and safety of a standardized arthroscopic procedure for the treatment of two stages of ID; early/intermediate stage and intermediate/late stage. **Materials and Methods:** Retrospective analysis of medical records of 78 patients (99 joints) treated by arthroscopic lysis and lavage in the authors' department during a 5-year period. Patients were diagnosed preoperatively as suffering from ID of the TMJ. The results were stratified according to the stage of ID. Three outcome variables were used to assess efficacy of treatment: Maximal interincisal opening (MIO), level of pain on a visual analog scale (VAS), and frequency of intermittent locking episodes. In addition, complications were reported. **Results:** Mean MIO of the group of patients with intermediate/late stage ID increased from  $27 \pm 4.7$  mm preoperatively to  $38 \pm 5.4$  mm postoperatively ( $P < 0.0001$ ). For the group of patients with early/intermediate stage ID, mean MIO did not change significantly after arthroscopy ( $39.1 \pm 6.2$  mm compared to  $41.4 \pm 5$  mm,  $P = 0.06$ ), however, subjective evaluation of pain on a VAS decreased from  $7.2 \pm 1.2$  preoperatively to  $3.4 \pm 2.2$  postoperatively ( $P < 0.0001$ ), and 80% of the patients (25 of 31) denied experiencing intermittent locking episodes after treatment ( $P < 0.0001$ ). **Conclusion:** Arthroscopic lysis and lavage is a safe and effective therapeutic modality for the treatment of both mild and advanced stages of ID.

**Keywords:** Arthroscopic lysis and lavage, arthroscopy, internal derangement, temporomandibular joint

## INTRODUCTION

Internal derangement (ID) of the temporomandibular joint (TMJ) is defined as a malpositioning of the articular disc from its normal position relative to the condyle and eminence. It signifies an interference with smooth joint movement.<sup>[1]</sup> The disorder may vary in the severity from mild condition with no or minimal symptoms to severe disorder with substantial degree of pain and dysfunction. Wilkes classified ID into five stages.<sup>[2]</sup> Patients with early stage ID (stage 1) complain of clicking sounds upon jaw opening and closing. There is no pain or dysfunction at this stage, and individuals who seek medical treatment are usually advised to avoid chewing hard and chewy foods, limit mouth opening during yawning and eating, and if the clicks are severe then occlusal splint may be recommended. Early/intermediate stage

of ID (stage 2) manifests with clicking of the joint, intermittent locking episodes, and transient pain. Patients at this stage are treated with the conservative methods mentioned above, with the addition of anti-inflammatory medications with or without muscle relaxants. If a 3–4 months trial fails to demonstrate

This is an open access article distributed under the terms of the Creative Commons Attribution-NonCommercial-ShareAlike 3.0 License, which allows others to remix, tweak, and build upon the work non-commercially, as long as the author is credited and the new creations are licensed under the identical terms.

For reprints contact: reprints@medknow.com

Cite this article as: Abboud WA, Givol N, Yahalom R. Arthroscopic lysis and lavage for internal derangement of the temporomandibular joint. Ann Maxillofac Surg 2015;5:158-62.

a trend toward improvement in signs and symptoms, then arthroscopy of the TMJ is recommended. Intermediate stage ID (stage 3), also known as acute closed lock, manifests with limited mouth opening, deviation of jaw upon opening to the affected side, and pain in the involved joint. The disorder usually has an acute onset of symptoms. The initial treatment offered in our department for these patients is usually arthrocentesis under local anesthesia, and only cases who fail to respond to arthrocentesis are advanced to arthroscopy. Intermediate/late stages of ID (stage 4) are characterized by limited mouth opening and various degrees of pain. Chronic closed lock is the term commonly used to describe this stage. In our department, the recommended treatment for cases recalcitrant to conservative therapies is arthroscopic lysis and lavage. Late stage ID (stage 5) signifies the development of advanced degenerative changes in the joint, and clinically manifests with crepitus and grinding sounds, episodic or continuous pain, and difficulty with function. Symptomatic patients at this stage are usually treated with open joint surgery.

Arthroscopy of the TMJ was first described by Ohnishi in 1975.<sup>[3,4]</sup> In 1986, Sanders<sup>[5]</sup> described arthroscopic lysis and lavage as a standardized procedure for the treatment of chronic closed lock of the TMJ. Three decades later, however, this minimally invasive surgical option is still not readily available in most departments of oral and maxillofacial surgery, primarily due to the surgical expertise required and the need for sophisticated armamentarium. The effect of arthroscopic lysis and lavage lies primarily in the irrigation of the joint cavity, washout of inflammatory cytokines, mobilization of the articular disc, stretching of the capsule, and lysis of intra-articular adhesions.<sup>[6,7]</sup>

The question of how efficient arthroscopy in the treatment of ID of the TMJ has not been answered definitively. Review of the literature reveals that many studies evaluated various arthroscopic procedures ranging from simple lysis and lavage to advanced operative arthroscopies without differentiation between the different treatments. Many studies did not report clear diagnoses for the study population or did not differentiate between the different diagnoses and stages when reporting the results.<sup>[8-13]</sup> The objective of this study was to evaluate the efficacy of a standardized arthroscopic procedure (arthroscopic lysis and lavage) in the treatment of 2 specific stages of ID; early/intermediate ID (stage 2, intermittent locking) and intermediate/late ID (stage 4, chronic closed lock).

## MATERIALS AND METHODS

This is a retrospective analysis of data from medical records. During a 5-year period, 125 patients with various TMJ diagnoses underwent arthroscopic lysis and lavage in the authors' department. Of these, 31 were classified as having early/intermediate ID (stage 2) and 47 patients were classified as having intermediate/late ID (stage 4), and the 78 patients comprised the study cohort. Patients with stage 3 ID were not included in the study because they received arthrocentesis before arthroscopy. Previous surgical intervention before arthroscopy was considered an exclusion criterion. In our department, there are no patients with stages I or V treated with arthroscopy.

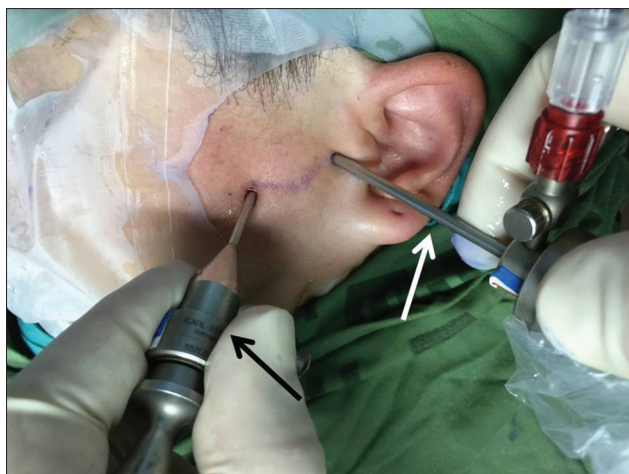
The diagnosis of the various stages of ID was based on preoperative clinical and imaging evaluation and intraoperatively by arthroscopic findings. The preoperative clinical findings of the patients with early/intermediate ID (stage 2) were mainly clicking and beginning transient locking or catching episodes accompanied by pain. These locking episodes lasted seconds to minutes to hours and were released spontaneously or by jaw manipulation by the patient. These patients did not have a constant limitation in mouth opening or function, and their main complaint was a decrease in quality of life owing to the intermittent locking of the jaw and transient pain. The preoperative clinical findings of patients with intermediate/late ID (stage 4) were mainly limited mouth opening with or without mandibular deviation to the affected side upon opening, and the affected joint was tender in at least two of the following objective examinations: Palpation, contralateral movement, contralateral loading of the joint, or actively stretched opening.

Preoperative imaging consisted of computerized tomographic (CT) scans or magnetic resonance imaging (MRI). All images were evaluated by a radiologist who specialized in head and neck radiology. The MR scans of patients with early/intermediate ID (stage 2) depicted a reducing disc displacement, and in some cases, mild disc deformity was observed. There were no signs of degeneration (narrowing of joint cavity, flattening of articular surfaces, subchondral sclerosis, osteophytes, etc.) on MRI or CT scans. The MR scans of patients with intermediate/late ID (stage 4) depicted a nonreducing disc displacement, and various degrees of disc deformity were evident. There were mild to moderate degrees of degenerative changes on CT and MRI.

Before advancing to arthroscopy, all patients underwent conservative nonsurgical therapy consisting of either physiotherapy, splint therapy, or both and were nonresponsive to it.

One author (W.A.) was involved in all surgical procedures. All arthroscopic procedures were performed under general anesthesia with nasoendotracheal intubation. One gram of intravenous Cefazolin was given shortly after intubation. Procedures were performed by single- or double puncture technique. The superior joint compartment was approached through the inferolateral approach as described by Murakami and Ono.<sup>[4]</sup> Puncture of the joint cavity was performed as described by McCain *et al.*<sup>[3]</sup> A 30° angle arthroscope (Storz, Tuttlingen, Germany) with a diameter of 1.9 mm or 2.4 mm was used in all cases. After puncture of the joint cavity, a diagnostic sweep of the superior compartment was performed as described by Sanders.<sup>[5]</sup> Fluid (saline) outflow was through an 18-gauge needle inserted shortly after the insertion of the arthroscope. Double puncture cases included the insertion of a second cannula [Figure 1]. Irrigation with an average of 200 mL of isotonic saline solution was performed under 40–60-kPa pressure. Adhesions were lysed by a blunt trocar, and in some instances, using tissue forceps and graspers.

Postoperative mobilization of the jaw lasted for a minimum of 4 weeks and consisted of self-stretching exercises and guided physiotherapy by a professional physiotherapist.



**Figure 1:** Intraoperative view of arthroscopic lysis and lavage. White arrow: Arthroscope inserted into the posterior recess of the superior joint compartment. Black arrow: Working cannula inserted into the anterior recess of the superior joint compartment

The medical records of the patients contained a measurement of maximal interincisal opening (MIO) at every visit to the clinic, before and after arthroscopy. The average and range of MMO of the study population were calculated. A comparison of the pre- and post-operative MMO values was performed to evaluate the efficacy of treatment. The MMO measurement at the last follow-up evaluation available for each patient was considered to be the postoperative value. The medical records of the group of patients with early/intermediate ID had in addition to MMO, two additional evaluations; a subjective evaluation of pain and discomfort by a visual analog scale (VAS) ranging from 0–10, and a verbal evaluation of the frequency and severity of the locking or catching episodes. These patients were asked verbal questions regarding the frequency and severity of the locks. Patients rated the frequency of their locking episodes preoperatively as occurring on a daily, weekly, or monthly basis and rated the severity of the locking episodes as lasting for seconds, minutes, hours, or days. At every follow-up evaluation, patients were asked whether they experienced any locking episodes since treatment and, if so, whether the frequency and severity of the locks were less than, similar to, or worse than preoperatively.

#### Statistical analysis

All statistical analyses were performed using StatsDirect 2.8.0 (StatsDirect Ltd., Altrincham, UK). Data are presented as mean  $\pm$  standard deviation. Comparison of continuous parameters was performed by *t*-test or by paired *t*-test for comparisons of before and after arthroscopic intervention. Comparison of proportions was performed by Fisher exact test. In all analyses, a  $P < 0.05$  was considered significant.

The study was approved by the institutional ethical review board. The study conformed to guidelines of the Declaration of Helsinki.

## RESULTS

Seventy-eight patients were included in the study. The mean age of the study population was 29 years (range, 14–66). Sixty patients (77%) were female and 18 (23%) were male. Of

the 31 patients who comprised the early/intermediate group, 12 (38%) had bilateral involvement, and of the 47 patients who comprised the intermediate/late group, 9 (19%) had bilateral involvement, making the total number of joints treated to be 99 joints [Table 1]. The mean follow-up after arthroscopy was 10 months, with the shortest follow-up being 2 months. There were no drop-outs. There was no significant difference between the 2 groups regarding gender, age, and follow-up period.

The mean preoperative maximal interincisal opening (MIO) of the early/intermediate group (stage 2) was  $39.1 \pm 6.2$  mm. The mean preoperative MIO of the intermediate/late group (stage 4) was  $27 \pm 4.7$  mm. A comparison of the preoperative and postoperative values was performed for this outcome variable. The mean MIO of the early/intermediate group (stage 2) did not change significantly after arthroscopy, increasing from  $39.1 \pm 6.2$  mm to  $41.4 \pm 5$  mm, and the difference was not significant statistically ( $P = 0.06$ ). Twenty-one of the 31 patients had an MIO of at least 36 mm preoperatively, and almost all (29 of 31) had an MIO of at least 36 mm postoperatively. The mean MIO of the intermediate/late group (stage 4) increased from  $27 \pm 4.7$  mm preoperatively to  $38 \pm 5.4$  mm postoperatively, and this increase was statistically significant ( $P < 0.0001$ ). Forty-two out of the 47 patients (89%) comprising this group achieved greater MIO values after arthroscopy [Table 2].

The patients of the early/intermediate group (stage 2) had two additional subjective evaluations; the frequency of locking episodes and an evaluation of pain and discomfort on a VAS [Table 3]. Preoperatively, all the patients of this group suffered from intermittent locking and catching episodes (100%). After treatment, the majority (80%; 25 of 31) denied experiencing any locking episodes. Of the other 6 patients, who did experience locking episodes, 4 patients (13%) reported experiencing locking episodes, but with less frequency or severity than preoperatively and 2 patients (6%) reported no improvement about locking episodes after treatment. The decrease in locking episodes was found to be statistically significant ( $P < 0.0001$ ). None of the patients reported worsening of the locking episodes.

The mean pretreatment VAS score of the 31 patients comprising the early/intermediate stage was  $7.2 \pm 1.2$ . The mean postoperative VAS score was  $3.4 \pm 2.2$ . The decrease was statistically significant ( $P < 0.0001$ ).

#### Complications

None of the patients of the early/intermediate group experienced any complications. Four patients (8%) of the Intermediate/Late group suffered from complications, which were paresis of the frontal branch of the facial nerve in 2 cases, earache and dizziness in 1 patient, and periorbital edema due to fluid extravasage in 1 patient. All complications were, however, temporary and resolved completely within 2 weeks.

## DISCUSSION

This study found arthroscopic lysis and lavage to be effective in increasing mouth opening in patients suffering from intermediate/late stage ID, and in decreasing and even eliminating

**Table 1: Characteristics of the study cohort**

	Number of patients	Ratio of unilateral to bilateral involvement	Mean age and range (years)
Early/intermediate (stage 2)	31	19:12	25 (16-53)
Intermediate/late (stage 4)	47	38:9	32 (14-66)

**Table 2: Preoperative and postoperative maximal interincisal opening**

	Before arthroscopy (mm)	After arthroscopy (mm)	P
Early/intermediate (stage 2)	39.1±6.2	41.4±5	0.06
Intermediate/late (stage 4)	27±4.7	38±5.4	<0.0001

**Table 3: Pain values and intermittent locking episodes for patients with early/intermediate internal derangement (stage 2)**

	Before arthroscopy	After arthroscopy	P
Pain	7.2±1.2	3.4±2.2	<0.0001
Locking episodes (%)	100	20	<0.0001

the intermittent locking episodes and transient pain that characterize patients with early/intermediate stage ID.

MIO as an outcome did not reflect the improvement following arthroscopy in the group of early/intermediate ID. Patients with this stage of ID should be evaluated primarily for elimination of intermittent locking episodes and decrease of transient pain. At this stage, usually there is no constant limitation in mouth opening.<sup>[14]</sup> On the other hand, MIO should be considered the primary outcome variable for patients suffering from intermediate/late ID, as it reliably reflects the change after arthroscopy. There are different types of intracapsular TMJ disorders that are so different in diagnosis and treatment that they should not be lumped together when reporting the treatment results. TMJ surgical outcomes should be reported by the specific category of TMJ disorder.<sup>[15]</sup>

There are few studies in the literature that evaluated the efficacy of arthroscopic lysis and lavage on the different stages of ID separately.<sup>[16-20]</sup> This study evaluated 2 stages of ID, and the outcomes were stratified according to stage. Patients with stage 3 ID were excluded from the study because they were treated with arthrocentesis and only those who did not benefit from it were advanced to arthroscopy. Including this group of patients, in our opinion, will cause the patient sample to be fundamentally flawed.

Using clear diagnoses and staging system lies in the basis of good clinical practice and research. Wilkes classification of ID is one of the most widely used systems. It is simple and thorough. However, the clinician must bear in mind that not all TMJ disorders fit into this classification, and often patients present with joint disorders that have an osteoarthritic process in their pathophysiology, rather than ID. The astute clinician should be

able to differentiate between degenerative and derangement disorders in both the mild and advanced stages.

There are two main strengths of this study: The specific joint pathologies included (e.g., derangement stage 2 and 4 only) and the uniformity of the surgical procedure (e.g., a standardized arthroscopic lysis and lavage performed by one surgeon). Review of the literature shows that many studies lack clear diagnoses of the temporomandibular disorders included or lack differentiation between the different diagnoses and stages when reporting treatment outcomes.<sup>[8-13]</sup> Another issue is the lack of uniformity to the surgical procedure performed. Many studies evaluated various procedures ranging from simple arthroscopic lysis and lavage to the more advanced operative arthroscopy, and the results were not stratified separately according to the efficacy of each surgical intervention.<sup>[8-13]</sup> Moreover, when different surgical techniques were evaluated for the treatment of the same entity, assessment of randomization was lacking.

The absence of complications in the early/intermediate group compared with few complications in the intermediate/late group could be explained by the fact that more advanced stages of ID may often require more instrumentation and capsular stretch to achieve sufficient disk mobilization, which reflects on longer intraoperative time. Still the overall low complication rate demonstrated in this study and in other large-scale studies<sup>[21,22]</sup> make it clear that arthroscopy of the TMJ is a safe and effective treatment modality. The authors recommend that when nonsurgical therapy fails to improve the signs and symptoms of the disorder, arthroscopic lysis and lavage should be used.

#### Financial support and sponsorship

Nil.

#### Conflicts of interest

There are no conflicts of interest.

## REFERENCES

- de Leeuw R. Internal derangements of the temporomandibular joint. *Oral Maxillofac Surg Clin North Am* 2008;20:159-68.
- Wilkes CH. Internal derangements of the temporomandibular joint. Pathological variations. *Arch Otolaryngol Head Neck Surg* 1989;115:469-77.
- McCain JP, de la Rúa H, LeBlanc WG. Puncture technique and portals of entry for diagnostic and operative arthroscopy of the temporomandibular joint. *Arthroscopy* 1991;7:221-32.
- Murakami K, Ono T. Temporomandibular joint arthroscopy by inferolateral approach. *Int J Oral Maxillofac Surg* 1986;15:410-7.
- Sanders B. Arthroscopic surgery of the temporomandibular joint: Treatment of internal derangement with persistent closed lock. *Oral Surg Oral Med Oral Pathol* 1986;62:361-72.
- Nitzan DW. Arthrocentesis – Incentives for using this minimally invasive approach for temporomandibular disorders. *Oral Maxillofac Surg Clin North Am* 2006;18:311-28, vi.
- Nitzan DW, Dolwick MF, Heft MW. Arthroscopic lavage and lysis of the temporomandibular joint: A change in perspective. *J Oral Maxillofac Surg* 1990;48:798-801.
- McCain JP, Sanders B, Koslin MG, Quinn JH, Peters PB, Indresano AT. Temporomandibular joint arthroscopy: A 6-year multicenter retrospective study of 4,831 joints. *J Oral Maxillofac Surg* 1992;50:926-30.
- Murakami K, Segami N, Okamoto M, Yamamura I, Takahashi K, Tsuboi Y. Outcome of arthroscopic surgery for internal derangement

- of the temporomandibular joint: Long-term results covering 10 years. *J Craniomaxillofac Surg* 2000;28:264-71.
10. Mosby EL. Efficacy of temporomandibular joint arthroscopy: A retrospective study. *J Oral Maxillofac Surg* 1993;51:17-21.
  11. Perrott DH, Alborzi A, Kaban LB, Helms CA. A prospective evaluation of the effectiveness of temporomandibular joint arthroscopy. *J Oral Maxillofac Surg* 1990;48:1029-32.
  12. Israel HA, Roser SM. Patient response to temporomandibular joint arthroscopy: Preliminary findings in 24 patients. *J Oral Maxillofac Surg* 1989;47:570-3.
  13. Zhang S, Huang D, Liu X, Yang C, Undt G, Haddad SM, *et al.* Arthroscopic treatment for intra-articular adhesions of the temporomandibular joint. *J Oral Maxillofac Surg* 2011;69:2120-7.
  14. Abboud W, Yahalom R, Givol N. Treatment of intermittent locking of the jaw in Wilkes stage II derangement by arthroscopic lysis and lavage. *J Oral Maxillofac Surg* 2015;73:1466-72.
  15. Tarro AW. Clinical controversies in oral and maxillofacial surgery: Surgical arthroscopy (part 1) or arthroscopic lysis and lavage (part 2) as the preferred treatment for internal derangement of the temporomandibular joint. *J Oral Maxillofac Surg* 2001;59:962-3.
  16. Bronstein S, Merrill R. Clinical staging for TMJ internal derangement: Application to arthroscopy. *J Craniomandib Disord Facial Oral Pain* 1992;6:7-16.
  17. Smolka W, Yanai C, Smolka K, Iizuka T. Efficiency of arthroscopic lysis and lavage for internal derangement of the temporomandibular joint correlated with Wilkes classification. *Oral Surg Oral Med Oral Pathol Oral Radiol Endod* 2008;106:317-23.
  18. Smolka W, Iizuka T. Arthroscopic lysis and lavage in different stages of internal derangement of the temporomandibular joint: Correlation of preoperative staging to arthroscopic findings and treatment outcome. *J Oral Maxillofac Surg* 2005;63:471-8.
  19. González-García R, Rodríguez-Campo FJ. Arthroscopic lysis and lavage versus operative arthroscopy in the outcome of temporomandibular joint internal derangement: A comparative study based on Wilkes stages. *J Oral Maxillofac Surg* 2011;69:2513-24.
  20. Weedon S, Ahmed N, Sidebottom AJ. Prospective assessment of outcomes following disposable arthroscopy of the temporomandibular joint. *Br J Oral Maxillofac Surg* 2013;51:625-9.
  21. Zhang S, Yang C, Cai X, Liu X, Huang D, Xie Q, *et al.* Prevention and treatment for the rare complications of arthroscopic surgery in the temporomandibular joint. *J Oral Maxillofac Surg* 2011;69:E347-53.
  22. González-García R, Rodríguez-Campo FJ, Escorial-Hernández V, Muñoz-Guerra MF, Sastre-Pérez J, Naval-Gías L, *et al.* Complications of temporomandibular joint arthroscopy: A retrospective analytic study of 670 arthroscopic procedures. *J Oral Maxillofac Surg* 2006;64:1587-91.