

Histoplasmosis outbreak in Tamboril cave—Minas Gerais state, Brazil[☆]



Fabiana Rocha-silva^a, Sônia M. Figueiredo^{a,b}, Thamara T.S. Silveira^a, Claudia B. Assunção^a,
 Sabrina S. Campolina^c, João P.P. Pena-barbosa^d, Alexandre Rotondo^b,
 Rachel B. Caligiorne^{a,*}

^a Núcleo de Pós-Graduação e Pesquisa do Hospital, Santa Casa de Belo Horizonte Hospital, Rua Domingos Vieira, 590, Belo Horizonte 30150240, Minas Gerais, Brazil

^b Universidade Federal de Ouro Preto, Ouro Preto, Brazil

^c Centro de Pesquisas René Rachou-FIOCRUZ, Belo Horizonte, Brazil

^d Departamento de Zoologia, Universidade de São Paulo, São Paulo, Brazil

ARTICLE INFO

Article history:

Received 18 September 2013

Received in revised form

19 November 2013

Accepted 4 December 2013

Keywords:

Histoplasma capsulatum

Histoplasmosis

Speleologist

Cavern's fungi

ABSTRACT

In this study, we report four cases of *Histoplasma capsulatum* infection in eight biologists who made an expedition to determine the prevalence of this fungus in a cave localized in the northwest of Minas Gerais state, Brazil. This case report demonstrates the importance of evaluating the *H. capsulatum* presence in Brazilian caves before opening to public visitations.

© 2014 The Authors. International Society for Human and Animal Mycology. Published by Elsevier B.V. All rights reserved.

1. Introduction

Histoplasmosis is a cosmopolitan systemic mycosis caused by the fungus *Histoplasma capsulatum*. This disease has been already reported in USA's Middle West and Northeast; Latin America, Asia, Africa and several cases with no etiological confirmation in Europe [1]. Histoplasmosis is the most prevalent mycosis disseminated in Central America, United States (Ohio and Mississippi) and Mexico's southeast [2]. Although histoplasmosis can affect healthy individuals, the disease has been frequently related to immunocompromised patients [1]. Severe manifestations are common with rapid progression being in many cases lethal. Facing that, a precise and quick diagnosis is needed to ensure efficient treatment [3].

The dimorphic fungus *H. capsulatum* lives as a saprophytic form in soil, especially in alkaline conditions (pH 5 to 10) and temperatures between 20 to 30 degrees. The infection occurs after initial exposure to *H. capsulatum* by inhaling the spores present in the environment. Once inhaled into the alveoli, the organism readily spreads in macrophages throughout the reticuloendothelial system [4,5]. At the same time, the conidia transform into yeast-like

cells, characterizing the dimorphism of this species. Studies in vitro revealed that conidia may transform into yeast-like cells efficiently whether or not they are phagocytosed by macrophages cells, but not when ingested by dendritic cells, suggesting that these cells restrict transformation into the yeast stage [6].

H. capsulatum can survive at extreme conditions and change its microenvironment to achieve pathogenicity [7]. Many foci were observed after accidental exposure to great amount of bird and bat feces on endemic and non-endemic areas [8]. There are some case reports describing infections caused by *H. capsulatum* after tourism trips [9]. In Central America, a histoplasmosis burden in a tourist group that visited caves was reported. It confirms the importance of the fungus identification in caves before opening for tourist visitors and workers [10].

The present work discusses a case of four immunocompetent researchers that developed different clinical aspects of histoplasmosis after bat's guano collected in a private cavern named Tamboril, located in the Minas Gerais state, Brazil. The clinical report varied from pulmonary to systemic commitments that were evidenced by X-ray and clinical investigation.

2. Case

The cave of Tamboril has 2.5 km extension with a diverse calcite formation and habitats such as a lake. It is located at 150 km from Brasilia, Brazil capital. Its fauna is composed mostly

[☆]This is an open-access article distributed under the terms of the Creative Commons Attribution-NonCommercial-No Derivative Works License, which permits non-commercial use, distribution, and reproduction in any medium, provided the original author and source are credited.

* Corresponding author. Tel./fax: +55 31 32388838.

E-mail address: rachelbc@santacasabh.org.br (R.B. Caligiorne).

by different populations of bats and insects that live on bat guano. This cave was open to visitation until the land was bought by a calcium miner enterprise.

After several years closed and in order to reopen the cave to visitors, the enterprise employed a group of eight biologists and cavers investigate *H. capsulatum* occurrence as well as other fungal species. Facing that, bat's guanoses were collected at different cave locations.

The researchers used whole attire and adopted measures appropriated for this study. However, due to the intense heat and long collection periods (almost 11 h) inside the cave, the researchers took off their masks several times, enabling a possible inhalation of fungal spores. Subsequently, in the 10th day after the guano exposure, four of the eight researches presented with histoplasmosis symptoms.

The researchers, with ages varying from 20 to 35 years old, were assisted by infectiologists of Federal University of Minas Gerais's medicine Clinical Hospital, Belo Horizonte, Brazil. Four of the eight researchers who had entered the cave presented with clinical symptoms including lethargy and night fever of body temperature ranging from 37.5 to 38.5 °C. No cervical or generalized lymphadenomegaly as well as other clinical manifestations were observed at this stage. Complete blood counting (CBC) was performed on the day 12 showing normal hemoglobin, leucocytes levels and erythrocyte sedimentation rate. On the other hand, C-reactive protein dosage was higher considering reference levels in three of the four researches (Table 1).

The serological tests using the anti-*H. capsulatum* antibody were done on day 15, for the four patients, and were all negative. Chest radiography demonstrated nodular diffuse shadowing and calcifications as described in pulmonary infections such as histoplasmosis (Fig. 1).

The mycological tests were made by sputum analysis and culture for the four patients. Fresh sputum was examined under the microscope after 10% potassium hydroxide (KOH) treatment, followed by Lactophenol cotton blue staining. It was observed numerous small (7 µm) and oval yeasts, characteristic of the specie *H. capsulatum* (Fig. 2A). For fungi isolation, the sputum was disseminated on Agar-Sabouraud plaques containing Chloramphenicol 0.05%. After two weeks, beige creamy colonies (yeast form) as well as light beige, cotton colonies (filamentous) presenting *H. capsulatum* macromorphological characteristics, were observed. Microscopic analyses were made after staining colonies fragments with Lactophenol cotton blue dye and showed numerous characteristics of *H. capsulatum* including alkaline septate hyphae, brown macroconidia with thick and cog wall, 1-celled, spherical, 8–14 µm diam., (Fig. 2B).

Two of the four researchers numbered as 1 and 3 developed severe symptoms as arthritis and arthralgia in the knees and

elbows; swollen hands and legs; permanent fatigue and respiratory symptoms prolongation. Therefore, antifungal treatment was initiated on day 20, with oral itraconazole 400 mg per day for 14 days. After one week of treatment (day 27) these symptoms disappeared. The cure after this therapy strongly suggests a fungal infection as a diagnostic treatment proof. The other two researchers (2 and 4) showed spontaneous cure without antifungal therapy with no disease symptoms on the day 27.

3. Discussion

Histoplasmosis is endemic on tropical and temperate zones over the world, which have temperatures between 20 and 30 degrees and high humidity. This disease is endemic in Mississippi, Ohio, Caribbean, south of Mexico, South America, Africa, Asia, and in some areas of Central Europe. On these regions, *H. capsulatum* is frequently found in soil contaminated with birds and bats feces [8,11–13]. In an undesirable manner, our results demonstrated that the *H. capsulatum* was present on the explored environment. The way that the infection occurred made clear that pathogen identification is crucial to understand and diagnose the fungus infection. The specific and rapid diagnosis is important mostly because the clinical symptoms can be confused with other pathologies such as pneumonia and tuberculosis [11].

Although the researches dressed individual protective equipment during guano collection, the infections strongly suggest that the cave was infested of *H. capsulatum* spores. It also demonstrates that disease progression is related to individual immune system competence. Facing that, expeditions into bat-colonized caves can result in different infections frame according to the host immune system and previous pathogen contact.

The four patients who developed symptoms had never visited the cavern whereas the other four researches that had no symptoms visited the cavern previously. This fact suggests that these individuals might be resistant to the infection as they probably had previous contact or even subclinical infection. When the disease is readily diagnosed the treatment reduces the infections symptoms within 3 days [14].

Histoplasmosis can progressively disseminate and is diagnosed by chest radiograph, histology and microbiology and if it is not treated, it can be fatal [1,15,16]. Facing that, the health programs should develop to investigate fungus incidence, mostly on tropical areas as observed in Brazil [2,17]. Understating the possible fungus reservoir and the description of its endemic area, we can prevent disease transmission avoiding the infection [18].

Another way to control fungi infestations is to clean the environment with fumigation with Formaldehyde 3.8% and take off the guano. However, this practice has a high risk to environment once

Table 1
General characteristics of the researchers.

Researcher	Age years	Gender	Type of infection	Night fever	WBC [$10^3/\mu\text{L}$]	Serology	Protein C -reactive	X-ray Fig. 1	Treatment
1	25	Female	Acute	Yes	5.40	Negative	9.8 mg/L	1 A and B	Yes
2	20	Male	Acute	Yes	7.56	Negative	6.2 mg/L	1 C and D	No
3	33	Male	Acute	Yes ^a	5.93	Negative	61.1 mg/L	1 E and F	Yes
4	29	Female	Acute	Yes	8.96	Negative	48.5 mg/L	1 G and H	No
5	35	Male	Asymptomatic	No	nd	nd	nd	nd	No
6	23	Male	Asymptomatic	No	nd	nd	nd	nd	No
7	24	Male	Asymptomatic	No	nd	nd	nd	nd	No
8	26	Male	Asymptomatic	No	nd	nd	nd	nd	No

nd: Not determined.

Treatment Posology—Itraconazole, 400 mg daily for 14 days.

Serology available in Brazilian laboratories is the double radial immunodiffusion.

WBC—White Blood Cell count in microliter of blood in the day 12.

^a The research 3 presented fever daytime, with worsening between the 15th and 20th day.

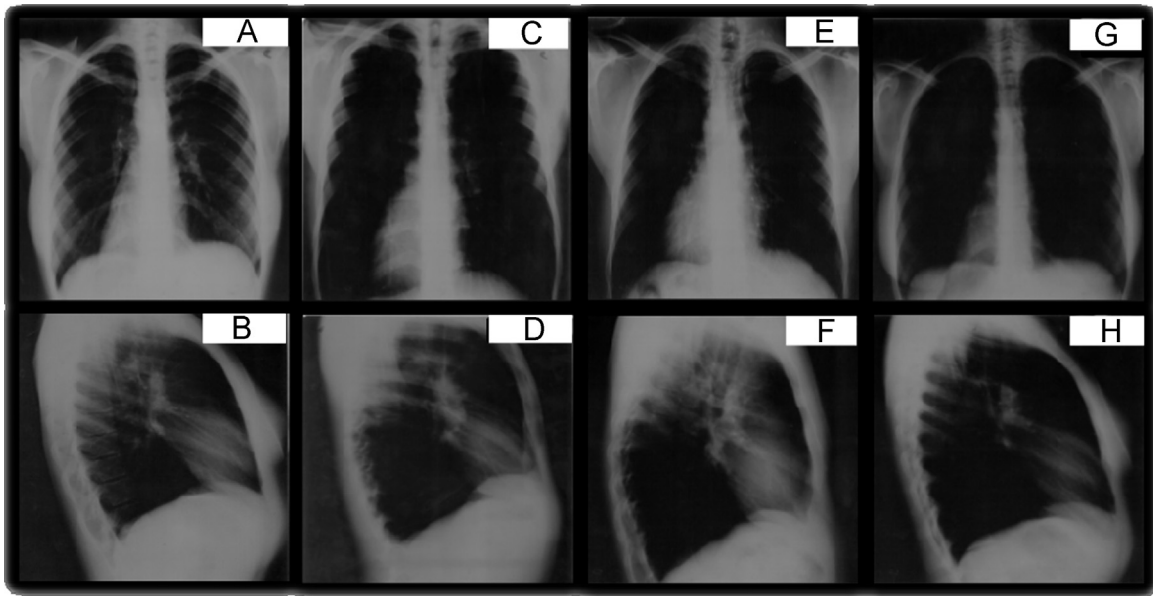


Fig. 1. Researchers chest X-ray showing calcifications and nodular shadowing suggesting initial pulmonary infection of each research infected. A,B-Research 1; C,D-Research 2; E,F-Research 3; G,H-Research 4.

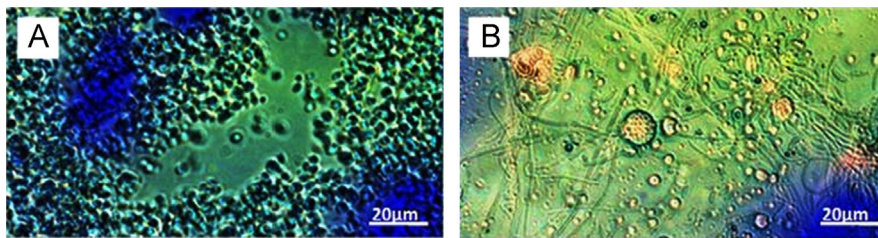


Fig. 2. Researchers sputum fresh exams with potassium hydroxide and stained by Lactofenol presenting small, oval, thick walled (A). Sputum culture microscopy showing septate hyphae, which cog thick walls (B). Microscopy 1000 × .

this chemical agent kills others form of life. Moreover, guano is a niche for many arthropod species and taking it off could deregulate the cave ecosystem. So, cave-visiting prohibition is the only way to prevent fungi infections [3]. Furthermore, more researches are needed to monitor, prevent and manage emerging fungal infections.

According to the data presented on this article, we recommend some procedures: (a) more control in cave access due to possible *H. capsulatum* and other fungal infections; (b) banning public entrance for visitation or research in caves containing *H. capsulatum*; (c) if it is extremely necessary to enter on contaminated cave, people should wear personal protective equipment all the time inside the cave; (d) promote on endemic areas campaign about cave visiting on television, radio and schools lectures; (e) stimulate the histoplasmosis cases notification to Health systems and competent government organs.

Conflict of interest statement

The authors have no conflict of interest to declare.

Acknowledgements

This work was supported by the National Council for Research and Development – CNPq and Research Foundation of the State of Minas Gerais – FAPEMIG.

References

- [1] Ardizzoni A, Baschieri MC, Manca L, Orsi CF, Venturelli C, Meacci M, Peppoloni S, Farina C, Blasi E. The protein “mycoarray” a novel serological assay for the laboratory diagnosis of primitive endemic mycoses. *New Microbiol* 2011;34:307–16.
- [2] Sifuentes-Osornio J, Corzo-León DE, Ponce-de-León LA. Epidemiology of invasive fungal infections in Latin America. *Curr Fungal Infect Rep* 2012;6:23–34.
- [3] Wank B, Lazera M. Histoplasmosis clássica e africana. In: Sidrim JJC, Rocha MFG, editors. *Micologia médica à luz de autores contemporâneos*. Rio de Janeiro: Guanabara Koogan; 2004. p. 222–36.
- [4] López CE. Dimorphism and pathogenesis of *Histoplasma capsulatum*. *Rev Argent Microbiol* 2006;38(4):235–42.
- [5] Kauffman CA. Histoplasmosis. *Clin Chest Med* 2009;30:217–25.
- [6] Newman SL, Lemen W, Smulian AG. Dendritic cells restrict the transformation of *Histoplasma capsulatum* conidia into yeasts. *Med Mycol* 2011;49(4):356–64.
- [7] Woods JP. *Histoplasma capsulatum* molecular genetics, pathogenesis, and responsiveness to its environment. *Fungal Genet Biol* 2002;35(2):81–97.
- [8] Ferreira MS, Borges AS. Histoplasmosis. *Rev Soc Bras Med Trop* 2009;42(2):192–8.
- [9] Kotton CN. Travel and transplantation: travel-related diseases in transplant recipients. *Curr Opin Organ Transplant* 2012;17(6):594–600.
- [10] Nygard K, Brantsaeter A, Feruglio S, Rayn J, Dotevall L, Hasle G, Myrvang B. Histoplasmosis among travelers to Central America. *Tidsskr Nor Laegeforen* 2006;126(21):2838–42.
- [11] La Hoz RM, Loyd JE, Wheat J L, Baddley JW. How I treat histoplasmosis. *Curr Fungal Infect Rep* 2013;7:36–43.
- [12] Brilhante RSN, Fechine MAB, Mesquita JRL, Cordeiro RA, Rocha MFG, Monteiro AJ, Lima RAC, Caetano EP, Pereira JF, Castelo-Branco DSCM, Camargo ZP, Sidrim JJC. Histoplasmosis in HIV-positive patients in Ceará, Brazil: clinical-laboratory aspects and in vitro antifungal susceptibility of *Histoplasma capsulatum* isolates. *Trans R Soc Trop Med Hyg* 2012;106(8):484–8.

- [13] Kauffman CA. Histoplasmosis. In: Kauffman CA, Pappas PG, Dismukes WE, Sobel JD, editors. Clinical mycology. New York: Oxford University Press; 2011. p. 321–35.
- [14] Muñoz CO, Cano LE, Gonzalez A. Detección e identificación de *Histoplasma capsulatum* por el laboratorio: de los métodos convencionales a las pruebas moleculares. Infect 2010;14:2.
- [15] Rubin H, Furcolow ML, Yates JL, Brasher CA. The course and prognosis of histoplasmosis. Am J Med 1959;27:278–88.
- [16] Rosado-Odom VM, Daoud J, Johnson R, Allen SD, Lockhart SR, Iqbal N, Shieh WJ, Zak S, Sharfuddin AA. Cutaneous presentation of progressive disseminated histoplasmosis nine years after renal transplantation. Transpl Infect Dis 2013;0:1–6.
- [17] Chan Tche Hiong M. Histoplasmosse pulmonaire à *Histoplasma capsulatum*: À propos de quatre cas observés à Rouen, editor. Université de Rouen, Boulevard Gambetta, France, 2012.
- [18] Faciolla RCL, Coelho MC, Santan RC, Martinez R. Histoplasmosis in immunocompetent individuals living in an endemic area in the Brazilian Southeast. Rev Soc Bras Med Trop 2013;46(4):461–5.