

Sudden Sensorineural Hearing Loss Following the Second Dose of COVID-19 Vaccine

Nikolaos Tsetsos¹, Alexandros Poutoglidis¹, Konstantinos Vlachtsis¹, Adamantios Kilmpasanis¹, Spyridon Gougousis¹

1. Department of Otorhinolaryngology - Head and Neck Surgery, "G. Papanikolaou" General Hospital, Thessaloniki, GRC

Corresponding author: Nikolaos Tsetsos, tsetsosnikos@yahoo.gr

Abstract

Sudden sensorineural hearing loss (SSHL) is a common otolaryngology emergency that significantly affects the patient's quality of life. Although in most cases its etiology remains unknown (idiopathic SSHL), viral infections and vascular compromise constitute the most widely accepted etiopathogenic mechanisms. Specifically, occlusion of the internal auditory artery has been reported in cases of sudden deafness. Thrombotic events following the Oxford-AstraZeneca COVID-19 vaccine are rare. There have been reports of SSHL following immunization with Pfizer and Moderna COVID-19 vaccine; however, no etiologic relationship has been established between the two entities yet. We present a unique case of SSHL following the second dose of the Oxford-AstraZeneca COVID-19 vaccine. A 61-year-old female was referred to our department with a four-day history of the right-sided sense of fullness combined with almost complete hearing loss that had started two days after the second dose of Oxford-AstraZeneca COVID-19 vaccine. Pure tone audiometry showed profound right-sided sensorineural hearing loss. Magnetic resonance imaging of the brain and internal auditory canal and magnetic resonance angiography were both normal. The combination of glucocorticoids and acetylsalicylic acid leads to almost full recovery 15 days after deafness. The COVID-19 era is full of new challenges and clinical dilemmas. In our case, the addition of acetylsalicylic acid to the patient's initial treatment may have contributed to the hearing restoration; however, this fact will remain a hypothesis.

Categories: Neurology, Otolaryngology, Public Health

Keywords: covid-19, sudden sensorineural hearing loss (ssnhl), covid-19 vaccine, sensorineural deafness, acetylsalicylic acid

Introduction

Sudden sensorineural hearing loss (SSHL) is defined as the rapid onset of hearing of at least 30 dB across three consecutive frequencies occurring within a period of 72 hours based on the US National Institute for Deafness and Communication Disorders (NICDC) [1]. Its annual incidence ranges from 5 to 20 cases in 100,000 individuals, with an estimated number of 66,000 new cases per year in the USA [2]. Viral infections, vascular compromise, and autoimmune disorders are some of the possible etiologies, although in 90% of the patients, no cause is identified despite the exhaustive investigation, and the SSHL is characterized as idiopathic [2].

Vascular compromise due to hemorrhage, thrombosis, and vasospasm in the inner ear vessels may lead to cochlear ischemia and potentially SSHL [3]. However, current guidelines advise against the use of thrombolytics, vasodilators, or vasoactive agents as routine therapy in patients with SSHL, due to the lack of documented efficacy and the potential side effects [2].

Case Presentation

A 61-year-old female was referred to our Department with a four-day history of the right-sided sense of fullness combined with almost complete hearing loss that had started two days after the second dose of Oxford-AstraZeneca COVID-19 vaccine. She did not report any history of earache, trauma, or discharge. Hearing loss was not accompanied by tinnitus or vertigo. She had a medical history of hypertension, dyslipidemia, and Hashimoto's thyroiditis all under medical treatment. None of her prescribed medication had been commenced within the previous six months. She denied tobacco use or alcohol consumption.

Otoscopy was unremarkable on both sides. Weber tuning fork test lateralized to the left ear while Rinne test was positive on both sides. Pure tone audiometry showed profound right-sided SSHL of at least 85 dB in every frequency (250-8,000 Hz) (Figure 1).

Review began 08/16/2021

Review ended 08/21/2021

Published 08/25/2021

© Copyright 2021

Tsetsos et al. This is an open access article distributed under the terms of the Creative Commons Attribution License CC-BY 4.0., which permits unrestricted use, distribution, and reproduction in any medium, provided the original author and source are credited.

How to cite this article

Tsetsos N, Poutoglidis A, Vlachtsis K, et al. (August 25, 2021) Sudden Sensorineural Hearing Loss Following the Second Dose of COVID-19 Vaccine. Cureus 13(8): e17435. DOI 10.7759/cureus.17435

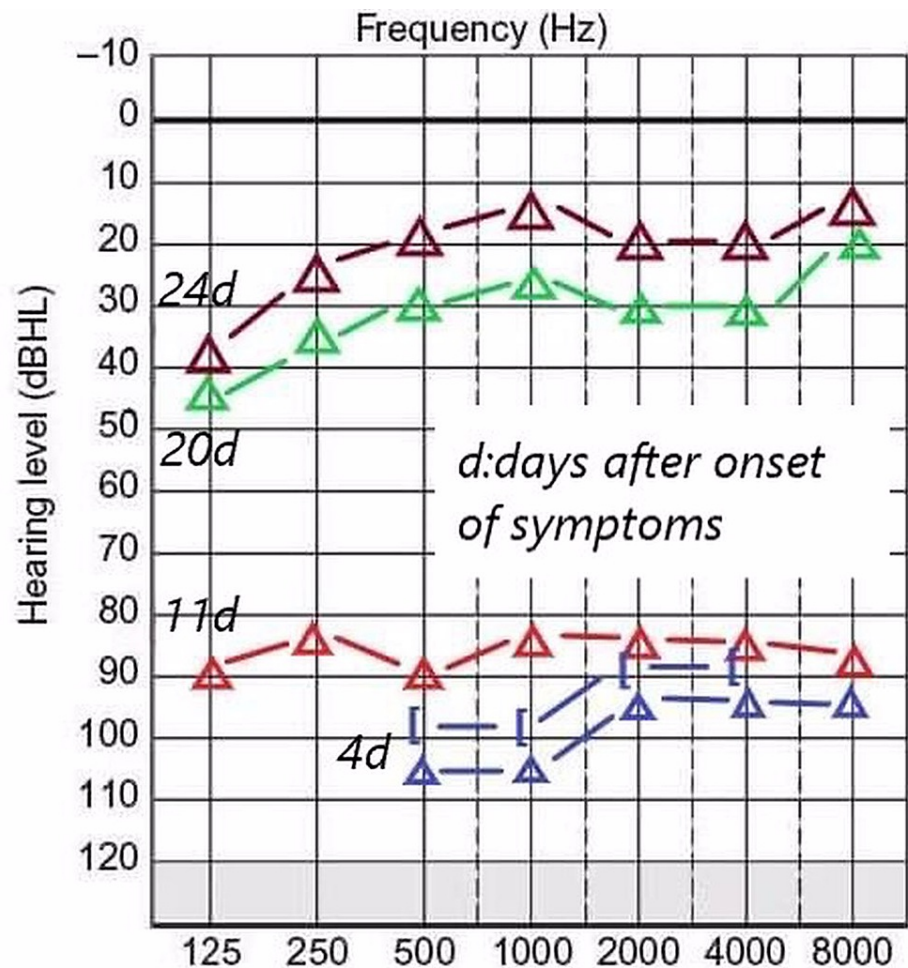


FIGURE 1: Pure tone audiogram presenting the course of hearing improvement from day 4 after the onset of symptoms (admission in the ENT Department) to day 24 (completion of oral glucocorticoids and acetylsalicylic acid).

The initial routine diagnostic workup did not reveal any abnormal findings.

The patient received systemic intravenous glucocorticoids (Dexamethasone 8 mg three times per day for three days with tapering over a week). However, due to her recent history of vaccination with Oxford-AstraZeneca COVID-19 vaccine, neurologists and internists were asked to assess the patient. Anticoagulant therapy with 100 mg of acetylsalicylic acid once daily was commenced. The hearing was evaluated every two days with new pure tone audiometry, which did not reveal any remarkable improvement. One week after treatment initiation, magnetic resonance imaging (MRI) of the brain and internal auditory canal and magnetic resonance angiography (MRA) were conducted. Both imaging tests were normal (Figures 2A-2C).

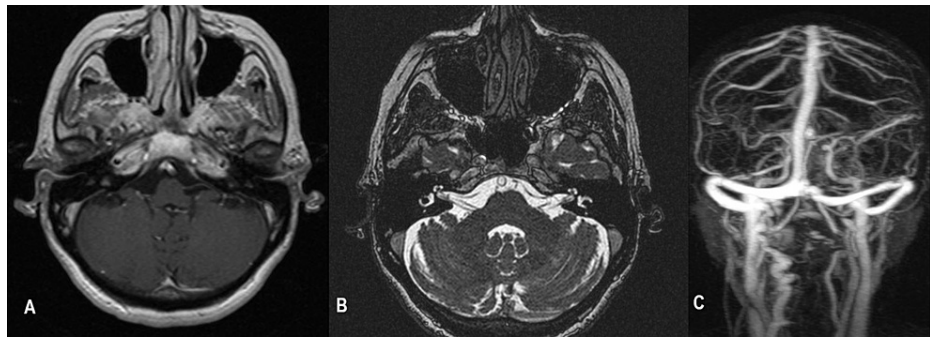


FIGURE 2: (A) Postcontrast axial T1WI MRI (B) Postcontrast axial T2WI MRI and (C) MRA scan of the circle of Willis excluded any identifiable cause of the unilateral hearing loss.

The patient was discharged from the hospital after seven days and was prescribed a nine-day course of oral glucocorticoids and acetylsalicylic acid. After completing the treatment, the patient returned to our Audiology Clinic for a new pure tone audiogram. The patient reported significant improvement in her hearing (15 days after deafness onset and 11 days after initiation of treatment). The new audiogram showed a significant increase in her threshold (almost full recovery) (Figure 1).

Discussion

The cochlea is mainly supplied by one terminal artery, the labyrinthine artery, something that renders it very sensitive to circulatory alterations and ischemia. Thrombosis or vasospasm of the internal auditory artery constitutes one of the main etiopathogenetic mechanisms for idiopathic SSHL. However, the location of the inner ear and its blood supply in the temporal bone, allowed only experimental studies to advocate this mechanism [4].

AstraZeneca COVID-19 vaccine (ChAdOx1 nCoV-19, AZD1222, Vaxzevria; Oxford/AstraZeneca) provides effective immunization against SARS-CoV-2 in the general population [5]. However, safety concerns about increased risk for thrombotic events have led to a temporary halt of vaccination with this vaccine by the German Ministry of Health and other European countries [6,7]. The percentage of deaths following thrombosis is very low and it is suggested that the benefits of immunization far outweigh the risks of potential side effects [8].

In the USA, a Johns Hopkins study concluded that COVID-19 vaccines are not associated with an increased risk for SSHL, based on the evaluation of 40 cases (28 had received the Pfizer vaccine, and 12 had received the Moderna vaccine) of confirmed SSHL among 86,553,330 vaccinations. The incidence of SSHL following the COVID-19 vaccination was estimated to be 0.3% and not only did it not exceed that of the general population, but it could be deemed lower [9]. However, this study is limited by the fact that no other vaccines that are now widely used such as the Oxford-AstraZeneca covid-19 vaccine, were included. Our plan to add acetylsalicylic acid to the patient's initial treatment may have contributed to the hearing restoration; however, this fact will remain a hypothesis.

Conclusions

The COVID-19 era is full of new challenges and clinical dilemmas. A case of SSHL two days after the COVID-19 vaccination should be evaluated carefully and should not be dismissed as a coincidental event. The addition of acetylsalicylic acid to the patient's initial treatment may have contributed to the hearing restoration; however, this fact will remain a hypothesis, as no objective test can ascertain the occlusion of such a microcirculation.

Additional Information

Disclosures

Human subjects: Consent was obtained or waived by all participants in this study. Ethics Committee G' Papanikolaou issued approval 485/2021. The study has been approved by the Ethics Committee G' Papanikolaou. **Conflicts of interest:** In compliance with the ICMJE uniform disclosure form, all authors declare the following: **Payment/services info:** All authors have declared that no financial support was received from any organization for the submitted work. **Financial relationships:** All authors have declared that they have no financial relationships at present or within the previous three years with any organizations that might have an interest in the submitted work. **Other relationships:** All authors have declared that there are no other relationships or activities that could appear to have influenced the

submitted work.

References

1. National Institute of Health: National Institute of Health Sudden Deafness. National Institute of Health, Bethesda, MD; 2000.
2. Chandrasekhar SS, Tsai Do BS, Schwartz SR, et al.: Clinical practice guideline: sudden hearing loss (Update). *Otolaryngol Head Neck Surg.* 2019, 161:S1-S45. [10.1177/0194599819859885](https://doi.org/10.1177/0194599819859885)
3. Kuhn M, Heman-Ackah SE, Shaikh JA, Roehm PC: Sudden sensorineural hearing loss: a review of diagnosis, treatment, and prognosis. *Trends Amplif.* 2011, 15:91-105. [10.1177/1084713811408349](https://doi.org/10.1177/1084713811408349)
4. Mosnier I, Stepanian A, Baron G, et al.: Cardiovascular and thromboembolic risk factors in idiopathic sudden sensorineural hearing loss: a case-control study. *Audiol Neurootol.* 2011, 16:55-66. [10.1159/000312640](https://doi.org/10.1159/000312640)
5. McQuade ETR, Platts-Mills JA: ChAdOx1 nCoV-19 vaccine: asymptomatic efficacy estimates. *Lancet.* 2021, 397:2247-8. [10.1016/S0140-6736\(21\)00951-X](https://doi.org/10.1016/S0140-6736(21)00951-X)
6. Oldenburg J, Klamroth R, Langer F, et al.: Diagnosis and management of vaccine-related thrombosis following AstraZeneca COVID-19 vaccination: guidance statement from the GTH. *Hamostaseologie.* 2021, 41:184-9. [10.1055/a-1469-7481](https://doi.org/10.1055/a-1469-7481)
7. Wise J: Covid-19: European countries suspend use of Oxford-AstraZeneca vaccine after reports of blood clots. *BMJ.* 2021, 372:n699. [10.1136/bmj.n699](https://doi.org/10.1136/bmj.n699)
8. Mahase E: AstraZeneca vaccine: blood clots are "extremely rare" and benefits outweigh risks, regulators conclude. *BMJ.* 2021, 373:n931.
9. Formeister EJ, Chien W, Agrawal Y, Carey JP, Stewart CM, Sun DQ: Preliminary analysis of association between COVID-19 vaccination and sudden hearing loss using US Centers for Disease Control and Prevention vaccine adverse events reporting system data. *JAMA Otolaryngol Head Neck Surg.* 2021, 147:674-6. [10.1001/jamaoto.2021.0869](https://doi.org/10.1001/jamaoto.2021.0869)