

Available online at www.sciencedirect.com

ScienceDirect

journal homepage: www.elsevier.com/locate/radcr

Case Report

H-magnetic resonance spectroscopy: diagnostic tool in recurrent headache in systemic lupus erythematosus. A case report

Emanuele Tinelli, MD, PhD*, Simona Pontecorvo, MD, PhD, Manuela Morreale, MD, PhD, Francesca Caramia, MD, Ada Francia, MD

Department of Human Neurosciences, Sapienza, University of Rome, Rome, Italy

ARTICLE INFO

Article history:

Received 26 July 2018

Revised 17 October 2018

Accepted 22 October 2018

Available online 6 November 2018

Keywords:

Systemic lupus erythematosus

Headache

H-MRS

Metabolic alterations

ABSTRACT

We describe serial MR-spectroscopy studies in a patient with systemic lupus erythematosus and headache. We used MR-spectroscopy to monitor disease activity during periods with and without headache.

MR-spectroscopy investigates metabolic alterations and was used to explore the pathophysiological mechanism involved in the complications of systemic lupus erythematosus.

Our patient underwent serial conventional MRI and MR-spectroscopy at times of controlled and uncontrolled headache, with or without visual aura.

MR-spectroscopy showed an increase in the choline/creatine ratio in thalamus and posterior white matter only during periods of uncontrolled headache with visual aura. Conventional MRI scans were normal at all times.

MR-spectroscopy should be used in the diagnosis and follow-up of headache in patients with systemic lupus erythematosus.

© 2018 The Authors. Published by Elsevier Inc. on behalf of University of Washington.

This is an open access article under the CC BY-NC-ND license.

(<http://creativecommons.org/licenses/by-nc-nd/4.0/>)

Introduction

Systemic lupus erythematosus (SLE) is an autoimmune multiorgan disease which predominantly affects young women.

Neuropsychiatric manifestations, such as psychosis and seizures are common in SLE and may present as isolated

symptoms or in association with other signs of systemic involvement [1].

Headache is a common manifestation of SLE, occurring in approximately 40% of patients and is more frequent in SLE patients with neuropsychiatric manifestations [2].

To date, the specific cause of the high frequency of headaches in SLE patients has not been determined;

* Corresponding author.

E-mail addresses: emanuele.tinelli@gmail.com (E. Tinelli), simona.pontecorvo@uniroma1.it (S. Pontecorvo), manuela.morreale@uniroma1.it (M. Morreale), francesca.caramia@uniroma1.it (F. Caramia), ada.francia@uniroma1.it (A. Francia).
<https://doi.org/10.1016/j.radcr.2018.10.020>

1930-0433/© 2018 The Authors. Published by Elsevier Inc. on behalf of University of Washington. This is an open access article under the CC BY-NC-ND license. (<http://creativecommons.org/licenses/by-nc-nd/4.0/>)

circulating cytokines, cerebrovascular insult, or neuronal injury could be involved [3,4]. The relationship between headache and neuroradiological findings in these patients is also not well known [5].

Conventional cerebral magnetic resonance imaging (MRI) in SLE patients can highlight focal ischemic lesions, white matter hyperintensity, ventricular dilation, and cortical atrophy [4]; however it can also be normal [6,7].

Neuronal dysfunction without MRI visible brain findings may indicate metabolic alterations. In this report we present the case of an SLE patient with recurrent headache, in which H-magnetic resonance spectroscopy (H-MRS) was used as a diagnostic and follow-up procedure.

Case report

A 39-year-old woman was admitted to our center for neuroimmunology in March 2013. The anamnesis was unremarkable. In 2005 arthritis and autoimmune thrombocytopenia were diagnosed. Two years later, SLE according to ARA Criteria [8], and Sjogren's syndrome were diagnosed.

The neurological history began when the patient was 13, when she developed a catamenial migraine without aura (IHS migraine criteria) [9], characterized by severe pain intensity, VAS = 10. At the age of 27 the frequency of attacks increased. The response to therapy became less evident. Headache was unresponsive to common analgesics; only corticosteroid therapy decreased the duration and the intensity of attacks. Also the efficacy of therapy for autoimmune diseases gradually decreased. In May 2013, the patient underwent psychiatric, neurocognitive, and neurophysiologic evaluations. Mood and attention disorder were detected; headache was severe, which was still unresponsive to common analgesics. In September 2013, antiepileptic drugs were introduced which led to an improvement in the headache. Headache features changed in April 2015, with the appearance of visual aura and right side hypoesthesia. In June 2015, treatment with intravenous cyclophosphamide was started which lessened the severity of headache.

Over the years the patient underwent serial conventional MRI and H-MRS at different time points during periods of uncontrolled and controlled headaches, and during headaches with visual aura.

Conventional MRI and H-MRS images were acquired (Philips-Intera 1.5 T) at 3 points: at clinical presentation in May 2013, 1 year later in March 2014 after clinical remission and 2 years later in May 2015, during a period of headaches with aura. Conventional MRI was normal in all examinations.

Multivoxel H-MRS (TR: 1500 ms, TE: 144 ms, matrix: 16) was acquired to evaluate normal appearing posterior periventricular white matter, thalamus, and basal ganglia. The spectra were postprocessed using the software supplied by the machine.

The neurometabolites examined were N-acetylaspartate (Naa: 2.0 ppm) as a neuronal marker, choline (Cho: 3.2 ppm) as a cell membrane metabolism marker, creatine (Cr: 3.0 ppm) as a cell energetic metabolism marker.

As a control group, in June and July 2015 we studied also 6 SLE patients (6 females; age mean \pm SD = 39.6 \pm 2.8) without aura with 2 serial MRI and H-MRS to report the Cho/Cr value and interscan variations of metabolite concentrations. The Cho/Cr interscan variations in the control group was calculated in the left thalamus mean \pm SD = 0.14 \pm 0.02, left normal posterior periventricular white matter mean \pm SD = 0.13 \pm 0.03, and left basal ganglia mean \pm SD = 0.13 \pm 0.02.

The patient's first and third H-MRS examinations showed an increase in the Cho/Cr value in the left thalamus and left posterior periventricular white matter compared to the second examination (Fig. 1).

In the left thalamus, the first examination showed a higher Cho/Cr value compared to the second examination mean = 1.44 vs 1.22, and the third examination showed a higher Cho/Cr value compared to the second examination mean = 1.46 vs 1.22. In the left posterior periventricular white matter, the first examination showed a higher Cho/Cr value than the second examination mean = 1.40 vs 1.15, and the third examination showed a higher Cho/Cr value than the second examination mean = 1.43 vs 1.15. These values were higher than the control group (Table 1).

No significant differences were found in the left basal ganglia. The Naa/Cr ratio value did not show any significant variation. At the present time the patient shows a remission of symptoms.

Discussion

In this case report we show a correlation between the type, severity of headache, and H-MRS abnormalities at 3 points: at clinical presentation during severe headache, after clinical remission, and during a period of headaches with aura.

Some studies have demonstrated either an equal or higher prevalence of migraine compared with tension-type headaches in patients with SLE [10].

A few studies have suggested the existence of a genuine "lupus headache" in SLE patients, which may be associated with disease activity, is usually unresponsive to common analgesics, and improves with the use of corticosteroids [11,12]. However, this entity is still a matter of debate in the literature. Migrainous phenomena in SLE patients have been associated with the involvement of the central nervous system, the use of several drugs (such as nonsteroid anti-inflammatories), and the antiphospholipid syndrome secondary to SLE. The causes of the headache are unclear: circulating cytokines, cerebrovascular insult, or neuronal injury could be involved [13].

Some authors propose that there is no specific cause of headache in SLE, and that psychosocial factors and chronic disease may be responsible for this high prevalence [14]. However, it is still unclear whether headache in general, or only certain types of headache, such as migraine with aura, represents part of the SLE symptom spectrum. Thalamus and posterior white matter are the principal regions involved in the headache attacks with aura [15].

In SLE patients with headache, conventional MRI may be negative or may show unspecific findings such as focal lesions, infarcts, and white matter hyperintensity. H-MRS can provide

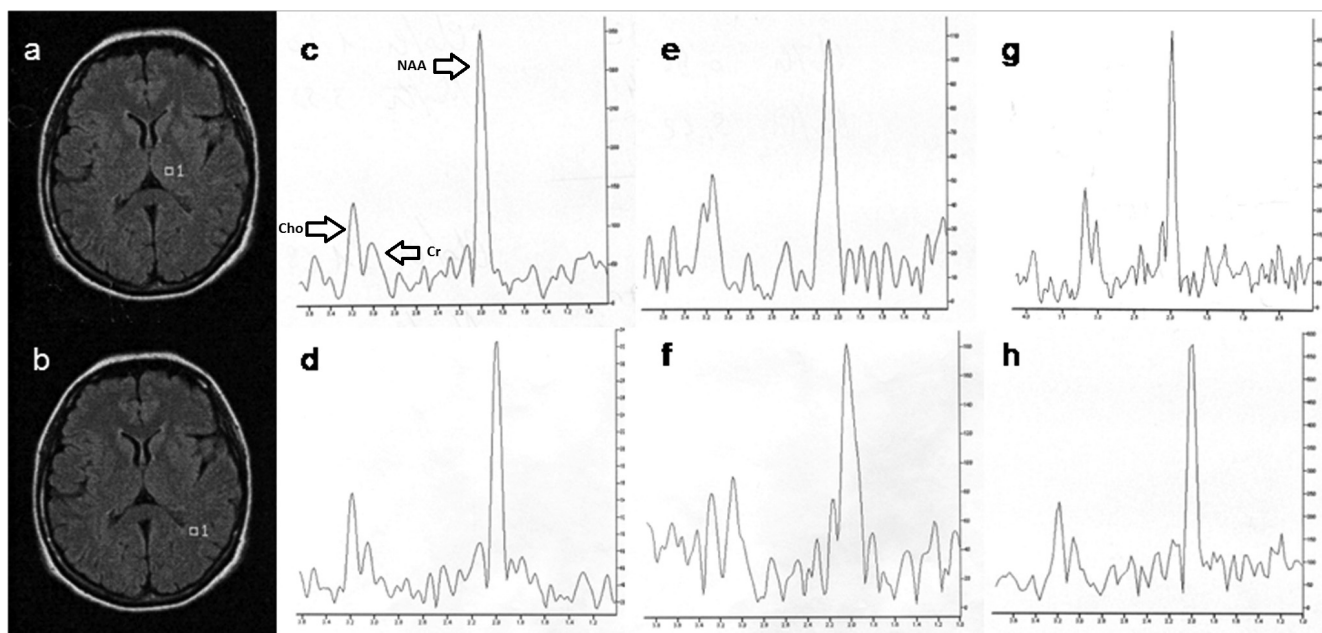


Fig. 1 – Multivoxel H-MRS analysis of VOI located in left thalamus (a) and left posterior periventricular white matter (b). In May 2013 (c-d) during a period of severe headache without aura and in May 2015 (g-h) during a period of headache with aura, H-MRS showed a Cho/Cr ratio higher than the second scan performed in March 2014 (e-f), during the remission of symptoms.

Cho, Choline; Cr, Creatine; NAA, N-acetylaspartate.

Table 1 – Choline/Creatine ratio of VOI in patient during severe headache (May 2013), after clinical remission (March 2014), during a period of headaches with aura (May 2015) and in control subjects group (mean \pm SD).

Cho/Cr	May 2013	March 2014	May 2015	Control subjects
Thalamus	1.44	1.22	1.46	1.18 \pm 0.01
Posterior white matter	1.40	1.15	1.43	1.14 \pm 0.01

supplemental information in neuropsychiatric SLE patients in whom structural MRI failed to show focal changes [16].

Systemic lupus erythematosus with Sjögren syndrome has been recognized in the literature. In Sjögren syndrome, MRI suggests discrete cerebral tissue damage, T2 weighted images may show white matter hyperintensities that are larger and smaller than 2 mm [17–19].

H-MRS of the human brain in vivo provides a noninvasive quantification of biological compounds. Normal brain parenchyma contains large quantities of N-acetyl groups which originate largely from Naa, a compound located exclusively in neurons and neuronal processes [20].

Choline is a cellular marker of membrane density and integrity; malignant tumors show an increase in the Choline peak because of increased cellularity. Increases in the Cho ratio relative to NAA and Cr is observed in other conditions such as cerebral infarctions, inflammation, and MS, and hence in itself, is not a specific finding. Creatine is considered both a marker of energy metabolism, and as a stable metabolite, and is used for calculating metabolite ratios. The increase in the Cho/Cr ratio has also been observed in patients with SLE in normal-appearing brain tissue. This metabolic alteration may

be an indicator of brain injury by microinfarction, cell infiltration, membrane activation, or initial degradation [16,21,22].

In our patient conventional MRI was normal but H-MRS showed abnormalities.

In our patient at the H-MRS exams performed during the presence of headache a significant increase of in Cho/Cr peaks was observed compared to the second examination, during the remission symptoms, and control group.

A decrease in Naa in SLE patients has been reported in the literature and probably reflects neuronal loss and dysfunctions [5,22].

The absence of an Naa change in our case is in agreement with the reversibility of symptoms which suggest the absence of neuronal death.

This case therefore suggests that H-MRS might be useful in the diagnosis and follow-up of headache in neuropsychiatric SLE.

In conclusion, in our patient H-MRS showed metabolic alterations in the thalamus and normal-appearing white matter during migraine attacks. These alterations may be due to an inflammatory process, and H-MRS can help in elucidating the pathogenesis of neuropsychiatric SLE.

REFERENCES

- [1] Huizinga TW, Diamond B. Lupus and the central nervous system. *Lupus* 2008;17(5):376–9. doi:10.1177/0961203308090112.
- [2] Atkinson RA, Appenzeller O. Headache in small vessel disease of the brain: a study of patient with systemic lupus erythematosus. *Headache* 1975;15:198–201.
- [3] Weder-Cisneros ND, Téllez-Zenteno JF, Cardiel MH, Guibert-Toledano M, Cabiedes J, Velásquez-Paz AL, et al. Prevalence and factors associated with headache in patients with systemic lupus erythematosus. *Cephalalgia* 2004;24:1031–44. doi:10.1111/j.1468-2982.2004.00822.x.
- [4] Johnson RT, Richerdsen EP. The neurological manifestations of systemic lupus erythematosus. A clinical–pathological study of 24 cases and review of literature. *Medicine* 1968;47:337–69.
- [5] Bicakci S, Ozbek S, Bicakci K, Aslan K, Kara B, Sarica Y. Recurrent headache and RMN findings in systemic lupus erythematosus. *J Natl Med Assoc* 2008;100(3):323–6.
- [6] Sibbitt WL, Sibbitt RR, Brooks WM. Neuroimaging in neuropsychiatric systemic lupus erythematosus. *Arthritis Rheum* 1999;42:2026–38. doi:10.1002/1529-0131(199910)42:10<2026::AID-ANR2>3.0.CO;2-J.
- [7] West SG, Emlen W, Wener MH, Kotzin BL. Neuropsychiatric lupus erythematosus: a 10-year prospective study on the value of diagnostic tests. *Am J Med* 1995;99:153–63.
- [8] Tan EM, Cohen AS, Fries JF, Masi AT, et al. The 1982 revised criteria for the classification of systemic lupus erythematosus. *Arthritis Rheum* 1982;25:1271–7.
- [9] Headache Classification Committee of the International Headache Society Classification and diagnostic criteria for headache disorders, cranial neuralgias and facial pain. *Cephalalgia* 1988;8(suppl 7):1–96.
- [10] Lessa B, Santana A, Lima I, Almeida JM, Santiago M. Prevalence and classification of headache in patients with systemic lupus erythematosus. *Clin Rheumatol* 2006;25:850–3. doi:10.1007/s10067-005-0186-x.
- [11] Vázquez-Cruz J, Traboulssi H, Rodríguez-De la Serna A, Geli C, Roig C, Diaz C. A prospective study of chronic or recurrent headache in systemic lupus erythematosus. *Headache* 1990;30:232–5.
- [12] Brandt KD, Lessell S. Migrainous phenomena in systemic lupus erythematosus. Prevalence and factors associated with headache in patient. *Arthritis Rheum* 1978;21:7–16.
- [13] Rozell CL, Sibbitt WL Jr, Brooks WM. Structural and neurochemical markers of brain injury in the migraine diathesis of systemic lupus erythematosus. *Cephalalgia* 1998;19:209–15. doi:10.1046/j.1468-2982.1998.1804209.x.
- [14] Omdal R, Waterloo K, Koldingsnes W, Husby G, Mellgren SI. Somatic and psychological features of headache in systemic lupus erythematosus. *J Rheumatol* 2001;28:772–9.
- [15] Hadjikhani N, Sanchez Del Rio M, Wu O, et al. Mechanisms of migraine aura revealed by functional MRI in human visual cortex. *Proc Natl Acad Sci USA* 2001;98(8):4687–92. doi:10.1073/pnas.071582498.
- [16] Peterson PL, Howe FA, Clark CA, Axford JS. Quantitative magnetic resonance imaging in neuropsychiatric systemic lupus erythematosus. *Lupus* 2003;12(12):897–902. doi:10.1191/0961203303lu499oa.
- [17] Yao Q, Altman RD, Wang X. Systemic lupus erythematosus with Sjögren syndrome compared to systemic lupus erythematosus alone: a meta-analysis. *J Clin Rheumatol* 2012;18(1):28–32. doi:10.1097/RHU.0b013e31823ecbdf.
- [18] Morgen K, McFarland HF, Pillemer SR. Central nervous system disease in primary Sjogrens syndrome: the role of magnetic resonance imaging. *Semin Arthritis Rheum* 2004;34(3):623–30.
- [19] Tzarouchi LC, Tsifetaki N, Konitsiotis S, Zikou A, Astrakas L, Drosos A, et al. CNS involvement in primary Sjogren syndrome: assessment of gray and white matter changes with MRI and voxel-based morphometry. *AJR Am J Roentgenol* 2011;197(5):1207–12. doi:10.2214/AJR.10.5984.
- [20] Moffett JR, Ross B, Arun P, Madhavarao CN, Namboodiri AM. N-Acetylaspartate in the CNS: from neurodiagnostics to neurobiology. *Prog Neurobiol* 2007;81(2) 89–13. doi:10.1016/j.pneurobio.2006.12.003.
- [21] Soares DP, Law M. Magnetic resonance spectroscopy of the brain: review of metabolites and clinical applications. *Clinical Radiology* 2009;64(1):12–21. doi:10.1016/j.crad.2008.07.002.
- [22] Appenzeller S, Li LM, Costallat LT, Cendes F. Evidence of reversible axonal dysfunction in systemic lupus erythematosus: a proton MRS study. *Brain* 2005;128:2933–40. doi:10.1093/brain/awh646.