

Clinical Note

Laryngeal carcinoma in a father and son. *Possible familial risk?*

Sarah S. Al-Otaibi, MBBS, Yaseer N. Al Zaher, MD,
Nabil N. Al Zaher, FRCS (C), FACS,
Hatim A. Khoja, MD, FRCS(C).

It is our pleasure to share with our readers and the medical community, information regarding the occurrence of laryngeal carcinoma in a father and son pair. This is only the sixth identified familial case worldwide in the Middle East.¹ Based on this rare observation, appropriate consideration should be given to the influence of genetic factors in the etiopathogenesis of this tumor. With this report, we try to shed some light to the probability that laryngeal cancer may have some genetic predisposition.

A 26-year-old male, healthy, attended our clinic with a 5-month history of continuous voice hoarseness without other symptoms. His past medical history included smoking for 7 pack per years, but with no alcohol consumption or recorded personal or family history of Fanconi anemia or dyskeratosis congenita. However, his father had undergone chemoradiotherapy at the age of 44 for a left glottic laryngeal carcinoma. The laryngoscopic assessment of our patient, the son, revealed the presence of a left vocal cord small irregular mass lesion and subsequent lesion biopsy confirmed an invasive moderately differentiated squamous cell carcinoma (Figure 1). The staging studies that were carried out also confirmed a glottic (T1aN0M0) laryngeal cancer. All management options were presented to him, who eventually elected to be treated with external beam radiotherapy. His father, an ex-smoker, had previously been diagnosed with a well-differentiated left glottic laryngeal carcinoma (T3N0M0) at the age of 44 and was successfully treated at our institution with chemoradiotherapy 9 years ago. The father is still alive and well and, so far, has had no recurrence.

Over 90% of laryngeal malignancies are pathologically diagnosed as squamous cell carcinomas and are most commonly seen in males between 51 to 60 years of age.² Well-established risk factors include, among others, tobacco smoking and excessive alcohol consumption, which when combined, synergistically increase risk. Furthermore, both the duration and intensity of smoking contributes to the risk of developing this disease.³ However, these risk factors do not explain why certain families have an increased incidence of this type of tumor, especially at an earlier onset than usual.

A review of the literature uncovered 5 similar familial occurrences of laryngeal cancer,¹ yet none presented at

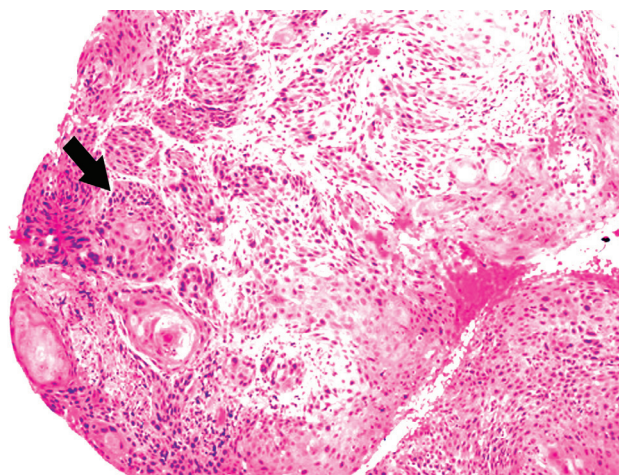


Figure 1 - Section, including the arrow, shows an invasive squamous cell carcinoma, moderately differentiated in the son

such an early age as observed here, and there is no clear-cut evidence supporting a heritable laryngeal carcinoma. Genetic polymorphisms associated with carcinogen and folate metabolism predispose individuals to an increased risk of head and neck cancer.⁴ Garavello et al⁵ stated that a family history of laryngeal carcinoma in a first-degree relative does indeed increase this risk, even more so when the affected relative is younger than 60 years of age. So, a family history of laryngeal carcinoma acts as an independent risk factor, in addition to smoking and alcohol.

Cases of laryngeal carcinoma within families raise the suspicion of genetic susceptibility. In our young patient with a family history of laryngeal cancer, a genetic component may well be hypothesized; in both patients the tumor was in the left vocal cord and both were diagnosed in a younger age than the average of 60 years. Members of the Medical Genetics Department at our institution were consulted and we were advised that there is currently no known genetic mutation that could explain the presence of a squamous cell carcinoma of the larynx in both father and the son.

In conclusion, laryngeal carcinoma in first-degree relatives does warrant a genetic consideration as having an inheritable component. This also may be more relevant where the age of onset is below average. Further future studies would therefore be advised to uncover the genetic linkage laryngeal carcinoma may have.

Received 11th December 2017. Accepted 21st February 2018.

From the Department of Otolaryngology-Head & Neck Surgery (Al-Otaibi, Al Zaher YN, Al Zaher NN), and from the Department of Pathology & Laboratory Medicine (Khoja), King Faisal Specialist Hospital & Research Centre, Riyadh, Kingdom of Saudi Arabia.

Address correspondence and reprints request to: Dr. Sarah S. Al-Otaibi, Department of Otolaryngology-Head & Neck Surgery, King Faisal Specialist Hospital & Research Centre, Riyadh, Kingdom of Saudi Arabia. E-mail: ssalotaibi@outlook.com
ORCID ID: orcid.org/0000-0003-1116-2040

References

1. Gencik A, Wey W, Müller H. High incidence of laryngeal carcinoma in a swiss family. *ORL J Otorhinolaryngol Relat Spec* 1986; 48: 162-166.
2. Aslan H, Pinar E, Öztürkcan S, Aladag I, Karaca N, Etit D, et al. Potential pitfalls of computed tomography in advanced laryngeal cancer. *ENT Updates* 2016; 6: 5-11.
3. Instituto Nacional de Câncer José Alencar Gomes da Silva. Estimate 2014: Cancer incidence in Brazil. [cited 2014]. Available from URL: http://www.inca.gov.br/rbc/n_60/v01/pdf/11-resenha-estimativa-2014-incidencia-de-cancer-no-brasil.pdf
4. Hiyama T, Yoshihara M, Tanaka S, Chayama K. Genetic polymorphisms and head and neck cancer risk (review). *Int J Oncol* 2008; 32: 945-973.
5. Garavello W, Turati F, Bosetti C, Talamini R, Levi F, Lucenteforte E, et al. Family history of cancer and the risk of laryngeal cancer: a case-control study from Italy and Switzerland. *Int J Cancer* 2012; 130: 665-670.