

# Secondary sulcus-fixed foldable IOL implantation with 25-G infusion in patients with previous PPV after open-globe injury

Tiangeng He, Caiyun You, Song Chen, Xiangda Meng, Yuanyuan Liu, Hua Yan

Department of Ophthalmology, Tianjin Medical University General Hospital, Tianjin - PR China

Tiangeng He and Caiyun You contributed equally to this work.

## ABSTRACT

**Purpose:** To evaluate the safety and efficacy of secondary sulcus-fixed foldable intraocular lens (IOL) implantation through a clear corneal incision with 25-G infusion in patients with previous pars plana vitrectomy (PPV) after open-globe injury, and to analyze postoperative outcomes and prognostic factors of treatment.

**Methods:** Clinical data of 89 eyes of 89 patients with open-globe injury who underwent secondary sulcus-fixed foldable IOL implantation through a clear corneal incision with 25-G infusion after vitrectomy in our hospital between January 2008 and June 2015 were retrospectively analyzed. The examinations before IOL implantation mainly included visual acuity, slit-lamp examination, direct and indirect ophthalmoscope, visual electrophysiology, corneal endothelium, B scan, ultrasound biomicroscope, and intraocular pressure. Five eyes underwent suturing of peripheral iris and 7 eyes underwent suturing of iris laceration simultaneously. The mean follow-up was 18 months with a range from 6 months to 8 years.

**Results:** The mean interval between secondary sulcus-fixed foldable IOL implantation and vitrectomy was 2.8 months with a range from 2 to 6 months. The uncorrected visual acuity improved in all patients with a well-centered IOL ranging from 0.1 to 0.8 with the best-corrected visual acuity from 0.1 to 1.0 after secondary IOL implantation. The postoperative complications mainly included mild anterior chamber exudates in 10 eyes (11%), temporary IOP elevation in 12 eyes (13%), and recurrent retinal detachment in 5 eyes (6%), which were subsequently managed by surgery.

**Conclusions:** The interval of 2.8 months between vitrectomy and secondary IOL implantation is an appropriate and safe option to correct aphakia in patients receiving vitrectomy for open-globe injury.

**Keywords:** Intraocular foreign body, Intraocular lens implantation, Open-globe injury, Pars plana vitrectomy

## Introduction

Ocular trauma is the leading cause of acquired monocular blindness. Open-globe injury often has a poor visual outcome owing to possible posttraumatic endophthalmitis, intraocular foreign body (IOFB), penetrating injury, or ocular rupture (1-4). Posttraumatic endophthalmitis is a rare but serious complication of open-globe injury with poor prognosis.

Open-globe injuries complicated by the presence of an IOFB constitute a vision-threatening condition, and poor prognostic factors include retinal detachment and infection (5).

Early diagnosis and prompt management are necessary to avoid severe complications such as eye enucleation in open-globe injuries. Risk factors for this complication are IOFB, type of ocular trauma, and especially a delay in initial management of the trauma. Surgical intervention with pars plana vitrectomy (PPV) combined with IOFB removal, traumatic cataract extraction, and repair of retina is a safe and effective method to preserve severely traumatized eyes and even improve vision (1, 4). Anatomical and functional result of the combined injury depends not only on the choice of the surgical technique, but predominantly on the extent and severity of the initial injury.

Secondary intraocular lens (IOL) implantation can offer good visual rehabilitation in vitrectomized eyes that can be well-corrected by spectacles after vitrectomy. Timing and method of secondary IOL implantation for correction of vitrectomized aphakia is a challenge, especially in terms of loss

Accepted: March 13, 2017

Published online: May 16, 2017

### Corresponding author:

Hua Yan, MD, PhD  
Department of Ophthalmology  
Tianjin Medical University General Hospital  
No. 154 Anshan Road  
300052 Tianjin, China  
phuayan2000@163.com

of integrity of capsule and zonular dialysis. Several studies demonstrated favorable results of primary IOL implantation performed at the time of initial reconstruction for injured eyes according to the advocating strategy (6-9). However, complications such as fibrinous uveitis, synechiae, pupillary capture, retinal detachment, and other posterior segment complications have been associated with primary IOL implantation in those injured eyes (10-13). Therefore, in this series, we introduced and analyzed the surgical method of secondary sulcus-fixed foldable IOL implantation through a clear corneal incision with 25-G infusion in 89 eyes with PPV after open-globe injury in our hospital. The aim of this study is to evaluate the timing and visual outcome in patients with previous PPV after open-globe injury, and to analyze the main prognostic factors of treatment.

## Methods

### Patients

The study was approved by the Tianjin Medical University General Hospital Medical Ethics Committee. Clinical data of 89 eyes of 89 patients with open-globe injury who underwent secondary sulcus-fixed foldable IOL implantation through a clear corneal incision with 25-G infusion after vitrectomy in our hospital between January 2008 and June 2015 were retrospectively analyzed. All 89 patients (61 male, 28 female) received unilateral complicated eye injury initially. The age ranged from 15 to 67 years with a mean of 37 years. Each had a history of primary treatment of penetrating injury. The vision ranged from light perception to 0.3 before vitrectomy. The preoperative intraocular pressure (IOP) ranged from 10 mm Hg to 19 mm Hg with a mean of 13 mm Hg. The mean follow-up was 18 months with a range from 6 months to 8 years. The anterior and posterior capsule were absent in all patients after vitrectomy.

In all injured eyes, there were 36 eyes of 36 patients with penetrating injury, 28 eyes of 28 patients with IOFB, 13 eyes of 13 patients with ocular rupture, and 12 eyes of 12 patients with endophthalmitis. The IOFB included magnetic foreign body in 17 eyes of 17 patients, glass foreign body in 5 eyes of 5 patients, and eyelash foreign body in 6 eyes of 6 patients.

Systematic evaluation is necessary for ocular trauma patients before secondary surgery. All patients underwent complete ophthalmologic examinations prior to secondary IOL implantation, which mainly included uncorrected visual acuity (UCVA), best-corrected visual acuity (BCVA), slit-lamp biomicroscopy, direct and indirect ophthalmoscopy, visual electrophysiology, corneal endothelium, B-scan, ultrasound biomicroscopy, and IOP. Keratometry and biometry of the injured eyes were performed. If keratometry and biometry were not possible on the injured eye, fellow eye measurements were adopted. Exclusion criteria for secondary IOL implantation included BCVA less than 0.1 preoperatively by spectacles.

### Surgical procedures and postoperative management

All surgeries were performed by a single surgeon (H.Y.) under retrobulbar injection of lidocaine making the eyes

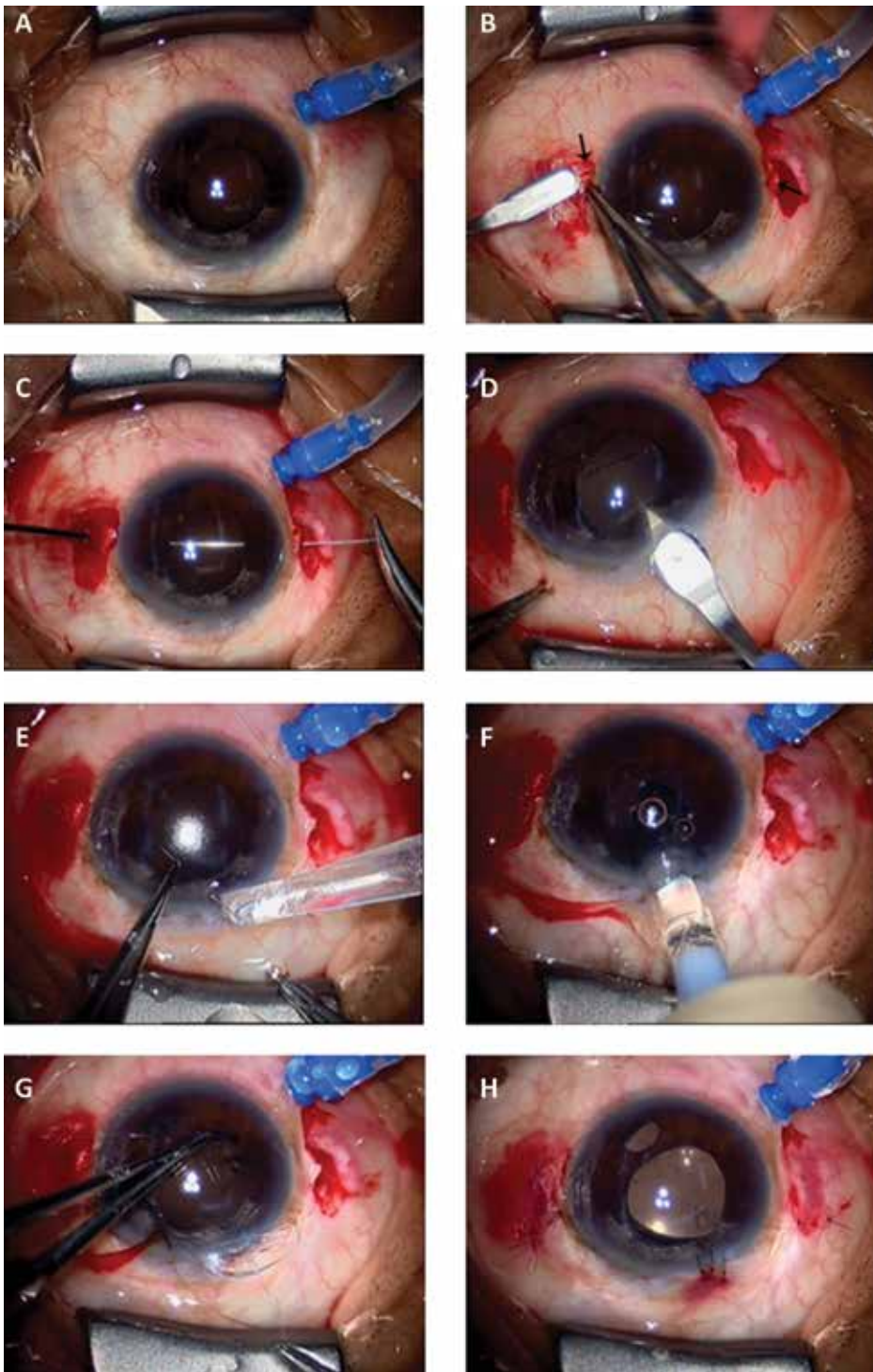
akinetic. All patients had povidone-iodine 10% preparation to the lids and conjunctival sac. During the initial vitrectomy procedure, 20-G or 23-G PPV was adopted. Traumatic cataract extraction was performed simultaneously either through sclerotomy or clear corneal incision. In cases of IOFB, posterior vitreous detachment was induced when it was not there. The IOFB was made free from its attachments. If IOFB had diameter less than 3 mm, it was removed through the enlarged sclerotomy site. If the size of IOFB was larger than 3 mm in diameter, it was usually lifted to the pupillary plane and removed through the corneal limbus incision. Then, complete vitrectomy was performed. Photocoagulation or cryotherapy was conducted for closing retinal break and followed by filling with silicone oil or  $C_3F_8$ . Peripheral iridectomy was performed in cases with silicone oil tamponade. Thirty-six eyes were tamponaded with silicone oil, and 53 eyes were tamponaded with  $C_3F_8$  during vitrectomy.

In endophthalmitis cases, anterior chamber and vitreous specimens were obtained for microbiology culture before turning on of the infusion fluid. Once a sample was obtained, the infusion was turned on and the vitrectomy procedure was continued. The samples were cultured on blood agar, chocolate agar, Sabouraud agar, and thioglycolate broth. After inflammatory vitreous was completely resected, the pus on the surface of retina was drained by backflush needle. If the retinal vessels were obstructed, laser photocoagulation was applied. Air-fluid exchange and silicone oil injection were conducted before the sclerotomies were closed (14).

Secondary IOL implantation was performed under retrobulbar injection of lidocaine. In eyes without any anterior and posterior capsule, 25-G infusion cannula was created, and then the triangular lamellar scleral flaps were made at 3 and 9 o'clock, respectively, for protecting IOL suture. The suture needle entered the eye under the sclera flap at 9 o'clock and was relayed into a 1 mL syringe needle at 3 o'clock, and then the suture was pulled out through the clear corneal incision. The foldable IOL was fixed by suturing in the sulcus (Fig. 1). Five eyes underwent suturing of peripheral iris and 7 eyes underwent suturing of iris laceration simultaneously. We implanted a secondary IOL in patients with BCVA better than 0.1 preoperatively. The power was calculated with the SRK-II formula according to the keratometry and biometry.

Antibiotic eyedrops were used 3 times a day for 1 week postoperatively. Follow-up was scheduled every day at the first postoperative week, then every week for 1 month, and every 3 months up to 1 year after surgery. Follow-up visits then were performed every 6-12 months. Recording of BCVA, IOP, slit-lamp examination, and indirect ophthalmoscopy was done postoperatively in each case.

All cases had characteristic data extracted from the medical records including general demographics, type of trauma, interval between vitrectomy and secondary IOL implantation, preoperative and postoperative visual acuity (UCVA and BCVA), IOP, and complications. Statistical analysis was carried out using independent sample test method for quantitative variables.  $P < 0.05$  was considered statistically significant. All data were analyzed by using the computer statistical analysis software package SPSS 13.



**Fig. 1** - A 38-year-old man underwent initial vitrectomy for traumatic cataract extraction, intraocular foreign body removal, and retinal detachment with  $C_3F_8$  filling. The best-corrected visual acuity (BCVA) was 0.6 after vitrectomy. The secondary sulcus-fixed foldable intraocular lens (IOL) implantation through a clear corneal incision with 25-G infusion was performed 3 months after initial vitrectomy. The uncorrected visual acuity was 0.5 and BCVA was 0.6 at the final follow-up postoperatively. (A) A 25-G infusion cannula was fixed 3 mm from the corneal limbus at the inferotemporal site. The infusion was kept turned on until the completion of the surgery. (B) Triangular lamellar scleral flaps were made with the corneal limbus as base (arrow) at 3 and 9 o'clock for protecting the IOL suture. (C) The suture needle (10-0 polypropylene) entered the eye under the sclera flap at 9 o'clock and was relayed into a 1 mL syringe needle in the posterior chamber, which entered the eye at 3 o'clock. (D) A 3.0 mm clear corneal incision was made, and the 10-0 polypropylene suture was pulled out through the incision. (E) The foldable lens was put in the IOL injector, and was pushed until the front haptic just exposed from the cartridge. Then the front haptic was tied by 10-0 polypropylene for preparing fixation. (F) The foldable lens was pushed into the posterior chamber with the posterior haptic left out of the incision. (G) The posterior haptic was tied by 10-0 polypropylene for preparing fixation. (H) The foldable IOL was fixed by suturing in the sulcus with a well-centered position.

## Results

### Timing of secondary IOL implantation

Anatomic success was achieved in 89 eyes (100%) after initial vitrectomy. The mean interval between secondary IOL implantation and vitrectomy was 2.8 months with a range from 2 to 6 months.

### Visual acuity

The BCVA was 0.1 to 1.0 after vitrectomy. In the current series, the UCVA improved in all patients with a well-centered IOL ranging from 0.1 to 0.8, and the BCVA ranged from 0.1 to 1.0 after secondary IOL implantation. In our data, 3 eyes (3%) had final BCVA of 1.0, and 61 eyes (69%) had a BCVA ranging from 0.3 to 1.0 at the last follow-up.

The other 25 eyes (28%) achieved final BCVA from 0.1 to 0.3.

### **Intraocular pressure**

The mean postoperative IOP was 14 mm Hg with a range from 10 mm Hg to 19 mm Hg, and there was no significant difference compared with preoperative values ( $p > 0.05$ ).

### **Complications**

Postoperative complications after secondary IOL implantation included mild anterior chamber exudates in 10 eyes (11%), temporary IOP elevation in 12 eyes (13%), and recurrent retinal detachment in 5 eyes (6%), which were subsequently managed by surgery. No other complications were observed in this study.

### **Discussion**

Anatomic and functional results of this complicated injury depend not only on the choice of the surgical technique, but predominantly on the extent and severity of the initial injury. Attempted IOL implantation in eyes with BCVA better than 0.1 can lead to improvement of UCVA in those patients with previous PPV for open-globe injury. However, the management and timing of secondary sulcus-fixed foldable IOL implantation is the pivotal issue. At present, there are no unified criteria of timing for secondary sulcus-fixed foldable IOL implantation. It is necessary to monitor the surgical outcome and to investigate reasonable timing and easy method for aphakia after initial vitrectomy for open-globe injury.

In this series, we collected 89 eyes that underwent secondary sulcus-fixed foldable IOL implantation after traumatic cataract extraction and PPV for vitreoretinopathy associated with the initial open-globe injury. We found an interval of 2.8 months between vitrectomy and secondary sulcus-fixed foldable IOL implantation as an appropriate and safe option to correct aphakia in those patients. All patients achieved UCVA improvement with a well-centered IOL and low rate of complications by secondary sulcus-fixed foldable IOL correction.

Concerning the timing of secondary sulcus-fixed foldable IOL implantation in vitrectomized eyes after open-globe injury, we found 2.8 months to be a reasonable and safe choice. First, the gas such as  $C_3F_8$  introduced into the vitreous cavity nearly disappeared around 2 months after vitrectomy surgery. If resetting of the retinal detachment is favorable, then secondary sulcus-fixed IOL implantation is feasible. Second, in vitrectomized eyes with silicone oil tamponade filling, silicone oil removal is commonly performed 2 to 3 months postoperatively, and combined secondary IOL implantation is conducted simultaneously if the retinal reattachment after silicone oil removal is perfect. Third, the duration of 2 to 3 months after vitrectomy can provide vitrectomized eyes a more stable retinal anatomic result and refraction status, which will induce much more accurate calculated diopters of IOL and less rate of recurrence of retinal detachment. Finally, the postoperative complications disappeared 2 to 3 months after PPV, and that led to only mild inflammation occurring after the secondary IOL implantation.

Secondary IOL implantation in the sulcus was sutured or not depending on the integrity of capsular bag. Posterior chamber IOL was implanted over the anterior or posterior capsule if the residual anterior or posterior capsule was strong enough to support the IOL. Choices of IOL implantation in cases without capsular support should be sulcus fixation by suturing. In our study, all patients received secondary sulcus-fixed foldable IOL implantation with 25-G infusion. Compared with the previous IOL implantation method (15), secondary sulcus-fixed foldable IOL implantation with 25-G infusion makes the intraoperative IOP more stable. A previous method of secondary sulcus-fixed IOL implantation was performed by injection of adequate Healon into the eye to make the intraoperative IOP stable, which had to be aspirated at the end of the surgery. The postoperative IOP inevitably elevated even Healon aspirated completely during the surgery. However, with the use of 25-G infusion, IOP can be maintained from the beginning to the end of the surgery, and all the manipulations of IOL implantation can proceed safely. Also, the postoperative IOP should be normal without any effect of Healon.

In the procedure of sulcus-fixed IOL implantation, the position of IOL suturing should be kept away from the previous retinal injury and potential vitreous traction, in case it leads to unnecessary peripheral vitreous incarceration into the sclerotomy intraoperatively and recurrence of postoperative retinal detachment by vitreous traction (16). In the report of Olsen and Pribila (17) using endoscopic to fix IOL implantation, postoperative visual function improved with the advantages of clear operation procedure without bleeding and accurate position IOL fixed. However, the operation is technically challenging, requiring more surgical time and a very experienced surgeon, and has increased possibility of associated complications.

Riazi et al (3) reported their outcome of secondary IOL implantation after initial vitrectomy for trauma, and their results showed that 6 to 60 months was a proper option for these eyes. In their cases, all the patients had visual improvement postoperatively as well, although a few had postoperative complications of uveitis, hemorrhage, and choroid detachment. A study by Mahapatra and Rao (18) found that 28% of their patients had retinal detachment due to vitreous retinopathy after vitrectomy, IOFB removal, and sulcus initial IOL implantation. Chuang and Lai (19) reported on their cases of traumatic cataract with open-globe injury and secondary IOL implantation, and significant visual improvement was observed. The major complications in their series were secondary glaucoma, macular ruffle, and retinal detachment. In the current series, all patients achieved UCVA improvement with a well-centered IOL. The postoperative UCVA ranged from 0.1 to 0.8 and the BCVA ranged from 0.1 to 1.0. This is comparable with previous similar studies.

We reviewed the outcome and complications in 89 vitrectomized eyes with penetrating injury, IOFB, endophthalmitis, or ocular rupture, and anatomic success was achieved in all eyes by initial vitrectomy. Postoperative mean IOP had no significant difference compared with preoperative IOP. In our data, postoperative complications, especially the incidence of retinal detachment (6%), were significantly lower than that in previous reports. In total, the postoperative complications

after secondary sulcus-fixed foldable IOL implantation mainly included mild anterior chamber exudates, temporary IOP elevation, and recurrent retinal detachment, and no other complications were observed in this study. We considered that possible reasons for postoperative complications might be simultaneous complicated surgical procedure in the traumatic eye that could aggravate the inflammatory response on the sulcus by suturing through the ciliary muscle and unstable IOP during the operation (20), including vitrectomy and sulcus-fixed IOL implantation together with the trauma itself. Severe inflammatory response will lead to the recurrence of retinal detachment due to probability of retinopathy. On the other hand, a prolonged interval between vitrectomy and secondary IOL implantation makes no sense in terms of the visual rehabilitation in aphakia. Considering these conditions, appropriate secondary IOL implantation when the eyes are relatively stable should be a more viable and safer option after initial vitrectomy (13, 21).

In summary, with the advances in surgical techniques of vitrectomy for open-globe injury, more cases of aphakia after ocular trauma have possible faster visual rehabilitation by secondary IOL implantation. Our results indicate that secondary sulcus-fixed foldable IOL implantation remains a safer and more effective option with fewer complications after vitrectomy for ocular injury. To our knowledge, there are few reports on secondary sulcus-fixed foldable IOL implantation with 25-G infusion after PPV for open-globe injury. According to our clinical experience, timing of 2.8 months after vitrectomy is safe and desirable in aphakia. Proper method and timing for secondary foldable IOL implantation can offer advanced visual rehabilitation with low rate of complications in vitrectomized eyes. The main disadvantage of this procedure is an added surgery, increasing cost and patient discomfort. Randomized controlled studies involving larger numbers of patients with longer follow-up period are required before any further conclusions can be drawn.

## Disclosures

Financial support: No financial support was received for this submission.

Conflict of interest: None of the authors has conflict of interest with this submission.

## References

- Chiquet C, Zech JC, Gain P, Adeleine P, Trepsat C. Visual outcome and prognostic factors after magnetic extraction of posterior segment foreign bodies in 40 cases. *Br J Ophthalmol*. 1998;82(7):801-806.
- Doskova H, Vlkova E. Surgical treatment of combined injuries of the anterior and posterior segment of the eye with intraocular metallic foreign body. *Ceska a slovenska oftalmologie: casopis Ceske oftalmologicke spolecnosti a Slovenske oftalmologicke spolecnosti*. 2006;62(1):42-47.
- Riazi M, Moghimi S, Najmi Z, Ghaffari R. Secondary Artisan-Verysise intraocular lens implantation for aphakic correction in post-traumatic vitrectomized eye. *Eye (Lond)*. 2008;22(11):1419-1424.
- Chorągiewicz T, Nowomiejska K, Wertejuk K, et al. Surgical treatment of open globe trauma complicated with the presence of an intraocular foreign body. *Klin Oczna*. 2015;117(1):5-8.
- Nicoară SD, Irimescu I, Călinici T, Cristian C. Intraocular foreign bodies extracted by pars plana vitrectomy: clinical characteristics, management, outcomes and prognostic factors. *BMC Ophthalmol*. 2015;15:151.
- Lamkin JC, Azar DT, Mead MD, Volpe NJ. Simultaneous corneal laceration repair, cataract removal, and posterior chamber intraocular lens implantation. *Am J Ophthalmol*. 1992;113(6):626-631.
- Rubsamen PE, Irvin WD, McCuen BW II, Smiddy WE, Bowman CB. Primary intraocular lens implantation in the setting of penetrating ocular trauma. *Ophthalmology*. 1995;102(1):101-107.
- Bowman RJ, Yorston D, Wood M, Gilbert C, Foster A. Primary intraocular lens implantation for penetrating lens trauma in Africa. *Ophthalmology*. 1998;105(9):1770-1774.
- Pavlovic S. Primary intraocular lens implantation during pars plana vitrectomy and intraretinal foreign body removal. *Retina*. 1999;19(5):430-436.
- Thouvenin D, Lesueur L, Arne JL. [Intercapsular implantation in the management of cataract in children. Study of 87 cases and comparison to 88 cases without implantation]. *J Fr Ophtalmol*. 1995;18(11):678-687.
- Koenig SB, Ruttum MS, Lewandowski MF, Schultz RO. Pseudophakia for traumatic cataracts in children. *Ophthalmology*. 1993;100(8):1218-1224.
- Chan TK, Mackintosh G, Yeoh R, Lim AS. Primary posterior chamber IOL implantation in penetrating ocular trauma. *Int Ophthalmol*. 1993;17(3):137-141.
- Tyagi AK, Kheterpal S, Callear AB, Kirkby GR, Price NJ. Simultaneous posterior chamber intraocular lens implant combined with vitreoretinal surgery for intraocular foreign body injuries. *Eye (Lond)*. 1998;12(Pt 2):230-233.
- Yan H, Lu Y, Yu J, et al. Silicone oil in the surgical treatment of traumatic endophthalmitis. *Eur J Ophthalmol*. 2008;18(5):680-684.
- Ma LW, Xuan D, Li XY, Zhang JS. Corneal astigmatism correction with scleral flaps in trans-scleral suture-fixed posterior chamber lens implantation: a preliminary clinical observation. *Int Ophthalmol*. 2011;4(5):502-507.
- Condon GP. Simplified small-incision peripheral iris fixation of an AcrySof intraocular lens in the absence of capsule support. *J Cataract Refract Surg*. 2003;29(9):1663-1667.
- Olsen TW, Pribila JT. Pars plana vitrectomy with endoscope-guided sutured posterior chamber intraocular lens implantation in children and adults. *Am J Ophthalmol*. 2011;151(2):287-96.e2.
- Mahapatra SK, Rao NG. Visual outcome of pars plana vitrectomy with intraocular foreign body removal through sclerocorneal tunnel and sulcus-fixed intraocular lens implantation as a single procedure, in cases of metallic intraocular foreign body with traumatic cataract. *Indian J Ophthalmol*. 2010;58(2):115-118.
- Chuang LH, Lai CC. Secondary intraocular lens implantation of traumatic cataract in open-globe injury. *Can J Ophthalmol*. 2005;40(4):454-459.
- Weissgold DJ, Kaushal P. Late onset of rhegmatogenous retinal detachments after successful posterior segment intraocular foreign body removal. *Br J Ophthalmol*. 2005;89(3):327-331.
- Lam DS, Tham CC, Kwok AK, Gopal L. Combined phacoemulsification, pars plana vitrectomy, removal of intraocular foreign body (IOFB), and primary intraocular lens implantation for patients with IOFB and traumatic cataract. *Eye (Lond)*. 1998;12(Pt 3a):395-398.

