

Massive Transcranial Parotid Pleomorphic Adenoma: Recurrence after 30 Years*

Graham M. Strub, M.D., Ph.D.¹ Alexandros Georgolios, M.D.¹ Robert S. Graham, M.D.²
Celeste N. Powers, M.D., Ph.D.³ Daniel H. Coelho, M.D.¹

¹ Department of Otolaryngology-Head and Neck Surgery;

² Department of Neurosurgery;

³ Department of Pathology, Virginia Commonwealth University Medical Center, Richmond, Virginia.

Address for correspondence and reprint requests Daniel Coelho, M.D., Department of Otolaryngology-Head and Neck Surgery, Virginia Commonwealth University Medical Center, Richmond, VA 23298-0146 (e-mail: dcoelho@mcvh-vcu.edu).

J Neurol Surg Rep 2012;73:1–5.

Abstract

Keywords

- ▶ pleomorphic adenoma
- ▶ benign mixed tumor
- ▶ recurrent pleomorphic adenoma
- ▶ carcinoma ex pleomorphic adenoma
- ▶ intracranial invasion

Pleomorphic adenoma, also known as benign mixed tumor, is the most common tumor affecting the parotid gland and can reach massive size; however, intracranial invasion is rare. Recurrence of pleomorphic adenoma after excision is a well-known phenomenon and can present decades after resection of the primary tumor. Here we present the case of a 53-year-old man who presented to our clinic with ear fullness, otalgia, and hearing loss 30 years after undergoing total parotidectomy and external beam radiotherapy for pleomorphic adenoma. Magnetic resonance imaging revealed a massive transcranial tumor invading the mastoid cavity, the dura of the posterior fossa, the fallopian and semicircular canals, the jugular foramen, the lateral infratemporal fossa skull base, the sigmoid and transverse sinuses, and the superior parapharyngeal region. Gross examination and histopathological studies confirmed that the mass was a recurrent pleomorphic adenoma. Here we discuss the features of recurrent pleomorphic adenoma and review the current literature.

Case Report

A 53-year-old man presented to the emergency department with a 7-day history of right ear fullness, otalgia, and hearing loss. He had recently been treated with antibiotics for sinusitis at an outside hospital but his symptoms failed to resolve. He denied vertigo, dizziness, otorrhea, or tinnitus. Physical examination demonstrated a mass behind an intact right eardrum, and tuning fork evidence of a conductive hearing loss. The remainder of his cranial nerve examination was normal, with the exception of the long-standing House-Brackmann Grade VI/VI right facial nerve paralysis. Audiogram demonstrated a right moderate conductive hearing loss with flat (Type B) tympanogram. The left side was normal.

The patient had a right parotid pleomorphic adenoma 35 years ago, which was treated by enucleation. He presented

with several subcutaneous nodules 7 years after the initial treatment, which were treated by total parotidectomy. During surgery the facial nerve was sacrificed due to tumor encasement. Pathology confirmed recurrent pleomorphic adenoma. Postoperatively the tumor bed was treated with external beam radiotherapy. After this he remained asymptomatic for nearly 30 years.

Magnetic resonance imaging of the head confirmed a large, irregular, heterogeneous, and variably enhancing mass in the right mastoid with extension medially along the floor of the posterior fossa measuring $\sim 5 \times 5 \times 5$ cm (▶ **Fig. 1**). The mass eroded through the mastoid laterally and inferiorly into the upper cervical soft tissues. The superior portions of the mastoid were opacified with enhancement, suggesting tumor infiltration. The mass extended inferiorly into the parapharyngeal space and extrinsically compressed the right sigmoid sinus displacing it medially. In addition, a 1×1 cm enhancing nodule in the right cerebellum medial to the cystic lesion was observed. The differential diagnosis at this point included carcinoma ex

*This article was originally published in *Skull Base Reports* on November 21, 2011 (DOI: 10.1055/s-0031-1296032)

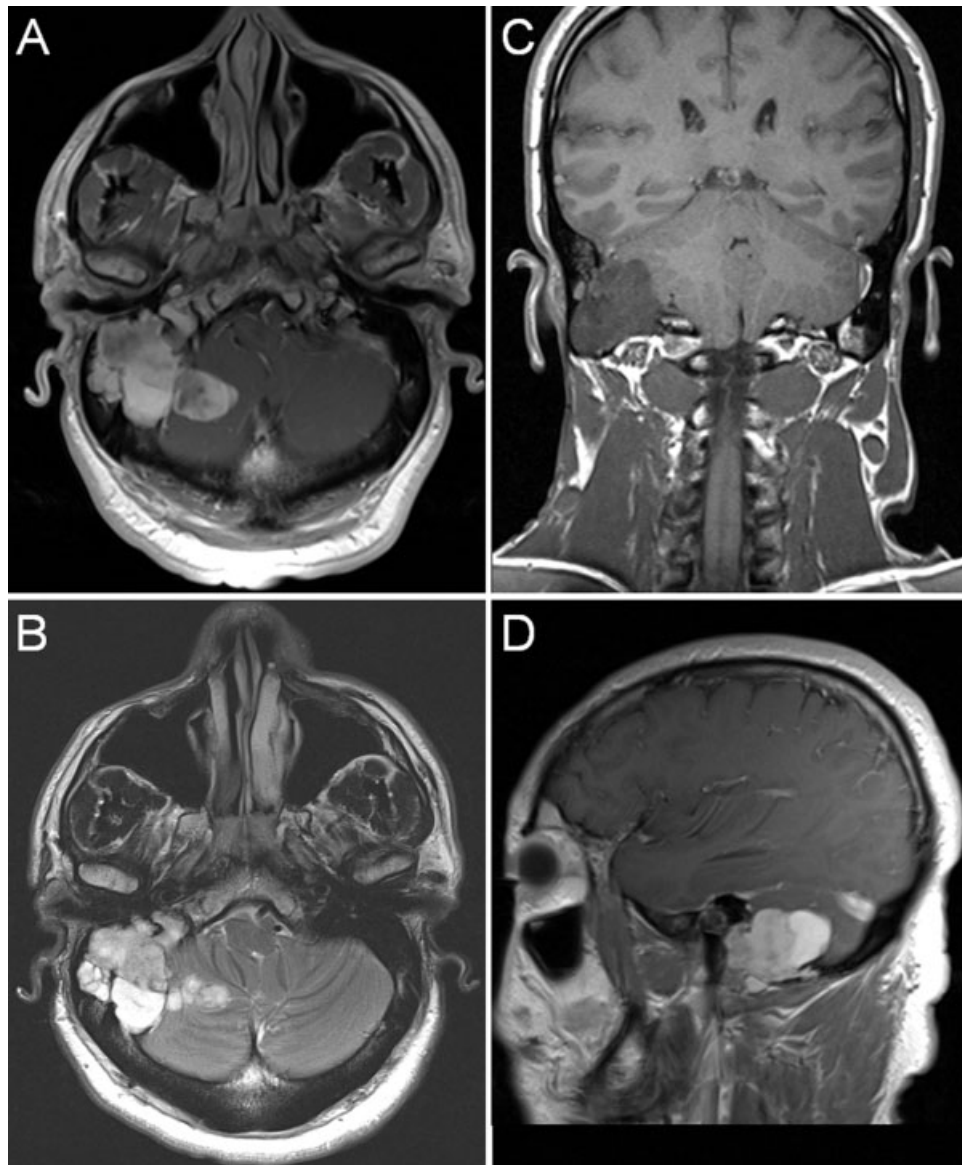


Figure 1 Preoperative magnetic resonance imaging. (A) Axial T1, (B) axial T2, (C) coronal T1, and (D) sagittal T1-weighted images reveal a variably enhancing mass in the right mastoid air cells extending medially along the floor of the posterior fossa, extending inferiorly into the parotid bed and medially into the cerebellum.

pleomorphic adenoma, postradiation sarcoma, another parotid gland carcinoma, and recurrent pleomorphic adenoma.

The patient was taken to the operating room for trans-temporal resection. Upon entering the mastoid, tumor was noted completely infiltrating the mastoid cavity. It eroded through the dura of the posterior fossa medial to the sigmoid sinus and into the cerebellum. The tumor had also eroded into the fallopian canal, requiring debridement and transection of the grossly involved facial nerve. The mass infiltrated the posterior semicircular canal and the aditus ad antrum; however, the middle ear space and facial recess were free of tumor. After tumor had been removed from these areas, the overlying dura was resected. Once proximal and distal venous control was achieved, the sigmoid and transverse sinuses (both involved by tumor) were resected inferior to the vein of

Labbé. Finally, the remaining tumor was removed from the jugular foramen, lateral infratemporal fossa skull base, and the superior parapharyngeal region.

Throughout the procedure, multiple specimens were collected for intraoperative frozen sections. All specimens were interpreted as consistent with benign mixed tumor (pleomorphic adenoma). The remainder of the specimen was examined following standard histological processing and staining with hematoxylin and eosin. Upon final review, the intraoperative diagnoses were corroborated. Although there was evidence of destruction of the mastoid and involvement of the facial nerve, the growth pattern of the tumor was lobulated and expansile rather than directly infiltrative (►Fig. 2). The tumor showed areas of cellularity without mitoses or cellular atypia as well as areas of abundant

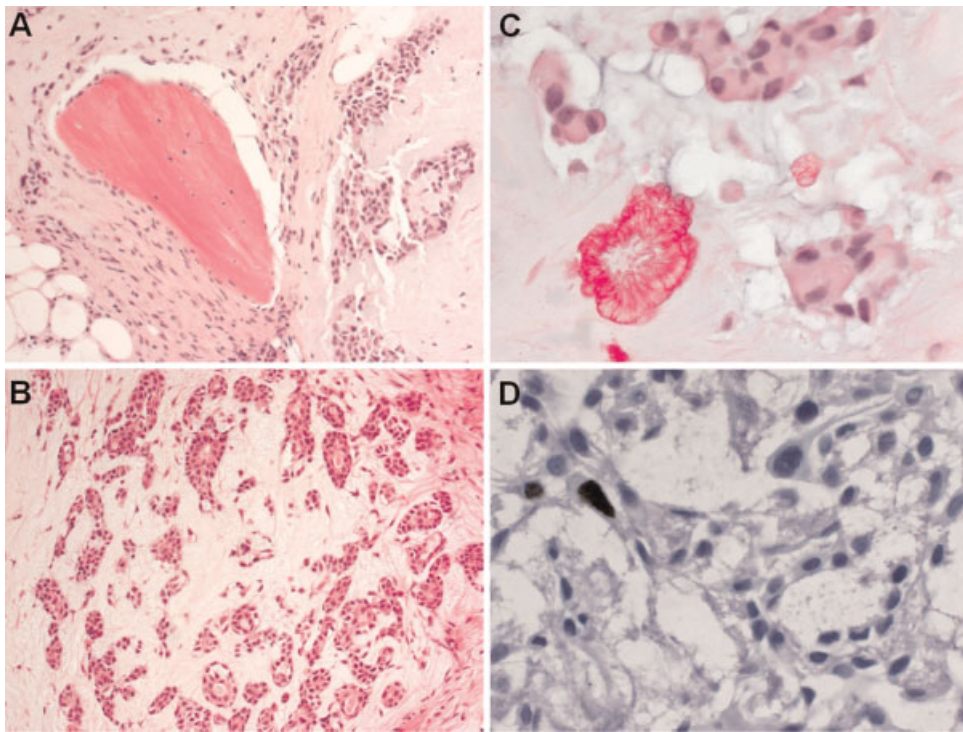


Figure 2 Histological features of recurrent mixed tumor. (A) Expansile growth of tumor extending into the mastoid causing local destruction, H&E, low magnification. (B) Cellular area of the tumor showing well-formed tubules in a chondromyxoid matrix, H&E, low magnification. (C) Paucicellular region of the tumor with abundant chondromyxoid matrix and tyrosine crystal, H&E, high magnification. (D) Ki-67 immunohistochemistry showing rare positive cell denoting a low proliferation rate.

chondromyxoid matrix. There were numerous foci of squamous metaplasia and tyrosine crystals were readily identified. There was no indication of malignant transformation of either the epithelial or mesenchymal components. Immunohistochemistry performed on the most cellular areas demonstrated a low proliferation rate (< 2%) and diffuse but weak staining with p53. Taken together, these findings excluded the possibility of a malignancy such as carcinoma ex pleomorphic adenoma, and were highly suggestive of an aggressive recurrence of an otherwise histologically benign pleomorphic adenoma.

Postoperatively the patient did well and was discharged on postoperative day 3. He immediately noted improvement in his hearing, though did have a transient vocal fold paresis which is currently resolving.

Discussion

Pleomorphic adenoma, also known as benign mixed tumor, is the most common tumor affecting the parotid gland, but can occur in any major or minor salivary gland as well as extra-salivary tissue.¹⁻⁴ Pleomorphic adenoma is most common in middle age and in women,⁵ and although rare in children, it remains the most common solid parotid mass in the pediatric population.⁶⁻⁹ These tumors arise directly from salivary gland tissue and consist of epithelial and mesenchymal cells; the latter can give rise to osseous, cartilaginous, hyaline, and myxoid elements, hence the name “mixed tumor.” Surgical resection is the treatment of choice for pleomorphic adenoma

due to possible malignant transformation (to carcinoma ex pleomorphic adenoma) and its potential to reach massive size, causing significant morbidity and cosmetic deformity. The invasion of bony structures is rare.¹⁰ In this study, we identify a unique pattern of intracranial invasion of a recurrent pleomorphic adenoma, as there does not exist anywhere in the literature a case reported with such extensive intracranial spread of this benign tumor.

Recurrence of pleomorphic adenoma after excision is a well-known phenomenon and can present decades after resection of the primary tumor.¹¹ The incidence of recurrent pleomorphic adenoma has been reported as high as 17%, depending on the surgical technique used in the primary excision.¹² Pleomorphic adenomas are not all truly encapsulated; rather some possess “pseudopodia” that vary in thickness and extend from the tumor surface, contributing to postoperative recurrence.¹³

Initially believed to be primarily due to tumor spillage during excision, recurrence may also be due to unique histological and genetic characteristics.¹² Additionally, the presence of microscopic satellite tumors left behind after resection has been reported to contribute to pleomorphic adenoma recurrence.¹³ More recently there has been an interest in determining the expression profile of various tumor marker genes to determine if particular expression patterns exist between pleomorphic adenomas and their malignant counterparts. Several studies have demonstrated that carcinoma ex pleomorphic adenoma has a higher proliferative index, as determined by the expression of the

proliferation marker K_i-67, as well as accumulation of dysfunctional p53, than benign pleomorphic adenomas.^{14–17} However, very few studies have examined the genetic differences between nonrecurrent and recurrent pleomorphic adenomas. Stennert and colleagues studied the expression of the proliferative marker K_i-67 in both myxoid and cellular types of recurrent pleomorphic adenomas and found a higher proliferative index in the more aggressive, cellular type recurrences.¹⁸ Hamada and colleagues compared the expression patterns between nonrecurrent and recurrent pleomorphic adenomas for glycosylated phosphoprotein mucin 1 (MUC1), which is upregulated in various cancers,¹⁹ and found that high expression of MUC1 was a significant risk factor in developing recurrence.²⁰ In our study the tumor showed a low proliferation (K_i-67) rate (<2%) with positive p53. Positive p53 immunohistochemistry has been identified not only in malignant salivary gland tumors but also in tumors showing classic pleomorphic adenoma histology, cellular pleomorphic adenomas, and recurrent pleomorphic adenomas.^{21–23} More significant is the utility of the nuclear antigen K_i-67 as a predictor of tumor behavior, in malignant tumors a high proliferation rate is suggestive of more aggressive behavior.²⁴ The low proliferation rate in addition to classic pleomorphic adenoma histology with no evidence of malignant transformation of either cellular or stromal components definitively placed this tumor into the category of a recurrent pleomorphic adenoma. Clearly, more prospective investigations are needed to determine if immunohistochemical profiling can reliably predict recurrence. While several characteristics appear to individually contribute to recurrent disease, it is the combination of surgical technique, histology, and genetics that conveys the true risk.

Conclusion

We present a unique case of massive transcranial invasion of a recurrent benign mixed tumor arising from the parotid. In the vast majority of cases reported of recurrent pleomorphic adenoma, the recurrent tumor is confined to the site of the primary tumor with some extension into surrounding tissue. While bone changes and destruction have been reported,^{10,25} we believe this case represents the most massive and destructive recurrent pleomorphic adenoma in the literature, and illustrates the point that recurrent pleomorphic adenoma must be within the differential diagnosis of any patient presenting with a malignant appearing intracranial lesion and a remote history of pleomorphic adenoma resection.

References

- Lingam RK, Dagher AA, Nigar E, Abbas SA, Kumar M. Pleomorphic adenoma (benign mixed tumour) of the salivary glands: its diverse clinical, radiological, and histopathological presentation. *Br J Oral Maxillofac Surg* 2011;49(1):14–20
- O'Brien CJ. Current management of benign parotid tumors—the role of limited superficial parotidectomy. *Head Neck* 2003;25(11):946–952
- Piekarski J, Nejc D, Szymczak W, Wronski K, Jezierski A. Results of extracapsular dissection of pleomorphic adenoma of parotid gland. *J Oral Maxillofac Surg* 2004;62(10):1198–1202
- Subhashraj K. Salivary gland tumors: a single institution experience in India. *Br J Oral Maxillofac Surg* 2008;46(8):635–638
- Laccourreye H, Laccourreye O, Cauchois R, Jouffre V, Ménard M, Brasnu D. Total conservative parotidectomy for primary benign pleomorphic adenoma of the parotid gland: a 25-year experience with 229 patients. *Laryngoscope* 1994;104(12):1487–1494
- Witt RL. The significance of the margin in parotid surgery for pleomorphic adenoma. *Laryngoscope* 2002;112(12):2141–2154
- Bentz BG, Hughes CA, Lüdemann JP, Maddalozzo J. Masses of the salivary gland region in children. *Arch Otolaryngol Head Neck Surg* 2000;126(12):1435–1439
- Luna MA, Batsakis JG, el-Naggar AK. Salivary gland tumors in children. *Ann Otol Rhinol Laryngol* 1991;100(10):869–871
- Linares CZ. Mixed tumor of parotid in childhood. *Int J Pediatr Otorhinolaryngol* 1991;22(3):269–273
- Yasumoto M, Sunaba K, Shibuya H, Kurabayashi T. Recurrent pleomorphic adenoma of the head and neck. *Neuroradiology* 1999;41(4):300–304
- Koral K, Sayre J, Bhuta S, Abemayor E, Lufkin R. Recurrent pleomorphic adenoma of the parotid gland in pediatric and adult patients: value of multiple lesions as a diagnostic indicator. *AJR Am J Roentgenol* 2003;180(4):1171–1174
- Suh MW, Hah JH, Kwon SK, et al. Clinical manifestations of recurrent parotid pleomorphic adenoma. *Clin Exp Otorhinolaryngol* 2009;2(4):193–197
- Orita Y, Hamaya K, Miki K, et al. Satellite tumors surrounding primary pleomorphic adenomas of the parotid gland. *Eur Arch Otorhinolaryngol* 2010;267(5):801–806
- Azuma M, Kasai Y, Tamatani T, Sato M. Involvement of p53 mutation in the development of human salivary gland pleomorphic adenomas. *Cancer Lett* 1992;65(1):61–71
- Li X, Tsuji T, Wen S, Mimura Y, Sasaki K, Shinozaki F. Detection of numeric abnormalities of chromosome 17 and p53 deletions by fluorescence in situ hybridization in pleomorphic adenomas and carcinomas in pleomorphic adenoma. *Correlation with p53 expression. Cancer* 1997;79(12):2314–2319
- Tashiro T, Hirokawa M, Harada H, Yokoyama S, Sano T. Cell membrane expression of MIB-1 in salivary gland pleomorphic adenoma. *Histopathology* 2002;41(6):559–561
- Lazzaro B, Cleveland D. P53 and Ki-67 antigen expression in small oral biopsy specimens of salivary gland tumors. *Oral Surg Oral Med Oral Pathol Oral Radiol Endod* 2000;89(5):613–617
- Stennert E, Wittekindt C, Klussmann JP, Arnold G, Guntinas-Lichius O. Recurrent pleomorphic adenoma of the parotid gland: a prospective histopathological and immunohistochemical study. *Laryngoscope* 2004;114(1):158–163
- Hu XF, Yang E, Li J, Xing PX. MUC1 cytoplasmic tail: a potential therapeutic target for ovarian carcinoma. *Expert Rev Anticancer Ther* 2006;6(8):1261–1271
- Hamada T, Matsukita S, Goto M, et al. Mucin expression in pleomorphic adenoma of salivary gland: a potential role for MUC1 as a marker to predict recurrence. *J Clin Pathol* 2004;57(8):813–821
- DeRoche TC, Hoschar AP, Hunt JL. Immunohistochemical evaluation of androgen receptor, HER-2/neu, and p53 in benign pleomorphic adenomas. *Arch Pathol Lab Med* 2008;132(12):1907–1911
- Al-Rawi NH, Omer H, Al Kawas S. Immunohistochemical analysis of P(53) and bcl-2 in benign and malignant salivary glands tumors. *J Oral Pathol Med* 2010;39(1):48–55
- Gedlicka C, Item CB, Wögerbauer M, et al. Transformation of pleomorphic adenoma to carcinoma ex pleomorphic adenoma of the parotid gland is independent of p53 mutations. *J Surg Oncol* 2010;101(2):127–130

- 24 Luukka H, Klemi P, Leivo I, Vahlberg T, Grénman R. Prognostic significance of Ki-67 and p53 as tumor markers in salivary gland malignancies in Finland: an evaluation of 212 cases. *Acta Oncol* 2006;45(6):669–675
- 25 Kamida T, Abe T, Inoue R, Kobayashi H, Suzuki M, Matsumoto A. Stereotactic radiosurgery for recurrent pleomorphic adenoma invading the skull base—case report—. *Neurol Med Chir (Tokyo)* 2005;45(3):161–163