

Knee Meniscus Posterior Root Repair with FiberTak



Carlos Mesquita Queirós, M.D., Tiago Amorim-Barbosa, M.D., Helder Fonte, M.D., and Alcindo Silva, M.D.

Abstract: Repair of medial meniscal root tear is nowadays a validated procedure in order to restore knee biomechanics and to prevent early development of arthritis. There are various techniques described, without any being considered superior. This article describes a technique with a knotless suture anchor design, using a high posteromedial portal to insert the anchor and a meniscal suture passer device from the anteromedial portal. The technique eliminates the need for transtibial drilling and knot tying, and it certifies a strong reproducible tension.

Introduction

Medial Meniscal Posterior Root (MMPR) integrity is essential to maintain hoop stress, load sharing, and shock absorption in a native knee.¹ A posterior medial root tear will lead to extrusion and altered biomechanics, causing early degenerative arthritis, which can be comparable to that of a complete meniscectomy.²

Most of the repair techniques can be achieved by fixation with transtibial drilling or by direct fixation with suture anchor. Transtibial drilling, pull-out sutures, and extracortical or screw fixation are more prone to abrasion of the suture and elongation of the construct and they use a long lever arm.³ However, they are technically less demanding, as the new meniscal suture passers with appropriate size allow meniscal perforation with minimal tissue damage and reliable suture management. Regarding the suture anchor, it provides a short construction, with strong fixation,⁴ but it introduces new challenges in suture passing and suture management, as well as handling posterior compartment portals.

Which technique is superior at achieving proper meniscal healing is not fully known, as both techniques

have been shown to have good results in diminishing extrusion, improving pain and preventing the development of early arthritis.^{5,6}

A technique of MMPR repair is described using the FiberTak Soft Anchors (Arthrex, Naples, FL), a meniscal suture passer device, accomplishing fixation without transtibial drilling, simplifying the suture management, deprived of knot tying and with reproducible controlled tensioning.

Surgical Technique

Indications for this surgery follow the same indication for other meniscal root repair techniques, regarding cartilage lesions and lower limb general alignment.

The technique can be used to treat medial or lateral meniscal root avulsions and full-thickness radial tears adjacent to the meniscal root attachment. A Knotless FiberTak Soft Anchor, and a meniscal suture passer—in this video Scorpion (Arthrex)—is used. We describe the technique for medial root repair (Video 1).

The patient is positioned supine, a tourniquet is applied, and support for the foot is provided to maintain 90° of flexion. The operative extremity is prepared and draped in the usual fashion for routine knee arthroscopy.

A high anterolateral parapatellar portal is used for visualization. A spine needle is used to make a low anteromedial portal just above the anterior one-third of the medial meniscus, to avoid the anterior tibial spine when managing the meniscal suture passer. After confirmation of the root tear, to improve not only visualization but also to avoid cartilage damage when managing sutures, the medial collateral ligament is lengthened, by percutaneous partial outside-in using the “magic point,” according to Banacha Chernchujit.⁷

Centro Hospitalar Entre Douro e Vouga, Vila Nova de Gaia, Portugal (C.M.Q.); Hospital de Sto. António, Porto, Portugal (T.A.-B., H.F.); and Praceta de Henrique Moreira Vila Nova de Gaia, Portugal (A.S.).

Received September 29, 2021; accepted November 16, 2021.

Address correspondence to Carlos Mesquita Queirós, M.D., Centro Hospitalar Entre Douro e Vouga, Alameda Jardins D'Arrabida, 438, 90B 4400-438, Vila Nova de Gaia, Portugal. E-mail: cmesquitaqueiros@gmail.com

© 2022 THE AUTHORS. Published by Elsevier Inc. on behalf of the Arthroscopy Association of North America. This is an open access article under the CC BY-NC-ND license (<http://creativecommons.org/licenses/by-nc-nd/4.0/>).

2212-6287/211393

<https://doi.org/10.1016/j.eats.2021.11.020>

A 3.5-mm shaver is used to debride the meniscal lesion, and it should confirm meniscal reducibility to the root footprint. A curette is used to remove the cartilage of the footprint.

Then the arthroscope is passed to the posteromedial compartment below the PCL—Gillquist maneuver—and the knee is placed at a 90° angle. With the help of a spinal needle, a high posteromedial portal is made. This portal allows proper placement of the 1.6 knotless FiberTak soft anchors. A curved guide is placed in the exposed bone and drilled with a 2.6-mm drill (Fig 1). The anchor is hammered and gently pulled back to achieve correct fixation. Each anchor comes preloaded with a white/blue #2 Coreless FiberWire suture and a shuttle suture (black and white, one half with a 2-0 FiberWire with end loop with the other half a .9-mm SutureTape).

Next, the white and blue suture is retrieved through the anteromedial portal, loaded into the meniscal suture passer device (Scorpion Arthrex) and passed through to the most posterior point of the meniscal tissue (Fig 2). After retrieving the suture at the anteromedial portal, the same white and blue suture is reloaded into the meniscal Scorpion and passed through the anterior part of the meniscal root, but this time with the Scorpion upside down, passing the suture from the superior to the inferior surface, to perform a mattress suture (Fig 3). Next, the suture is retrieved from the anteromedial portal, and confirmation is made that the suture is correctly placed in the meniscal root.

Next, the looped end of the black suture shuttle is retrieved from the posteromedial portal through the anteromedial portal.

The suture splice-locking mechanism is created by inserting the white and blue repair suture into the loop of the black shuttling suture. The other end of the black shuttling suture is pulled from the posteromedial portal, shuttling the repair blue suture back into the anchor

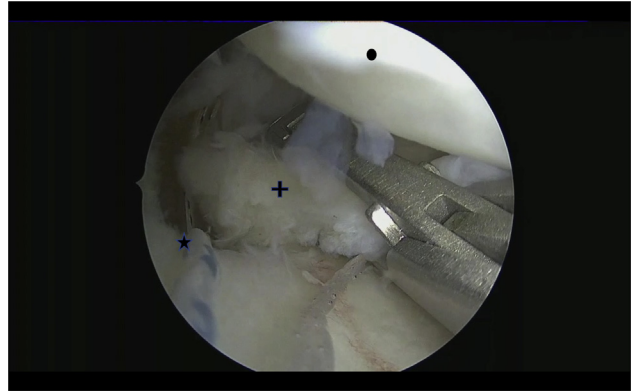


Fig 2. First suture passing in the posterior part of medial. View from anterolateral portal of the medial compartment. + denotes medial meniscus. • denotes posterior cruciate ligament. ★ denotes medial meniscal root footprint.

completing the splice. The repair suture can be controlled and tensioned under direct visualization until the desired reduction is achieved. As the tensioning mechanism is a mattress suture, the reduction can be accomplished with the help of a meniscal grabber (Fig 4). The suture cutter has a small profile leaving a flush knotless repair. Correct reduction and tension are confirmed with a probe.

After surgery, the patient underwent a routine post-operative protocol. No weight bearing was allowed, without a knee immobilizer for the first 6 weeks. Active motion exercises were encouraged from 0° to 120° of flexion. After 6 weeks, full weight bearing was permitted. Full flexion and squatting were allowed after 3 months.

Discussion

The most widely accepted transtibial repair of medial meniscal root tear provides a reproducible technique with good clinical results, as shown by LaPrade.⁸

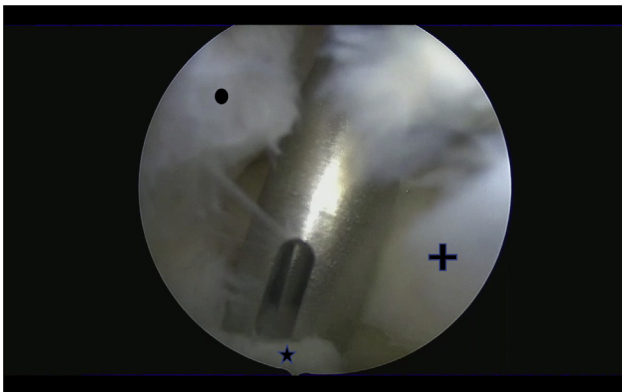


Fig 1. Anchor placement with curved guide. Posterior medial compartment view. The anchor guide through the posteromedial portal allows easy access to meniscal root footprint. + denotes medial meniscus. • denotes posterior cruciate ligament. ★ denotes medial meniscal root footprint.

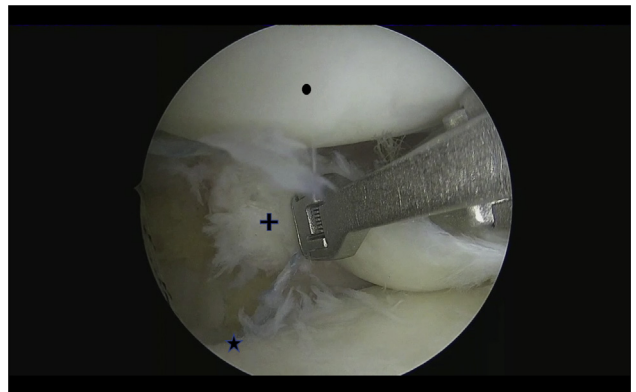


Fig 3. Second suture passing in the anterior part of the meniscal root. View from anterolateral portal of the medial compartment. The meniscal suture passer is shown upside down. + denotes medial meniscus. • denotes posterior cruciate ligament. ★ denotes medial meniscal root footprint.

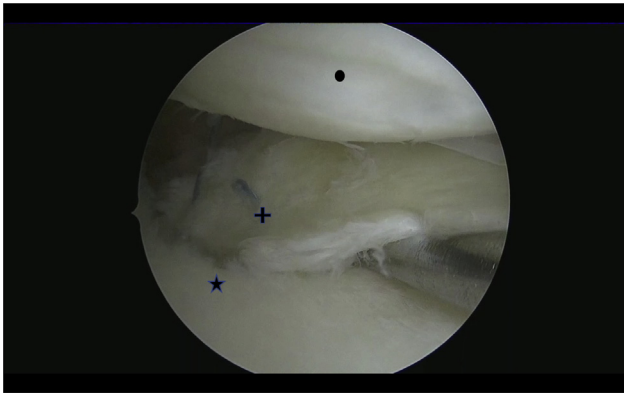


Fig 4. Medial meniscal root repaired. View from anterolateral portal of the medial compartment. Confirmation of stable fixation of the root. Medial Condyle + denotes medial meniscus. • denotes posterior cruciate ligament. ★ denotes medial meniscal root footprint.

However, some studies have reported less satisfactory results after transosseous meniscal root repair, due to meniscal extrusion^{4,9} and nonhealing of meniscal tissue on second-look arthroscopic surgery.^{10,11} Fortunately, many of these patients showed clinical improvement, despite findings of incomplete or failed healing on second-look arthroscopy.⁷

Displacement of the root (up to 3.8 mm after cyclic loading) has been pointed out as the cause of these failures.¹² There is believed to be a “bungee effect,” in which the suture elongation or longitudinal motion of the sutures within the transtibial tunnel results in the displacement of the repaired meniscal root. Also, up to .9 mm of meniscal displacement was demonstrated in tibial fixation with buttons.¹³ Considering the length of the construct, fixation with extracortical buttons or screws and pullout sutures to achieve controlled tension and stable fixation can be challenging.¹⁴

Our all-inside technique uses a suture anchor, which has better biomechanical profile (mimicking the native tension of the tissues),^{4,15} and avoids distal tibial bone tunnels that could interfere with concomitant ligament reconstruction (Table 1). Issues related to distal tibial fixation, such as elongation and abrasion of sutures, can be dismissed, excluding the possibility of the “bungee effect”. Also, the knotless mechanism provides a lower

Table 1. Advantages and Disadvantages

Advantages	Disadvantages
Lower lever arm compared to transtibial techniques	Posteromedial portal
Knotless repair	Managing the Scorpion upside down
No need of specific guide or instrumentation	
Firm fixation	
Without tunnel	

Table 2. Pearls and Pitfalls

Pearls	Pitfall	Solutions
MCL lengthening	Reduction the FiberTak anchor	Gentle traction until reduction
Low anteromedial portal	Meniscal suture passer fails to pass suture	Consider using an extra suture to shuttle the anchor suture
High and posterior posteromedial portal	Passing the second time with the Scorpion upside-down	Pass a shuttling suture in a normal fashion
Gentle meniscal root reduction	Tensioning the root	Place the root in place before tensioning

MCL, medial collateral ligament.

rate of suture slippage (loss of loop security),¹⁶ and more reproducible tension.

As nonanatomic placement of the meniscal root by only 3 mm significantly compromises meniscal function,¹⁷ the curved guide introduced from the posteromedial portal allows easy and correct placement on the footprint without the need to rely on a transosseous guide. Furthermore, the posteromedial portal skin incision is far less invasive.

While using the Scorpion upside-down might be challenging, the lengthening of the medial collateral ligament provides enough joint space to avoid cartilage damage. Also, when tensioning the suture mechanism, the meniscal root should be already reduced to prevent secondary rupture of the already fragile tissue (Table 2).

The main limitation to this technique resides in the tibial bone quality, as the suture anchor needs to expand to achieve proper fixation, when dealing with osteoporotic bone, the anchor can fail proper fixation. Also, if dealing with a meniscal radial tear near the root, another type of fixation should be chosen, or a more medial root footprint should be drilled.

This technique provides a stable, surgeon-friendly technique, without the concerns related to fixation. Future studies should compare the biomechanical properties between suture anchor repair and the different techniques of transosseous repair.

References

- Bhatia S, LaPrade CM, Ellman MB, LaPrade RF. Meniscal root tears: Significance, diagnosis, and treatment. *Am J Sports Med* 2014;42:3016-3030.
- Bernard CD, Kennedy NI, Tagliero AJ, et al. Medial meniscus posterior root tear treatment: A matched cohort comparison of nonoperative management, partial meniscectomy, and repair. *Am J Sports Med* 2020;48:128-132.
- Moon HK, Koh YG, Kim YC, Park YS, Jo SB, Kwon SK. Prognostic factors of arthroscopic pull-out repair for a posterior root tear of the medial meniscus. *Am J Sports Med* 2012;40:1138-1143.

4. Feucht MJ, Grande E, Brunhuber J, et al. Biomechanical comparison between suture anchor and transtibial pull-out repair for posterior medial meniscus root tears. *Am J Sports Med* 2014;42:187-193.
5. Chung KS, Ha JK, Ra HJ, Kim JG. A meta-analysis of clinical and radiographic outcomes of posterior horn medial meniscus root repairs. *Knee Surg Sports Traumatol Arthrosc* 2016;24:1455-1468. <https://doi.org/10.1007/s00167-015-3832-0>.
6. Jung YH, Choi NH, Oh JS, Victoroff BN. All-inside repair for a root tear of the medial meniscus using a suture anchor. *Am J Sports Med* 2012;40:1406-1417.
7. Chernchujit B, Gajbhiye K, Wanaprasert N, Artha A. Percutaneous partial outside-in release of medial collateral ligament for arthroscopic medial meniscus surgery with tight medial compartment by finding a "magic point". *Arthrosc Tech* 2020;9:e935-e940.
8. LaPrade RF, Matheny LM, Moulton SG, James EW, Dean CS. Posterior meniscal root repairs: Outcomes of an anatomic transtibial pull-out technique. *Am J Sports Med* 2016;45:884-891.
9. Feucht MJ, Kühle J, Bode G, et al. Arthroscopic transtibial pullout repair for posterior medial meniscus root tears: A systematic review of clinical, radiographic, and second-look arthroscopic results. *Arthroscopy* 2015;31:1808-1816.
10. Seo HS, Lee SC, Jung KA. Second-look arthroscopic findings after repairs of posterior root tears of the medial meniscus. *Am J Sports Med* 2011;39:99-107.
11. Lee SS, Ahn JH, Kim JH, Kyung BS, Wang JH. Evaluation of healing after medial meniscal root repair using second-look arthroscopy, clinical, and radiological criteria. *Am J Sports Med* 2018;46:2661-2668.
12. Röpke EF, Kopf S, Drange S, Becker R, Lohmann CH, Stärke C. Biomechanical evaluation of meniscal root repair: a porcine study. *Knee Surg Sports Traumatol Arthrosc* 2015;23:45-50.
13. Cerminara AJ, LaPrade CM, Smith SD, Ellman MB, Wijdicks CA, LaPrade RF. Biomechanical evaluation of a transtibial pull-out meniscal root repair: Challenging the bungee effect. *Am J Sports Med* 2014;42:2988-2995.
14. Feucht MJ, Grande E, Brunhuber J, Burgkart R, Imhoff AB, Braun S. Biomechanical evaluation of different suture techniques for arthroscopic transtibial pull-out repair of posterior medial meniscus root tears. *Am J Sports Med* 2013;41:2784-2790.
15. Dzidzishvili L, Lopez-Torres II, Saez D, Arguello JM, Calvo E. A comparison of the transtibial pullout technique and all-inside meniscal repair in medial meniscus posterior root tear: Prognostic factors and midterm clinical outcomes. *J Orthop* 2021;26:130-134. <https://doi.org/10.1016/j.jor.2021.08.001>.
16. Lee SK, Yang BS, Park BM, Yeom JU, Kim JH, Yu JS. Medial meniscal root repair using curved guide and soft suture anchor. *Clin Orthop Surg* 2018;10:111-115.
17. Kamatsuki Y, Furumatsu T, Hiranaka T, et al. Accurate placement of a tibial tunnel significantly improves meniscal healing and clinical outcomes at 1 year after medial meniscus posterior root repair. *Knee Surg Sports Traumatol Arthrosc* 2021;29:3715-3723. <https://doi.org/10.1007/s00167-020-06376-9>.