

Received: 2022.02.03

Accepted: 2022.03.10

Available online: 2022.03.21

Published: 2022.04.24

# Successful Conservative Treatment of an Acute Arterial Occlusion After Total Knee Arthroplasty: Report of 2 Cases and Review of the Literature

## Authors' Contribution:

Study Design A  
Data Collection B  
Statistical Analysis C  
Data Interpretation D  
Manuscript Preparation E  
Literature Search F  
Funds Collection G

BEF 1 **Kemmei Ikuta**  
ABCDE 1 **Tomoyuki Matsumoto**  
B 2 **Koji Takayama**  
B 1 **Naoki Nakano**  
B 1 **Yoshinori Takashima**  
BE 1 **Hiroki Ohnishi**  
B 1 **Shinya Hayashi**  
B 1 **Yuichi Kuroda**  
E 1 **Ryosuke Kuroda**

1 Department of Orthopedic Surgery, Kobe University Graduate School of Medicine, Kobe, Hyogo, Japan

2 Department of Orthopedic Surgery, Anshin Hospital, Kobe, Hyogo, Japan

**Corresponding Author:** Tomoyuki Matsumoto, e-mail: [mastun@m4.dion.ne.jp](mailto:mastun@m4.dion.ne.jp)

**Financial support:** None declared

**Conflict of interest:** None declared

## Case series

**Patients:** Female, 68-year-old • Female, 79-year-old

**Final Diagnosis:** Popliteal artery occlusion

**Symptoms:** 68-years-old woman presented a weak dorsalis pedis pulse in the foot and weakness to dorsiflexion of the toe at an operative side immediately after TKA • 79-years-old woman presented a cold right foot and lack of popliteal and dorsalis pedis pulse in the operative extremity immediately after TKA

**Medication:** —

**Clinical Procedure:** Conservative management

**Specialty:** Orthopedics and Traumatology

**Objective:** Challenging differential diagnosis

**Background:** Acute arterial occlusion after total knee arthroplasty (TKA) is a rare but occasionally limb-threatening complication. Successful outcomes of surgical treatment for acute arterial occlusion after TKA have been frequently reported in the literature; however, few reports have described conservative treatment. This case report describes the successful conservative treatment of popliteal artery occlusion after TKA.

**Case Report:** We report 2 cases of popliteal artery occlusion after TKA that were managed with conservative treatment. In Case 1, a 68-year-old woman presented with a weak dorsalis pedis pulse in the foot and weakness to dorsiflexion of the toe on the operative side immediately after TKA. The operative lower extremity arterial ultrasonography and computed tomography angiography demonstrated the popliteal artery occlusion. In Case 2, a 79-year-old woman presented a cold right foot and lack of popliteal and dorsalis pedis pulse in the operated extremity immediately after TKA, and Doppler ultrasound did not reveal a flow for the dorsalis pedis artery. In both patients, urgent angiographies showed popliteal artery occlusion, and blood flow was observable in the anterior tibial, peroneal, and foot arteries collateral perfusion. Thus, conservative treatments were chosen, and anticoagulant and vasodilator therapies were undergone in both patients. At 6 months after surgery, they were able to walk without intermittent claudication.

**Conclusions:** Conservative treatment can be a good option for popliteal artery occlusion after TKA in cases of rich collateral circulation.

**Keywords:** Arterial Occlusive Diseases • Arthroplasty, Replacement, Knee • Conservative Treatment


Full-text PDF: <https://www.amjcaserep.com/abstract/index/idArt/936295>



 2104

 —

 6

 23

## Background

As the general population ages, the number of people with knee osteoarthritis is increasing [1]. In addition, more patients of advanced age are choosing surgical treatment to improve their quality of life. Total knee arthroplasty (TKA) is the safest and most cost-effective procedure for restoring function to an arthritic knee joint [2]. However, various complications have been reported for TKA [3]. Once complications develop, their management is not necessarily easy. In particular, acute arterial occlusion is severe and leads to many sequelae: compromised wound healing, infection, and the worst scenario, amputation [4]. Although the incidence of arterial complications after TKA, including arterial occlusion, arteriovenous fistula, arterial aneurysm, and arterial severance, is rare, with a reported rate of 0.033% to 0.17% in large patient populations [5-7], we must take care to prevent serious complications and choose the appropriate treatment.

The appropriate treatment of arterial complications after TKA comprises conservative therapy and surgical intervention, although surgical intervention is chosen most often. Dua et al reported that most of these patients either received stent placement (44%) or peripheral bypass (30%) as the treatment modality for popliteal artery injury, and 96% of this group had a successful procedure with recovered distal blood flow, while 1 patient had a peripheral bypass complication that required a redo-bypass and another patient had a patch angioplasty and required an embolectomy. However, there were no amputations or deaths in this cohort. Moreover, iatrogenic popliteal artery injury after TKA was a very rare occurrence, with a reported rate of 0.003% [8]. Hence, few studies have reported the results of conservative treatments for popliteal artery injury [9]. Herein, we report 2 cases of successful conservative treatment for acute popliteal artery occlusion after TKA.

## Case Report

### Case 1

The patient was a 68-year-old woman who had right knee pain due to osteoarthritis. A striking feature of the patient was high adiposity, with a body mass index (BMI) of 31.9 kg/m<sup>2</sup>. She did not have a medical history of coronary risk factors. Preoperative physical examination of the right knee revealed a limited range of motion (ROM) of -40° to 80°. Preoperative radiographs showed severe varus deformity, with a femorotibial angle of 210° (Figure 1). After conservative therapies had failed to improve her function, a right primary TKA (Persona CPS, Zimmer, Warsaw, Indiana, USA) was performed at a previous hospital (Figure 2). When a proximal tibial osteotomy was performed using a bone cutting saw blade without a navigation/

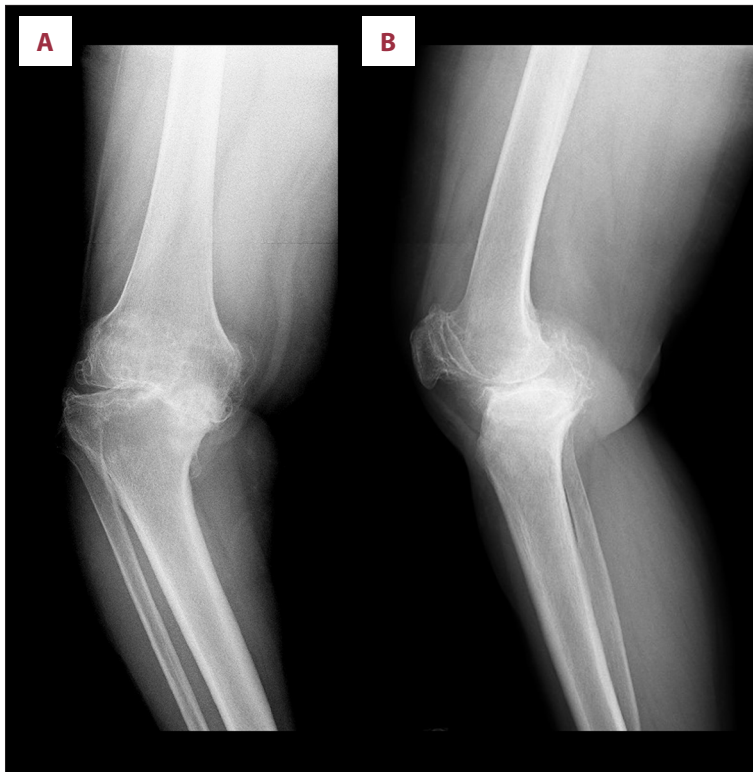
robotic system, the retractor was inserted into the posterior tibia to protect the posterior tissue. A tourniquet was inflated to 250 mmHg for a total of 95 min. Although a weak dorsalis pedis pulse in the right foot and weakness to dorsiflexion of the right toe were detected immediately after the surgery, the patient received watchful waiting since Doppler ultrasound revealed a flow for the dorsalis pedis artery and recovered toe dorsiflexion. On postoperative day 3, a lower extremity arterial ultrasonography and computed tomography angiography demonstrated the right popliteal artery occlusion. The patient was then referred to our hospital.

Urgent angiography was performed, which showed the right popliteal artery occlusion. Blood flow in the anterior tibial, peroneal, and dorsalis pedis arteries was observed, provided via collateral perfusion (Figure 3). After angiography, the dorsalis pedis and posterior tibial pulses were palpable, and the foot showed normal sensation and temperature. Hence, conservative treatment was chosen based on evidence of an adequate peripheral circulation and absence of symptoms. Of note, we were prepared to proceed to surgical treatment if symptoms of impaired circulation developed. The patient was treated with anticoagulant (Bayaspirin, 100 mg/day) and vasodilator (alprostadil, 10 µg, 2 times/day), with rehabilitation conducted according to the usual institutional protocol. At 6 months after surgery, the patient had a ROM of 0° to 100° and was able to walk without intermittent claudication.

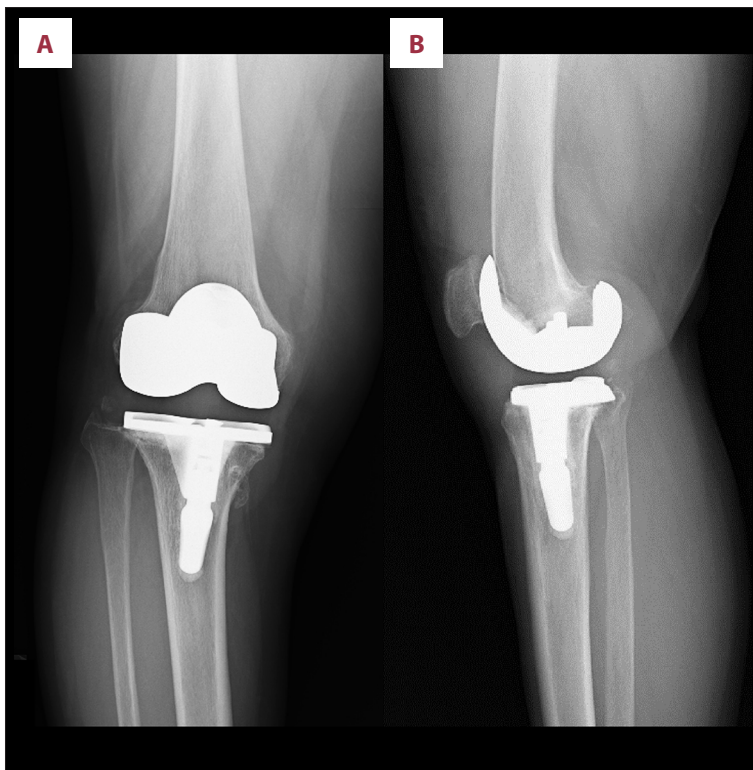
### Case 2

The patient was a 79-year-old woman who had right knee pain due to osteoarthritis. Her BMI was 24.2 kg/m<sup>2</sup>. She had a history of hypertension. Preoperative physical examination of the knee revealed a limited ROM of -30° to 95°. Preoperative radiographs showed severe varus deformity, with an femorotibial angle of 195° (Figure 4). After conservative therapies had failed to improve her function, a right primary TKA (Vanguard PS, Biomet, Warsaw, Indiana, USA) was performed at a previous hospital (Figure 5). When a proximal tibial osteotomy was performed using a bone cutting saw blade without a navigation/robotic system, the retractor was inserted into the posterior tibia to protect the posterior tissue. A tourniquet was inflated to 250 mmHg for a total of 74 min. Immediately after the surgery, a cold right foot and lack of popliteal and dorsalis pedis pulse in the operated extremity were detected. Doppler ultrasound did not reveal a flow for the dorsalis pedis artery, and the patient was then suspected of having acute arterial occlusions after TKA and was referred to our hospital.

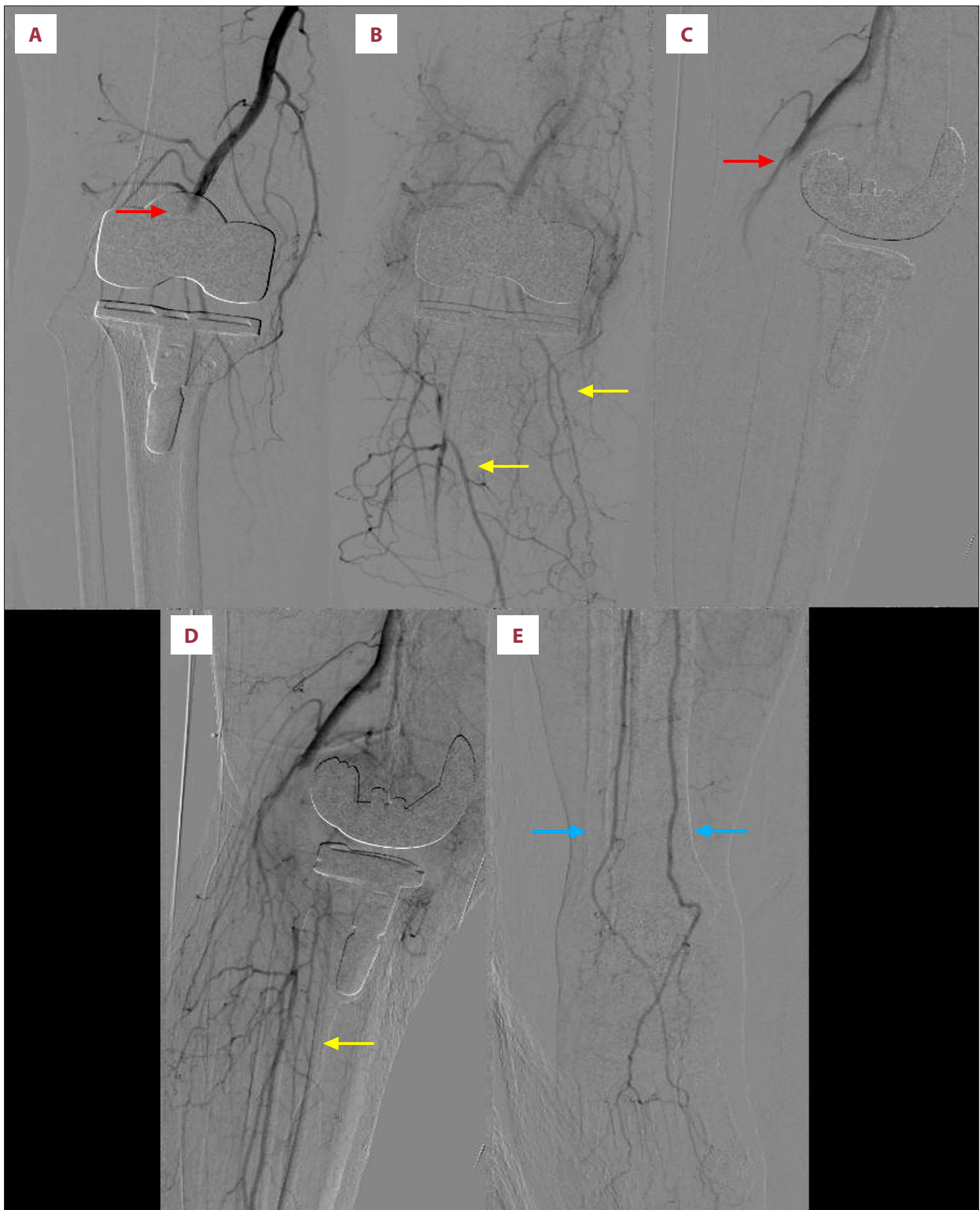
Urgent angiography was performed, showing the right popliteal artery occlusion. Blood flow was observable in the anterior tibial, peroneal, and medial plantar arteries via collateral perfusion (Figure 6). After angiography, syncope occurred via a



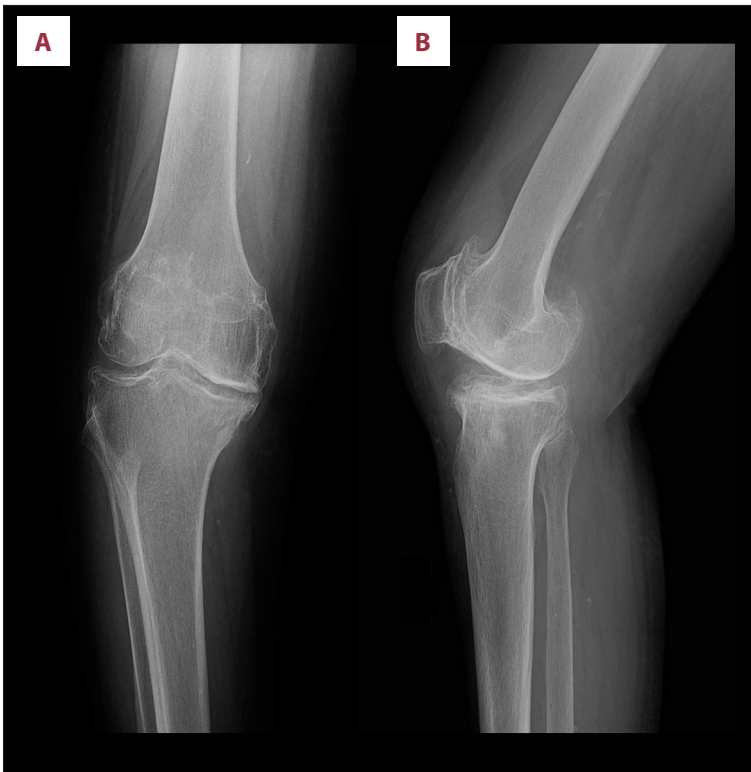**Figure 1.** Preoperative radiograph of the right knee (Case 1), anteroposterior (A) and lateral (B) views.



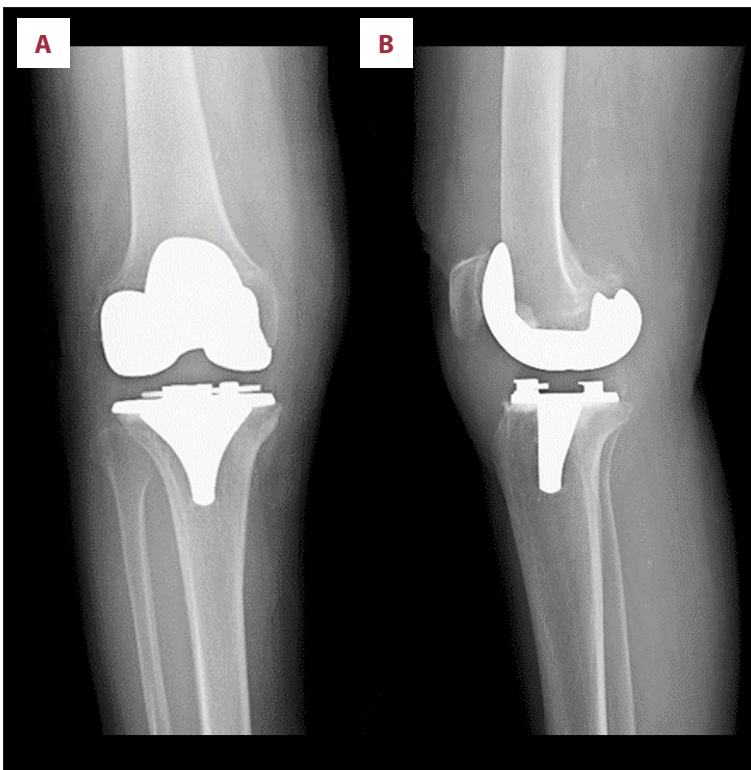
**Figure 2.** Postoperative radiograph of the right knee (Case 1), anteroposterior (A) and lateral (B) views.



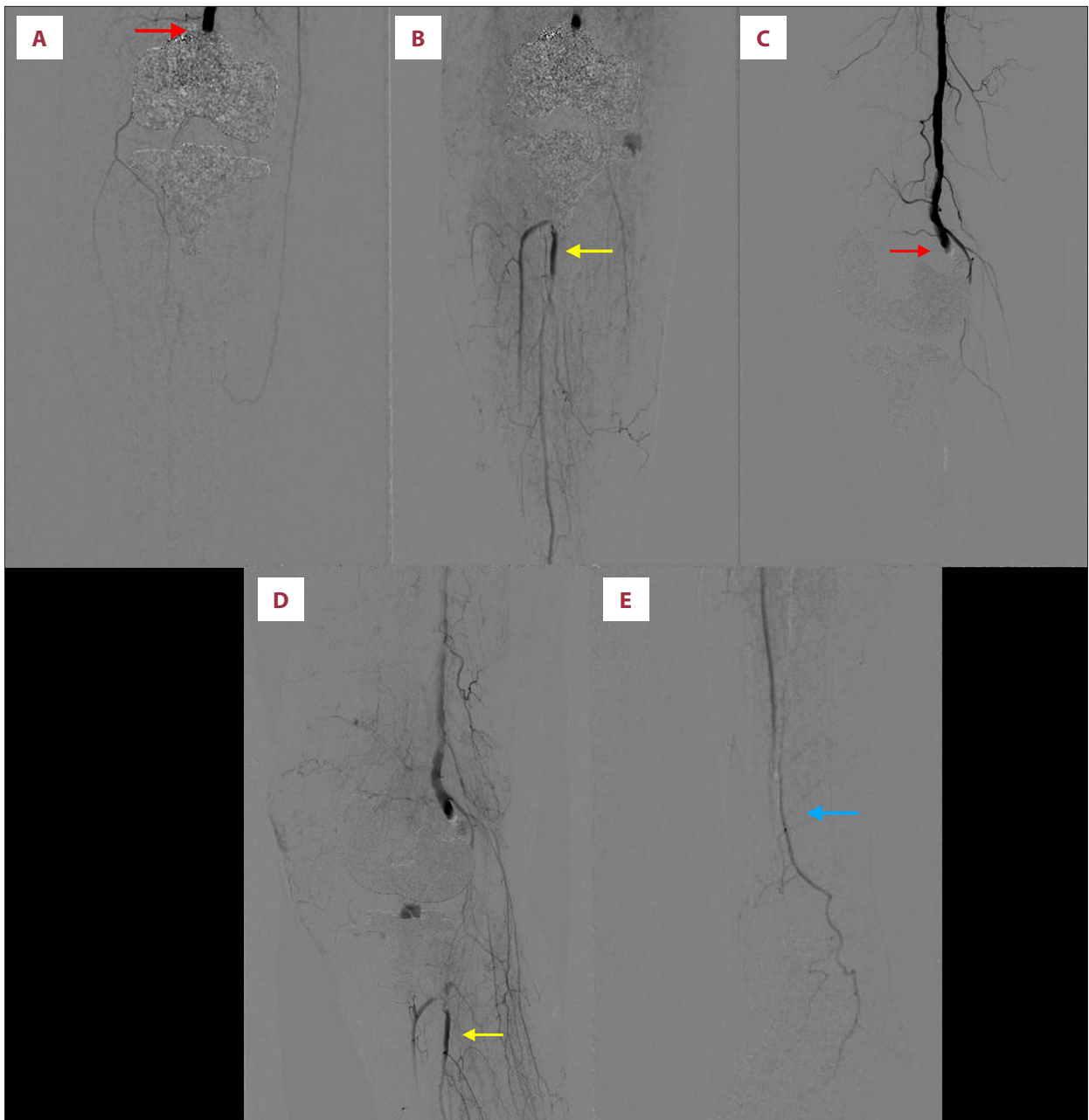
**Figure 3.** Angiography of the right knee showing occlusion of the popliteal artery with collateral perfusion of the anterior tibial artery, peroneal artery, and dorsalis pedis artery (Case 1); anteroposterior (A) and lateral (C) views of early phase showing occlusion of the popliteal artery (red arrow); anteroposterior (B) and lateral (D) views of late phase showing collateral perfusion of the anterior tibial artery and the peroneal artery (yellow arrow); and angiography of the right foot (E) showing the blood flow of the dorsalis pedis artery (blue arrow).



**Figure 4.** Preoperative radiograph of the right knee (Case 2), anteroposterior (A) and lateral (B) views.



**Figure 5.** Postoperative radiograph of the right knee (Case 2), anteroposterior (A) and lateral (B) views.



**Figure 6.** Angiography of the right knee showing occlusion of the popliteal artery with collateral perfusion of the anterior tibial artery; the peroneal artery and medial plantar artery (Case 2); anteroposterior (A) and lateral (C) views of early phase showing occlusion of the popliteal artery (red arrow); anteroposterior (B) and lateral (D) views of late phase showing collateral perfusion of the anterior tibial artery and peroneal artery (yellow arrow); and angiography of the right foot (E) showing the blood flow of the medial plantar artery (blue arrow).

vagal reflex; anemia was also detected. If the patient had been in good overall health, there was the possibility that surgical intervention would have been performed. However, based on evidence of adequate peripheral circulation and the patient's poor overall condition for surgical intervention, which was caused by syncope and anemia, we proceeded with conservative treatment, which was judged appropriate by a cardiovascular

surgeon. We were prepared to proceed to surgical treatment if symptoms of impaired circulation developed. After the patient returned to the Intensive Care Unit, the dorsalis pedis and posterior tibial pulses recovered gradually. The foot became gradually warmer, with recovery of normal foot sensation and movement. The patient subsequently underwent anticoagulant (Bayaspirin, 100 mg/day) and vasodilator (alprostadil,

10 µg, 2/day) therapies, with rehabilitation conducted according to the usual institutional protocol. At 6 months after surgery, the patient had a ROM of 0° to 100° and was able to walk without intermittent claudication.

## Discussion

We report 2 cases of the successful conservative treatment for acute popliteal artery occlusion after TKA. The most important inference derived from our experiences in these patients was that a collateral circulation around the area of arterial occlusion likely contributed to the conservative treatment success. The incidence of arterial complications after TKA including arterial occlusion, arteriovenous fistula, arterial aneurysm, and arterial severance are rare, with a reported rate of 0.033% to 0.17% in large patient populations [5-7]. However, acute arterial occlusion may be limb-threatening if not treated appropriately. For risk assessment of arterial complication, preoperative physical examinations are necessary, which include Doppler ultrasound and regularly measured preoperative peripheral pulses test, ankle-brachial index, capillary refill, and oxygen saturation [10]. Preoperative peripheral circulation assessment may contribute to judging whether conservative treatment will be successful.

Reported risk factors of arterial complications after TKA include a history of arterial insufficiency, preexisting atherosclerotic disease, including inducing factors, such as dyslipidemia, diabetes, hypertension, prior smoking, and obesity, preexisting peripheral vascular disease, previous vascular surgery, atrial fibrillation, history of cancer, absent or asymmetrical pedal pulses, presence of a popliteal aneurysm, calcification of the distal superficial femoral artery or the popliteal artery, and an extreme flexion contracture [4,10-15]. Redo arthroplasty has double the rate of arterial injury [6]. The correction of an extreme flexion contracture (>30°) leads to a reduction in the lumen of the artery due to its elongation [4]. Moreover, implant design might have some influence on artery occlusion after TKA. For TKA, constrained prosthesis designs, such as the posterior stabilized design, might have a higher risk than the cruciate retaining design, especially for knees with severe deformity, which need further osteotomy or soft tissue release [10]. The intraoperative risk factors include the insertion of the retractor into the posterolateral corner of the tibia, excision of the posterior osteophyte, and nonphysiological manipulation of the knee [4,16,17]. One of the mechanisms of arterial occlusion is the intimal injury of the popliteal artery with unrecognized distraction, kinking, or torsion during the performance of TKA [11]. In addition, the damage to the intima can already have occurred when the maximum pressure of the tourniquet is reached, regardless of the duration of ischemia [4]. In our case, both patients with obesity and flexion

contracture ≥30° underwent TKA utilizing the posterior stabilized prosthesis. We suggest that careful evaluation of circulation be carried out before surgery in addition to full preparation before surgery and careful performance during surgery, especially for patients with higher risks of arterial occlusion.

Acute arterial occlusions after TKA should be diagnosed as soon as possible and the arterial condition should be accurately assessed to prevent amputation or death. In a report by Green and Allen, 86% of the patients required amputation if the surgery was performed more than 8 h after interruption of the popliteal arterial blood flow [18]. The first presentation as a warning of occlusion is particularly important and useful. The classic presentation of limb ischemia is known as the 6Ps: pallor, pain, paresthesia, paralysis, pulselessness, and poikilothermia [19]. The peripheral pulses test is an easy and essential physical examination for early diagnosis. Zeng et al found that 43% of patients with arterial occlusion had decreased or absent pulses [10]. If the pulses are abnormal, additional examinations, such as Doppler ultrasound and angiography, should be performed. Angiography gives precise vascular imaging. In our 2 cases, the reason conservative therapy was chosen was because the patients did not present the 6Ps and angiography showed adequate peripheral circulation. However, whether collateral circulation is rich is a subjective assessment. To make that assessment, it is important to make a comprehensive judgment that includes clinical symptoms for ischemia, including the 6Ps, and Doppler ultrasonography. Saunders et al reported that late recognition of iatrogenic arterial injury after TKA caused an above-knee amputation and that it is necessary for surgeons performing TKA to be aware of the potential risk factors for arterial injury and to maintain a high index of suspicion for these infrequent injuries during the postoperative period [20].

There are various treatments for arterial occlusion. The conservative treatment includes anticoagulation, thrombolysis, vasodilation, and fasciotomy, while surgical treatment includes thrombectomy, balloon angioplasty, bypass graft, and stent [10]. Surgical revascularization has long been the standard approach to restoration of limb perfusion [21]. Postoperative repair of arterial injuries was associated with excellent limb salvage rates of 94.1% [7]. Calligaro et al reported that arterial thrombectomy was successful in only approximately one-fourth (5/18, 28%) of the acute ischemic complications associated with TKA [6]. However, due to advancements in thrombolytic therapy and catheter based techniques, endovascular approaches have emerged as first-line therapy in the treatment of acute limb ischemia [21]. Few studies have reported the results of conservative treatments. Li et al reported a case of anterior tibial artery (ATA) occlusion after TKA that was treated without surgery [9]. They explained that ATA is not the major artery responsible for circulation in the lower extremity, and therefore,

ATA occlusion can be managed conservatively without aggressive treatment. However, the popliteal artery divides into its terminal branches as the ATA and posterior tibial artery, and acute popliteal artery occlusion results in sudden loss of arterial perfusion to the lower extremity. In both of our cases, due to the presence of collateral circulation to the foot, the lower extremity was not in vasoocclusive crisis, despite the occlusion not being resolved. The collateral circulation, although speculated, is difficult to predict. We do note, however, that the amount of collateral circulation needed to adequately manage popliteal artery occlusion conservatively is unknown. One of the noninvasive techniques of microcirculation perfusion analysis is skin perfusion pressure, which is an essential modality for evaluating ischemia severity and predicting wound healing and limb loss [22]. The postoperative skin perfusion pressure may be a parameter when evaluating postoperative circulation. Although most acute arterial complications after TKA were diagnosed on the day of surgery [23], we should be aware of the possibility of arterial occlusion in the postoperative period and be watchful for symptoms of limb ischemia.

## References:

1. Zhang Y, Jordan JM. Epidemiology of osteoarthritis. *Clin Geriatr Med.* 2010;26(3):355-69
2. Jones CA, Beaupre LA, Johnston DW, Suarez-Almazor ME. Total joint arthroplasties: Current concepts of patient outcomes after surgery. *Clin Geriatr Med.* 2005;21(3):527-41, vi
3. Menendez ME, Memsoudis SG, Opperer M, et al. A nationwide analysis of risk factors for in-hospital myocardial infarction after total joint arthroplasty. *Int Orthop.* 2015;39(4):777-86
4. Matziolis G, Perka C, Labs K. Acute arterial occlusion after total knee arthroplasty. *Arch Orthop Trauma Surg.* 2004;124(2):134-36
5. Rand JA. Vascular complications of total knee arthroplasty. Report of three cases. *J Arthroplasty.* 1987;2(2):89-93
6. Calligaro KD, Dougherty MJ, Ryan S, Booth RE. Acute arterial complications associated with total hip and knee arthroplasty. *J Vasc Surg.* 2003;38(6):1170-77
7. Abularrage CJ, Weiswasser JM, Dezee KJ, et al. Predictors of lower extremity arterial injury after total knee or total hip arthroplasty. *J Vasc Surg.* 2008;47(4): 803-7; discussion 807-8
8. Dua A, Zepeda R, Hernandez FC, et al. The national incidence of iatrogenic popliteal artery injury during total knee replacement. *Vascular.* 2015;23(5):455-58
9. Li X, Song Y, Wang J. Anterior tibial artery occlusion post total knee arthroplasty: A case report. *Medicine (Baltimore).* 2019;98(29):e16503
10. Li Z, Xiang S, Bian YY, et al. Diagnosis and treatment of arterial occlusion after knee arthroplasty: The sooner, the better. *Orthop Surg.* 2019;11(3):366-72
11. Bayne CO, Bayne O, Peterson M, Cain E. Acute arterial thrombosis after bilateral total knee arthroplasty. *J Arthroplasty.* 2008;23(8):1239.e1-6
12. Park BJ, Cho HM, An KY, Lee HJ. Acute arterial occlusion following primary total knee arthroplasty. *Knee Surg Relat Res.* 2018;30(1):84-88
13. Smith DE, McGraw RW, Taylor DC, Masri BA. Arterial complications and total knee arthroplasty. *J Am Acad Orthop Surg.* 2001;9(4):253-57
14. Park IH, Lee SC, Park IS, et al. Asymptomatic peripheral vascular disease in total knee arthroplasty: Preoperative prevalence and risk factors. *J Orthop Traumatol.* 2015;16(1):23-26
15. Nicolajsen CW, Dickenson MH, Budtz-Lilly J, Eldrup N. Frequency of cancer in patients operated on for acute peripheral arterial thrombosis and the impact on prognosis. *J Vasc Surg.* 2015;62(6):1598-606
16. Ninomiya JT, Dean JC, Goldberg VM. Injury to the popliteal artery and its anatomical location in total knee arthroplasty. *J Arthroplasty.* 1999;14(7):803-9
17. Tindall AJ, Shetty AA, James KD, et al. Prevalence and surgical significance of a high-origin anterior tibial artery. *J Orthop Surg (Hong Kong).* 2006;14(1):13-16
18. Green NE, Allen BL. Vascular injuries associated with dislocation of knee. *J Bone Jt Surg.* 1977;59(2):236-39
19. Smith DA, Lilie CJ. Acute arterial occlusion. [Updated 2021 Dec 16]. In: StatPearls [Internet]. Treasure Island (FL): StatPearls Publishing; Available from: <https://www.ncbi.nlm.nih.gov/books/NBK441851/>
20. Saunders JH, Subramonia S, Tennant WG. Endovascular repair of iatrogenic popliteal artery trauma. *Eur J Trauma Emerg Surg.* 2012;38(6):617-22
21. Lind B, Morcos O, Ferral H, et al. Endovascular strategies in the management of acute limb ischemia. *Vasc Specialist Int.* 2019;35(1):4-9
22. Ikeoka K, Watanabe T, Shinoda Y, et al. Below-the-ankle arrival time as a novel limb tissue perfusion index: Two-dimensional perfusion angiography evaluation. *J Endovasc Ther.* 2020;27(2):198-204
23. Troutman DA, Dougherty MJ, Spivack AI, Calligaro KD. Updated strategies to treat acute arterial complications associated with total knee and hip arthroplasty. *J Vasc Surg.* 2013;58(4):1037-42

## Conclusions

Acute arterial occlusion associated with TKA is a rare but occasionally limb-threatening complication. For most patients, surgical treatment is chosen. In certain cases, however, conservative treatment can be chosen under watchful waiting. Adequate postoperative and preoperative assessment of the patient's arterial condition is essential to the successful management of acute arterial occlusion.

## Department and Institution Where Work Was Done

Department of Orthopedic Surgery, Kobe University Graduate School of Medicine

## Declaration of Figures' Authenticity

All figures submitted have been created by the authors who confirm that the images are original with no duplication and have not been previously published in whole or in part.